

LETTER OF APPROVAL / RECOMMENDATION



To,

The Coordinator,
Mediwheel (Arcofemi Healthcare Limited)
Helpline number: 011- 41195959

Dear Sir / Madam,

Sub: Annual Health Checkup for the employees of Bank of Baroda

This is to inform you that the following employee wishes to avail the facility of Cashless Annual Health Checkup provided by you in terms of our agreement.

PARTICULARS	EMPLOYEE DETAILS
NAME	MR. MISHRA RAKESH KUMAR
EC NO.	123739
DESIGNATION	SINGLE WINDOW OPERATOR A
PLACE OF WORK	DHANBAD
BIRTHDATE	26-09-1978
PROPOSED DATE OF HEALTH CHECKUP	11-09-2021
BOOKING REFERENCE NO.	21S123739100003646E

This letter of approval / recommendation is valid if submitted along with copy of the Bank of Baroda employee id card. This approval is valid from **08-09-2021** till **31-03-2022** The list of medical tests to be conducted is provided in the annexure to this letter. Please note that the said health checkup is a **cashless facility** as per our tie up arrangement. We request you to attend to the health checkup requirement of our employee and accord your top priority and best resources in this regard. The EC Number and the booking reference number as given in the above table shall be mentioned in the invoice, invariably.

We solicit your co-operation in this regard.

Yours faithfully,

Sd/-

Chief General Manager
HRM Department
Bank of Baroda

(Note: This is a computer generated letter. No Signature required. For any clarification, please contact Mediwheel (Arcofemi Healthcare Limited))



बैंक ऑफ़ बड़ौदा
Bank of Baroda



नाम : राकेश कुमार मिश्र
Name : Rakesh Kumar Mishra

कर्मचारी कूट क्र 123739
E.C. No. : 123739

RK

If found, please return to,

Asst. General Manager (HRM)

Bank of Baroda, Baroda Surya Bhawan, Main Road Bistupur

Jamshedpur-831001, Jharkhand

Phone +91 657 424910, 6459458

PERMANENT ADDRESS : C/o. Pankaj Mishra, Mathuranagar, Kola Kusma
P.O.- K.G. Ashram, Dist.- Dhanbad,
Jharkhand-828109

EMERGENCY CONTACT NO. : 9425794937

रक्त समूह / Blood Group : O-

पहचान चिन्ह / Identification Marks : One black mole on right shoulder



Type : Mediwheel

DEPARTMENT OF GENERAL MEDICINE

Regd. No.	: SEP21-22921	Visit	: OPD/110921/450
Patient Name	: MR. MISHRA RAKESH KUMAR	Mobile	: 9425794937
Age/Sex	: 42 Yrs / MALE	Date	: 11-Sep-2021
Address	: MATHURA NAGAR, KOLA KUSMA-, DHANBAD Jharkhand, INDIA		
Doctor	: Dr. PANKAJ KUMAR (M.B.B.S, DNB-GENERAL MEDICINE)		
OPD Timing	:		

BP - 122/81 mmHg.
Q 81 bpm

full body health checkup.

Invest

- LAT
- routine urine.
- T3, T4, TSH
- PSA
- HbA1c
- ESR
- CBC
- Blood Creatinine
- blood urea nitrogen
- lipid profile.
- usg whole abdomen
- x-ray chest
- echo rd.
- BGLU
- KFT panel.

Adv

- no need medicine.


Dr. PANKAJ
DNB (Medicine)



DEPARTMENT OF PATHOLOGY

Name : MR. MISHRA RAKESH KUMAR
Age : 42 Yrs Sex : Male
Doctor : SELF WALK-IN
Reg. No. : SEP21-22921
Sub Dept. : Biochemistry

Lab No: : 2,639
Collection Date: 11-Sep-2021
Collection Time: 12:49:00PM
Reporting Date : 14-Sep-2021

Test	Result	Reference Range
LIVER FUNCTION TEST (LFT)		
Bilirubin (Total)	0.4 mg/dl	0.2 - 1.0 mg/dl
Bilirubin (Direct)	0.2 mg/dl	0 - 0.2 mg/dl
Bilirubin (Indirect)	0.2 mg/dl	0.2 - 0.8 mg/dl
Total Proteins	7.2 g/dl	6.5 - 8.5 g/dl
Albumin	4.1 g/dl	3.5 - 5.5 g/dl
Globulin	3.1 g/dl	1.5 - 3.5 g/dl
SGOT	24.9 IU/L	< 40 IU/L
SGPT	45.4 IU/L	< 49 IU/L
Alkaline Phosphatase	212.5 IU/L	70-306 IU/L
Gamma-GT	47.9 U/L	0-55 U/L

DEPARTMENT OF PATHOLOGY

Name : MR. MISHRA RAKESH KUMAR
Age : 42 Yrs Sex : Male
Doctor : SELF WALK-IN
Reg. No. : SEP21-22921
Sub Dept. : Clinical Pathology

Lab No: 2,637
Collection Date: 11-Sep-2021
Collection Time: 12:48:52PM
Reporting Date: 14-Sep-2021

Test	Result	Reference Range
<u>Routine Examination of Urine</u>		
Quantity	30 ml (Approx)	
Colour	STRAW	
Appearance	CLEAR	
Specific Gravity	1.010	
Reaction (pH)	ACIDIC	
Albumin.	NIL	
Sugar	NIL	
Ketone Bodies	XX	
Bile Salts	XX	
Bile Pigments	XX	
RBC	NIL /hpf	/hpf
Pus Cells	0-1 /hpf	
Epithelial Cells	0-1	/hpf.
Casts	NOT SEEN /hpf.	/hpf.
Crystals	NOT SEEN /hpf.	/hpf.
Bacteria	NOT SEEN /hpf.	/hpf.



24 HOUR EMERGENCY

"KEEP THE REPORTS CAREFULLY AND BRING THEM ALONG DURING YOUR NEXT VISIT TO OUR HOSPITAL"



DEPARTMENT OF PATHOLOGY

Name : MR. MISHRA RAKESH KUMAR
Age : 42 Yrs Sex : Male
Doctor : SELF WALK-IN
Reg. No. : SEP21-22921
Sub Dept. : Immunology

Lab No: : 2,639
Collection Date: 11-Sep-2021
Collection Time: 12:49:00PM
Reporting Date : 14-Sep-2021

Test	Result	Reference Range
<u>Thyroid hormones T3 T4 TSH (Enzyme Immunoassay)</u>		
T3, Total, Serum	0.95 ng/ml	0.74-1.79 ng/ml
T4, Total, Serum	7.72 ng/dl	4.7-12.8 ng/dl
TSH, SERUM (Enzyme Immunoas:	1.89 μ IU/ml	0.25-5.00 μ IU/ml
<u>PSA (PROSTATIC SPECIFIC ANTIGEN TEST TOTAL)</u>		
P.S.A.	0.32 ng/ml.	0.0 - 4.0 Border line 4.0 - 10.0 ng/ml.
<u>HbA1c (glycosylated Hb)</u>		
glycosylated Hb	6.0 %	4.6-6.2 %
<u>ESR</u>		
E.S.R (Westergren)	23 mm/hr	0 - 20 mm/hr





DEPARTMENT OF PATHOLOGY

Name : MR. MISHRA RAKESH KUMAR
Age : 42 Yrs Sex : Male
Doctor : SELF WALK-IN
Reg. No. : SEP21-22921
Sub Dept. : Haematology

Lab No: : 2,632
Collection Date: 11-Sep-2021
Collection Time: 12:48:31PM
Reporting Date : 14-Sep-2021

Test	Result	Reference Range
	<u>CBC</u>	
Haemoglobin	13.9 g/dl	13 - 18 g/dl
Red Blood Cells Count	5.00 / cumm	4.0 - 6.0 / cumm
TOTAL COUNT OF PLATELET	1.93 lakhs/cumm	1 - 4 lakhs/cumm
Total WBC Count	9,400 /cumm	4000 - 11000 /cumm
Neutrophils	41 %	55 - 75 %
Lymphocytes	44 %	15 - 30 %
Eosinophils	12 %	1 - 6 %
Monocytes	03 %	2 - 10 %
Basophils	00 %	0 - 1 %
PCV	41.3 %	40 - 54 %
MCV	82.6 cu-microns	80 - 99 cu-microns
MCHC	33.7 %	32 - 38 %
	<u>Blood Grouping</u>	
ABO Group	"O"	
Rh (Factor)	NEGATIVE	
	<u>Blood Urea Nitrogen</u>	
Blood Urea Nitrogen	12.4 mg/dl	5 - 20 mg/dl



DEPARTMENT OF PATHOLOGY

Name : MR. MISHRA RAKESH KUMAR
Age : 42 Yrs Sex : Male
Doctor : SELF WALK-IN
Reg. No. : SEP21-22921
Sub Dept. : Biochemistry

Lab No: : 2,639
Collection Date: 11-Sep-2021
Collection Time: 12:49:00PM
Reporting Date : 14-Sep-2021

Test	Result	Reference Range
	<u>Lipid Profile</u>	
Serum Cholesterol	150.0 mg/dl	150 - 250 mg/dl
Serum Triglyceride	115.0 mg/dl	50-190 mg/dl
HDL Cholesterol	50.3 mg/dl	35 - 55 mg/dl
LDL Cholesterol	76.7 mg/dl	Upto 160 mg/dl
VLDL Cholesterol	23.0 mg/dl	Upto 60 mg/dl

Dhanbad's 1st NABH & NABL Certified Hospital & Lab

PATHOLOGIST



अंशु हॉस्पिटल
सबके लिए स्वास्थ्य

Baramuri, P.O. - Bishunpur Polytechnic, Dhanbad (Jharkhand) - 828130
Regd. Office : Phulaniand, Kharkaree, Dhanbad (Jharkhand) - 828125
Mob.: 9234302735, 9234651512, 9234661514
CIN : U85110JH2005PLC011673

RADIOLOGY REPORT

Patient Information			
Patient Name	MR MISHRA RAKESH KUMAR.	Patient ID	22921
Age Gender	42Y/MALE	Scan Date	SEP 11 2021
Referring Doctor	DR SELF	Report Date	SEP 11 2021

X-RAY CHEST

VIEWS

PA View of Chest

FINDINGS

Lungs

- Prominent broncho-vascular markings both para hilar shadow.
- Rest of the bilateral lungs fields are clear.

Airways

- Trachea is central. Tracheo-bronchial tree is normal.

Heart

- Cardiac silhouette is normal.

Others

- Bilateral CP angles are clear.
- Both domes of diaphragm are normally placed.
- Bony thoracic cage is normal.
- No soft tissue abnormality seen.

IMPRESSION

- Prominent broncho-vascular markings both para hilar shadow.

RECOMMENDATION

Suggested clinical correlation

Dr. Kajal Agarwal

MD Radiology

Consultant Radiologist

Disclaimer

It is an online interpretation of medical imaging based on the available clinical data. Patient's identification in online reporting is not established, so this report cannot be utilized for any medico legal purpose/ certifications. All modern machines/procedures have their own limitations. If there is any clinical discrepancy, this investigation may be repeated or reassessed by other tests.

MR MISHRA RAKESH KUMAR 42Y/M DR SELF 1

© AHL/D/0070

24 HOUR EMERGENCY



"KEEP THE REPORTS CAREFULLY AND BRING THEM ALONG DURING YOUR NEXT VISIT TO OUR HOSPITAL"



OUT PATIENT DEPARTMENT

ECHOCARDIOGRAPHY REPORT

Name: MR RAKESH KUMAR MISHRA

Age: 42

Sex: Male

Date: 11/09/2021

2D & M-MODE MEASUREMENTS

IVSd	1.1 cm
LVIDd	4.6 cm
LVPWd	1.1 cm
IVSs	1.6 cm
LVIDs	2.9 cm
Ao Diam	3.6 cm
LA Diam	3.7 cm

2D & M-MODE CALCULATIONS

EDV(Teich)	95 ml
ESV(Teich)	33 ml
EF(Teich)	66 %
%FS	36 %
SV(Teich)	63 ml
LVd Mass	205.63 g
RWT	0.49
LA/Ao	1.03

MITRAL VALVE

MV E Vel	0.83 m/s
MV DecT	199 ms
MV Dec Slope	4.2 m/s ²
MV A Vel	0.64 m/s
MV E/A Ratio	1.29

AORTIC VALVE

AV Vmax	1.27 m/s
AV maxPG	6.40 mmHg

TRICUSPID VALVE

PV Vmax	0.96 m/s
PV maxPG	3.67 mmHg

PULMONARY VALVE

COMMENTS:

- NORMAL SIZE OF CARDIAC CHAMBERS
- NO LVRWMA
- GOOD LV SYSTOLIC FUNCTION(EF-63%)
- NO MR, AR, TR
- IAS, IVS INTACT
- NO CLOT, PE
- IVC NORMAL

IMPRESSION:

- NORMAL SIZE OF CARDIAC CHAMBERS
- NO LVRWMA
- GOOD LV SYSTOLIC FUNCTION(EF-63%)

DR. S.H. CHAVAN
(CONSULTANT CARDIOLOGIST)

TECH. SIG

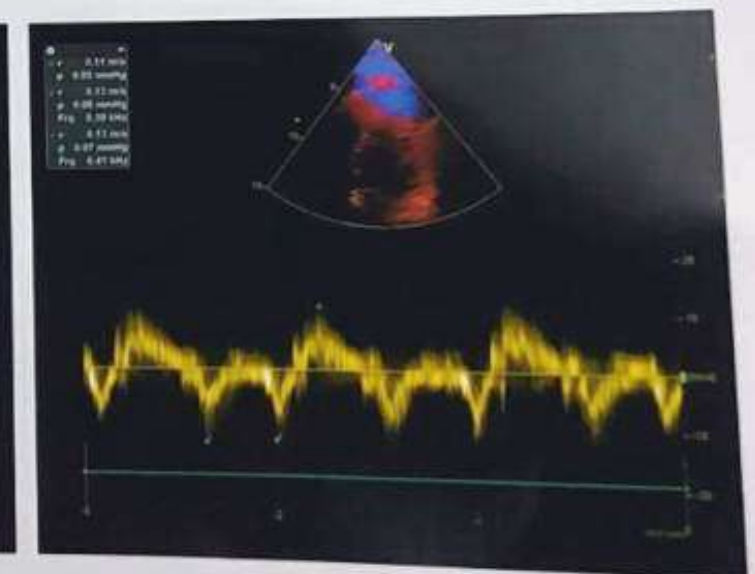
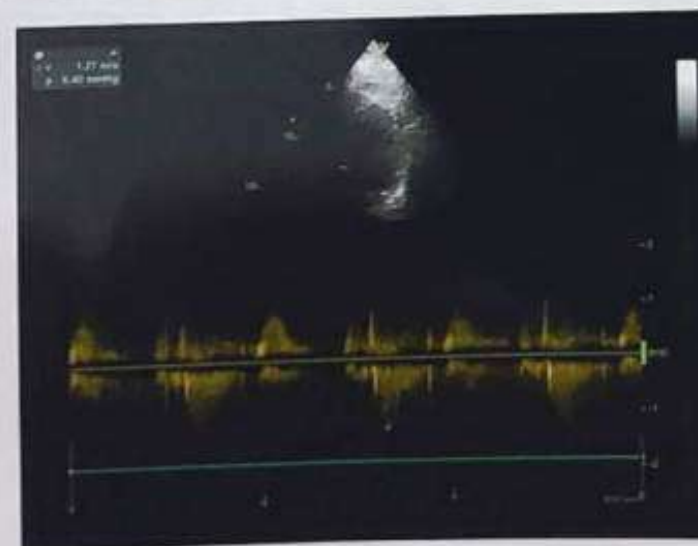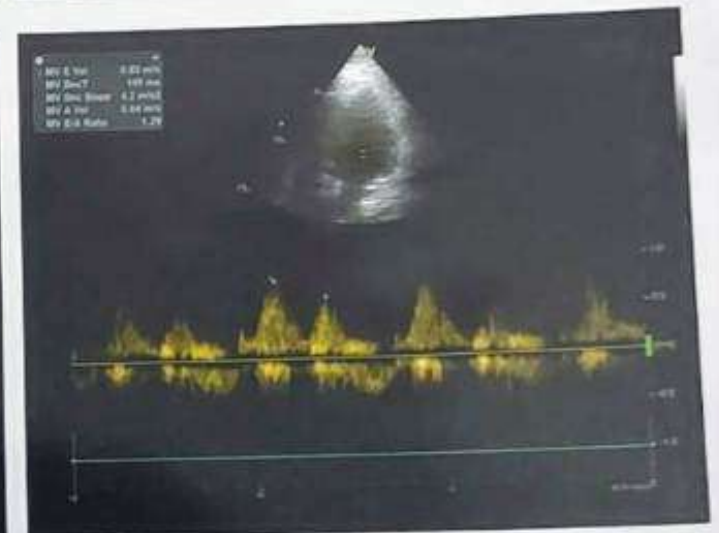
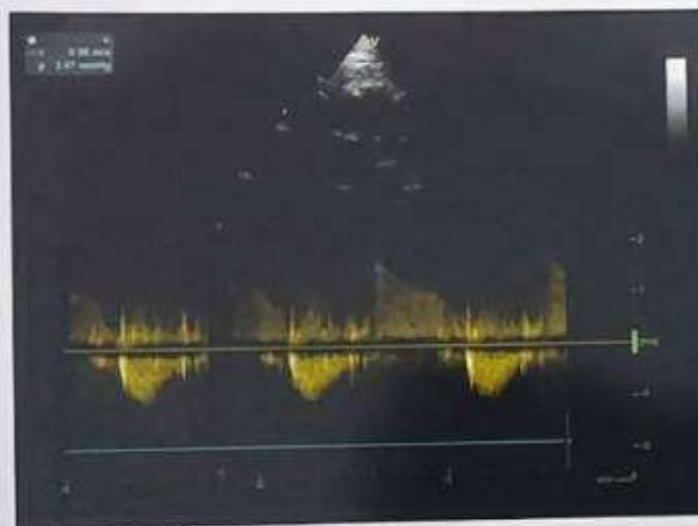
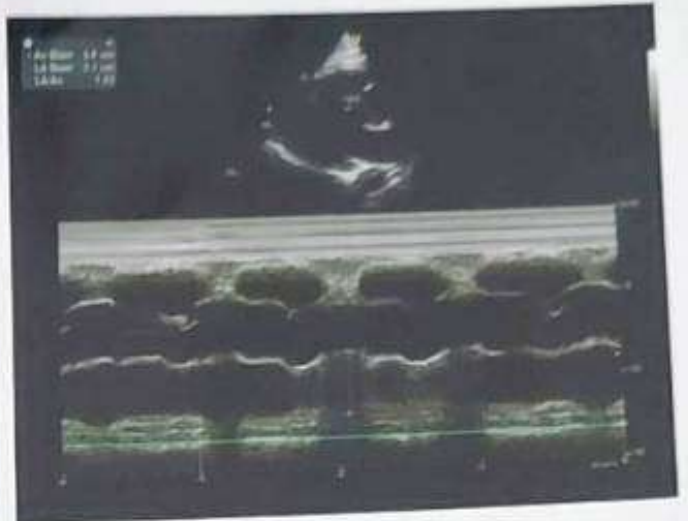
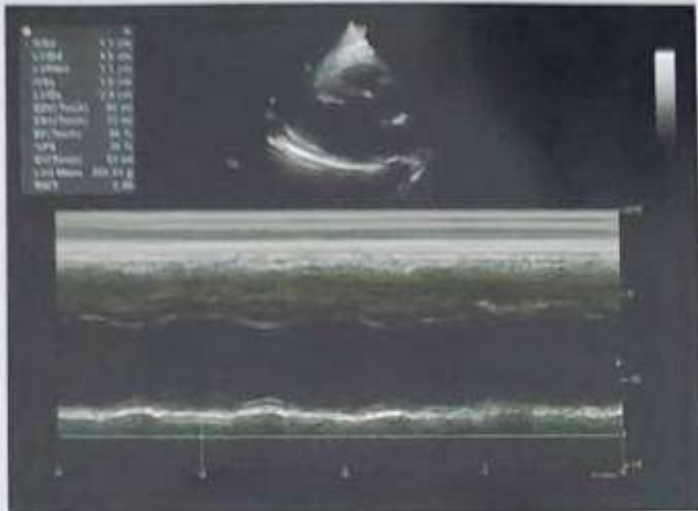


MEDICA HEART INSTITUTE, DHANBAD

Name : MR RAKESH KUMAR MISHRA

Date : 11/09/2021

Patient Id : MR RA45_45723






RADIOLOGY REPORT

Reg.No.	22921	Ref.Dr.	SELF
Name	MR. MISHRA RAKESH KR.	Study	USG WHOLE ABDOMEN
Age & Sex	42Y/M	Reporting Date	11.09.2021

USG WHOLE ABDOMEN

- LIVER** : Liver is normal in size & shape. It appears bright in echotexture. No obvious focal lesion is seen. IHBR are not dilated.
- GALL BLADDER** : GB is well distended. No obvious calculus or mass lesion is seen. The wall thickness is normal.
- CBD** : CBD is normal in course & caliber.
- PV** : PV is normal in course & caliber.
- PANCREAS** : Pancreas is normal in size, shape & echotexture. Peripancreatic soft tissues appear normal. MPD is not dilated.
- SPLEEN** : Spleen is normal in shape, size & echotexture. It measures 9.8 cm in size.
- KIDNEYS** : The right kidney measures 11.3 x 4.9 cm. The left kidney measures 10.5 x 5.3 cm. Both kidneys are normal in shape, size & position. The pelvicalyceal system is normal. Corticomedullary differentiation is maintained. No focal lesion is seen.
- URINARY BLADDER** : Urinary bladder is well distended. No obvious calculus or mass lesion is seen.
- PROSTATE** : Prostate is normal in size, shape & echotexture. It measures 3.4 x 4.3 x 2.9cm (volume - 22 grams)
- OTHERS** : No ascites or retroperitoneal lymphadenopathy is seen.
- IMPRESSION** :
 - Grade I diffuse fatty infiltration of liver.


11/09/2021
Dr. VAISHALI PATEL
MBBS, DNB (Radio-diagnosis)
Consultant Radiologist

