

**Health Check up Booking Request(bobE39563), Beneficiary Code-19666**

1 message

Mediwheel <wellness@mediwheel.in>  
To: vidhidiagnostics@gmail.com  
Cc: customercare@mediwheel.in

22 May 2023 at 14:33



**Mediwheel**  
...Your wellness partner



011-41195959

Email:wellness@mediwheel.in

Dear **VIDHI DIAGNOSTICS,**

**City :** Ahmedabad . **Address :** L-86 Swatantra - Senani Nagar , Opp- Akhbarnagar Bus Terminals, New Wadaj , Ahmedabad -13,

We have received the confirmation for the following booking .

**Name** : MS. LAXMIDHAR ANJUM ISMAILBHAI  
**Age** : 34  
**Gender** : Female  
**Package Name** : Medi-Wheel Metro Full Body Health Checkup Female Below 40  
**Contact Details** : 9723530348  
**Booking Date** : 22-05-2023  
**Appointment Date** : 27-05-2023

Member Information			
Booked Member Name	Age	Gender	Cost(In INR)
MS. LAXMIDHAR ANJUM ISMAILBHAI	34	Female	Cashless
Total amount to be paid			Cashless

We will get back to you with confirmation update shortly. Please find the package details as attached for your reference.

**Package Name** : Medi-Wheel Metro Full Body Health Checkup Female Below 40 - Includes (37)Tests

**Tests included in this Package**

Ecg, TSH, X-ray Chest, Stress Test (tmt)/ 2d Echo, Blood Sugar Postprandial, A:g Ratio, Blood Group, Total Cholesterol, Triglycerides, Fasting Blood Sugar, Ultrasound Whole Abdomen , Glycosylated Haemoglobin (hba1c), Hdl, Vldl, Urine Analysis, LDL, Total Protine, General Consultation, HDL/ LDL ratio, GGT(Gamma-glutamyl Transferase), Eye Check-up consultation, ALP (ALKALINE PHOSPHATASE), Uric Acid, AST/ALT Ratio, Serum Protein, CBC with ESR, Stool Analysis, Urine Sugar Fasting, Urine Sugar PP, T3, T4, Cholesterol Total / HDL Ratio, BUN, BUN/Creatinine Ratio, Bilirubin Total & Direct and Indirect, Albumin, Globulin

### Medical Examination Report

Date : 27-05-2023

#### 1. Personal Particulars

Name : Leximidhar Anjum Ismailbhai










Age : 36 years Gender : Male / Female

Marital Status : Married

Past & Present Medical History : H/O LSCS - OM 2015  
Currently taking tabs. Thy medicine

#### 2. Clinical Medical Examination

Height : 162 cm Weight : 63 kg  
Blood Pressure : 118/84 mmHg Pulse : 68 p/min

General Condition :  Skin :   
Central Nervous System :  Head & Neck :   
Cardiovascular System :  Chest :   
Abdomen :  Limbs :   
Last menstrual period : 

Vision: Right: 6/6 N/6 Left: 6/6 N/6

Colour vision : Normal/Colour Blind

Personal Habit : NO

Remarks : Fit / Unfit for employment

Dr. Vidhi D. Modh  
MBBS

Dr's name, signature & chop

Vidhi Diagnostics  
L-86, Swatantra Senani Nagar,  
Opp. Akhbarnagar Bus Terminals,  
Nr. Akhbarnagar Circle,  
New Vadaj, Ahmedabad-13.

27-05-2023 09:47:28

ID: 9444

Name: laxmidhar anjum ismailbhai

Age: 36yrs

Sex: Female

Hospital:

Department:

HR : 67 bpm

PR : 110 ms

QRS : 80 ms

QT/QTc : 408/430 ms

P/QRS/T : 59/68/55 deg.

RV5/SV1 : 1.876/-1.042 mv

RV5+SV1 : 2.918 mv

<< Analysis Result >>

\*\* atypical ECG \*\*

Sinus rhythm

Short PR interval

**Vidhi Diagnostics**

L-86, Swatantra-Senani Nagar,

Opp. Akhbarnagar Bus Terminals,

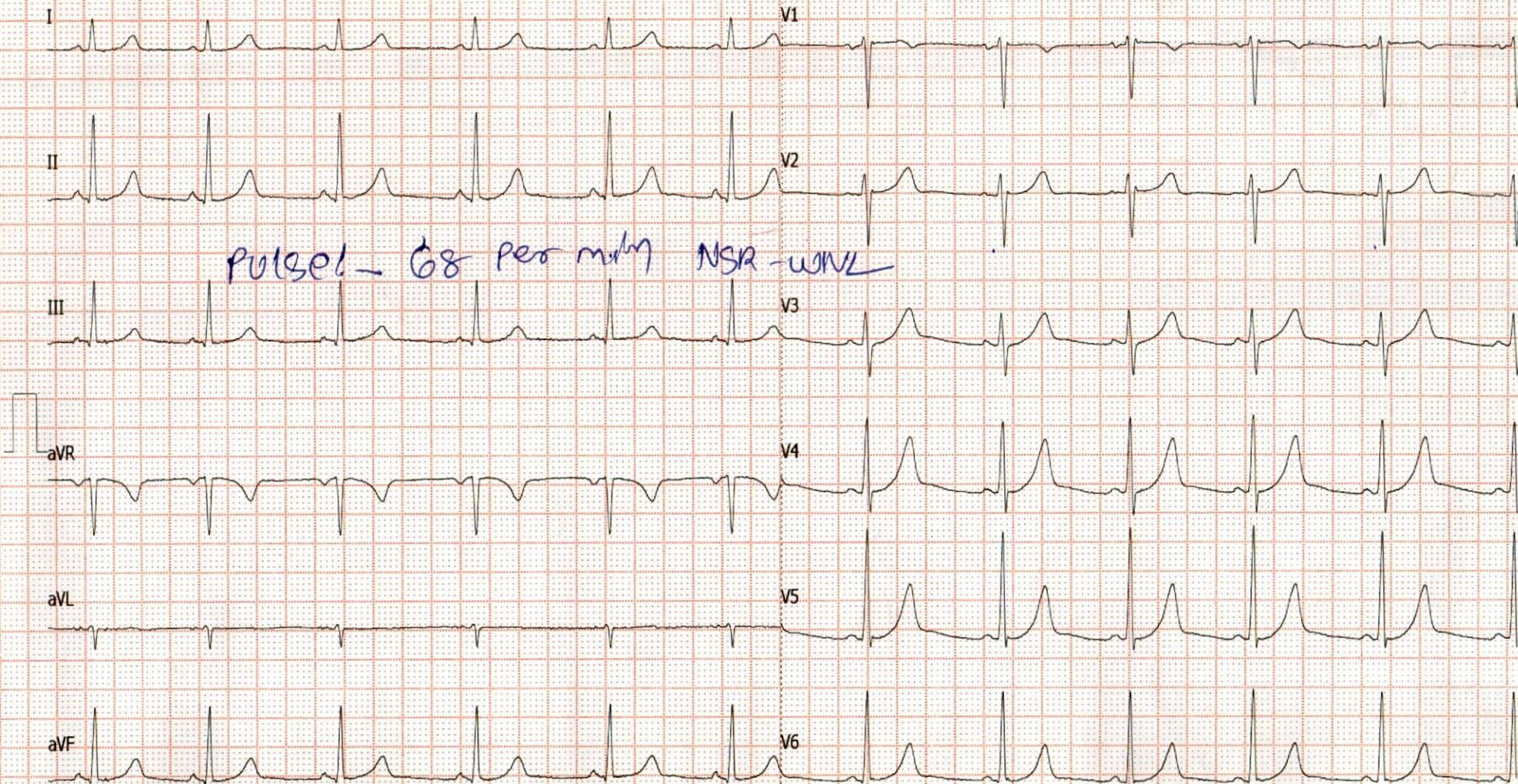
Nr. Akhbarnagar Circle,

New Wadaj, Ahmedabad-13.

**Dr. Avinash Bhaskar**  
KIMSBS. D Cardio  
Reg. No.: G-45946

Need to be confirmed by doctor. Doctor Name: \_\_\_\_\_

0.67Hz - 35Hz AC 50Hz 25 mm/s 10 mm/mv



## Dr. Dinesh S. Modh

M.D., D.M.R.E. (Radiodiagnosis)

Consultant Radiologist & Sonologist

Ex. Junior Lecturer, B.J. Medical College, Civil Hospital, A'bad.

Panel Doctor of L.I.C.



Patient's name: LAXMIDHAR ANJUM ISMAILBHAI  
Reg. ID : R-2268-23  
Referred by : Dr. MEDIWHEEL

Age/Sex : 36 Years/Female  
Accession : 6288  
Date : 27/05/2023

### X-RAY CHEST (PA VIEW)

Both lung fields appear normal.  
No e/o consolidation or cavitations is seen.  
Both costo-phrenic angles appear clear.  
Cardiac size is with in normal limits.  
Both domes of diaphragm appear normal.  
Bony thoracic cage appears normal.

Thanks for reference.

  
Dr. Dinesh S. Modh  
MD DMRE (Radiodiagnosis)  
G-23825  
DR DINESH S. MODH  
M.D. DMRE(RADIODIAGNOSIS)

ISO 9001:2015 Certified Diagnostics Center

Vidhi Imaging Center

L-86, Swatantra Senani Nagar, Opp. Indian Oil Petrol Pump, Akhbarnagar Circle, Nava Vadaj, Ahmedabad - 380 013.

Phone : (Radiology) 079-2762 1406 | M. 98799 29406, 98250 09406 | Time (Radiology) : Mon. to Sat. 9 am to 2 pm, 5 to 9 pm, Sunday 9 am to 12 Noon

E-mail : vidhidiagnostics@gmail.com, Website : www.vidhidiagnostics.com

Multislice CT Scan | CBCT-Dental Scan | Live 3D-4D Sonography | Colour Doppler | Echo Cardiography | Interventional Radiology | Maxillofacial Radiology | Fetal Medicine  
Digital X-Ray | Digital Mammography | Digital OPG/TMJ | ECG/TMT/PFT/EEG/EMG | Audiometry | Pathology Laboratory | Health Check Up Plans | Pre Employment Check Up

**CT SCAN & CBCT FACILITY NOW AVAILABLE**

## Dr. Dinesh S. Modh

M.D., D.M.R.E. (Radiodiagnosis)  
Consultant Radiologist & Sonologist  
Ex. Junior Lecturer, B.J. Medical College, Civil Hospital, A'bad.  
Panel Doctor of L.I.C.



Patient's name: LAXMIDHAR ANJUM ISMAILBHAI  
Reg. ID : R-2268-23  
Referred by : Dr. MEDIWHEEL

Age/Sex : 36 Years/Female  
Accession : 6288  
Date : 27/05/2023

### 2D- ECHO REPORT

#### FINAL CONCLUSION:

LV IS NORMAL SIZE. GOOD LV SYSTOLIC FUNCTION NO RWMA.  
LVEF - 60%. NO CONCENTRIC LVH.  
NORMAL LV COMPLIANCE.  
LA IS NORMAL SIZE. NO LA CLOT.  
RV IS NORMAL SIZE. GOOD RV SYSTOLIC FUNCTION.  
RA IS NORMAL SIZE.  
MITRAL VALVE IS NORMAL. NO MS. MILD MR (15%). NO MVP.  
AORTIC VALVE IS NORMAL. NO AS. NO AR.  
TRICUSPID VALVE IS NORMAL. NO TR. RVSP-26 mmHg. NO PAH.

NO CLOT, NO VEGETATION, NO PERICARDIAL EFFUSION.

#### DIMENSIONS:

AORTA	2.6 C.M
LEFT ATRIUM	2.7 C.M
LVDD	4.1 C.M.
IVSD	1.0 C.M
PWD	1.0 C.M
LVDS	2.6 C.M..

#### COLOUR DOPPLER FINDING:

STRUCTURE	VELOCITY m/sec
	Max
PULMONARY VALVE	0.7
MITRAL VALVE	E : 0.7 A: 0.4
AORTIC VALVE	1.0

Dr. Avinash Bhaskar  
MBBS. D. Cardio  
Reg. No.: G-45946  
DR AVINASH BHASKAR

ISO 9001:2015 Certified Diagnostics Center

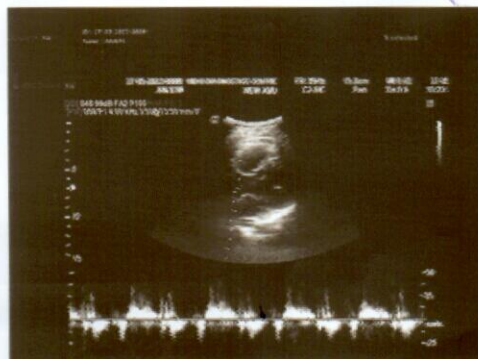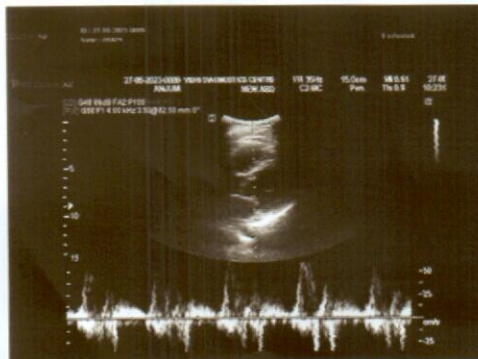
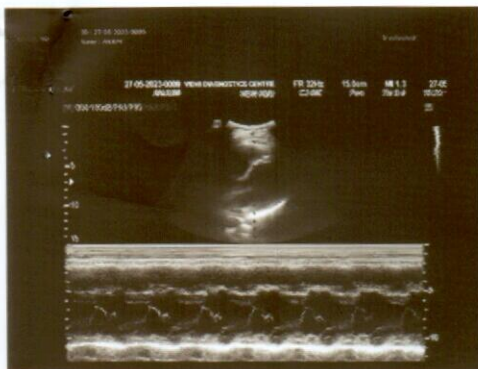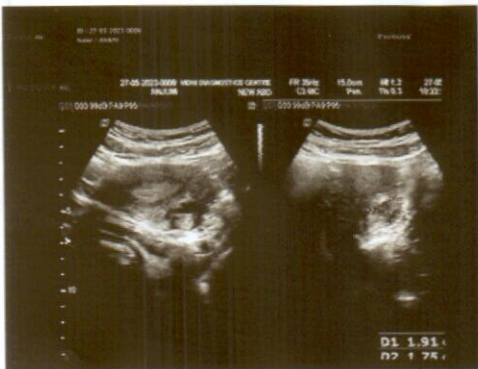
Vidhi Imaging Center

L-86, Swatantra Senani Nagar, Opp. Indian Oil Petrol Pump, Akharnagar Circle, Nava Vadaj, Ahmedabad - 380 013.

Phone : (Radiology) 079-2762 1406 | M. 98799 29406, 98250 09406 | Time (Radiology) : Mon. to Sat. 9 am to 2 pm, 5 to 9 pm, Sunday 9 am to 12 Noon  
E-mail : vidhidiagnostics@gmail.com, Website : www.vidhidiagnostics.com

Multislice CT Scan | CBCT-Dental Scan | Live 3D-4D Sonography | Colour Doppler | Echo Cardiography | Interventional Radiology | Maxillofacial Radiology | Fetal Medicine  
Digital X-Ray | Digital Mammography | Digital OPG/TMJ | ECG/TMT/PFT/EEG/EMG | Audiometry | Pathology Laboratory | Health Check Up Plans | Pre Employment Check Up

**CT SCAN & CBCT FACILITY NOW AVAILABLE**



## Dr. Dinesh S. Modh

M.D., D.M.R.E. (Radiodiagnosis)

Consultant Radiologist & Sonologist

Ex. Junior Lecturer, B.J. Medical College, Civil Hospital, A'bad.

Panel Doctor of L.I.C.



Patient's name : LAXMIDHAR ANJUM ISMAILBHAI  
Reg. ID : R-2268-23  
Referred by : Dr. MEDIWHEEL

Age/Sex : 36 Years/Female  
Accession : 6288  
Date : 27/05/2023

### USG ABDOMEN

LIVER: - Liver appears normal in size & show normal echotexture. No evidence of diffuse or focal lesion is seen. Intrahepatic biliary radicals appear normal. Portal vein and CBD appear normal. No e/o calculus is seen in bile duct.

GALL BLADDER: - Gall bladder is distended & appears normal. No evidence of calculus or cholecystitis is seen. No evidence of pericholecystic fluid is seen.

SPLEEN: - Spleen appears normal in size & shows normal echotexture. No evidence of diffuse or focal lesion is seen.

PANCREAS: - Pancreas appears normal size and echopattern. No e/o diffuse or focal lesion is seen. Main pancreatic duct appears normal.

KIDNEY: - Both Kidneys appear normal in size & echotexture.

No e/o calculus or hydronephrosis or hydroureter is seen in either side.

Cortico-medullary differentiation is maintained on either side.

Both suprarenal regions appear normal.

RIF & BOWEL LOOPS (By high frequency probe):-Normal.

No evidence of pre & para aortic lymphadenopathy is seen.

No evidence of free fluid is seen in abdomen.

No evidence of dilated or thickened bowel loops is seen.

Urinary bladder: - appears normal. No e/o calculus or mass lesion is seen in bladder.

Uterus appears normal in size and shows 19x17mm intra-mural fibroid in body of uterus posteriorly.

Cervical region appears normal.

Endometrial thickness is 6.4mm.

Both ovaries and adnexal regions appear normal.

No e/o free fluid is seen in pouch of Douglas.

Thanks for reference.

Dr. Dinesh S. Modh  
MD DMRE (Radiodiagnosis)  
G-23825

DR DINESH S. MODH

M.D. DMRE(RADIODIAGNOSIS)

ISO 9001:2015 Certified Diagnostics Center

Vidhi Imaging Center

L-86, Swatantra Senani Nagar, Opp. Indian Oil Petrol Pump, Akhbarnagar Circle, Nava Vadaj, Ahmedabad - 380 013.

Phone : (Radiology) 079-2762 1406 | M. 98799 29406, 98250 09406 | Time (Radiology) : Mon. to Sat. 9 am to 2 pm, 5 to 9 pm, Sunday 9 am to 12 Noon

E-mail : vidhidiagnostics@gmail.com, Website : www.vidhidiagnostics.com

Multislice CT Scan | CBCT-Dental Scan | Live 3D-4D Sonography | Colour Doppler | Echo Cardiography | Interventional Radiology | Maxillofacial Radiology | Fetal Medicine  
Digital X-Ray | Digital Mammography | Digital OPG/TMJ | ECG/TMT/PFT/EEG/EMG | Audiometry | Pathology Laboratory | Health Check Up Plans | Pre Employment Check Up

**CT SCAN & CBCT FACILITY NOW AVAILABLE**

15 - 27 01 2013 0000

Exam: 48470

Examination

27-05-2013-0000 VERA DIAGNOSTICS CENTRE  
ANAL.M

FR 25kg  
CO-6C

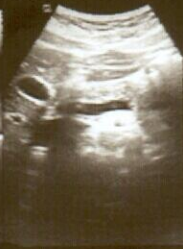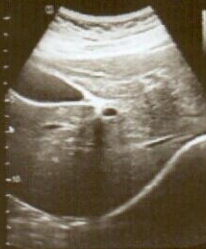15.0cm  
Pan

MR 1.3  
TR 0.3

27.02  
10.21

000-0000-7330700

000-0000-7330700



15 - 27 01 2013 0000

Exam: 48470

Examination

27-05-2013-0000 VERA DIAGNOSTICS CENTRE  
ANAL.M

FR 25kg  
CO-6C

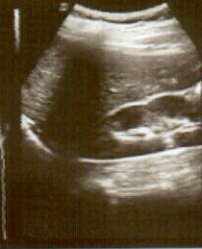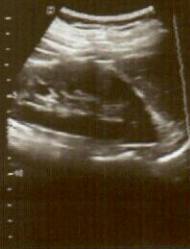15.0cm  
Pan

MR 1.3  
TR 0.3

27.02  
10.21

000-0000-7330700

000-0000-7330700





## Dr. Dinesh S. Modh

M.D., D.M.R.E. (Radiodiagnosis)

Consultant Radiologist & Sonologist

Ex. Junior Lecturer, B.J. Medical College, Civil Hospital, A'bad.

Panel Doctor of L.I.C.



27-05-2023

I don't want to give stool sample for any stool test.

Thanking you,  
Anjum Laxmidhar, (103392 - BOB),  
Namidhar

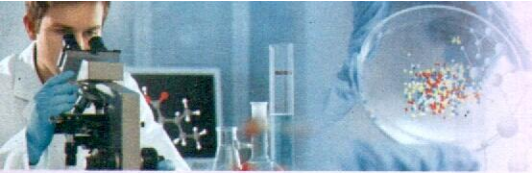**Vidhi Diagnostics**  
L-86, Swatantra-Senani Nagar,  
Opp. Akhbarnagar Bus Terminals,  
Nr. Akhbarnagar Circle,  
New Vadaj, Ahmedabad-13.

ISO 9001:2015 Certified Diagnostics Center

Vidhi Imaging Center, L-86, Swatantra Senani Nagar, Opp. Akhbarnagar Petrol Pump, Nr. Akhbarnagar Circle, Nava-Vadaj, Ahmedabad - 380 013.

Phone : 079-2762 1406, Mobile : 98799 29406, 98250 09406, E-mail : vidhidiagnostics@gmail.com, Website : www.vidhidiagnostics.com

FACILITIES : Live 3D-4D Sonography | Colour Doppler | Echo Cardiography | Interventional Radiology | Fetal Medicine | Digital X-Ray  
Digital Mammography | Digital OPG / TMJ | ECG / TMT / PFT / EEG / EMG | Pathology Laboratory | Health Check Up Plans | Pre Employment Check Up



Pathology Department

**VIDHI**<sup>®</sup>  
**DIAGNOSTICS**

Creating life in Punjab

Patient's name : LAXMIDHAR ANJUM ISMAILBHAI  
Age/Sex : 36 Years/Female  
Referred by : Dr. MEDIWHEEL  
Collection Time : 09:30

Reg. ID : P-1047-23  
Accession : 6271  
Order Dt/time : 27/05/2023 09:30

### Complete Blood Count

Sample Type: EDTA

Test Name	Result	Units	Biological Reference Interval
<b><u>Blood Counts</u></b>			
Haemoglobin :	<b>11.6</b>	Gms%	13.5 - 18.0
Total R.B.C. :	<b>4.28</b>	mill/c.mm	4.7 - 6.0
Total W. B. C. :	5870	/cu mm	4000 - 10500
Platelet Count :	275000	/cu.mm	1,50,000 - 4,50,000
<b><u>Differential Count</u></b>			
Neutrophils :	55	%	40 - 70
Lymphocytes :	40	%	20 - 40
Eosinophils :	03	%	1 - 4
Monocytes :	02	%	2 - 6
Basophils :	00	%	0 - 01
<b><u>Blood Indices</u></b>			
P. C. V :	<b>35.0</b>	%	42 - 52
M. C. V. :	81.8	fl	78 - 100
M.C.H :	27.2	pg	27 - 31
M. C. H. C :	33.2	%	32 - 36
R.D.W :	<b>14.6</b>	%	11.5 - 14.0
<b><u>E.S.R.( Westergren Method )</u></b>			
After one hour :	06	mm/hr	1 - 7

TESTS DONE ON FULLY AUTOMATED HEMATOLOGY ANALYZER.

*Dr. Gayatri M. Mehta*

M. D. (Patho)

Reg. No. G-32215

DR GAYATRI MEHTA  
MD(PATHOLOGY)

DR. ANAND D. PARIKH  
MD(PATHOLOGY)

LAB USE ONLY (Entered by :GM Enter Date/Time:27/05/2023 5:25:00 PM) (Verify by :GM Verify Date/Time:27/05/2023 5:25:00 PM)

ISO 9001:2015 Certified Diagnostics Center

Vidhi Imaging Center | Pathology Department

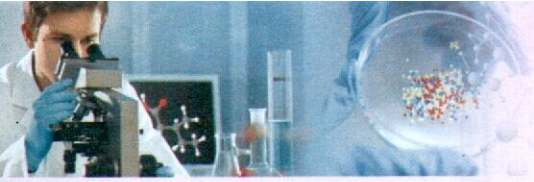L-86, Swatantra Senani Nagar, Opp. Akhbarnagar Petrol Pump, Nr. Akhbarnagar Circle, Nava-Vadaj, Ahmedabad - 380 013.

Ph. (Pathology) : 079-2762 1406, 8849893954 M. 98799 29406, 98250 09406, E-mail : vidhidiagnostics@gmail.com, Web. : www.vidhidiagnostics.com

Time (Pathology) : Mon. to Sat. 8.30 am to 8.00 pm, Sunday 9 am to 12 Noon

*Pathology means science behind medicine*

**CT SCAN & CBCT FACILITY NOW AVAILABLE**



Pathology Department



Patient's name : LAXMIDHAR ANJUM ISMAILBHAI  
Age/Sex : 36 Years/Female  
Referred by : Dr. MEDIWHEEL  
Collection Time : 09:30

Reg. ID : P-1047-23  
Accession : 6271  
Order Dt/time : 27/05/2023 09:30

**Blood Glucose**

Sample Type: Serum

Test Name	Result	Units	Biological Reference Interval
Fasting Blood Glucose : <i>GOD-POD Method.</i>	109.9	mg/dl	70 - 110

**Blood Glucose**

Sample Type: Serum

Test Name	Result	Units	Biological Reference Interval
Post Prandial Blood Glucose After 2hr. : <i>GOD-POD Method.</i>	128.3	mg/dl	80 - 140

*Dr. Gayatri M. Mehta*

M. D. (Patho)

Reg. No. G-32215

DR GAYATRI MEHTA  
MD(PATHOLOGY)

DR. ANAND D. PARIKH  
MD(PATHOLOGY)

LAB USE ONLY (Entered by :GM Enter Date/Time:27/05/2023 5:26:00 PM) (Verify by :GM Verify Date/Time:27/05/2023 5:26:00 PM)

ISO 9001:2015 Certified Diagnostics Center

Vidhi Imaging Center | Pathology Department

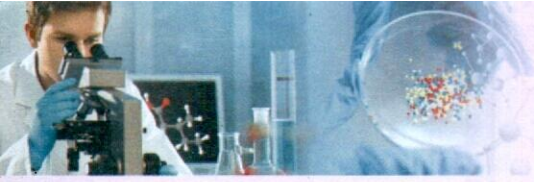L-86, Swatantra Senani Nagar, Opp. Akhbarnagar Petrol Pump, Nr. Akhbarnagar Circle, Nava-Vadaj, Ahmedabad - 380 013.

Ph. (Pathology) : 079-2762 1406, 8849893954 M. 98799 29406, 98250 09406, E-mail : vidhidiagnostics@gmail.com, Web. : www.vidhidiagnostics.com

Time (Pathology) : Mon. to Sat. 8.30 am to 8.00 pm, Sunday 9 am to 12 Noon

*Pathology means science behind medicine*

**CT SCAN & CBCT FACILITY NOW AVAILABLE**



Pathology Department



Patient's name : LAXMIDHAR ANJUM ISMAILBHAI  
Age/Sex : 36 Years/Female  
Referred by : Dr. MEDIWHEEL  
Collection Time : 09:30

Reg. ID : P-1047-23  
Accession : 6271  
Order Dt/time : 27/05/2023 09:30

**Blood Group**

Sample Type: EDTA sample.

Test Name	Result
BG :	" B "
RH :	POSITIVE
Remarks	Done by forward grouping method.

*Dr. Gayatri M. Mehta*  
M. D. (Patho)  
Reg. No. G-32215

DR GAYATRI MEHTA  
MD(PATHOLOGY)

DR. ANAND D. PARIKH  
MD(PATHOLOGY)

LAB USE ONLY (Entered by :GM Enter Date/Time:27/05/2023 5:23:00 PM) (Verify by :GM Verify Date/Time:27/05/2023 5:23:00 PM)

ISO 9001:2015 Certified Diagnostics Center  
Vidhi Imaging Center | Pathology Department

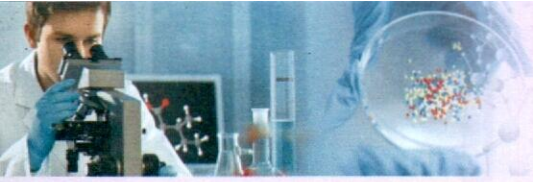L-86, Swatantra Senani Nagar, Opp. Akhbarnagar Petrol Pump, Nr. Akhbarnagar Circle, Nava-Vadaj, Ahmedabad - 380 013.

Ph. (Pathology) : 079-2762 1406, 8849893954 M. 98799 29406, 98250 09406, E-mail : vidhidiagnostics@gmail.com, Web. : www.vidhidiagnostics.com

Time (Pathology) : Mon. to Sat. 8.30 am to 8.00 pm, Sunday 9 am to 12 Noon

*Pathology means science behind medicine*

**CT SCAN & CBCT FACILITY NOW AVAILABLE**



Pathology Department



Patient's name : LAXMIDHAR ANJUM ISMAILBHAI  
Age/Sex : 36 Years/Female  
Referred by : Dr. MEDIWHEEL  
Collection Time : 09:30

Reg. ID : P-1047-23  
Accession : 6271  
Order Dt/time : 27/05/2023 09:30

### Lipid Profile

Sample Type: Serum

Test Name	Result	Units	Biological Reference Interval
<b>S. Cholesterol :</b> Oxidase-esterase method.	159	mg/dl	0 - 200
<b>S. Triglyceride :</b> Enzymatic Colorimetry method	62.8	mg/dL	0 - 200
<b>S. HDL - Cholesterol :</b> Serum by Enzymatic method.	56.9	mg/dL	35 - 65
<b>S. LDL - Cholesterol :</b> Serum by Enzymatic method	89.54	mg/dL	0 - 130
<b>S. VLDL - Cholesterol :</b>	12.56	mg/dL	0 - 30
<b>S. Chole/HDL.Ratio :</b>	2.79		1 - 6
<b>S. LDL / HDL Cholesterol Ratio :</b>	1.57		0 - 3.5

*Dr. Gayatri M. Mehta*  
M. D. (Patho)

DR. GAYATRI MEHTA 215  
MD(PATHOLOGY)

DR. ANAND D. PARIKH  
MD(PATHOLOGY)

LAB USE ONLY (Entered by :GM Enter Date/Time:27/05/2023 5:26:00 PM) (Verify by :GM Verify Date/Time:27/05/2023 5:26:00 PM)

ISO 9001:2015 Certified Diagnostics Center  
Vidhi Imaging Center | Pathology Department

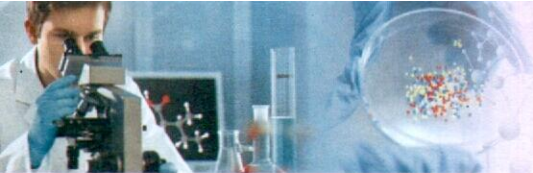L-86, Swatantra Senani Nagar, Opp. Akharnagar Petrol Pump, Nr. Akharnagar Circle, Nava-Vadaj, Ahmedabad - 380 013.

Ph. (Pathology) : 079-2762 1406, 8849893954 M. 98799 29406, 98250 09406, E-mail : vidhidiagnostics@gmail.com, Web. : www.vidhidiagnostics.com

Time (Pathology) : Mon. to Sat. 8.30 am to 8.00 pm, Sunday 9 am to 12 Noon

*Pathology means science behind medicine*

**CT SCAN & CBCT FACILITY NOW AVAILABLE**



Pathology Department



Patient's name : LAXMIDHAR ANJUM ISMAILBHAI  
Age/Sex : 36 Years/Female  
Referred by : Dr. MEDIWHEEL  
Collection Time : 09:30

Reg. ID : P-1047-23  
Accession : 6271  
Order Dt/time : 27/05/2023 09:30

### HbA1C

Sample Type: Serum

Test Name	Result	Units	Biological Reference Interval
HbA1C :	5.4	%	Non-diabetic: 4.2-6.2 Pre-diabetic : 6.3-7.2 Diabetic : 7.3-8.2
Mean Blood Glucose of Last 03 months.	108	mg/dl	

#### Comment

\*As per the new 2009 update of American Diabetes Association regarding HbA1C & Mean Blood Glucose relationship.

#### NOTE:

This test is used to monitor diabetic patients compliance with the therapeutic regimen and logo It's level is proportional to both the average blood glucose concentration and the life span of the red blood cells (RBC) in circulation. HbA1c values are free of day to day glucose fluctuations and are unaffected by exercise or recent food intake.

*Dr. Gayatri M. Mehta*

M. D. (Patho)

Reg. No. G-32215

DR GAYATRI MEHTA  
MD(PATHOLOGY)

DR. ANAND D. PARIKH  
MD(PATHOLOGY)

LAB USE ONLY (Entered by :GM Enter Date/Time:27/05/2023 5:26:00 PM) (Verify by :GM Verify Date/Time:27/05/2023 5:26:00 PM)

ISO 9001:2015 Certified Diagnostics Center

Vidhi Imaging Center | Pathology Department

L-86, Swatantra Senani Nagar, Opp. Akhbarnagar Petrol Pump, Nr. Akhbarnagar Circle, Nava-Vadaj, Ahmedabad - 380 013.

Ph. (Pathology) : 079-2762 1406, 8849893954 M. 98799 29406, 98250 09406, E-mail : vidhidiagnostics@gmail.com, Web. : www.vidhidiagnostics.com

Time (Pathology) : Mon. to Sat. 8.30 am to 8.00 pm, Sunday 9 am to 12 Noon

*Pathology means science behind medicine*

**CT SCAN & CBCT FACILITY NOW AVAILABLE**



Pathology Department



Patient's name : LAXMIDHAR ANJUM ISMAILBHAI  
Age/Sex : 36 Years/Female  
Referred by : Dr. MEDIWHEEL  
Collection Time : 09:30

Reg. ID : P-1047-23  
Accession : 6271  
Order Dt/time : 27/05/2023 09:30

**BIOCHEMISTRY**

Sample type :Serum

Test Name	Result	Units	Biological Reference Interval
Urea, (Serum by GLDH method) :	13.6	mg/dl	10 - 50
S.Uric acid, (Serum by Uricase method) :	3.8	mg/dl	3.4 - 7.0
Bun :	6.4	mg/dl	6-20
Creatinine, (Serum by Enzymatic reaction) :	0.71	mg/dl	0.5-1.2
BUN/CREATRATIO	9.01		13 - 20
S.G.P.T (ALT) : (Serum by IFCC method)	12.2	U/L	0 - 40
S.G.O.T (AST) : (Serum by IFCC method)	14.5	U/L	0 - 37
ALK.PHOSPHATASE : (Serum by PNP method)	51	U/L	40-129
G.G.T :	8.4	U/L	8 - 78
<b><u>BILIRUBIN</u></b>			
Total :	0.37	mg/dl	Up to 1.2
Direct :	0.20	mg/dl	0-0.7
Indirect :	0.17	mg/dl	0 - 0.5
<b><u>SERUM PROTEINS</u></b>			
Total Protein (Serum by Biuret method) :	6.86	gms/dl	6.4 - 8.5
Albumin (Serum by BCG method) :	4.24	gms/dl	3.97-4.94
Globulins :	2.62	gms/dl	2.3 - 3.5
A/G Ratio :	1.618		0.9 - 2.9

*Dr. Gayatri M. Mehta*

M. D. (Patho)

Reg. No. G-32215

DR GAYATRI MEHTA  
MD(PATHOLOGY)

DR. ANAND D. PARIKH  
MD(PATHOLOGY)

LAB USE ONLY (Entered by :GM Enter Date/Time:27/05/2023 5:31:00 PM) (Verify by :GM Verify Date/Time:27/05/2023 5:32:00 PM)

ISO 9001:2015 Certified Diagnostics Center

Vidhi Imaging Center | Pathology Department

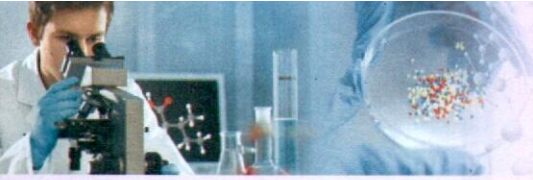L-86, Swatantra Senani Nagar, Opp. Akhbarnagar Petrol Pump, Nr. Akhbarnagar Circle, Nava-Vadaj, Ahmedabad - 380 013.

Ph. (Pathology) : 079-2762 1406, 8849893954 M. 98799 29406, 98250 09406, E-mail : vidhidiagnostics@gmail.com, Web. : www.vidhidiagnostics.com

Time (Pathology) : Mon. to Sat. 8.30 am to 8.00 pm, Sunday 9 am to 12 Noon

*Pathology means science behind medicine*

**CT SCAN & CBCT FACILITY NOW AVAILABLE**



Pathology Department



Patient's name : LAXMIDHAR ANJUM ISMAILBHAI  
Age/Sex : 36 Years/Female  
Referred by : Dr. MEDIWHEEL  
Collection Time : 09:30

Reg. ID : P-1047-23  
Accession : 6271  
Order Dt/time : 27/05/2023 09:30

### Thyroid Function Test

Sample Type: Serum

Test Name	Result	Units	Biological Reference Interval
TOTAL T3 :	1.30	ng/ml	0.84 - 2.0
TOTAL T4 :	12.6	ug/dl	5.1 - 14.0
TSH(Ultra sensitive) :	2.343	mIU/L	0.27 - 4.2

*Dr. Gayatri M. Mehta*  
M. D. (Patho)

DR GAYATRI MEHTA  
MD(PATHOLOGY)

DR. ANAND D. PARIKH  
MD(PATHOLOGY)

LAB USE ONLY (Entered by :GM Enter Date/Time:27/05/2023 5:27:00 PM) (Verify by :GM Verify Date/Time:27/05/2023 5:28:00 PM)

ISO 9001:2015 Certified Diagnostics Center  
Vidhi Imaging Center | Pathology Department

L-86, Swatantra Senani Nagar, Opp. Akhbarnagar Petrol Pump, Nr. Akhbarnagar Circle, Nava-Vadaj, Ahmedabad - 380 013.

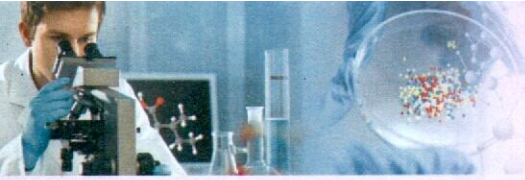Ph. (Pathology) : 079-2762 1406, 8849893954 M. 98799 29406, 98250 09406, E-mail : vidhidiagnostics@gmail.com, Web. : www.vidhidiagnostics.com

Time (Pathology) : Mon. to Sat. 8.30 am to 8.00 pm, Sunday 9 am to 12 Noon

*Pathology means science behind medicine*

**CT SCAN & CBCT FACILITY NOW AVAILABLE**





# Pathology Department



Patient's name : LAXMIDHAR ANJUM ISMAILBHAJ  
 Age/Sex : 36 Years/Female  
 Referred by : Dr. MEDIWHEEL  
 Collection Time : 09:30

Reg. ID : P-1047-23  
 Accession : 6271  
 Order Dt/time : 27/05/2023 09:30

## Urine Analysis

Sample Type: Urine

Test Name	Result	Units	Biological Reference Interval
<b><u>Physical Examination</u></b>			
Quantity :	30	ml	0 - 500 ml
Colour :	Pale Yellow		Pale Yellow
Transparency :	Slight Turbid.		Clear
Reaction :	Acidic		4.6 - 8.0
Specific Gravity :	1.025		1.016 - 1.022
Sediment :	Present		
<b><u>Chemical Examination</u></b>			
Albumin :	Present (Faint Trace)		Absent
Sugar :	NIL		Absent
Acetone :	Absent		Absent
Bile Salts :	Absent		Absent
Bile Pigments :	Absent		Absent
Urobilogen :	Absent		Absent
Nitrites :	Absent		Absent
<b><u>Microscopic Examination</u></b>			
Red blood Cells :	1-2	/h.p.f	Absent
Pus Cells :	2-3	/h.p.f	Absent
Epithelial Cells :	1-2	/h.p.f	< 10.0
Amorphous :	Absent	/h.p.f	Absent
Bacteria :	Absent	/h.p.f	Absent
Crystals :	Absent	/h.p.f	Absent
Casts :	Absent	/h.p.f	Absent
Fungus :	Not seen	/h.p.f	Absent

*Dr. Gayatri M. Mehta*

M. D. (Patho)

Reg. No. G-32215

DR GAYATRI MEHTA  
MD(PATHOLOGY)

DR. ANAND D. PARIKH  
MD(PATHOLOGY)

LAB USE ONLY (Entered by :GM Enter Date/Time:27/05/2023 5:38:00 PM) Verify by :GM Verify Date/Time:27/05/2023 5:33:00 PM)

ISO 9001:2015 Certified Diagnostic Center  
Vidhi Imaging Center | Pathology Department

L-86, Swatantra Senani Nagar, Opp. Akhbarnagar Petrol Pump, Nr. Akhbarnagar Circle, Nava-Vadaj, Ahmedabad - 380 013.

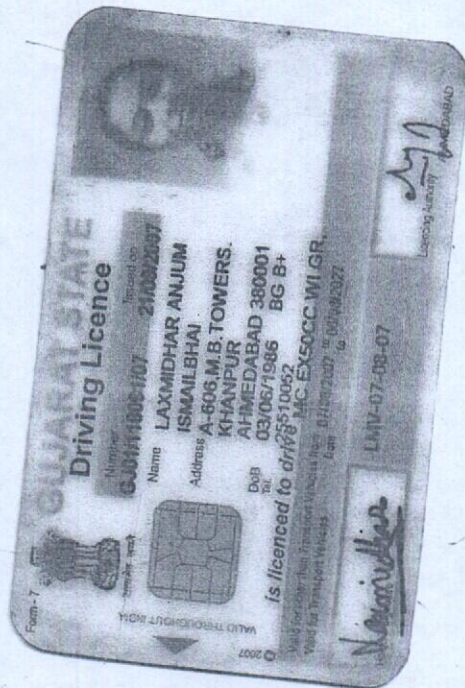Ph. (Pathology) : 079-2762 1406, 8849893954 M. 98799 29406, 98250 09406, E-mail : vidhidiagnostics@gmail.com, Web. : www.vidhidiagnostics.com

Time (Pathology) : Mon. to Sat. 8.30 am to 8.00 pm, Sunday 9 am to 12 Noon

*Pathology means science behind medicine*

**CT SCAN & CBCT FACILITY NOW AVAILABLE**


36/4/Remelle



x  
Laxmidhar

Dr. Vidhi D. Modh  
MBBS  
Reg. No. G-74540

**Vidhi Diagnostics**  
L-86, Swatantra-Senani Nagar,  
Opp. Akharnagar Bus Terminals,  
Nr. Akharnagar Circle,  
New Wadaj, Ahmedabad-13.



Saturday, 27 May 2023 9:27 am

Chandlodiya Road

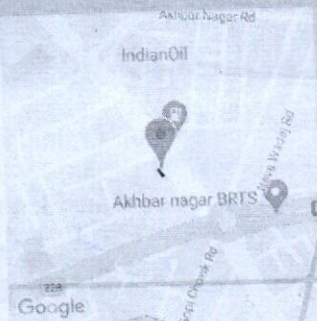Nirnay Nagar

Ahmedabad

Gujarat

Altitude: 64.9ft

Index number: 259



**Dr. Vidhi D. Modh**  
MBBS  
Reg. No. 3-74540

**Vidhi Diagnostics**  
L-86, Swatantra-Senani Nagar,  
Opp. Akhbar Nagar Bus Terminals,  
Nr. Akhbar Nagar Circle,  
New Vadaj, Ahmedabad-13.