

Name : Mrs. Anita Agarwal

Age: 36 Y

UHID:CJPN.0000088800

Address : blr

Sex: F


 Plan : ARCOFEMI MEDIWHEEL FEMALE AHC CREDIT PAN
 INDIA OP AGREEMENT

OP Number:CJPNOPV179428

Bill No :CJPN-OCR-66761

Date : 23.10.2023 08:52

Sno	Service Type	Service Name	Department
1		ARCOFEMI MEDIWHEEL - FULL BODY HEALTH ANNUAL PLUS CHECK - FEMALE - 2D ECHO - PAN INDIA - FY2324	
1		URINE GLUCOSE (FASTING)	
2		GAMMA GLUTAMYL TRANSFERASE (GGT)	
3		HbA1c GLYCATED HEMOGLOBIN	
4		TESTING BY TMT	
5		LIVER FUNCTION TEST (LFT)	
6		X-RAY CHEST PA	
7		GLUCOSE, FASTING	
8		HEMOGRAM + PERIPHERAL SMEAR	
9		ENT CONSULTATION	
10		FITNESS BY GENERAL PHYSICIAN	
11		GYNAECOLOGY CONSULTATION	Refused
12		DIET CONSULTATION	
13		COMPLETE URINE EXAMINATION	
14		URINE GLUCOSE (POST PRANDIAL)	11.45 AM
15		PERIPHERAL SMEAR	
16		ECG	
17		BLOOD GROUP ABO AND RH FACTOR	
18		LIPID PROFILE	
19		BODY MASS INDEX (BMI)	
20		LBC PAP TEST - PAPSURE	Refused
21		OPHTHAL BY GENERAL PHYSICIAN	R-3
22		RENAL PROFILE/RENAL FUNCTION TEST (RFT/KFT)	
23		ULTRASOUND - WHOLE ABDOMEN	
24		THYROID PROFILE (TOTAL T3, TOTAL T4, TSH)	
25		DENTAL CONSULTATION	R-22
26		GLUCOSE, POST PRANDIAL (PP), 2 HOURS (POST MEAL)	11.45 AM

Weight = 60.2kg
 Height = 161 Cms
 Waist = 78 Cms
 Hip = 88 cm
 BP = 107/75 mm/Hg
 PR = 82/ml-



CERTIFICATE OF MEDICAL FITNESS

This is to certify that I have conducted the clinical examination

of ANITA Agarwal 25m/1m
on 23/10/23

After reviewing the medical history and on clinical examination it has been found that
she is

• Medically Fit	<input checked="" type="checkbox"/>	Tick
• Fit with restrictions/recommendations	<input type="checkbox"/>	
Though following restrictions have been revealed, in my opinion, these are not impediments to the job.		
1.....		
2.....		
3.....		
However the employee should follow the advice/medication that has been communicated to him/her.		
Review after		
• Currently Unfit	<input type="checkbox"/>	
Review after		recommended
• Unfit	<input type="checkbox"/>	

Dr. M.P. Shiva Kumar
 MBBS., MD (GEN. MED.), FRSH (LONDON)
 Consultant - Physician & Diabetologist
 Mob : 9739563913, 9902552039
 KMC - 24348
 Dr. 
 Medical Officer
 The Apollo Clinic, (Location)

This certificate is not meant for medico-legal purposes

PATIENT CASE SHEET



Name: Arkita Agarwal Age: 36 Gender: F

Address: _____

UHID / Emp ID: CSPN.0000088800

Ref. by Doctor
CHC

Treating Doctor
Dr. Sijo

Past Dental History: NAD

Past Medical History: Thyroid.

Chief Complaint(s): Regular dental checkup

Investigation: RVG OPG CBCT

Examination:

Extra Oral Examination :

Intra Oral Examination :

Oral Mucosa:

Case

Tooth: DMF

18	17	16	15	14	13	12	11	21	22	23	24	25	26	27	28
48	47	46	45	44	43	42	41	31	32	33	34	35	36	37	38

Other Findings:

Periodontal Examination:

																	PD
																	BOP
																	P&C
18	17	16	15	14	13	12	11	21	22	23	24	25	26	27	28		
48	47	46	45	44	43	42	41	31	32	33	34	35	36	37	38		
																	P&C
																	BOP
																	PD

Treatment Advised:

→ Advised for oral prophylaxis
 → Advised for OPG

Medication (If Any):

(Handwritten scribble)

(Handwritten signature)

Name - Ankit Agarwal
Age - 38 y/f

Date - 23/10/23

Height :	Weight :	BMI :	Waist Circum :
Temp :	Pulse :	Resp :	B.P. :

General Examination / Allergies
History

Clinical Diagnosis & Management Plan

CO - Routine Eye
checkup

UUVU { 6/6/2 N6
6/12 N6

H/O PUP - No

± glass VU { 6/6 N1
6/6 N6

H/O Eye str - contact
str is done in RE
10 years back

colours vision is normal in BE

Rx RE = -0.50 dsph
LE = -0.50 dsph

Follow up date:

After 6 months.

Doctor Signature

ID: GJPN88800

Visit: MEDIWHEEL

23-Oct-2023

11:05:07

36years

161cm

Asian

60kg

Female

BRUCH

Max HR: 180bpm 97% of max predicted 184bpm

Max BP: 130/70

Total Exercise time: 9:02

Maximum workload: 10.1METS

25.0 mm/s
10.0 mm/mV
100hz

Referred by: SELF
Test Ind: CAD SCREENING

TMT IS NEGATIVE FOR INDUCIBLE ISCHEMIA

Reason for Termination:
Comments: GOOD EFFORT AND TOLERANCE
NORMAL HR/BP RESPONSE
NO ANGINA AND ARRHYTHMIA NOTED
NO SIGNIFICANT ST-T CHANGES SEEN

Phase Name	Stage Name	Time in Stage	Speed (mph)	Grade (%)	Workload (METS)	HR (bpm)	BP (mmHg)	RPP (x100)
PRETEST	SUPINE	1:09	0.8	0.0	1.3	103	110/70	134
EXERCISE	STAGE 1	3:00	1.7	0.0	4.6	122	120/70	175
	STAGE 2	3:00	2.5	2.0	7.0	146	130/70	229
	STAGE 3	3:00	3.4	4.0	10.1	176	130/70	229
	STAGE 4	0:02	3.4	4.0	10.1	176	130/70	229
RECOVERY	Post	3:06	***	***	1.0	109	100/70	109

Positive

Handwritten signature
23/10/23

Technician: JYOTHI

Unconfirmed

MAC55 010A

ID: CJPN88800

Visit: MEDIWHEEL

23-Oct-2023

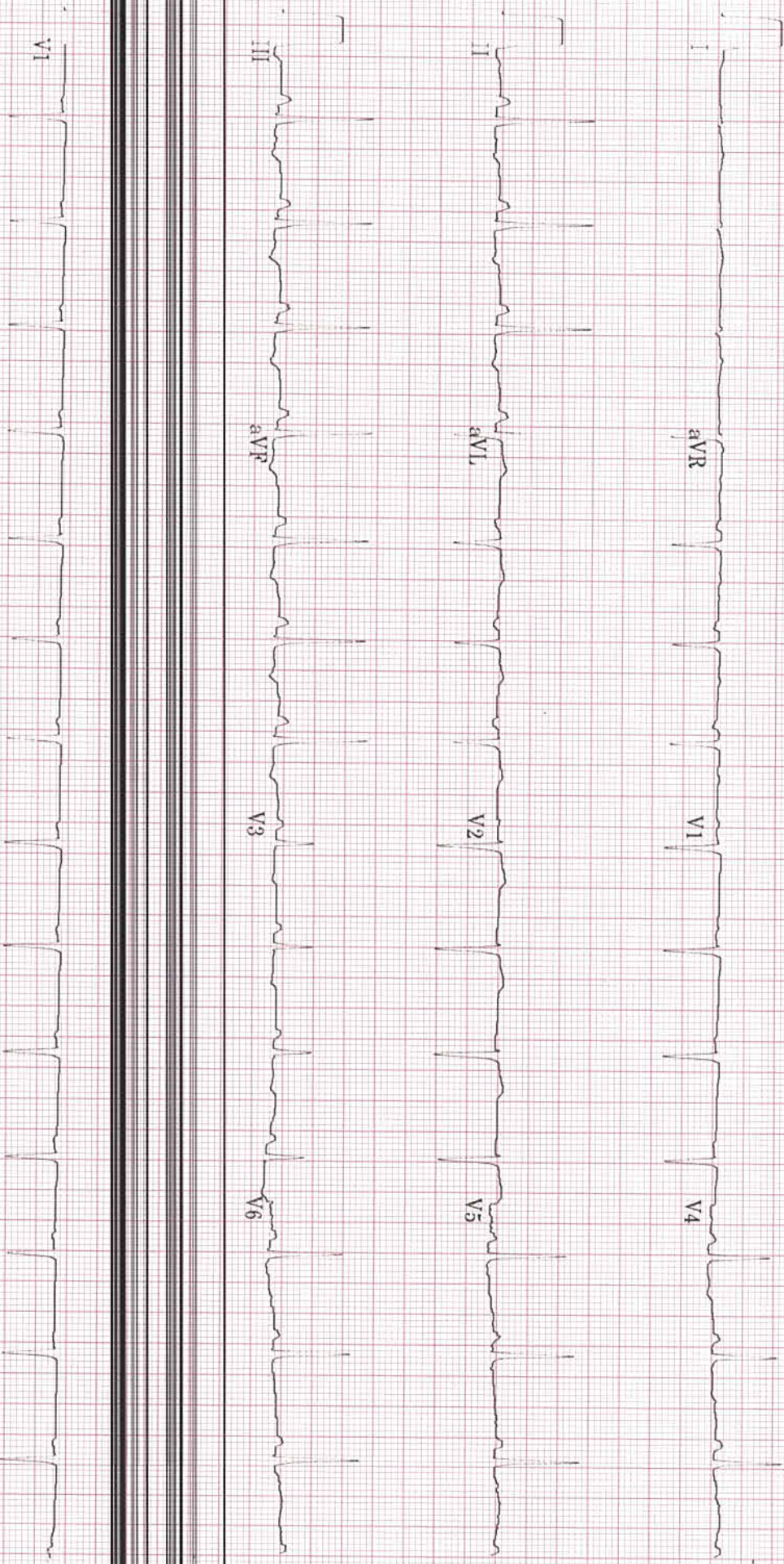
11:05:43

90bpm

PRETEST
SUPINE

0:38

BRUCE
***mph
***%



40 Hz 25.0 mm/s 10.0 mm/mV

A-H-S-50Hz HR 46

4 by 2.5s + 1 rhythm Id

MAC55 010A

ARROW CE

II

36years Female 161cm Asian 60kg

Vent. rate 92 bpm
PR interval 130 ms
QRS duration 76 ms
QT/QTc 310/383 ms
P-R-T axes 85 87 -50

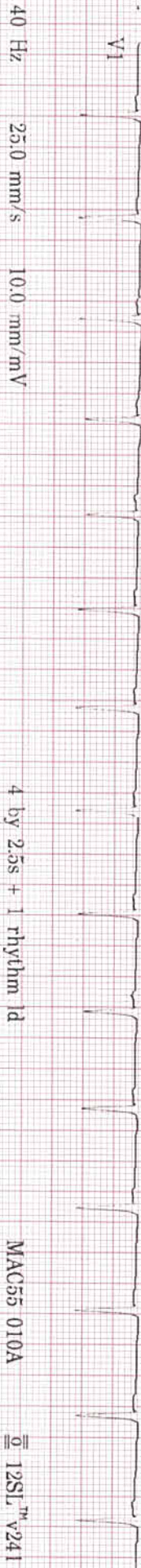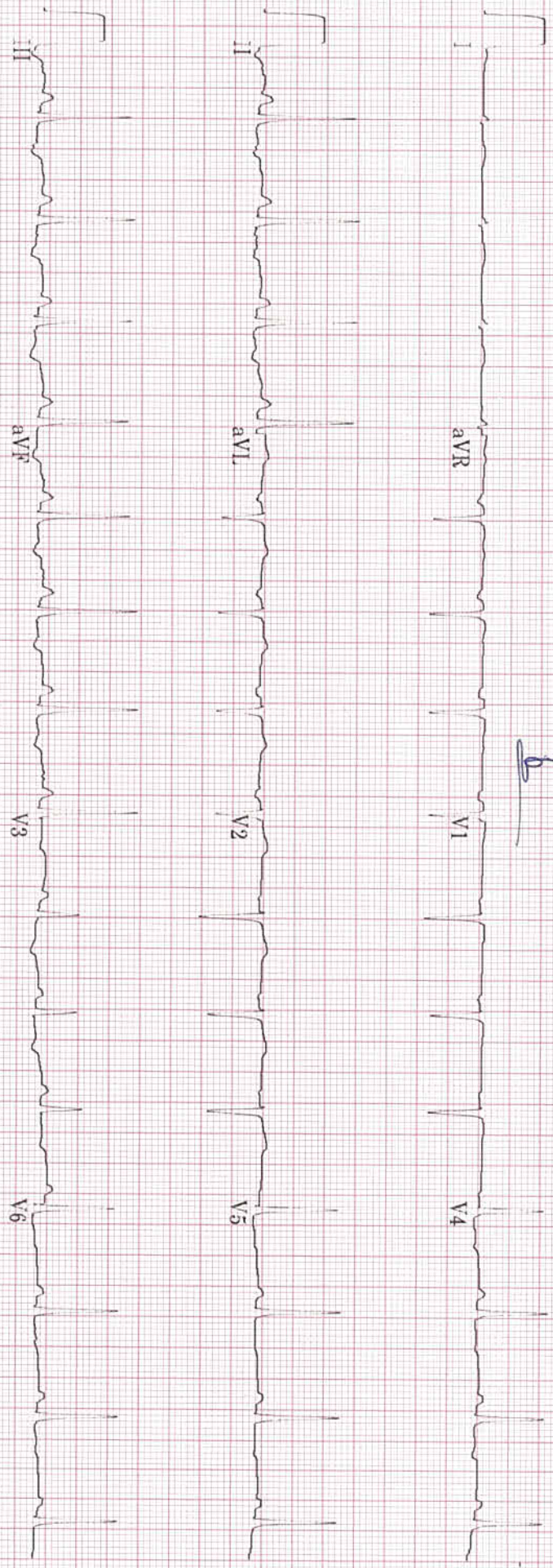
Technician: JYOTHI
Test ind: CAD SCREENING

Normal sinus rhythm
T wave abnormality, consider inferior ischemia
Abnormal ECG

Visit: MEDIWHEEL
Referred by: SELF

Unconfirmed

Ischemia



ARROW CC

4 by 2.5s + 1 rhythm 1d

MAC55 010A

12SL™ V241

ID: GJPN88800
Visit: MEDIWHEEL

23-Oct-2023
11:09:03

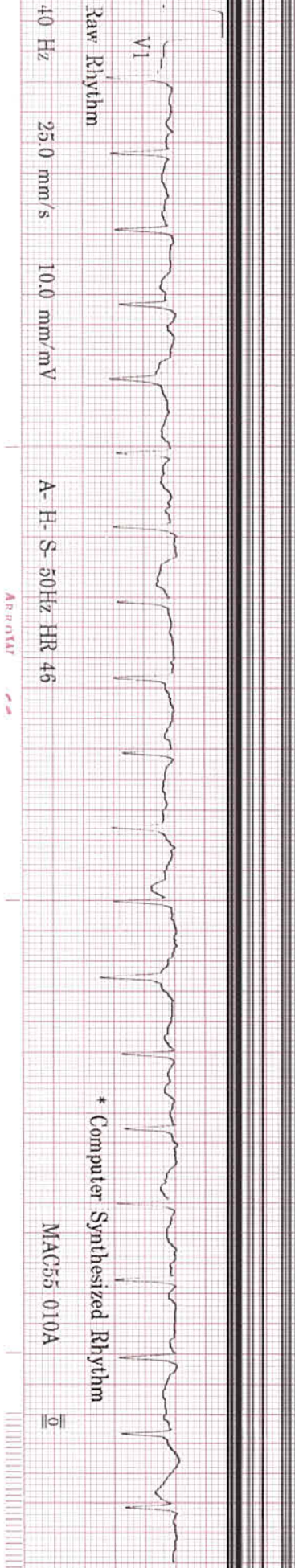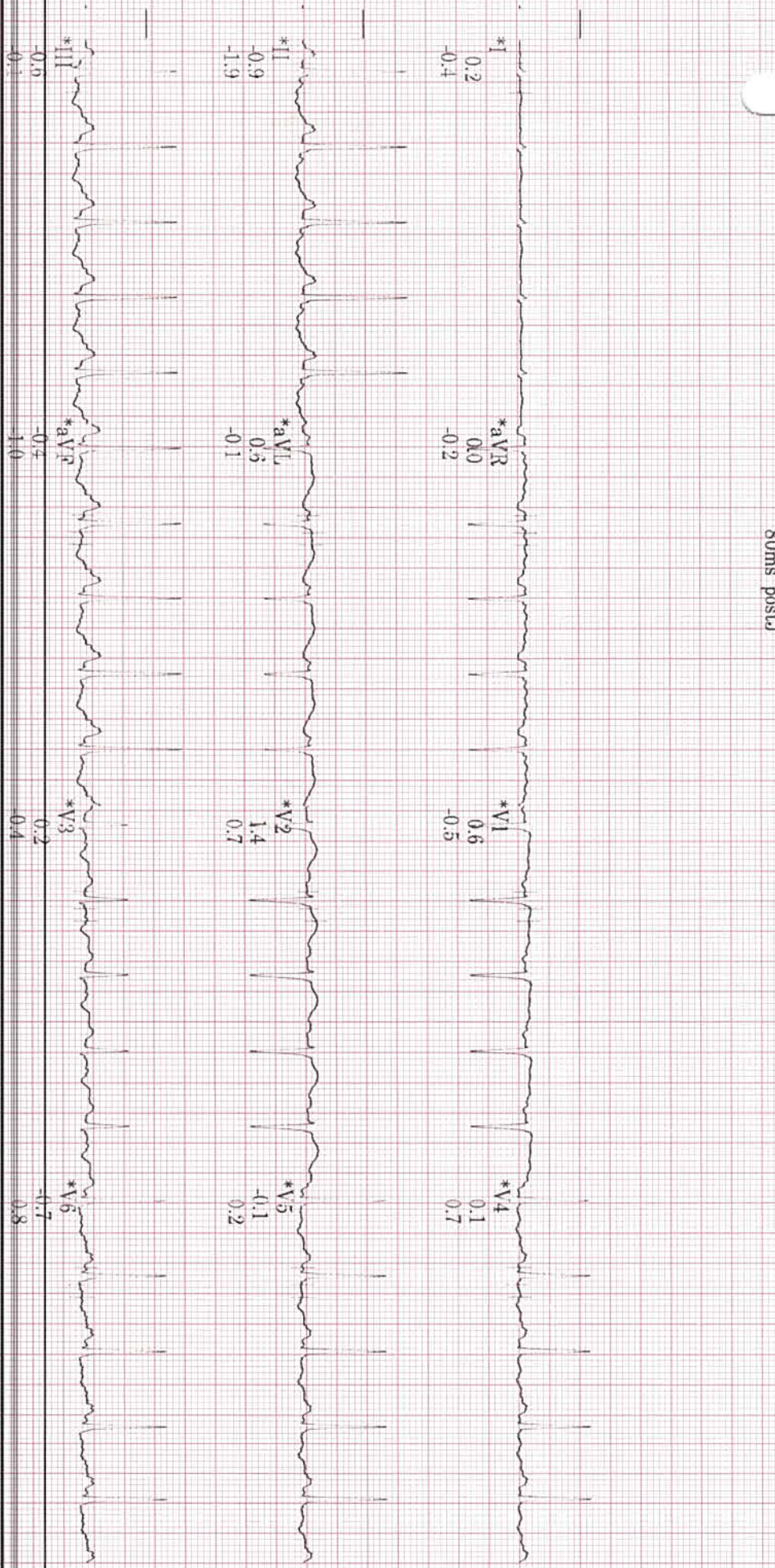
121bpm
BP: 110/70

ST @ 10mm/mV
80ms postJ

EXERCISE
STAGE 1
2:50

BRUCE
1.7mph
10.0%

Lead
ST(mm)
Slope(mV/s)



ID: GJPN88800
Visit: MEDIWHEEL

23-Oct-2023
11:12:05

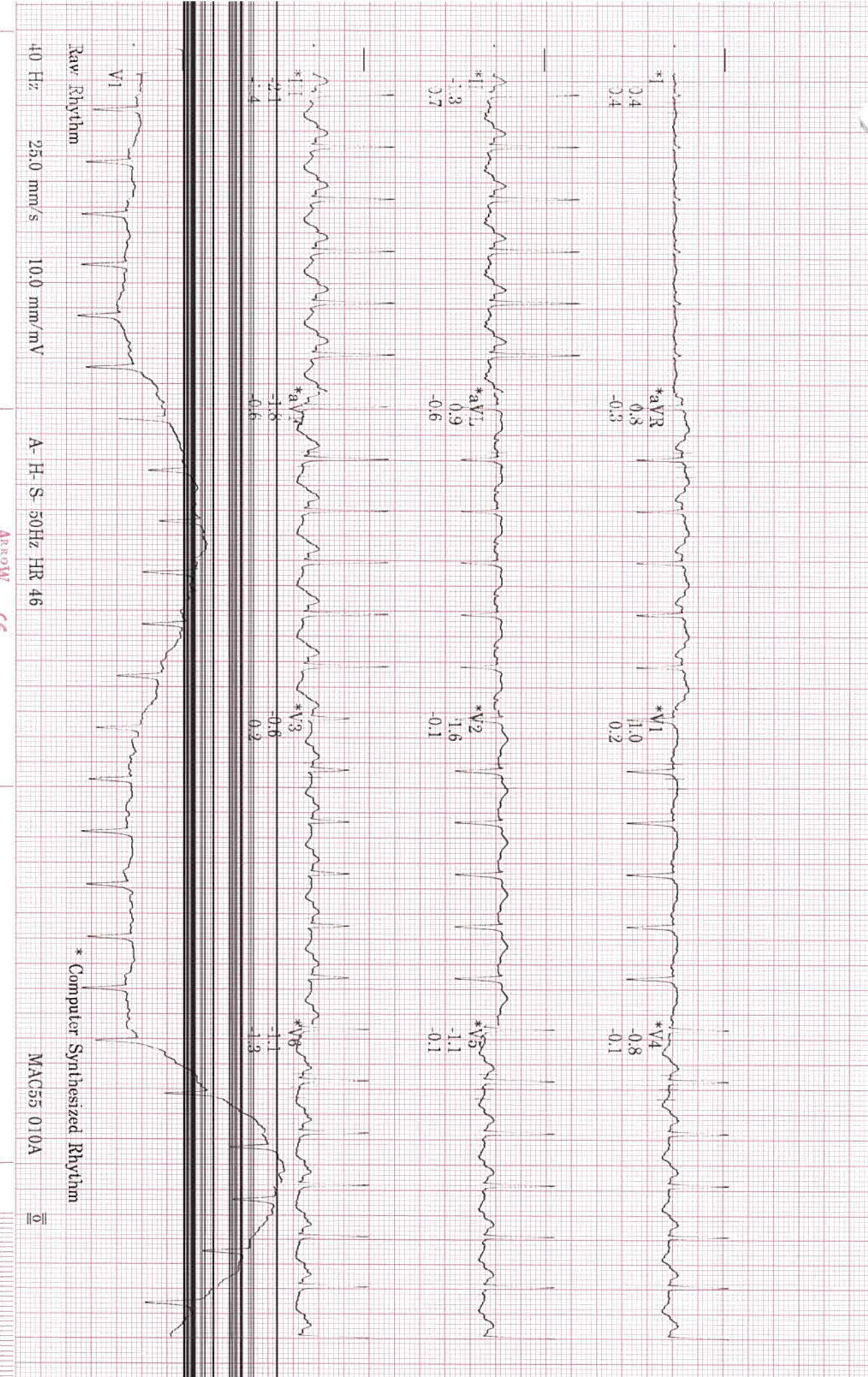
146bpm
BP: 120/70

ST @ 10mm/mV
80ms postJ

EXERCISE
STAGE 2
5:51

BRUCE
2.5mph
12.0%

Lead
ST(mm)
Slope(mV/s)



Arrow

ID: GJPN88800
Vist: MEDIWHEEL

23-Oct-2023
11:15:05

178bpm

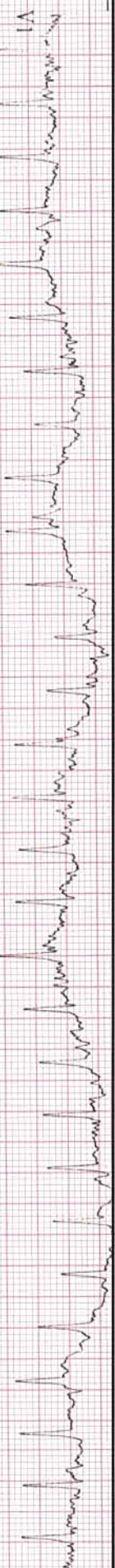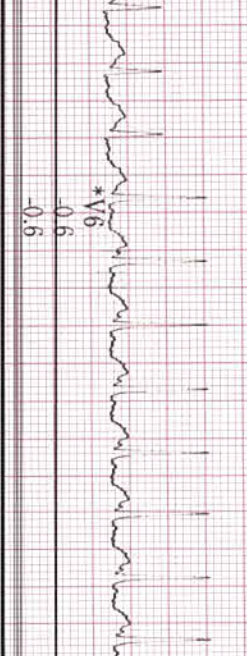
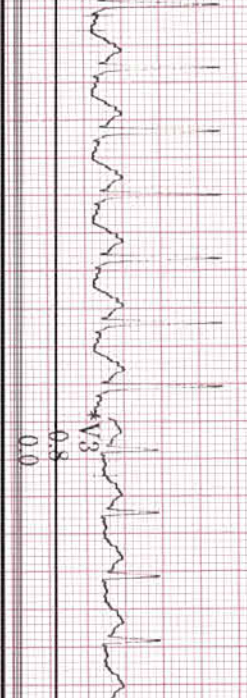
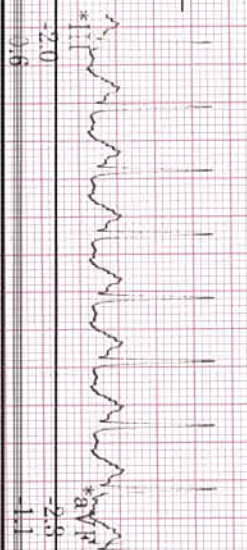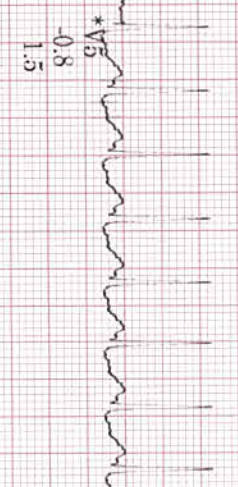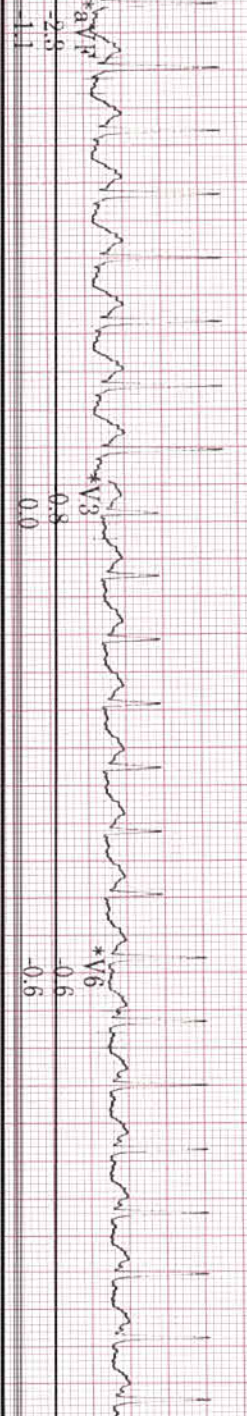
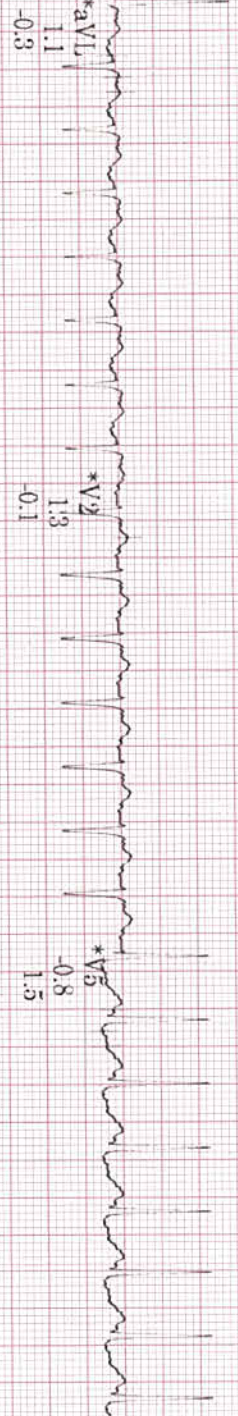
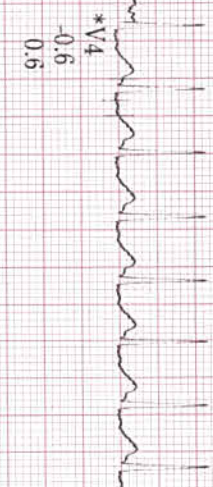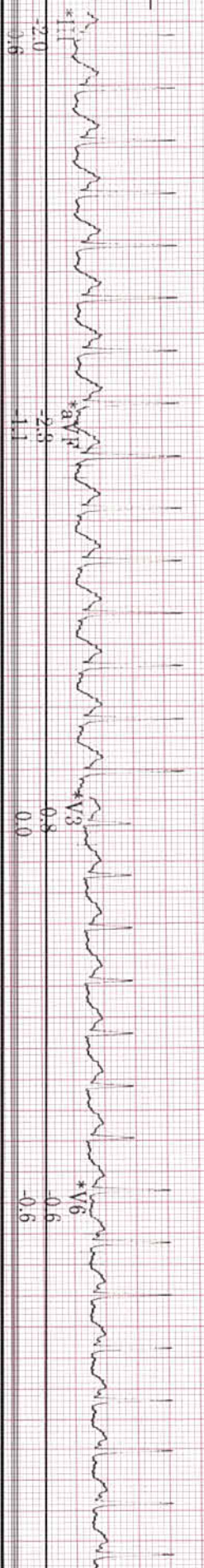
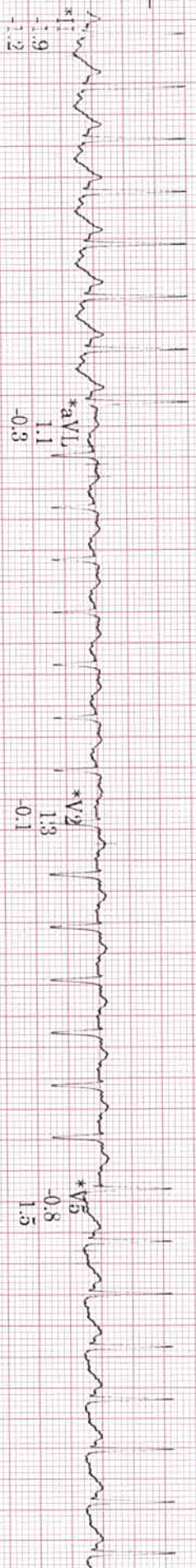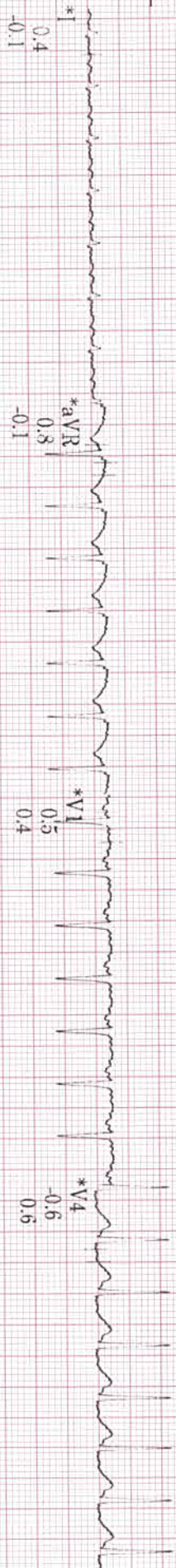
BP: 130/70

EXERCISE
STAGE 3
8:50

BRUCE
3.4mph
14.0%

ST @ 10mm/mV
80ms postJ

Lead
ST(mm)
Slope(mV/s)



* Computer Synthesized Rhythm

40 Hz 25.0 mm/s 10.0 mm/mV A-H-S-50Hz HR 46

MAC55 010A

Arrow

ID: GJPN88860
Visit: MEDIWHEEL

23-Oct-2023
11:15:17

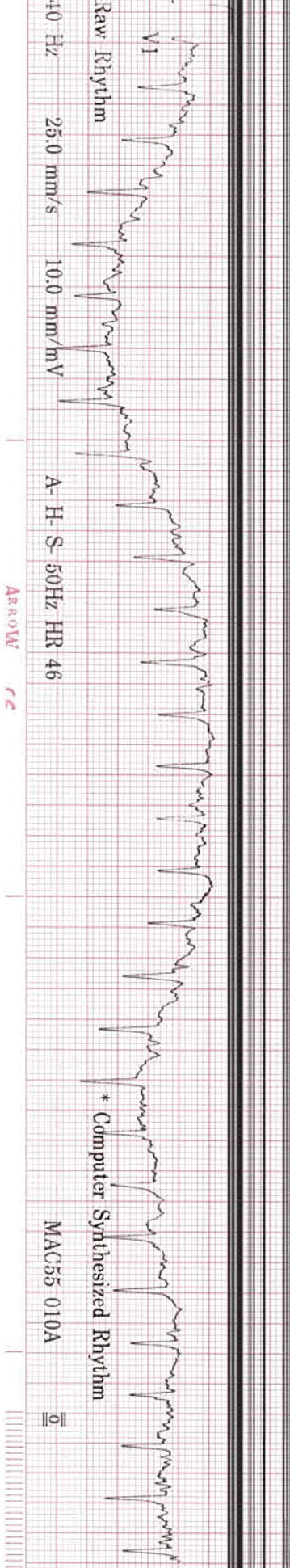
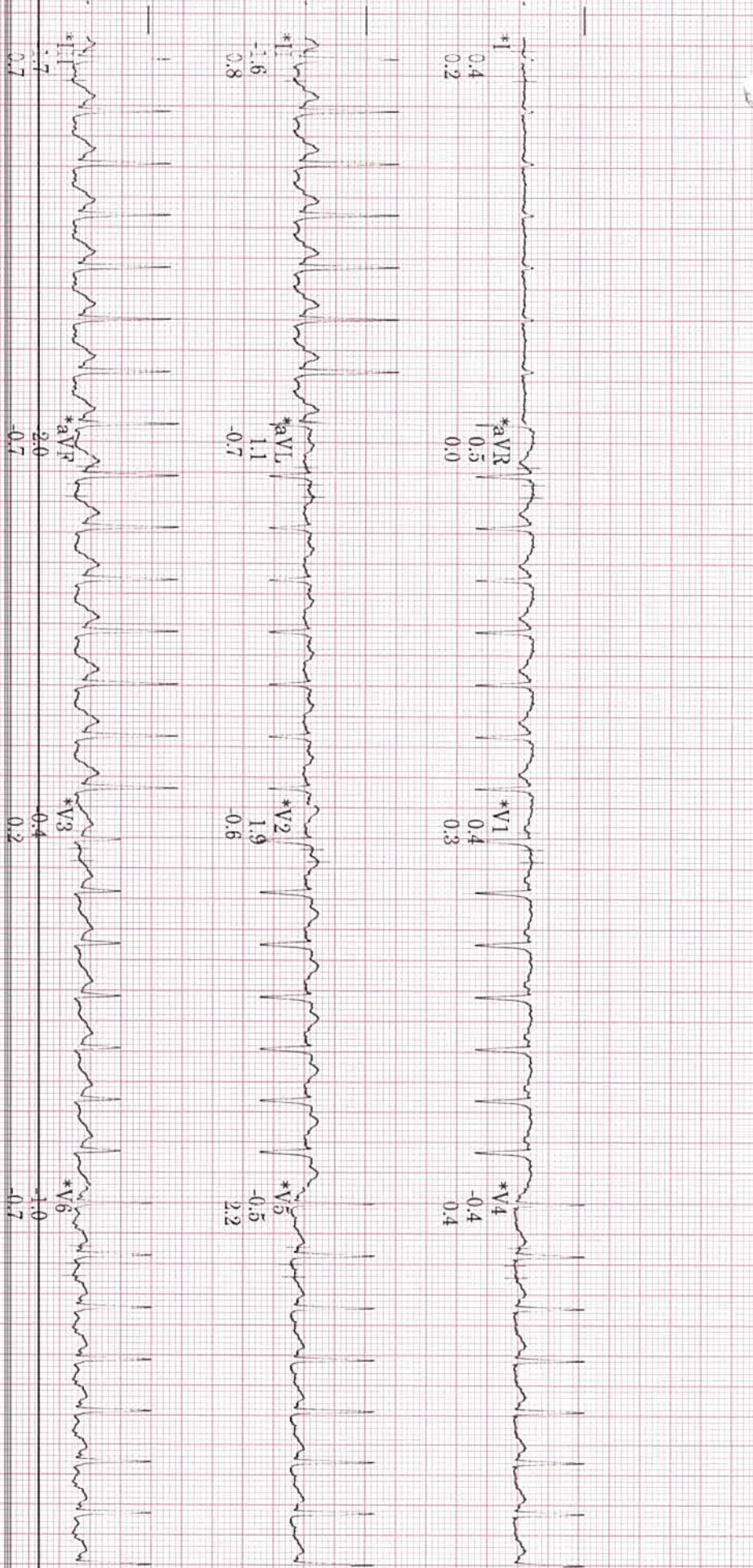
176bpm
BP: 130/70

ST @ 10mm/mV
80ms postJ

RECOVERY
Post
0:00

BRUCE
4.2mph
16.0%

Lead
ST(mm)
Slope(mV/s)



Arrow

ID: CJPN88800

Visit: MEDIWHEEL

23-Oct-2023

11:16:17

136bpm

BP: 130/70

ST @ 10mm/mV
80ms postJ

RECOVERY

Post

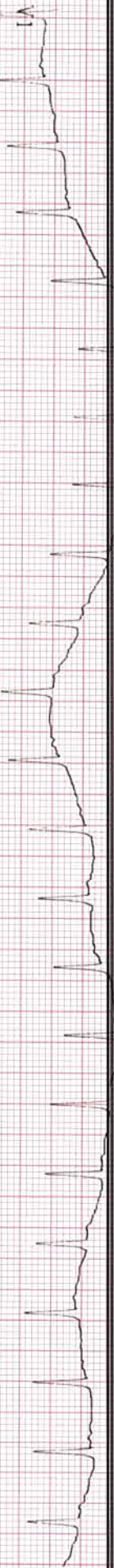
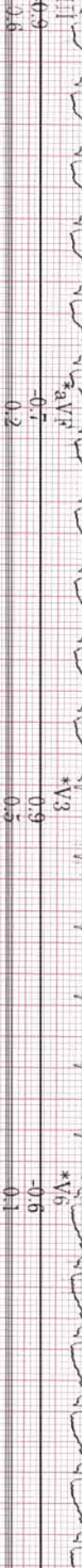
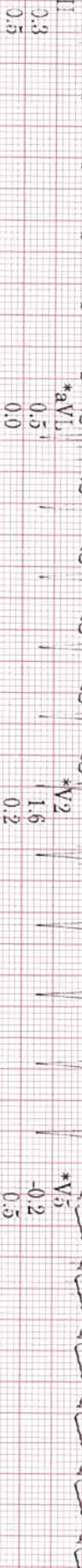
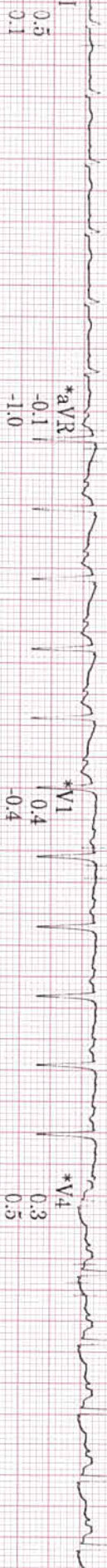
1:00

BRUCE

***mph

***%

Lead
ST(mm)
Slope(mV/s)



Raw Rhythm

40 Hz 25.0 mm/s 10.0 mm/mV

A-H-S-50Hz HR 46

* Computer Synthesized Rhythm

MAC55 010A

II

ID: GJPN88800
Visit: MEDIWHEEL

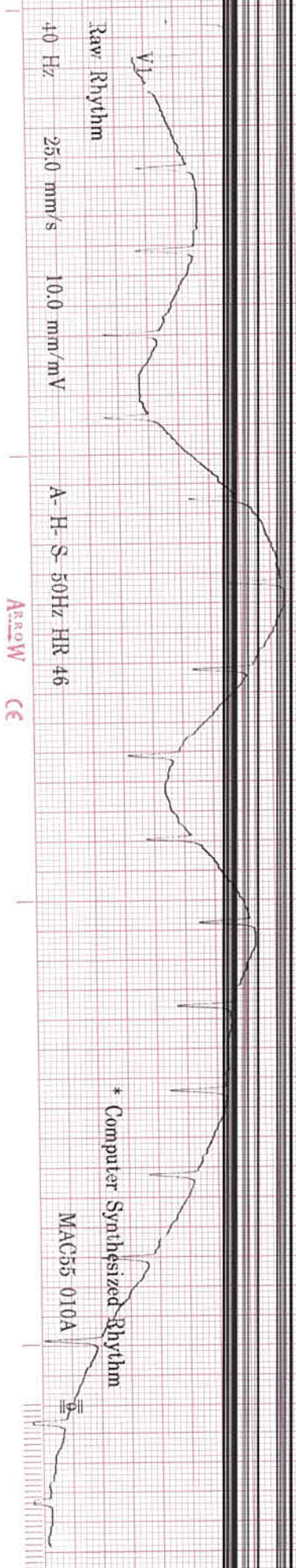
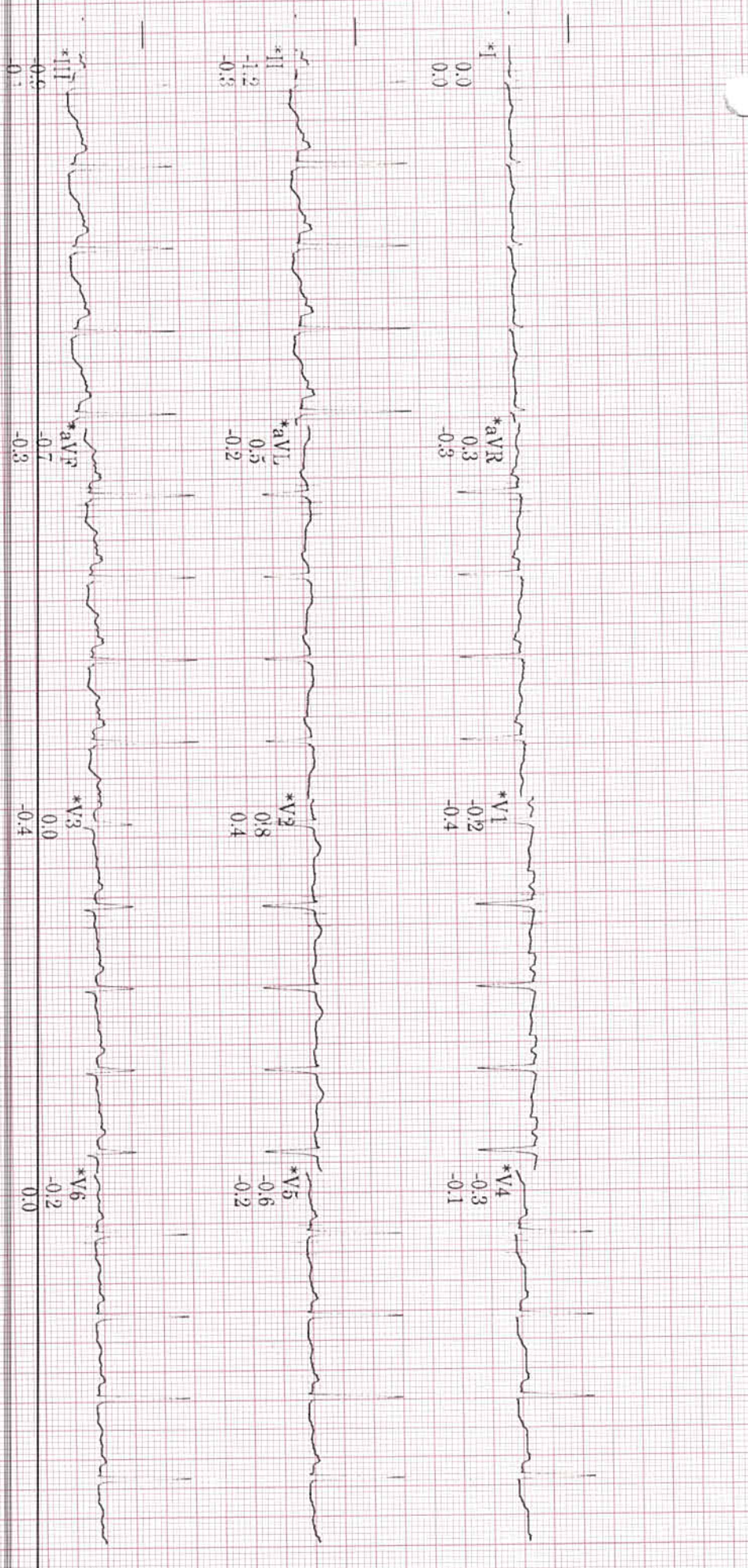
23-Oct-2023
11:38:17

RECOVERY
Post
3:00
109bpm
BP: 120/70

BRUCE
**mph
**%

ST @ 10mm/mV
80ms postJ

Lead
ST(mm)
Slope(mV/s)



ARROW CE

IP: GJPN88800
Y-SID: MEDWHEEL

25-Oct-2023
11:03:07

35 years
151 cm

Asian
60 kg

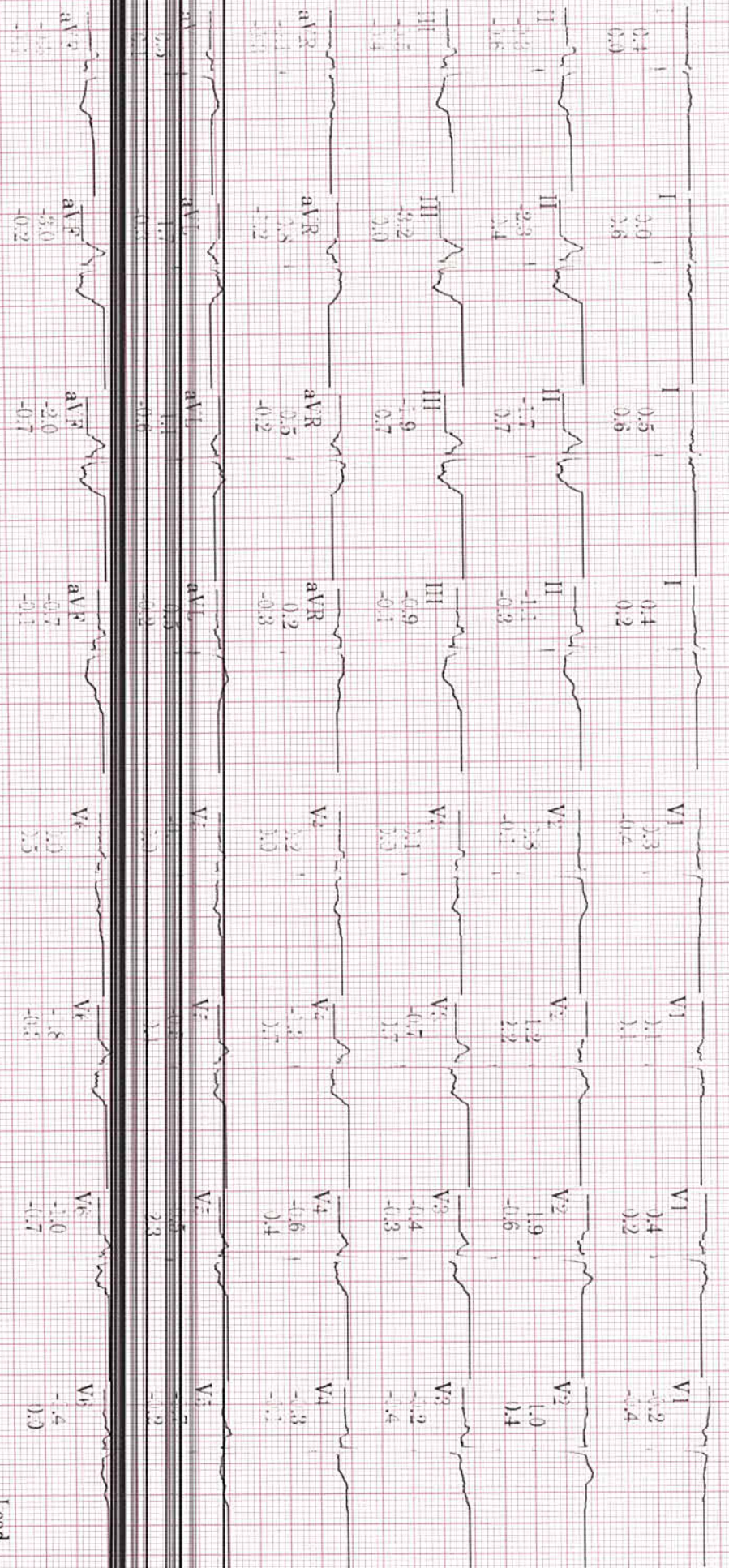Female

Referred by: SELF
Test Ind: CAD SCREENING

BRUC-1
Max HR: 180bpm 97% of max predicted 184bpm
Max EP: 130/70
Reason for Termination:
Comments: GOOD EFFORT AND TOLERANCE
NORMAL HR/EP RESPONSE
NO ANGINA AND ARRHYTHMIA NOTED
NO SIGNIFICANT ST-T CHANGES SEEN
*
TMT IS NEGATIVE FOR INDUCIBLE ISCHEMIA

Total Exercise time: 9:02
Maximum workload: 10.1 METS

BASELINE EXERCISE	MAX ST EXERCISE	PEAK EXERCISE	TEST END RECOVERY	BASELINE EXERCISE	MAX ST EXERCISE	PEAK EXERCISE	TEST END RECOVERY
6:00 169bpm	7:13 169bpm	9:00 176bpm BP: 130/70	3:06 109bpm BP: 100/70	0:00 133bpm	7:13 169bpm	9:00 176bpm BP: 130/70	3:06 109bpm BP: 100/70



Terminator: JYOTHI

Unconfirmed

MAC55 010A

ARROW CE

Lead
STV(mm)
Slope(mV/s)

ID: GJPN888800

Visit: MEDIWHEEL

23-Oct-2023
11:05:07

36years
161cm

Asian
60kg

Female

BRUCE

Max HR: 186bpm 97% of max predicted 184bpm
Max BP: 130/70
Maximum workload: 10.1METS

Total Exercise time: 9:02

Reason for Termination:
Comments: GOOD EFFORT AND TOLERANCE
NORMAL HR/BP RESPONSE
NO ANGINA AND ARRYTHMIA NOTED
NO SIGNIFICANT ST-T CHANGES SEEN

25.0 mm/s
10.0 mm/mV
100hz

Referred by: SELF
Test ind: CAD SCREENING

*
TMT IS NEGATIVE FOR INDUCIBLE ISCHEMIA

BASELINE

EXERCISE STAGE 1
0:00 1.3METS 103bpm
ST @ 10mm/mV
80ms postJ

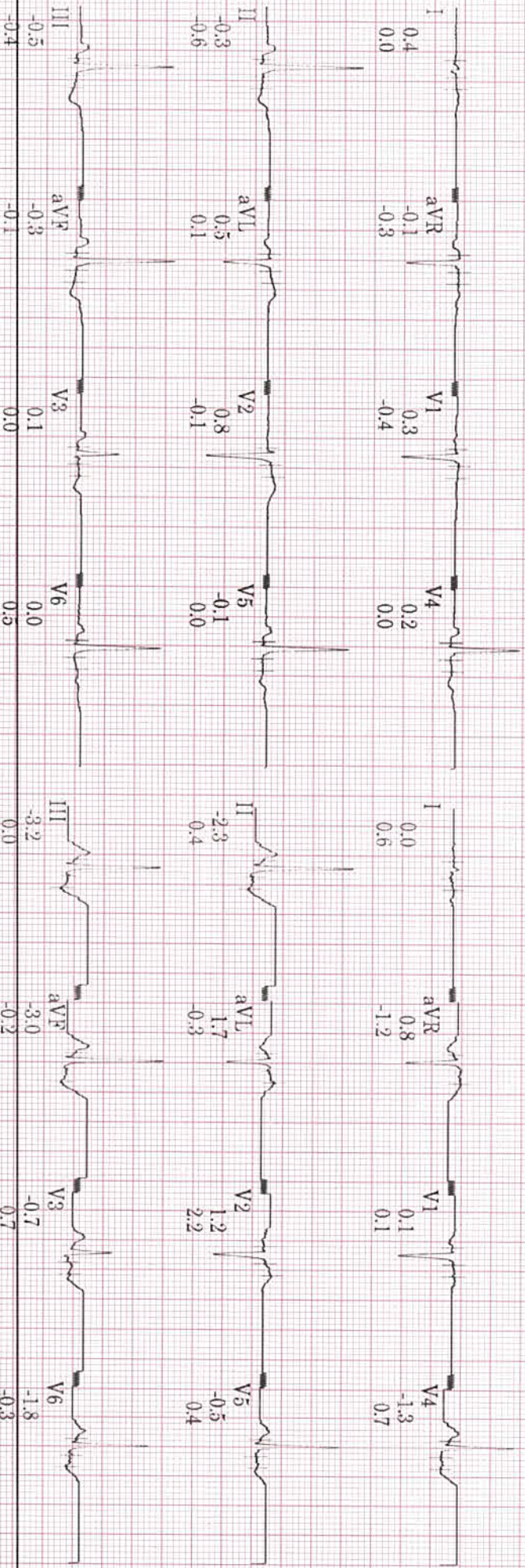
Lead
ST(mm)
Slope(mV/s)

EXERCISE STAGE 3
7:13 8.8METS

MAX ST

EXERCISE STAGE 3
169bpm
ST @ 10mm/mV
80ms postJ

Lead
ST(mm)
Slope(mV/s)



Technician: JYOTHI

Unconfirmed

MAC55 010A

Patient Name : Mrs. Ankita Agarwal

Age/Gender : 36 Y/F

UHID/MR No. : CJPN.0000088800

OP Visit No : CJPNOPV179428

Sample Collected on :

Reported on : 25-10-2023 08:23

LRN# : RAD2132083

Specimen :

Ref Doctor : SELF

Emp/Auth/TPA ID : 9887292949

DEPARTMENT OF RADIOLOGY

X-RAY CHEST PA

Both lung fields and hila are normal .

No obvious active pleuro-parenchymal lesion seen .

Both costophrenic and cardiophrenic angles are clear .

Both diaphragms are normal in position and contour .

Thoracic wall and soft tissues appear normal.

CONCLUSION :

No obvious abnormality seen.

Dr. KUSUMA JAYARAM

MBBS,DMRD

Radiology