



GUPTA ENT AND HEART CENTRE

Dayanand Marg, Nangli Circle, Alwar (Raj.) Ph. 0144-3591336 | M. 7378184427

Echocardiography Report

Name : Mr. Shiv Kumar Sharma Refd by: Dr. M. N. Thareja
Age / Sex : 59yrs./male Date : 11 November 2022

Clinical Diagnosis : For Cardiac Evaluation
2D Echocardiography Findings
Mitral Valve : Normal
Aortic Valve : Normal
Tricuspid Valve : Normal
Pulmonary Valve : Normal
Left Atrium : 4.5cm: Dilated
Left Ventricle : Normal LV size with normal LV systolic function. No RWMA

LVIDd	4.6cm.	IVSd	1.0cm.	EF	60%	Visual
LVIDs	2.7cm.	PWd	1.0cm.	EF	%	F.S.

Right Atrium : Normal
Right Ventricle : Normal
Aorta : 2.7cm: Normal
Pulmonary Artery : Normal
Pulmonary Veins : Normal
Superior Venacava : Normal
Inferior Venacava : Normal
Pericardium : Normal
Intracardiac Masses : No Intracardiac masses seen
IAS/IVS : Intact

Doppler Findings:

Valve	Peak Velocity (cm/s)	Peak Gradient (mmHg)	Mean Gradient (mmHg)	Regurgitation Grade	others/comments
Mitral Valve	E-/A-83/89			No MR	
Aortic Valve	128				
Tricuspid Valve				No TR, No PAH.	
Pulmonary Valve	74				

Diagnosis : Transthoracic echo done in supine position at resting heart rate of 70bpm, shows **Normal LV size with normal LV systolic function. LVEF~60% (Visual). No RWMA.**
Dilated LA, other cardiac chambers are normal in Size.
No MR, No TR, No PAH.
Grade I diastolic dysfunction.
No pericardial effusion /Vegetation /Clot Intracardiac masses seen.
Normal left sided arch of aorta, No Coarctation.



Dr. Prachi Gupta
MBBS, PGDCC
(Non-invasive cardiologist)
Gupta ENT and Heart Centre
Nangli Circle, Alwar

Please correlate clinically

This report is not valid for medico legal purpose.

भारत सरकार
Government of India

अभार
AABHAR

 Shiv Kumar Sharma
Date of Birth/DOB: 01/01/1963
Male/ MALE

6378 7696 5882
VID : 9108 0276 8247 9255
मेरा आधार, मेरी पहचान

Adar


Shivam

भारतीय विशिष्ट पहचान प्राधिकरण
Unique Identification Authority of India

AADHAR
AADHAR

Address:
S/O Jivan Ram Sharma, 33, Veer Savarkar
Nagar, Alwar, Alwar,
Rajasthan - 301001

Download Date: 29 Jul 2022



6378 7696 5882
VID : 9108 0276 8247 9255

1947 | help@uidai.gov.in | www.uidai.gov.in



THAREJA NURSING HOME



DIGITAL X-RAY, OPG, COMPUTERISED ECG & EEG, DIAGNOSTIC LABORATORY EQUIPED WITH COMPUTERISED AUTO ANALYZER & CBC

1, Ram Kuteer, Company Bagh Road, ALWAR - 301001 (Raj.) Ph: 0144-2700184, 2331842

PROPOSAL NO. 22D51129100029254E

Date

11-11-2022

Patient Name

MR SHIV KUMAR SHARMA

Age

59 Yrs.

Ref. By Dr.

M. N. THAREJA

Sex

M

Details of packages		Patients report	Units	Normal value
HB		13.9	gm%	M-11.5-18
TRBC		4.68	million /cu mm	M-4.0-5.5, F-3.9-5.6
TWBC		9500	cu mm	4000-11000
DLC	Polymorphs	55	%	42-75
	Lymphocytes	40	%	20-50
	Eosinophil	05	%	1-6
ESR		03	mm 1 st Hr.	M-0-9, F-0-20
Platelets		1,19,000	Lack / cu mm	1.5-4
PCV		39.3	%	37-54
MCV		84.0	Cubicmicrons	86-96
MCH		29.7	Picograms	26-34
MCHC		35.4	%	32-36
Blood Grouping & Rh Factor		"A" Rh +VE(Positive)		
BUN		13.0	Mg %	05-20
S.Creatinine		0.93	Mg/100ml	0.9-1.4 mg /100 ml
HBsAg		-		
HIV I & II		-	Elisa Method	
HbA1C		6.2	%	4-6%
PSA			Ng/ml	Less Than 4.0 Ng/ml

Details of packages		Patients report	Units	Normal value	
LFT	GGTP	26.0	U/L	5-60	
	SGOT	18.0	Units / ml	Upto 40	
	SGPT	21.0	Units / ml	Upto 40	
	S. Bilirubin	Total	0.7	mg%	Upto 1.2
		Direct	0.5	mg%	0-0.25
		Indirect	0.2	mg%	
		T. Protein	7.9	Gm%	6.2-8.3
		S. Albumin	4.5	Gm%	3.2-5.3
	Globulin	3.4	Gm%		
	Alkaline phosphate	102.0	IU/L	60 - 170	
S. Calcium	-	Gm%	8.5-10.5		
Uric Acid	4.1	Mg%	2.5-7 mg%		
Blood Sugar Fasting		85.0	Mg%	60-110 mg %	
Blood Sugar PP		162.0	Mg%	Upto 160	
Lipid Profile	S. Cholesterol	165.0	mg%	120-220	
	S. Triglycerides	120.0	mg/ml	Upto 170	
	HDL Cholesterol	52.0	IU/L		
	LDL cholesterol	89.0	IU/L	450 at 37° C	
	VI DL	24.0	mg %	Upto 35	

Routine Urine Analysis

Physical/ Chemical		Microscopic:	
Appearance	Clear	RBCs	Nil
Specific Gravity	1010	WBCs	2-3/ HPF
Ph	ACIDIC	Epith. Cells	2-3/HPF
Albumin	Nil	Casts	Nil
Glucose	Nil	Crystals	Nil
Ketones	-----	Bacteria	Nil
Blood	Nil	Glucose pp	Nil

Signature of Technician

Signature of Doctor

This Report is not Valid for Medical Legal Purpose



THAREJA NURSING HOME



DIGITAL X-RAY, OPG, COMPUTERISED ECG & EEG, DIAGNOSTIC
LABORATORY EQUIPED WITH COMPUTERISED AUTO ANALYZER & CBC

1, Ram Kuteer, Company Bagh Road, ALWAR - 301001 (Raj.) Ph: 0144-2700184, 2331842

PROPOSAL NO.

Patient Name SHIV KUMAR SHARMA

Ref. By Dr. M. N. THAREJA

Date 11/11/2022

Age 59 Yrs.

Sex M

PART - X-RAYED : X-RAY CHEST PA VIEW
REPORT : X-RAY CHEST P.A. VIEW
:- Chest is bilaterally symmetrical.
:- C.P. Angles are clear.

CONCLUSION: NORMAL STUDY

Vijay
Signature of Technician

Rivani
Signature of Doctor



THAREJA NURSING HOME

1, Ram Kuteer Company Bagh Road, ALWAR - 301001 (Raj.)
Mob. 9982111801, Ph. 0144-2700184, 2331842, Telefax: 0144-2342339
E-mail: drmnthareja@yahoo.com



Name Shiv Kumar Age 59 Yr OPD/UHID.....Date.....

Address Mobile No.....

VITALS	B.P.	Pulse	Temp.	Wt.	Ht.	Allergies
--------	------	-------	-------	-----	-----	-----------

Complaints General Dental checkup
c/o yellowish teeth

Findings
Catt
S++

Investigation
Adv scaling

Treatment

- DR. M.N. THAREJA**
7233 (RMC)
Male Infertility Specialist
- DR. SAVITA THAREJA**
7600 (RMC)
Female Infertility Specialist
- DR. JAYANT THAREJA**
A-0824 (RSDC)
M.D.S.
Oral & Maxillo - Facial Surgery
Ex Resident Trauma Centre,
AIIMS, Delhi
- DR. SHIVANI THAREJA**
10807 / 31220 (RMC)
Ophthalmologist
Cornea Specialist
- DR. PRERNA THAREJA**
A-3574
MDS (Endodontics)
Root Canal Specialist
Ex Resident
AIIMS, Jodhpur
- DR. H.R. GUPTA**
1744 (RMC)
Senior Consultant
M.S. Gen Surgeon
- DR. VARUN SAPRA**
Reg. No. 70990 (DMC)
MBBS DNB ORTHO, D.ORTHO
Joint Replacement &
Arthroscopy Surgeon

Jayant
Dr. Jayant Thareja
M.D.S.
Oral & Maxillofacial Surgery
Ex-Resident (AIIMS, TRAUMA, CENTRE)
9982111801

Pain Scale

0	2	4	6	8	10
No Pain	Mild Pain	Distressing	Disressing	Intense	Excruciating

Patient Name: Shiv Kumar Sharma

HR 69/min

Axis:

SINUS RHYTHM
LEFTWARD AXIS
OTHERWISE NORMAL ECG

Intervals:

P 54°

QRS -14°

T 42°

5.70

Shivani

UNCONFIRMED REPORT

BP: 59/85 / F

RR 866 ms

P 114 ms

PR 146 ms

QRS 86 ms

QT 392 ms

QTc 422 ms

P (II) 0.16 mV

S (V1) -0.42 mV

R (V5) 0.93 mV

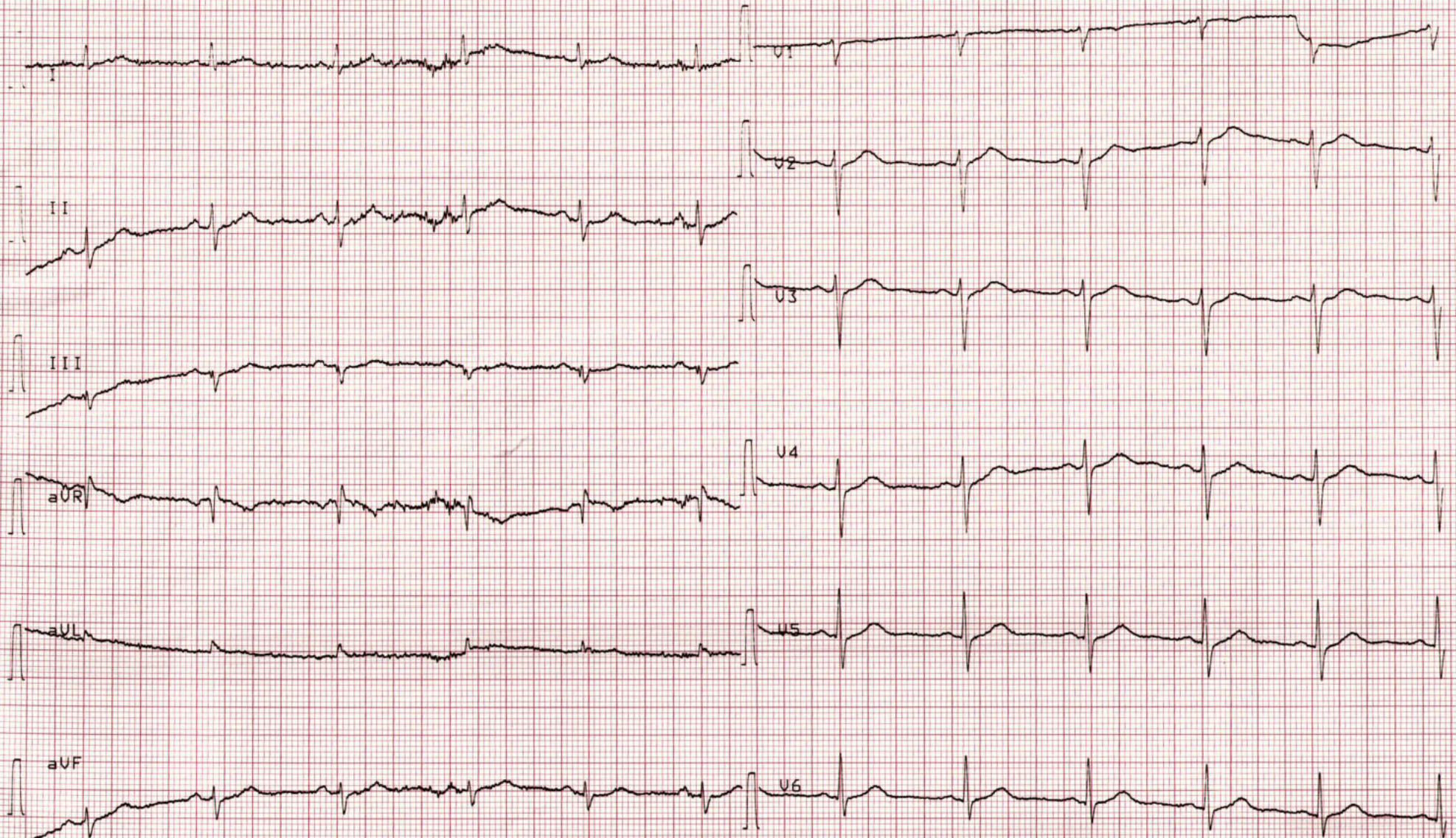
Sokol. 1.81 mV

..... cm / kg

11/11/22 mmHg

10 mm/mV

10 mm/mV





THAREJA NURSING HOME

1, Ram Kuteer Company Bagh Road, ALWAR - 301001 (Raj.)
Mob. 9982111801, Ph. 0144-2700184, 2331842, Telefax: 0144-2342339
E-mail: drmnthareja@yahoo.com



Name Mr. Shiv Kumar Shrivastava Age 59 Yr OPD/UHID.....Date 11/11/22
Address Mobile No.....

VITALS	B.P.	Pulse	Temp.	Wt.	Ht.	Allergies
--------	------	-------	-------	-----	-----	-----------

Complaints

Routine eye check up

Findings

*VA - 6/9
- 6/9
- N6
- N6 = glasses*
Investigation *Cornea clear B/E*

Treatment

Adv
(1) continue glasses

DR. M.N. THAREJA
7233 (RMC)
Male Infertility Specialist

DR. SAVITA THAREJA
7600 (RMC)
Female Infertility Specialist

DR. JAYANT THAREJA
A-0824 (RSDC)
M.D.S.
Oral & Maxillo - Facial Surgery
Ex Resident Trauma Centre,
AIIMS, Delhi

DR. SHIVANI THAREJA
10807 / 31220 (RMC)
Ophthalmologist
Cornea Specialist

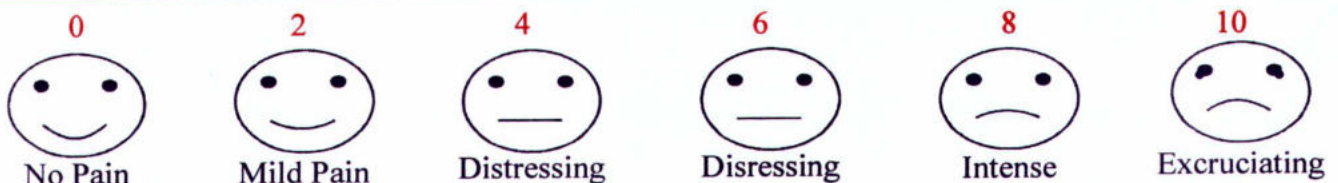
DR. PRERNA THAREJA
A-3574
MDS (Endodontics)
Root Canal Specialist
Ex Resident
AIIMS, Jodhpur

DR. H.R. GUPTA
1744 (RMC)
Senior Consultant
M.S. Gen Surgeon

DR. VARUN SAPRA
Reg. No. 70990 (DMC)
MBBS DNB ORTHO, D.ORTHO
Joint Replacement &
Arthroscopy Surgeon

Shivani
Dr. Shivani Thareja
M.S. (OPHTHAL)
Fellow (CORNEA)
L.V. Prasad Eye Institute
CORNEA CONSULTANT

Pain Scale





THAREJA NURSING HOME



DIGITAL X-RAY, OPG, COMPUTERISED ECG & EEG, DIAGNOSTIC
LABORATORY EQUIPED WITH COMPUTERISED AUTO ANALYZER & CBC

1, Ram Kuteer, Company Bagh Road, ALWAR - 301001 (Raj.) Ph: 0144-2700184, 2331842

Name : **SHIV KUMAR SHARMA**

Age : **59**

Sex : **MALE**

Ref. By : **M N THAREJA**

Lab No. :

Date : **November 11, 2022**

Immunology

<u>Test</u>	<u>Value</u>	<u>Units</u>	<u>Biological Ref. Values</u>
Prostate Specific Antigen (PSA)	1.20	ng/mL	< 4 ng/mL

Method : **Fluorescence Immunoassay Technology**

Sample Type : **Serum / Plasma / Whole Blood**

Supported By : **GYRO DIAGNOSTICS, JAIPUR**

Clinical Information :

Prostate Specific Antigen (PSA) is a Neutral Serine Protease with Chymotrypsin-like activity and Composed of a Single Polypeptide chain of 237 Amino Acids. It is an Intracellular Glycoprotein Containing 7-8% Carbohydrate as a Single N-linked Oligosaccharide side Chain, and has a Molecular Weight of Approximately 33 KDa. PSA is Synthesized by the Glandular Epithelium of the Prostate and Present in benign Hyperplastic and Malignant Prostatic Tissue, in Metastatic Prostatic Carcinoma, in Prostatic Fluid, and Seminal Plasma. Low Levels of PSA are Found in the Blood of Normal Male as a Result of Leakage of the Antigen from the Prostate Gland into Circulation. The Elevated Levels of PSA in the Blood are Associated with Prostatic Pathology, including Prostatitis, Benign Prostatic Hyperplasia (BPH), and Prostate Cancer.

Vijay
Signature of Technician

Bivani
Signature of Doctor

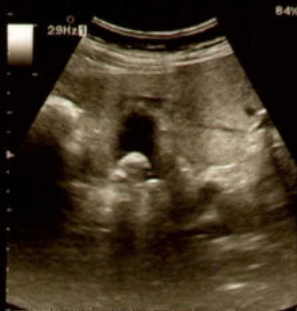ALOKA MEHARS SAHARA DIA
GNOSTICS ALWAR

:No ID

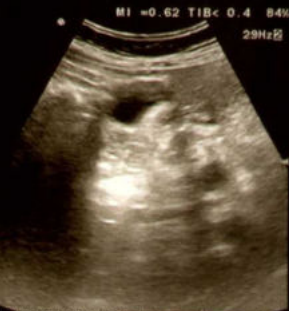: Y

11-11-'22

12:11:58



R15.0 061 C15



R15.0 061 C15

3:OBST

Probe:9123

AP BIR SCI



MEHAR'S

SAHARA DIAGNOSTICS

Reg. No. NHM/434

Dr. R.D. Arora

M.D., D.M.R.E (Radio-dagnosis)

University Topper

R.M.C. Reg. No. 28052 & 009456

Mob.: 9829136035

The Healing Ashram, 12 Kailash Colony, Bhagat Singh Circle, Alwar

11 NOV 2022

NAME : SHIV KUMAR SHARMA

Clinician: Dr

FOR : ABDOMEN

c/o pain abdomen [indication/ reason for scan]

Patient information -Technically poor quality scans because of obesity and thick abd wall +hypersthenia

On real time B-mode sonography

Liver is enlarged in size and echo pattern enhanced, no SOL is seen. Hepatic and portal veins are normal. CBD measures 3.5mm in caliber at porta , trace down lower end obscured

Gall Bladder is partially distended /contracted ,wall is thick and irregular [thickness reaches upto 3.5mm] ,cleavage plane with liver is clearly defined. lumen contains multiple calculai . No impacted calculus seen in neck at present

Pancreas is normal in size and echopattern,no SOL is seen.

Spleen is normal in size and echopattern,no SOL is seen.

Kidneys,bilaterally are normal in size and shape,no calculus or dilated calyces are seen.

Right Iliac region appendix could not be traced at present

No evidence of ascites, free Pleural effusion or lymphadenopathy is seen.

Urinary Bladder is normal in size,wall is normal in thickness ,no calculus or growth is seen.

Prostate normal

IMPRESSION:

CHRONIC CHOLECYSTITIS WITH CHOLELITHIASIS .

Fatty liver gr 1

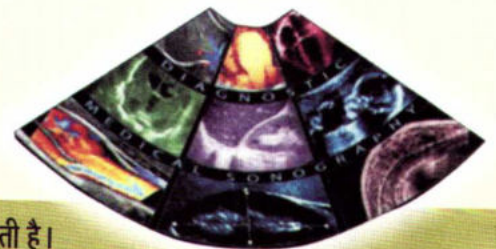Further evaluation is suggested.

Patient information -Kindly note no luminal pathology can be detected in non distended urinary tract .

Dr Ram das arora

Ultrasound scan is an investigation and therefore has technical limitations as well as inaccuracies inherent in the laboratory and statistical analysis of biological process. It should always be viewed in this perspective. Further this is a routine general scan grossly containing information sought by ref consultant and report generated thus, is for his perusal only. Considering pace of advances in the field of sonography, more specified information can also be obtained by prior intimation.

- Consultant of Radiology works
- Working hours 10 a.m. to 4 p.m. On Call Basis



“ भ्रूण लिंग परीक्षण करवाना जघन्य अपराध है तथा इसकी शिकायत 104 टोल फ्री सेवा पर की जा सकती है।

“ • “बेटी बचाओं - बेटी पढ़ाओं ”



THAREJA NURSING HOME



DIGITAL X-RAY, OPG, COMPUTERISED ECG & EEG, DIAGNOSTIC LABORATORY EQUIPED WITH COMPUTERISED AUTO ANALYZER & CBC

1, Ram Kuteer, Company Bagh Road, ALWAR - 301001 (Raj.) Ph: 0144-2700184, 2331842

Name : **SHIV KUMAR SHARMA** age **59** Sex : **MALE**

Ref. By : **M.N.THAREJA** Lab No. : Date : **November 11, 2022**

HORMONES & MARKERS

Test	Value	Units	Biological Ref. Values
T3 (Total Triiodothyronine)	0.81	ng/dL	0.60-1.81 ng/dL Adults
T4 (Total Thyroxine)	3.50	µg/dL	3.2-12.60 µg/dL : Adults
TSH (Thyroid Stimulating Hormone)	1.30	µIU/mL	Adults : 0.35-5.50 µIU/mL

Interpretation of TSH :-

Children

0 Days : 1.0~39.0 uIU/mL
 5 days : 1.7~9.1 uIU/mL
 1 year : 0.4~8.6 uIU/mL
 2 years : 0.4~7.6 uIU/mL
 3 years : 0.3~6.7 uIU/mL
 4-19 years : 0.4~6.2 uIU/mL

Adults

20-54 years : 0.35-5.50 uIU/mL
 55-87 years : 0.5-8.9 uIU/mL

Pregnancy

1st Trimester : 0.30 - 4.50 µIU/mL
 2nd Trimester : 0.50 - 4.60 µIU/mL
 3rd Trimester : 0.80 - 5.20 µIU/mL

Interpretation of TSH :-

Children

3.20 - 34.6 µIU/mL 1- 2 Days
 0.70 - 15.4 µIU/mL 3 - 4 Days
 0.70 - 9.10 µIU/mL 15 Days - 5 Months
 0.70 - 6.40 µIU/mL 5 Months - 20 Years

Pregnancy

0.30 - 4.50 µIU/mL 1st Trimester
 0.50 - 4.60 µIU/mL 2nd Trimester
 0.80 - 5.20 µIU/mL 3rd Trimester

Method : **Fluorescence Immunoassay Technology**

Sample Type : **Fresh Blood Serum**

Remarks :

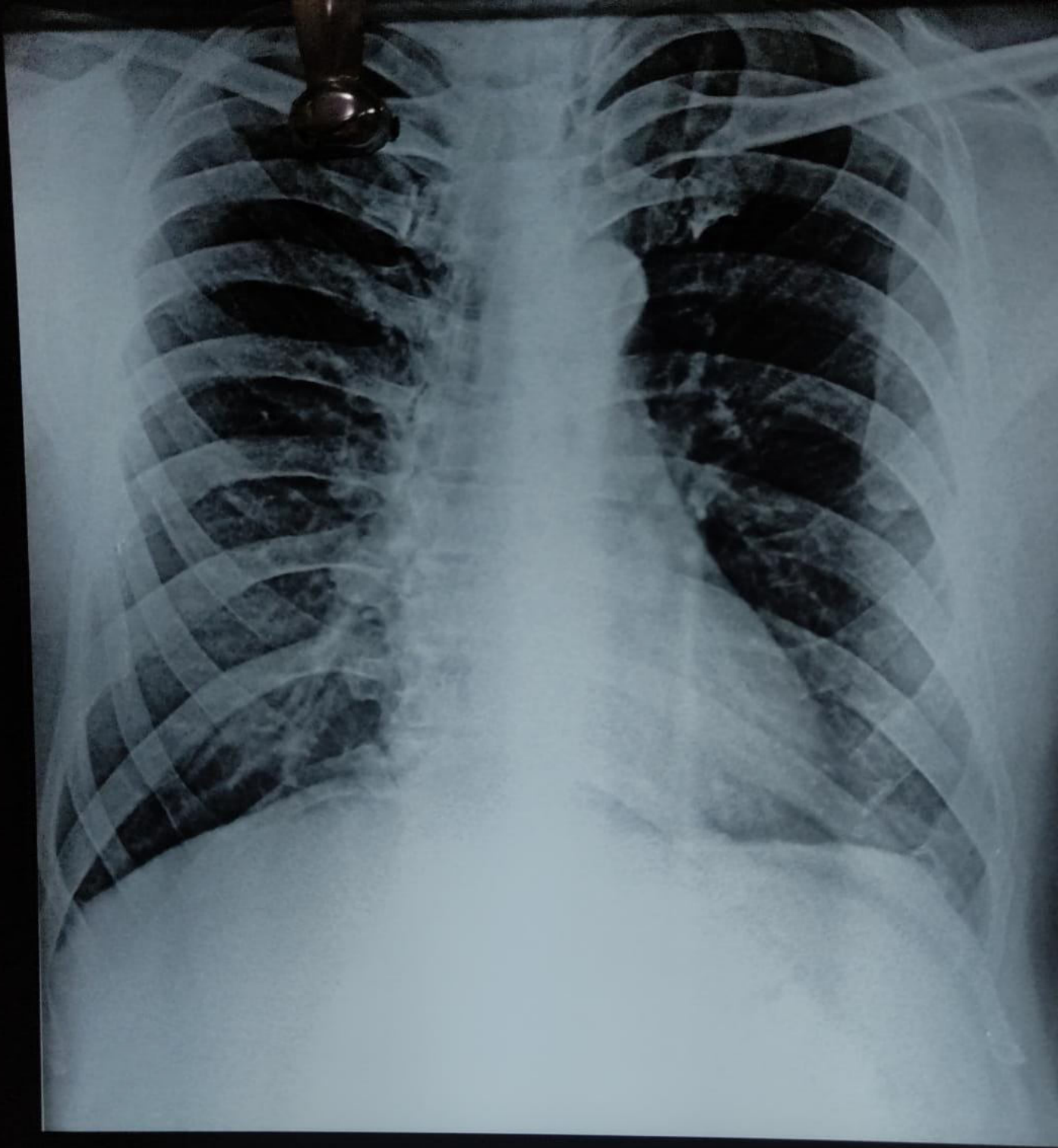
Primary malfunction of the Thyroid gland may result in excessive (hyper) or Low (hypo) release of T3 or T4. In addition, as TSH directly affect thyroid function, malfunction of the pituitary or the hypothalamus influences the thyroid gland activity.

Disease in any portion of the thyroid-pituitary-hypothalamus system may influence the level of T3 and T4 in the blood, in Primary Hypothyroidism,

TSH levels are significantly elevated, while in secondary and tertiary hypothyroidism, TSH levels may be low. In addition, in Euthyroid sick syndrome, multiple alterations in serum thyroid function test findings have been recognized.

Vijay
Signature of Technician

Shivani
Signature of Doctor



**SHIV KUMAR SHARMA 59 Y BY DR M.N. THAREJA 10556.22.1 M CHEST, PA
THAREJA NURSING HOME. COMPANY BAGH ROAD, ALWAR**