



To,

The Coordinator,  
Mediwheel (Arcofemi Healthcare Limited)  
Helpline number: 011- 41195959

Dear Sir / Madam,

**Sub: Annual Health Checkup for the employees of Bank of Baroda**

This is to inform you that the following spouse of our employee wishes to avail the facility of Cashless Annual Health Checkup provided by you in terms of our agreement.

PARTICULARS OF HEALTH CHECK UP BENEFICIARY	
NAME	ANSHU PANDEY ANSHU PANDEY
DATE OF BIRTH	05-03-1979
PROPOSED DATE OF HEALTH CHECKUP FOR EMPLOYEE SPOUSE	24-09-2022
BOOKING REFERENCE NO.	22S179052100026218S
SPOUSE DETAILS	
EMPLOYEE NAME	MR. PANDEY SUDHIR KUMAR
EMPLOYEE EC NO.	179052
EMPLOYEE DESIGNATION	HEAD CASHIER "E" _II
EMPLOYEE PLACE OF WORK	FARUKHABAD,FATEHGARH
EMPLOYEE BIRTHDATE	01-05-1979

This letter of approval / recommendation is valid if submitted along with copy of the Bank of Baroda employee id card. This approval is valid from **20-09-2022** till **31-03-2023**. The list of medical tests to be conducted is provided in the annexure to this letter. Please note that the said health checkup is a **cashless facility** as per our tie up arrangement. We request you to attend to the health checkup requirement of our employee's spouse and accord your top priority and best resources in this regard. The EC Number and the booking reference number as given in the above table shall be mentioned in the invoice, invariably.

We solicit your co-operation in this regard.

Yours faithfully,

Sd/-

**Chief General Manager  
HRM Department  
Bank of Baroda**

(Note: This is a computer generated letter. No Signature required. For any clarification, please contact Mediwheel (Arcofemi Healthcare Limited))



8166 7351 2851

Address: ORG AND QTRG  
SECTION, AIR FORCE  
STATION, KANPUR, Chaken  
Aerodrum, Chaken  
Aerodrum, Kanpur Nagar,  
Uttar Pradesh, 208008

पता: आरमर्जी एंड क्वार्टरमर्जी सेसन  
एयर फोर्स स्टेशन, कानपुर  
एकेटी एरड्रम, एकेटी आरड्रम  
कानपुर नगर, उत्तर प्रदेश, 208008

भारतीय पहचान अधिकारी केन्द्र

भारतीय पहचान अधिकारी केन्द्र



भारत सरकार

Government of India



अंशु पाण्डेय

ANSHU PANDEY

पिता : प्रेमकांत तिवारी

Father : PREMKANT TIWARI

जन्म तिथि/DOB: 05/03/1979

महिला / Female

8166 7351 2851

Dr. K. C. BHARADWAJ  
M.B.B.S., D. CARD  
Reg. No. 32749  
*K. Bharadwaj*



आधार - आम आदमी का अधिकार

Diagnostic Centre  
2072, Kankari Khana  
Mall Road, Kanpur



*K. K. Khanna*

DR. K. C. BHARADWAJ  
M.B.B.S., D. CARD  
Reg. No. 32749

Indra Diagnostic Centre  
23/22, Karachi Khana  
Mall Road, Kanpur

# Indira Diagnostic Centre, kanpur

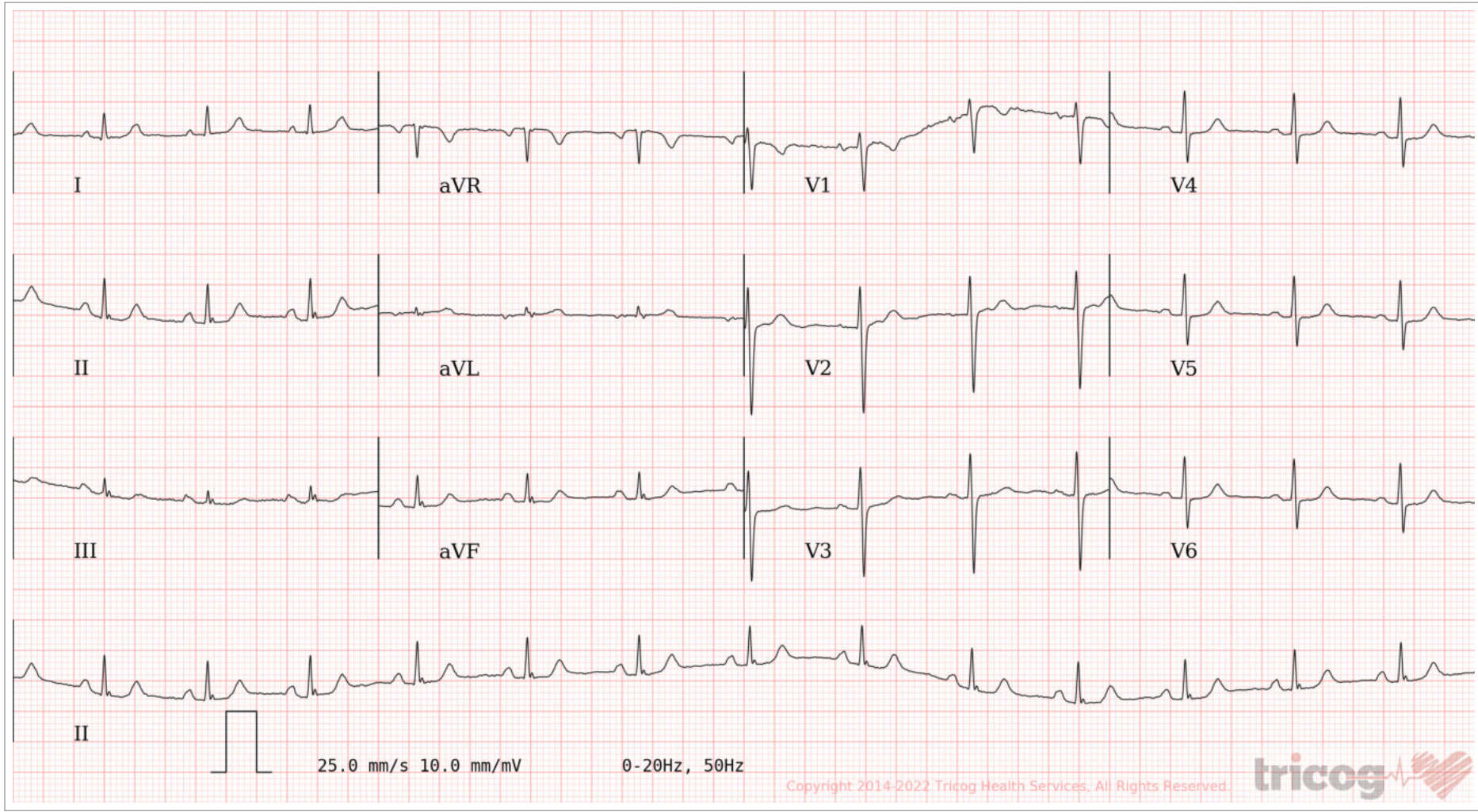



Age / Gender: 43/Female

Date and Time: 24th Sep 22 11:18 AM

Patient ID: IKNP0042052223

Patient Name: Ms.ANSHU PANDEY - BOBS16870



AR: 85bpm VR: 85bpm QRSD: 70ms QT: 322ms QTc: 383ms PRI: 136ms P-R-T: 69° 55° 47°

ECG Within Normal Limits: Sinus Rhythm, Normal Axis. Please correlate clinically.

AUTHORIZED BY

Dr. Charit  
MD, DM: Cardiology

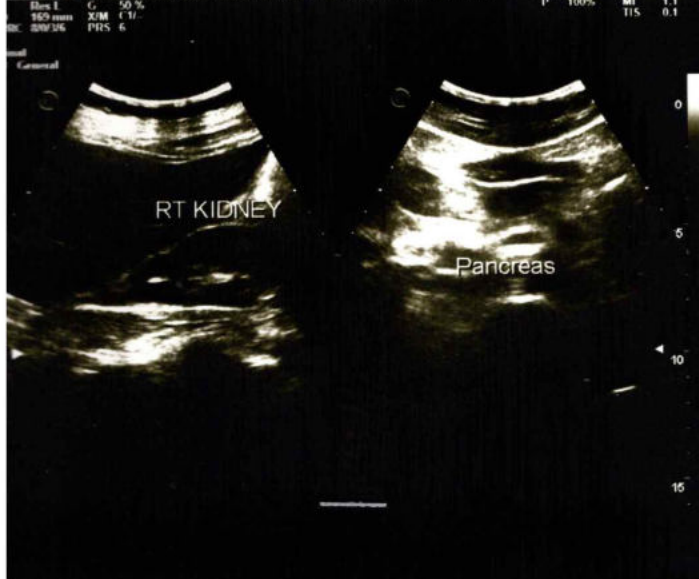
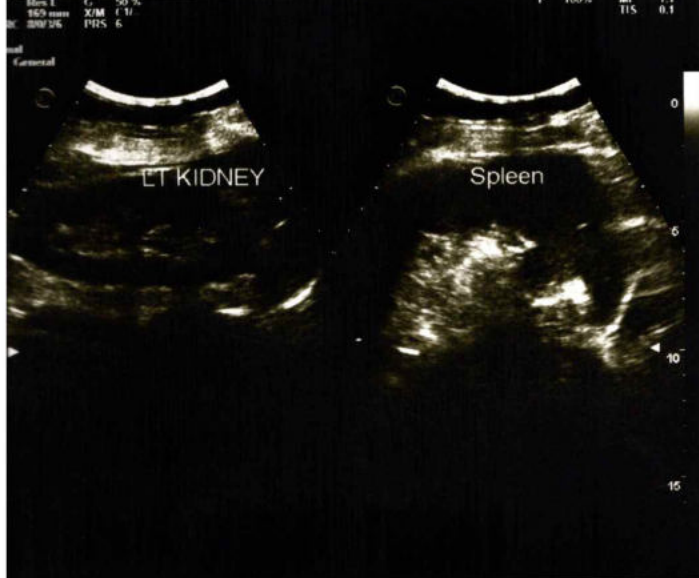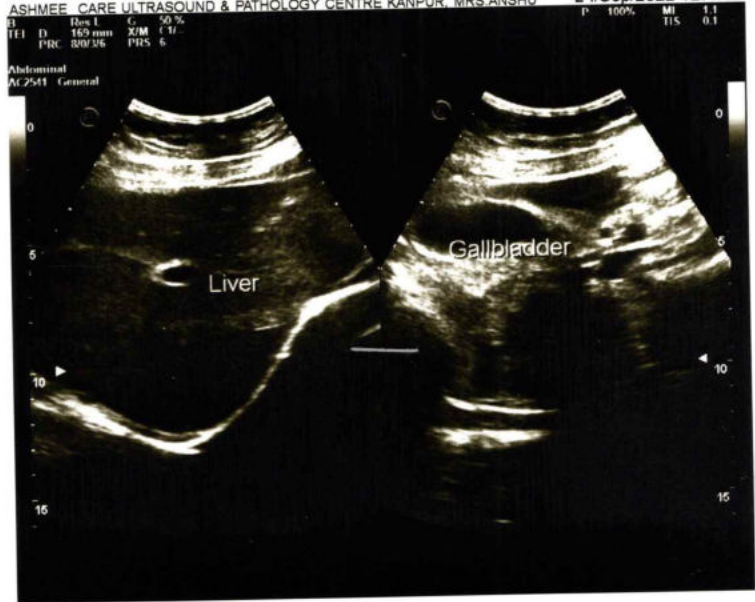
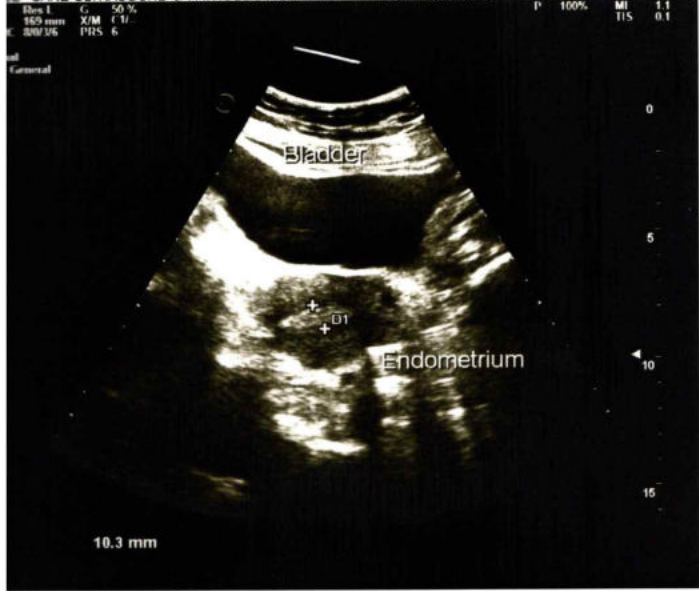63382

REPORTED BY

Dr. Alafia Hatim Canteenwala

2000/08/2914

Disclaimer: Analysis in this report is based on ECG alone and should only be used as an adjunct to clinical history, symptoms and results of other invasive and non-invasive tests and must be interpreted by a qualified physician.



# DR. A.K. GUPTA

M.B.B.S., D.C.P., I.A.P.M., P.M.H.S.  
Ex Chief Medical Superintendent  
Senior Consultant

# ASHMEE CARE

ULTRASOUND  
&  
CARDIO CENTRE

**2D ECHO ★ COLOUR DOPPLER ★ ULTRASOUND ★ TMT ★ ECG**

\*\*\*\*\*

NAME OF PATIENT: MRS. ANSHU PANDEY

AGE: 43 SEX: F

REF. BY: DR. I.D.C

DATE: 24-09-2022

\*\*\*\*\*

## ULTRASOUND REPORT WHOLE ABDOMEN

- LIVER** : LIVER IS NORMAL IN SIZE NO FOCAL LESION SEEN .THE  
INTRA-HEPATIC BILLIARY. RADICALS ARE NORMAL .THE HEPATIC VEINS ARE  
NORMAL.
- PORTAL VIEN** : NORMAL IN COURSE & CALIBER  
**GALL BLADDER** : GALL BLADDE WALL THICKNESS NORMAL .NO CALCULI SEEN IN G.B
- C B D** : NORMAL IN COURSE & CALIBER.  
**PANCREAS** : NORMAL IN SIZE, SHAPE AND ECHO TEXTURE. PANCREATIC DUCT IS NORMAL  
IN COURSE & CALIBER. NO FOCAL LESION SEEN.
- RT. KIDNEY** : NORMAL IN SIZE. POSITION AND AXIS. THE CORTICOMEDULLARY  
DIFFERENTIATION IS WELL MAINTAINED. NO CALCULI/ HYDRONEPHROSIS  
LESION SEEN.
- LT. KIDNEY** : NORMAL IN SIZE. POSITION AND AXIS. THE CORTICOMEDULLARY  
DIFFERENTIATION IS WELL MAINTAINED. NO CALCULUS/HYDRONEPHROSIS  
LESION SEEN.
- SPLEEN** : NORMAL IN SIZE AND ECHO TEXTURE. SPLENIC VEIN IS NORMAL IN  
DIAMETER.
- U. BLADDER** : NORMAL IN SIZE SHAPE AND OUTLINE. ITS WALL THICKNESS IS NORMAL. NO  
INTRALUMINAL MASS LESION/CALCULUS NOTED.
- UTERUS** : UTERUS IS ANTIVERTED NORMAL IN SIZE .**ENDOMETRIUM**  
**THICKNESS IS 10.3MM** . ENDOMETRIAL & MYOMETRIAL ECHO PATTERNS ARE  
NORMAL.
- B/L OVARIES** : BOTH OVARIES ARE NORMAL .NO T.O MASS LESION SEEN

**EXCESS BOWEL GASES SEEN IN ABDOMEN**

**IMPRESSION :**

- **ENDOMETRITIS**
- **BOWEL INFLAMMATION.**

**SONOLOGIST**



**DR. RACHIT GUPTA**

Attending Cardiologist, MD (Physician)  
PG Diploma in Clinical Cardiology

PNDT Registration No- PNDT/REG/94/2012

**SHOP NO.37/54, CAPITAL TOWER, MESTON ROAD, KANPUR NAGAR - 208001 ★ M.: 9307775184**

Note : This report is to help clinician for better patient management. Discrepancies due to technical or typing errors should be reported within three days for correction. No compensation liability stands.

NOT FOR MEDICO LEGAL PURPOSE