



ISO Certified (9001-2008)  
Late R. T. Bhoite Smruti Arogya Pratisthan's

# GIRIRAJ HOSPITAL

(State Govt. Recognised Hospital)



## PADMASHREE DR. APPASAHEB PAWAR HEART CARE CENTRE

DR. RAMESH R. BHOITE M.D.

Chairman

Reg.No.Mah.Soc.Act 1860/9888/95 Pune  
Bombay Public Trust Act. 1950/F/10595 Pune  
I.T.ded. U/S 80 G/PN 165 Rule 216/95/96  
F.C.R.A. 083930350

Only for Clinical Use

### CARDIAC COLOR DOPPLER

Patients Name: Mr Pankaj Dinkar Chandanshive

Age/Sex: 32 Year/male

Ref.: - Dr Ramesh Bhoite

Date -07<sup>th</sup> March ,2023

#### Findings: -

MV - MVA adequate, Mild MR

AV - Degenerative NO AS (AVG: 18 mmHg)/ No AR

TV - Mild TR, No PH (RVSP/TR: 14 mmHg)

PV - Normal

No Clot / Vegetation/ Pericardial Effusion

No RWMA, Mild Concentric LVH

Grade I DD

Measurements (mm); -AO-21, LA-34, IVS-11, LVPW-11, LVIDd-42, LVIDs-30 LVEF - 60%

#### Impression:

- No RWMA
- Normal LV systolic function LVEF 60%

  
Dr. Sunny Shinde

MD (MED) (BJMC, Pune),

DM (CARD) (KEMH, Mumbai)



36 Years

Male

84 bpm

--/-- mmHg

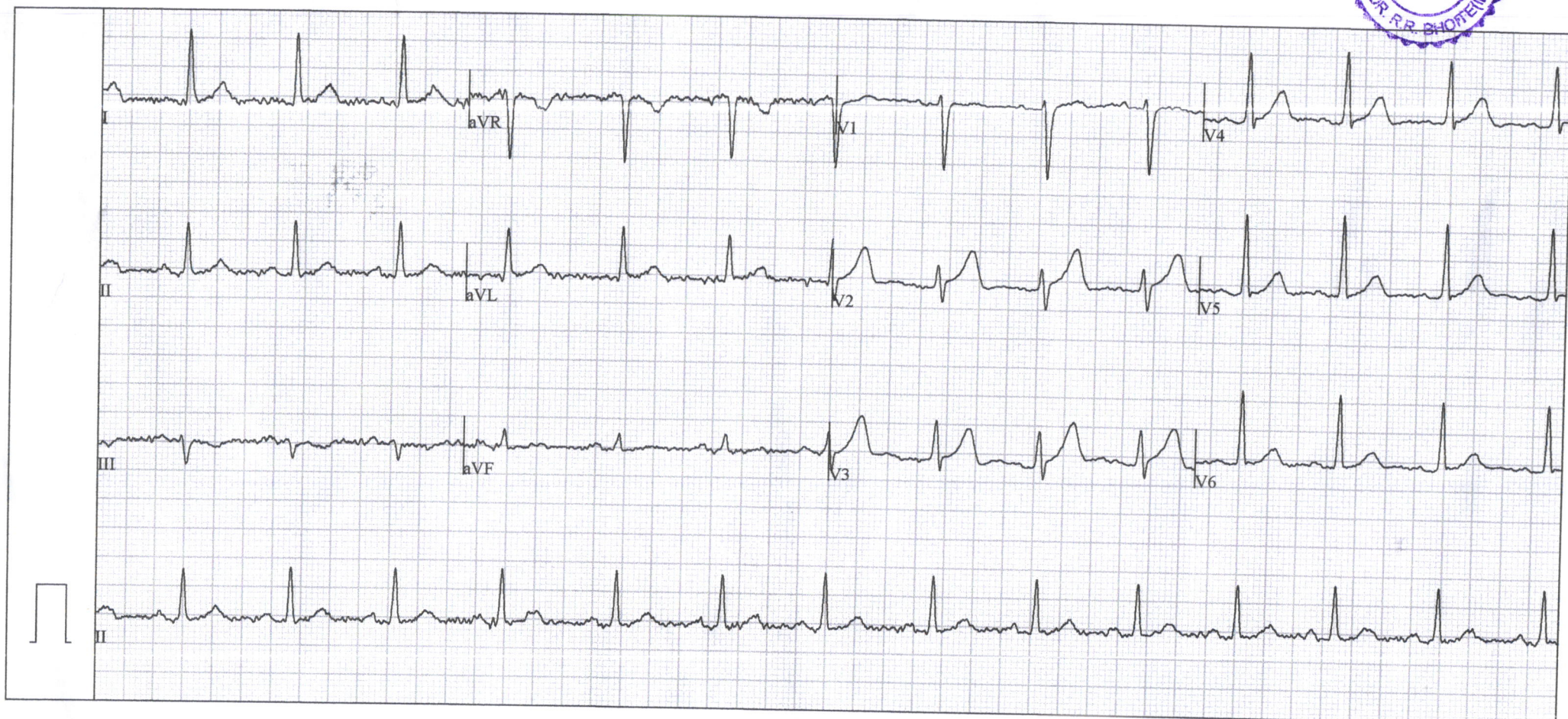
QRS : 80 ms  
QT / QTcBaz : 356 / 420 ms  
PR : 162 ms  
P : 86 ms  
RR / PP : 714 / 714 ms  
P / QRS / T : 65 / 18 / 13 degrees

Normal sinus rhythm  
Normal ECG

*Ramesh*

*ECG Normal*

**DR. RAMESH R. BHOITE, M.D.**  
Cardiologist  
Giriraj Hospital & Intensive Care Unit  
Indapur Road, Baramati-413102





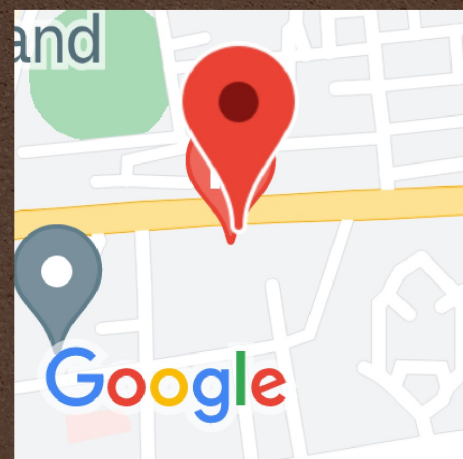

Baramati, Maharashtra, India

Near Bhoite Hospital, Indapur Road, ST Stand, Samarth Nagar, Baramati, Maharashtra 413102, India

Lat 18.1463079 / Long 74.5772557

Tuesday 07 March 2023 12:14:44







# GIRIRAJ DIAGNOSTIC CENTRE

Ultrasonography, Whole Body Colour Doppler Ultrasound, Echocardiography.



**NAME** : MR. PANKAJ CHANDANSHIVE      **AGE/SEX** : 32 YEARS/M  
**REF BY** : DR.MEDI-WHEEL INSURANCE      **DATE** : 07-03-2023

## USG STUDY OF ABDOMEN & PELVIS.

**Liver** appears normal in size shape & shows normal parenchymal reflectivity. No e/o focal mass lesion or any neoplasm seen in liver. Portal vein & CBD are normal.

**Gall bladder** is distended. Its wall thickness is normal. No peri gb collection and fat stranding.

**Pancreas:** normal in size and shape. No focal lesion or calcifications are seen within it. The pancreatic duct is normal.

**Spleen** in normal size & normal echotexture. No focal mass lesion seen in spleen.

**Both kidneys** appear normal size, shape, position & echotexture.

No calculus or mass lesion or scarring seen in both kidneys. Cortical echogenicity and thickness appears normal in both kidneys. Cortico-medullary differentiation is well maintained in both kidneys. No hydronephrosis.

**Urinary bladder** is well distended. The wall thickness is normal. No vesicle calculus is seen.

**Prostate:-** appears normal in shape, size and echotexture.

Visualized small bowel loops appear non dilated. Gaseous distension of large bowel loops.

No significant free fluid /abdominal lymphadenopathy.

### Conclusion:

- Normal USG abdomen and pelvis study.

### Suggested clinical and lab correlation.

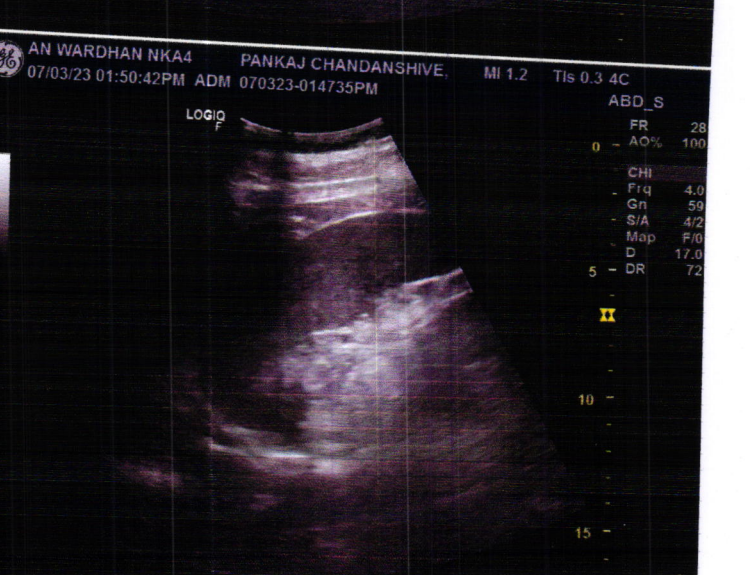
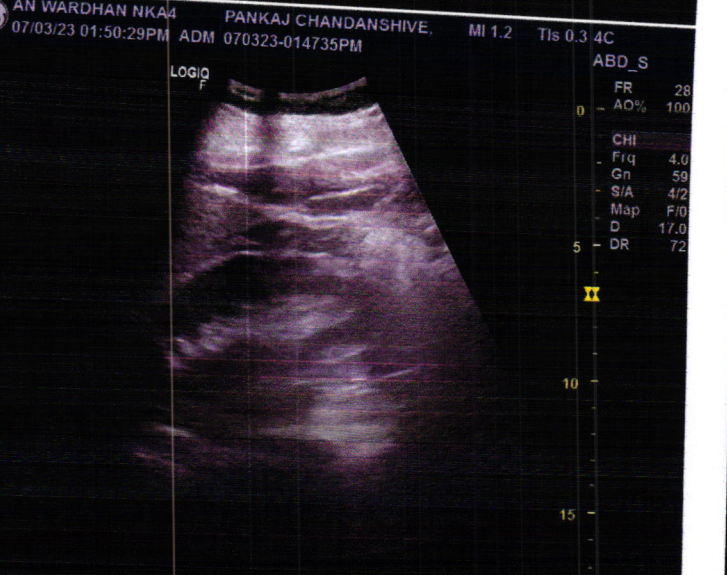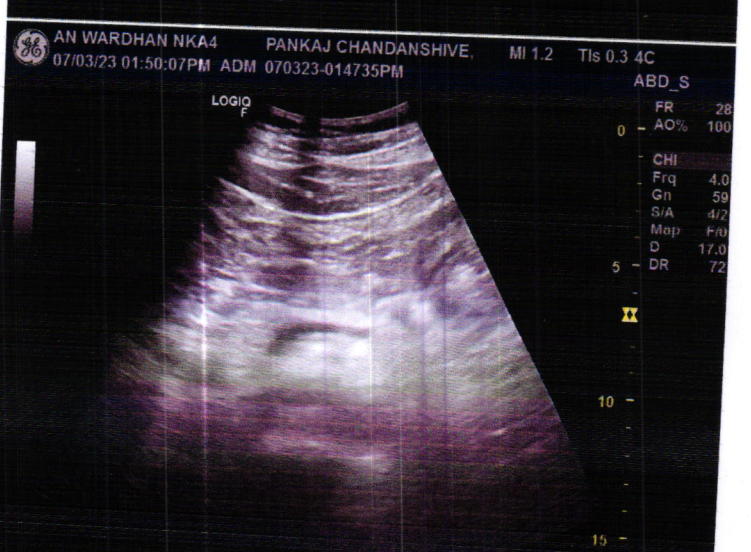
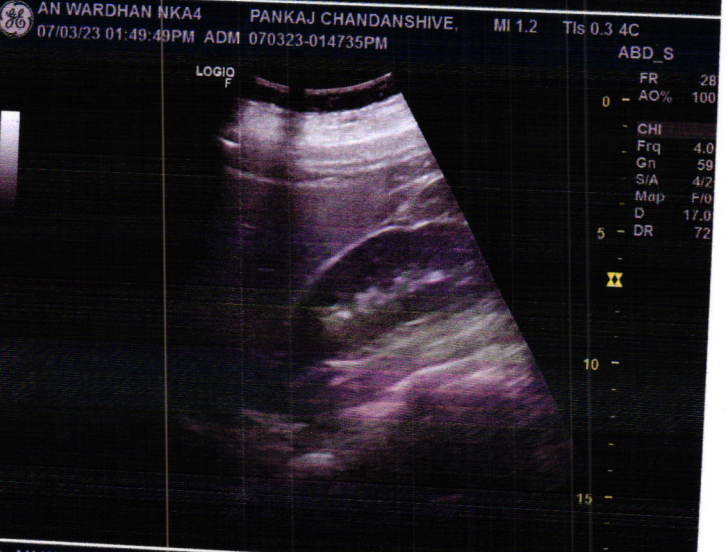
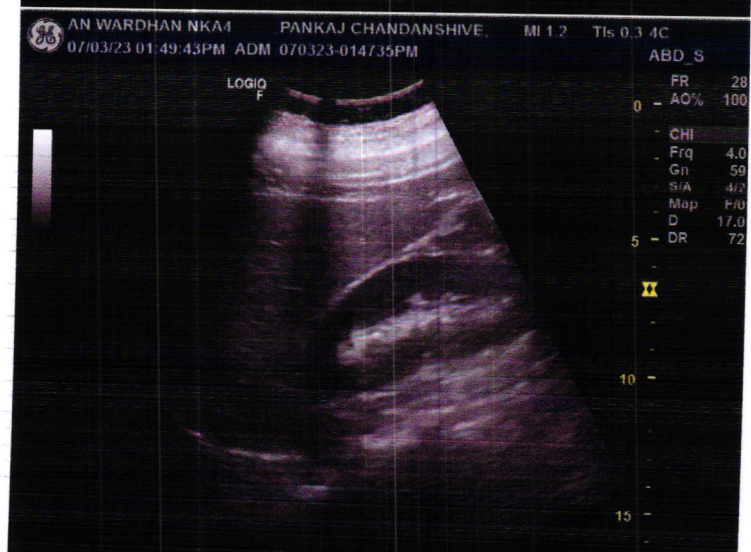
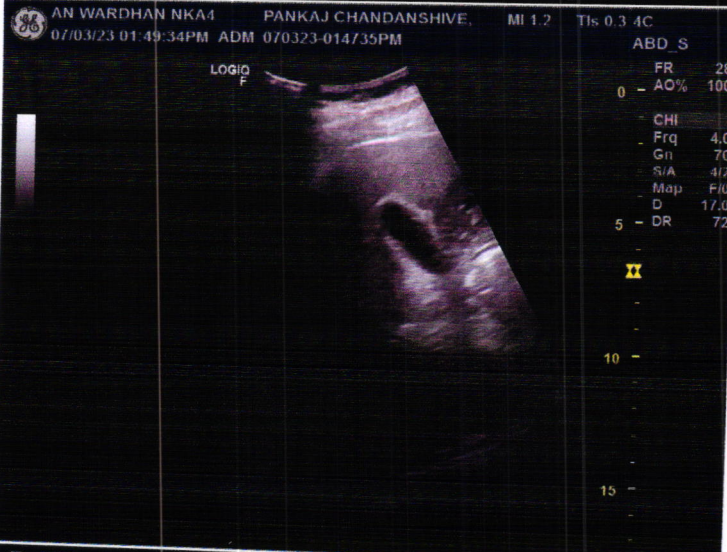
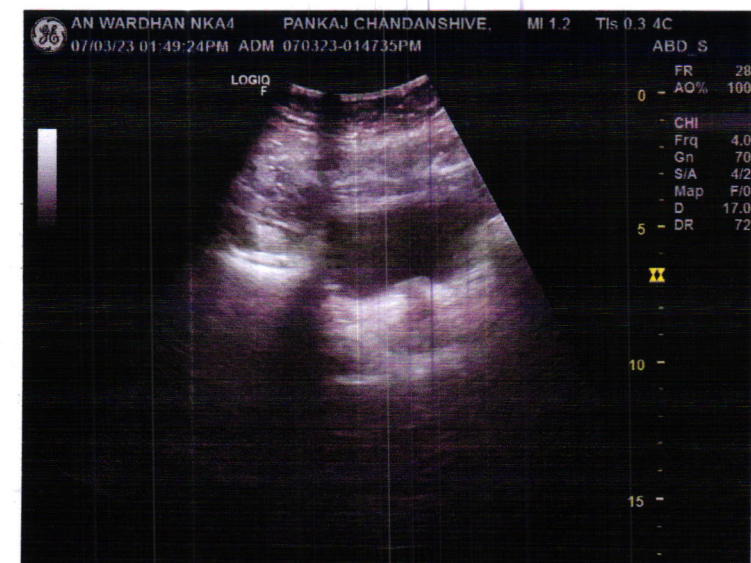
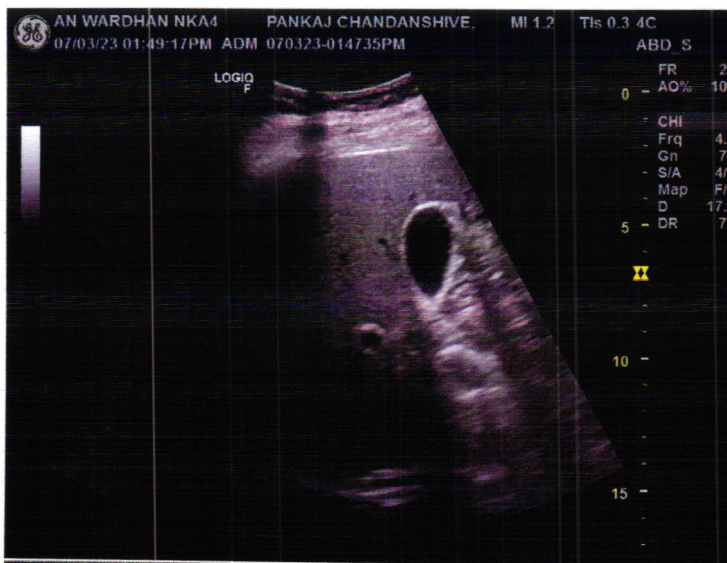
*Navids*

DR.NAVID SHATTARI

M.B.B.S, M.D. D.N.B

CONSULTANT RADIOLOGIST







# GIRIRAJ DIAGNOSTIC SERVICES

Whole Body Colour Doppler Ultrasound, Echocardiography & X-Ray



NAME : MR. PANKAJ CHANDANSHIVE

AGE / SEX : 32 YRS /MALE

REF : MEDIWHEEL INSURANCE

DATE : 07/03/2023

## X- RAY CHEST PA VIEW

- ❖ Both lung fields show equal translucency and vasculature.
- ❖ No obvious infiltration is seen on either side.
- ❖ Costo-phrenic and cardio-phrenic angles on both sides appears clear
- ❖ The cardiac size is normal.
- ❖ The domes of diaphragm are normal in position & show smooth outline.
- ❖ Visualized bones appear normal.

*Navids*

**DR. NAVID SHATTARI**  
**MBBS, MD, DNB**  
**CONSULTANT RADIOLOGIST**



GIRIRAJ HOSPITAL

PANKAJ CHANDANSHIVE/PAT008298/32 years/M/07-Mar-2023

R  
CHEST PA

GIRIRAJ DIAGNOSTIC CENTER BARAMATI

GIRIRAJ HOSPITAL CAMPUS, INDAPUR ROAD, BARAMATI, PH. 02112-222739/221335.