



भारतीय विशिष्ट पहचान प्राधिकरण

Unique Identification Authority of India

पता: S/O: सरदार विजय सिंह, क,
-, काजीपुरा, सासाराम, सासाराम,
रोहतास, बिहार, 821115

Address: S/O: Sardar Vijay Singh, -, -,
KAZIPURA, Sasaram, Sasaram, Rohtas,
Bihar, 821115

9697 1685 2145



1947
1800 300 1947



help@uidai.gov.in

WWW

www.uidai.gov.in



GPS Map Camera

Varanasi, Uttar Pradesh, India

44-B3, Durgakund, Bhelupur, Varanasi, Uttar Pradesh 221001, India

Lat 25.289246°

Long 82.993301°

25/02/23 09:05 AM GMT +05:30



भारत सरकार

Government of India



सरदार सोनु सिंह

Sardar Sonu Singh

पिता : एस. विजय सिंह

Father : S. Vijay Singh

जन्म तिथि / DOB : 21/09/1991

पुरुष / Male



9697 1685 2145

आधार - आम आदमी का अधिकार



GPS Map Camera

Varanasi, Uttar Pradesh, India

44-B3, Durgakund, Bhelupur, Varanasi, Uttar Pradesh 221001, India

Lat 25.289246°

Long 82.993301°

25/02/23 09:05 AM GMT +05:30

Facilities:

All clinical Biomedical & Hematology Investigations including Bone Marrow Examination VPT, Podiascan & Complete Foot Care (First Time in Purvanchal) All Hormonal Investigation by Chemiluminescent Method Visceral Fat by (AB-140) Ambulatory BP Monitoring CGMS & Insulin Pump Available PFT, 2D-ECHO (Color Doppler), Holter, TMT, Cardiac-3 available VIA, VILI. Colposcopy available Special Endocrinological Investigation Protocols.

ISO 9001:2008 Certified
Mobile: 9389994334, 9554572190, 9453837595



Panacea Pathology

Clinical Reference Lab

Persistence, Preparedness and Precision
EQAS (CMC Vellore Attached) & IQAS System
पूर्वांचल की सर्वोत्तम गुणवत्ता वाली पैथोलॉजी

PATIENT NAME : SARDAR SONU SINGH

AGE/GENDER : 32YRS/MALE

REFD BY DR. : ARCO FEMI HEALTHCARE LTD.

RECEIVED DATE : 25-02-2023(09:00AM)

SAMPLE : BLOOD & URINE

REPORT DATE : 25-02-2023(07:00PM)

PATHOLOGY REPORT

COMPLETE BLOOD COUNT (CBC)

TEST	LAB TEST VALUES	NORMAL RANGE
HEMOGRAM		
HEMOGLOBIN (FLOW CYTOMETRY)	14.2	13 – 16 gm/dl
TOTAL LEUCOCYTE COUNT (TLC)	6000	4000 – 11000
RBC COUNT	6.25	3.5 – 5.5
PCV (HCT)	49.0	37 – 47
MCV	78.4	80 – 95
MCH	22.7	28 – 34
MCHC	29.0	30 – 36
PLATELET COUNT	1,63,000	1,50,000 – 4,00,000
E.S.R. (WINTROBE FIRST HOURS)	12.0	20 mm/1 st hr
DIFFERENTIAL LEUCOCYTE		
NEUTROPHILS	49	40 – 75%
LYMPHOCYTES	42	20 – 45%
EOSINOPHILS	05	1 – 6%
MONOCYTES	04	2 – 8%
BASOPHILS	00	< 2 %

RENAL & KIDNEY PROFILE, SERUM

TEST	LAB TEST VALUES	NORMAL RANGE
RENAL FUNCTION TESTS		
BLOOD UREA NITROGEN (BUN)	9.2	10 – 50 mg/dl
SERUM CREATININE	0.81	0.60 – 1.60 mg/dl
URIC ACID	3.56	3.60 – 7.70 mg/dl
ALKALINE PHOSPHATASE (ALP)	71.0	142 – 353 mg/dl
TOTAL PROTIENS	7.46	0 – 39 mg/dl
ALBUMIN	4.21	3.8 – 5.4 mg/dl
SERUM GLOBULIN	3.25	2.1 – 3.5 mg/dl
CALCIUM	8.0	8.80 – 10.20
PHOSPHORUS	3.16	2.50 – 5.00
SERUM SODIUM NA+	1.014	135.00 – 155.00 mEq/Ltr
SERUM POTASIUM K+	4.12	3.60 – 5.50 mEq/Ltr
ICALCIUM	1.21	1.10 – 1.35 mmol/L
SERUM CHLORIDE CL+	101.3	98.00 – 110.00 mEq/Ltr

PAGE 1

Lab Technician

PANACEA HOSPITAL
(A UNIT OF AARON HEALTH CARE PVT. LTD.)
REG. NO.: AL-1500
B.36/44B, KABIR NAGAR
DURGAKUND, VARANASI
M.D. Pathology

Timing : 8.00 a.m. to 9.00 p.m. (Sunday 8.00 a.m. to 3.00 p.m.)

This Report is not valid for medico legal purpose

Note: These tests have technical limitations. Clinico-pathological interpretation is necessary. In case of any disparity test may be repeated immediately.

Address : 36/44 FK Kabir Nagar, Durgakund, Varanasi – 221005

Email: dramishra@gmail.com, drpallaviojha@gmail.com Website: panaceahospital.org

Facilities:
 All clinical Biomedical & Hematology Investigations
 including Bone Marrow Examination
 VPT, Podiascan & Complete Foot Care (First Time in Purvanchal)
 All Hormonal Investigation by Chemiluminescent Method
 Visceral Fat by (AB-140) Ambulatory BP Monitoring
 CGMS & Insulin Pump Available
 PFT, 2D-ECHO (Color Doppler), Holter, TMT, Cardiac-3 available
 VIA, VILI, Colposcopy available
 Special Endocrinological Investigation Protocols.

ISO 9001:2008 Certified
 Mobile: 9389994334, 9554572190, 9453837595



Panacea Pathology

Clinical Reference Lab

Persistence, Preparedness and Precision
 EQAS (CMC Vellore Attached) & IQAS System
 पूर्वांचल की सर्वोत्तम गुणवत्ता वाली पैथोलॉजी

PATIENT NAME : SARDAR SONU SINGH	AGE/GENDER : 32YRS/MALE
REFD BY DR. : ARCO FEMI HEALTHCARE LTD.	RECEIVED DATE : 25-02-2023(09:00AM)
SAMPLE : BLOOD & URINE	REPORT DATE : 25-02-2023(07:00PM)

PATHOLOGY REPORT

LIPID PROFILE, SERUM

TEST	LAB TEST VALUES	NORMAL RANGE
BLOOD CHEMISTRY		
TOTAL CHOLESTEROL (SERUM)	168.0	Desirable:- < 200 mg/dl Borderline:- 200 – 239 mg/dl High:- > 240 mg/dl
TRIGLYCERIDES (SERUM)	141.0	35 – 170 mg/dl
HDL CHOLESTEROL (SERUM)	40.0	35.30 – 79.50 mg/dl
LDL CHOLESTEROL (SERUM)	99.8	< 130 mg/dl
VLDL	28.2	< 40 mg/dl
CHOLESTROL/HDL RATIO	4.2	< 3.0 Low Risk Ratio 3.0 – 5.0 Avg Risk > 5.0 High Risk
LDL/HDL RATIO	2.4	< 3 Ratio

BLOOD GROUP

TEST	LAB TEST VALUES
BLOOD GROUP ABO & RH FACTOR	
BLOOD GROUP	"O"
RH FACTOR	POSITIVE

GLYCOSYLATED HEMOGLOBIN (HBA1C)

TEST	LAB TEST VALUES	NORMAL RANGE
HBA1C	5.7	Normal : <5.97 % Good Control : 5.97 – 6.81% Fair Control : 6.81 – 7.65% Poor Control : >7.65%

THYROID PROFILE (T3, T4, TSH)

TEST	LAB TEST VALUES	NORMAL RANGE
THYROID FUNCTION TEST		
T3	0.91	0.60 – 1.81 ng/ml
T4	7.24	4.50 – 10.90 ug/dl
TSH	2.31	0.39 – 6.10 uIU/mL

PAGE 2

Lab Technician

PANACEA HOSPITAL
 (A UNIT OF AAROH HEALTH CARE PVT. LTD.)
 REG. NO. AL-1500
 B.36/44, KABIR NAGAR
 DURGAKUND, VARANASI
 M.D., Pathology

Timing : 8.00 a.m. to 9.00 p.m. (Sunday 8.00 a.m. to 3.00 p.m.)

This Report is not valid for medico legal purpose

Note: These tests have technical limitations. Clinico-pathological interpretation is necessary. In case of any disparity test may be repeated immediately.

Address : 36/44 FK Kabir Nagar, Durgakund, Varanasi – 221005

Email: dramishra@gmail.com, drpallaviojha@gmail.com Website: panaceahospital.org

Facilities:
 All clinical Biomedical & Hematology Investigations
 including Bone Marrow Examination
 VPT, Podiascan & Complete Foot Care (First Time in Purvanchal)
 All Hormonal Investigation by Chemiluminescent Method
 Visceral Fat by (AB-140) Ambulatory BP Monitoring
 CGMS & Insulin Pump Available
 PFT, 2D-ECHO (Color Doppler), Holter, TMT, Cardiac-3 available
 VIA, VILI, Colposcopy available
 Special Endocrinological Investigation Protocols.

ISO 9001:2008 Certified
 Mobile: 9389994334, 9554572190, 9453837595



Panacea Pathology

Clinical Reference Lab

Persistence, Preparedness and Precision
 EQAS (CMC Vellore Attached) & IQAS System
 पूर्वांचल की सर्वोत्तम गुणवत्ता वाली पैथोलॉजी

PATIENT NAME : SARDAR SONU SINGH	AGE/GENDER : 32YRS/MALE
REFD BY DR. : ARCO FEMI HEALTHCARE LTD.	RECEIVED DATE : 25-02-2023(09:00AM)
SAMPLE : BLOOD & URINE	REPORT DATE : 25-02-2023(07:00PM)

PATHOLOGY REPORT

LIVER PROFILE TEST, SERUM

TEST	LAB TEST VALUES	NORMAL RANGE
BIO CHEMISTRY		
TOTAL BILIRUBIN	0.72	0.0 – 1.1 mg/dl
DIRECT BILIRUBIN	0.24	0.0 – 0.2 mg/dl
INDIRECT BILIRUBIN	0.48	< 0.90 mg/dl
SGOT (AST)	21.4	0 – 52 mg/dl
SGPT (ALT)	25.0	0 – 39 mg/dl
GGT (GYT)	19.6	< 55 U/L

URINE ROUTINE EXAMINATION

TEST	LAB TEST VALUES	NORMAL RANGE
PHYSICAL EXAMINATION		
QUANTITY	30	ML
COLOUR	STRAW	PALE YELLOW
APPEARANCE	CLEAR	CLEAR
SPECIFIC GRAVITY	1.015	1.01 – 1.03
PH	6.0	4.7 – 7.5
CHEMICAL EXAMINATION		
GLUCOSE	Not Detected	Not Detected
PROTEIN	NIL	Not Detected
MICROSCOPIC EXAMINATION		
PUS CELLS	1-2	0-5
RBC	Not Detected	Not Detected
EPITHELIAL CELLS	2-3	0-5
CASTS	Not Detected	Not Detected
CRYSTALS	Not Detected	Not Detected
BACTERIA	Not Detected	Not Detected

RANDOM/FASTING BLOOD SUGAR

TEST	LAB TEST VALUES	NORMAL RANGE
RBS/FBS		
RANDOM BLOOD SUGAR	87.0	125-140 mg/dl
FASTING BLOOD SUGAR	76.7	70-110 mg/dl

----- End of Report -----

Lab Technician

PANACEA HOSPITAL
 (A UNIT OF AAROH HEALTHCARE PVT. LTD.)
 REG. NO. AL-1500
 B.36/44 KABIR NAGAR
 DURGAKUND, VARANASI
 M.D. Pathology

Timing : 8.00 a.m. to 9.00 p.m. (Sunday 8.00 a.m. to 3.00 p.m.)

This Report is not valid for medico legal purpose

Note: These tests have technical limitations. Clinico-pathological interpretation is necessary. In case of any disparity test may be repeated immediately.

Address : 36/44 FK Kabir Nagar, Durgakund, Varanasi – 221005

Email: dramishra@gmail.com, drpallaviojha@gmail.com Website: panaceahospital.org



PANACEA HOSPITAL

B 36/44 F.K KABIR NAGAR, DURGAKUND
TOLLFREE NO-18001233070.
Whatsapp No - 8795832852
www.piire.org



OP Slip

Print Date : 25-Feb-2023 09:11AM



UHID No :- UD-22230003764 **OP No** :- OP-22230013945 **OP Date** :- 25 Feb 2023 9:10AM
Patient Name :- Mr SARDAR SONU SINGH **Age/Sex** :- 32 Y/Male **Mobile No** :- 7046446284
Father :- **Department** :- DIABETES, ENDOCRINOLOGY & METABOLIC PHYSICIAN
Pay Type :- Cash **Consultant** :- Dr ASHUTOSH MISHRA (MD(MEDICINE), IMS, BHU)
Token No :- NOR. -1 **Paid/Bal** :- 0.00 /500.00
Patient Type :- Normal
Address :- SASARAM, BIHAR

BP :- 110/80 **Rx**
 height :- 178
 Weight (kg) :- 61.3
 BMI :-

SpO2: 99
 PR: 82

Rx.

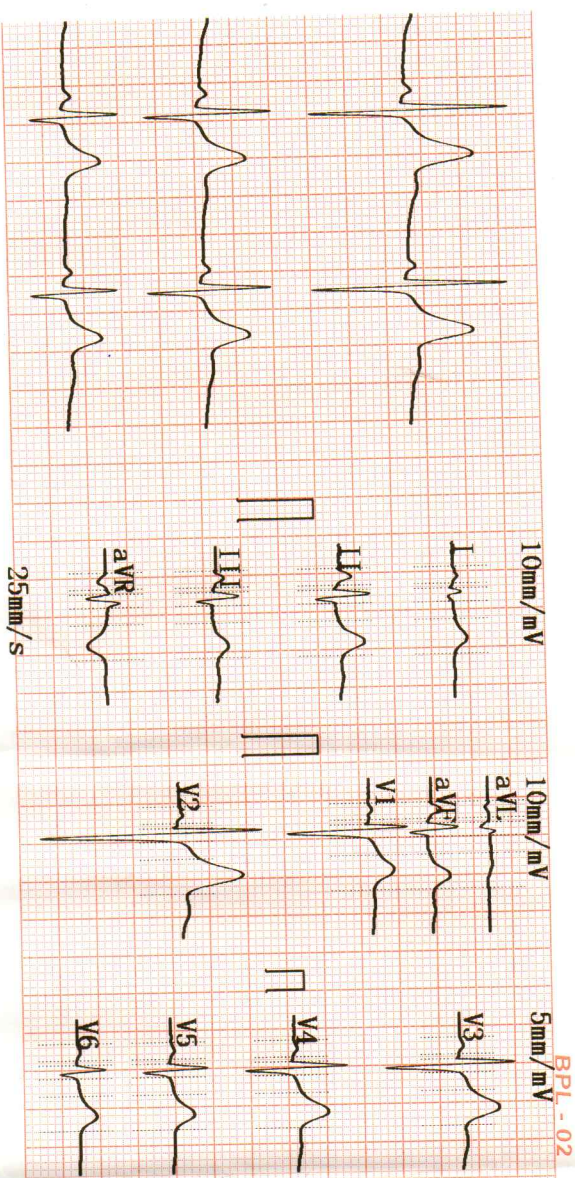
- Drel. 2000ml (a. c. d.)
- Cs. Doxery (400) OD

• 019 Influvac IM stat.

• 015 Pneumovae stat.

Printed By : Mr NITIN YADAV

Created By : Mr NITIN YADAV



BPL-02

2023-02-25 13:58

ID	:	
Name	:	
Sex	:	
Height	:	
SYS	:	
DIA	:	
HR	[bpm]	: 65
PR Interval	[ms]	: 117
P Duration	[ms]	: 90
QRS Duration	[ms]	: 73
T Duration	[ms]	: 186
QT/QTc	[ms]	: 353/366
P/QRS/T Axis	[deg]	: 67.4/73.5/57.4
R(V5)/S(V1)	[mV]	: 0.97/1.06
R(V5)+S(V1)	[mV]	: 2.03

<< Conclusions >>

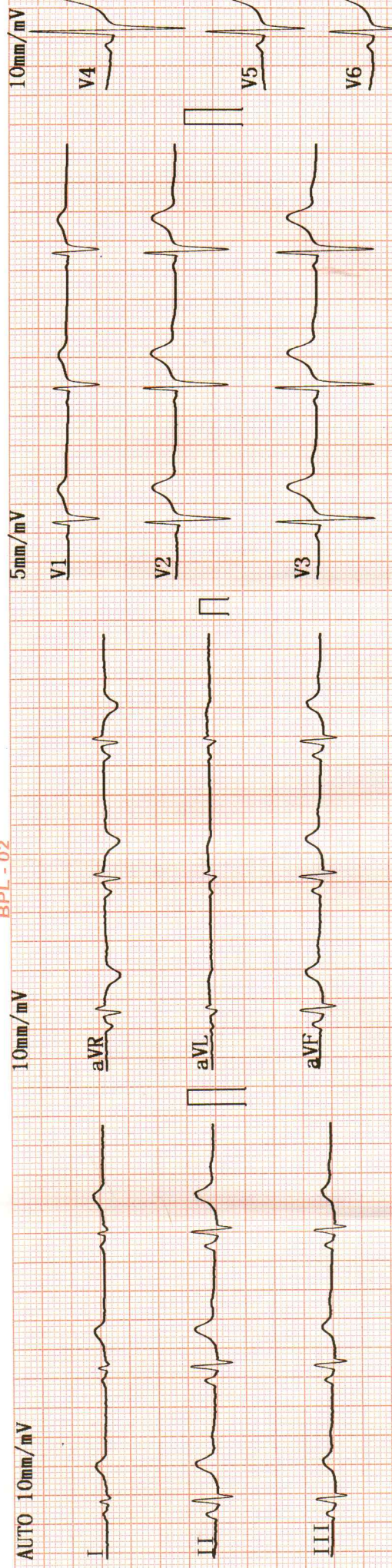
Cardiac electric axis normal;
 Report need physician confirm

Physician _____

CARDIART

Dr. Pallavi Mishra
 DR. PALLAVI MISHRA
 MBBS-MD (GENERAL MEDICINE)
 MCI Reg. No. 52033

BPL - 02



25mm/s AC50Hz+EMG35Hz+DFT

CARDIART



PANACEA HOSPITAL

A shelter for many hearts A Home for many lives

(An ISO 9001:2008 Certified Organisation)

Lab Attached with CMC Vellore Under EQAS Scheme

Name	MR.SARDAR SONU SINGH	Sex /Age	32/M	Date	25/02/2023
Ref. by	Dr.Pallavi Mishra(MD)	BSA - m ²		Echo window	fair

Echo - Cardiography


MITRAL VALVE Doppler	AML - normal morphology MV Flow - E - 0.9 A-0.4 E/A=1.75	PML - normal morphology MVA - 3.0 cm ² Mitral Regurgitation - No
TRICUSPID VALVE Doppler	Normal TV Flow -No	Tricuspid Regurgitation - No
PULMONARY VALVE Doppler	Normal PV Flow -No	Pulmonary Regurgitation - No
AORTIC VALVE Doppler	Trileaflet-No AV Flow - no	Aortic Regurgitation - no
MEASUREMENT	Aorta - 29.7 (20-38) mm IVS ed - 10.9 (6 -12) mm LVID ed - 34.8 (35 - 55) mm LVPW ed - 12.0 (6 -12) mm OA - 7 (> 5) mm	LA - 28.0 (24-32) mm IVS es -20.0 (6 - 12) mm LVID es - 24.6 (24 - 40) mm LVPW es - 9.7 (6 -12) mm EPSS - 8 (< 9) mm

CONCLUSION

All cardiac chamber dimensions are WNL
 No valvular abnormalities
 Good LV systolic function present Modified Simpson's method (4C, 2C) (LVEF-58%)
 No diastolic dysfunction present (E/A = 1.75) by tissue Doppler (E/e'=6.2)
 No RWMA
 No pericardial effusion
 Intact IAS / IV
 No PAH
 No intra cardiac mass /thrombus /vegetation

IMPRESSION **Normal Echocardiogram**

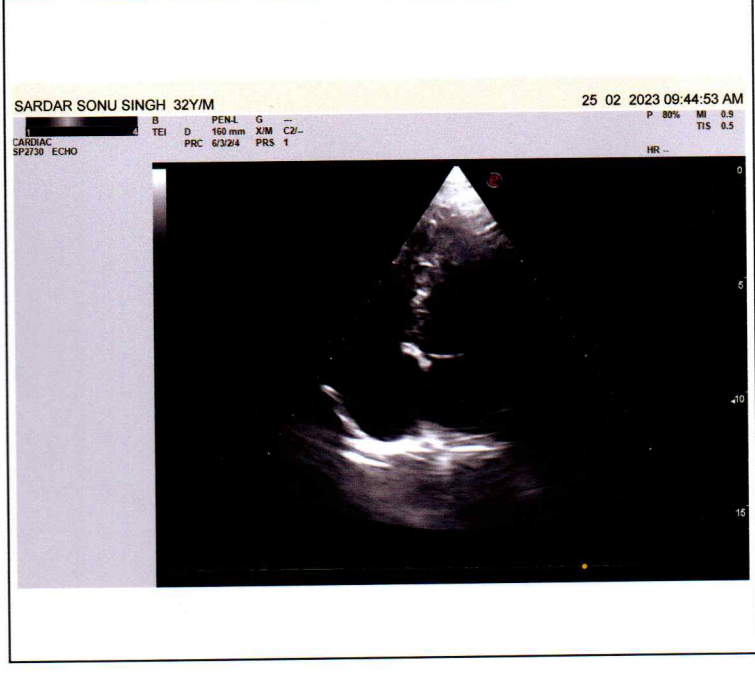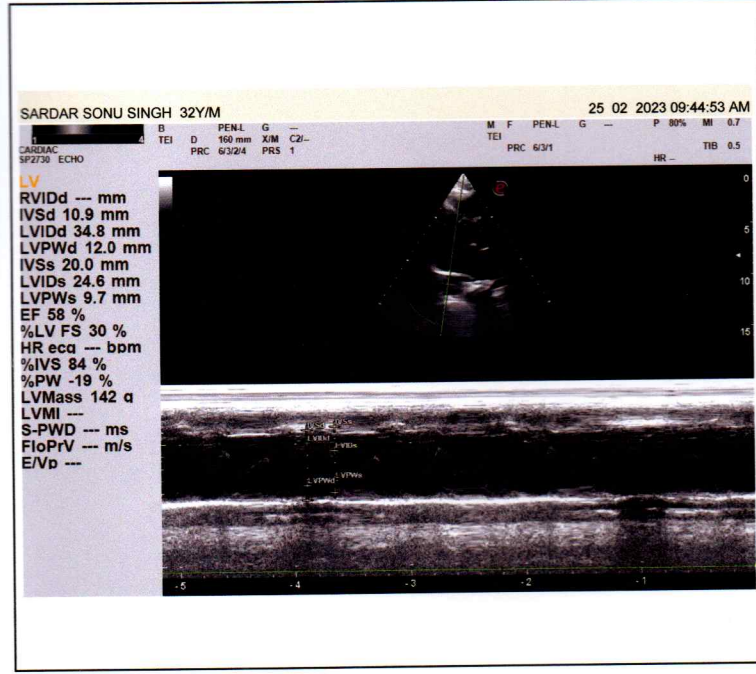
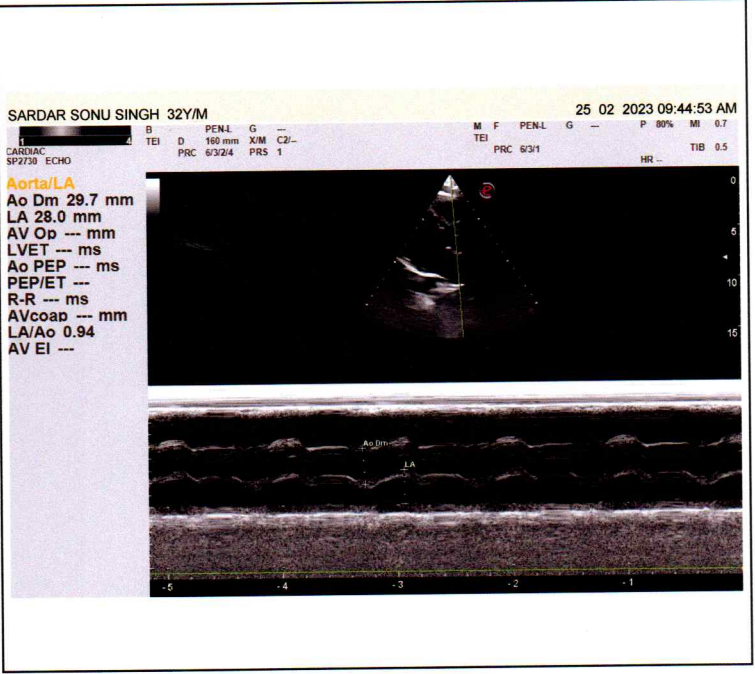
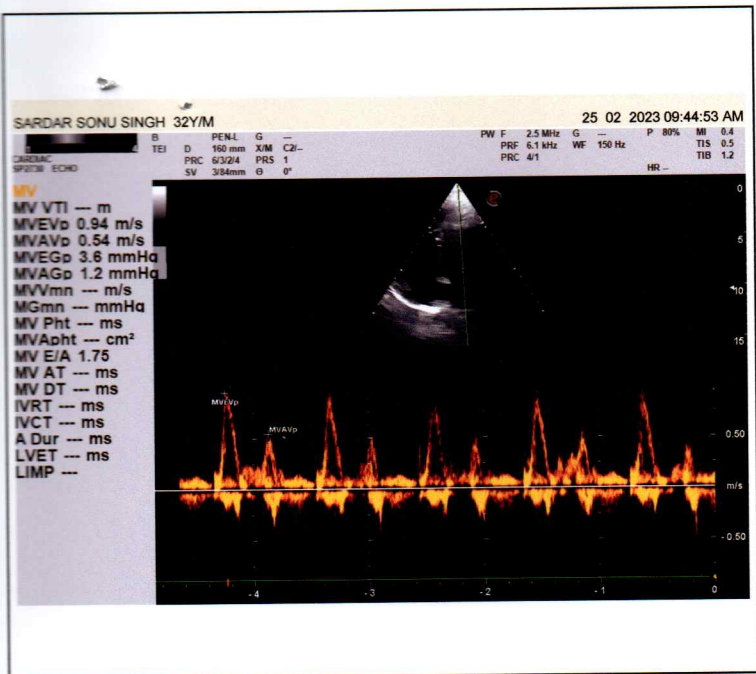

 Nira Mishra
 Physician Assistant
 (PIIRE)


 Dr. Pallavi Mishra
 MBBS, MD (MED) Lucknow
 Echo Cardiography Specialist, MIAE
 Non-invasive cardiologist
 Women Cardiologist
 Diabetocardiologist
 M.B.S. (GENERAL MEDICINE) No. 52033


Address : Kabir Nagar (Near Sanjay Shiksha Niketan), Durgakund, Varanasi

Mobile : 9554572190 / 9453837595 / Recpn. 9389994334

E-mail : dramishra@gmail.com, drpallaviojha@gmail.com, Website: www.piire.org





 **GPS Map Camera**

Varanasi, Uttar Pradesh, India

44-B3, Durgakund, Bhelupur, Varanasi, Uttar Pradesh 221001, India

Lat 25.289246°

Long 82.993301°

25/02/23 09:19 AM GMT +05:30

Panacea Hospital

Diabetes Organisation



आप कैमरे की निगरानी में हैं
YOU ARE UNDER CCTV SURVEILLANCE

महत्वपूर्ण सूचना
सुचना मरीज और उनके रिश्तेदारों के लिए
किसी भी अस्पताल/नर्सिंग होम/
क्लीनिक/हिल्थ सेक्टर में तोड़-फोड़
करना या डाक्टर एवं स्टाफ के साथ
अभद्र व्यवहार भवना ग्राह्यरहित
करना गैर जमानती अपराध है।
कानून
U.P. Medical Protection Act - 2013
1. शोषण, अपमान, धोखा देने वाली व्यवस्था।
2. 3 साल की जमानत 50000/- का जुर्माना।
3. कानूननियमित न्याय से सुनाने की शक्ति को हथकड़ी।
4. किसी भी तरह का नुकसान हमें जमानती नहीं है।
प्राप्त: हॉस्पिटल-नर्सिंग होम एंटी-कॉर्रुप्शन। आई.आई.टी. वाराणसी

GREVANCE REDRESSAL PROCEDURE
1. EMPLOYEE GREVANCE
2. DISCUSS WITH HOD
3. APPROACH THE GREVANCE REDRESSAL COMMITTEE (GRC)
&
4. PLEASE WAIT FOR GRC DECISION
5. APPEAL TO VICE CHAIRMAN
&
6. LEGAL APPROACH


National Accreditation Board
for Hospitals & Healthcare Providers

National Accreditation Board
for Hospitals & Healthcare Providers

ओ. पी. डी. पंजीकरण
O.P.D. REGISTRATION

HELP YOU

IPD BILLING

 **GPS Map Camera**

Varanasi, Uttar Pradesh, India
44-B3, Durgakund, Bhelupur, Varanasi, Uttar Pradesh 221001, India
Lat 25.289246°
Long 82.993301°
25/02/23 09:06 AM GMT +05:30



Call Now - 1800-123-3070

PANACEA HOSPITAL

A shelter for many hearts A Home for many lives

(An ISO 9001:2008 Certified Organisation)

Lab Attached with CMC Vellore Under EQAS Scheme

NAME: MR.SARDAR SONU SINGH

AGE/SEX: 32 YRS / MALE

REF BY: DR. ASHUTOSH MISHRA (MD)

DATE: 25/02/2023

ULTRA SOUND WHOLE ABDOMEN REPORT

Liver: Normal in shape and size(10.5 cm) and shows smooth and regular margin.

Gall bladder: Partially distended with normal wall thickness and echo-free lumen.

CBD Visualized part normal in course & caliber.

Pancreas: Normal in size, shape & echogenicity.Margins are smooth & regular.No diffuse/ focal lesion seen.

Spleen: Normal in size shape & echogenicity.Margins are smooth & regular. No diffuse / focal lesion seen.
Splenic vessels at hilum is normal.

Kidney: Right kidney: 9.3 X 4.3cm Left kidney: 8.7 X 4.2 cm Normal cortical echogenicity with well maintained Cortical-medullary differentiation.,Pelvicalyceal system normal.No calculus/mass lesion seen.No hydronephrosis/hydroureter seen.

Urinary bladder: Normally distended, wall thickness is normal. No echogenic foci lumen or diverticula seen.
Both VUJ appears normal.No E.R. calculus / mass lesion seen


Prostate: Normal in size, shape, & echogenicity. No calcification or focal cystic lesion seen.Capsular margins are smooth and regular.Seminal vesicles appear normal in size, shape & echogenicity.
No diffuse /focal lesion seen.

Others: No free fluid in peritoneal cavity.No free fluid in bilateral pleural cavity.

Impression:

❖ **NO SIGNIFICANT SONOLOGICAL ABNORMALITY DETECTED.**

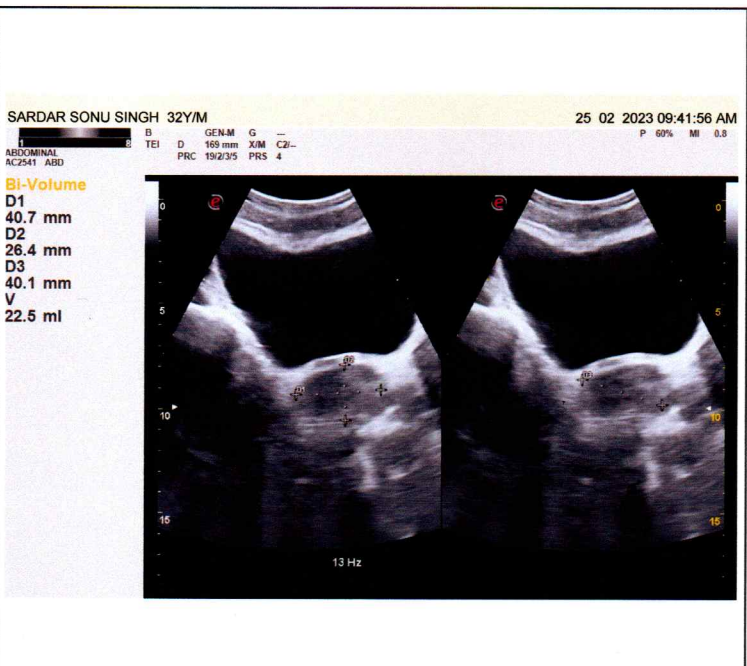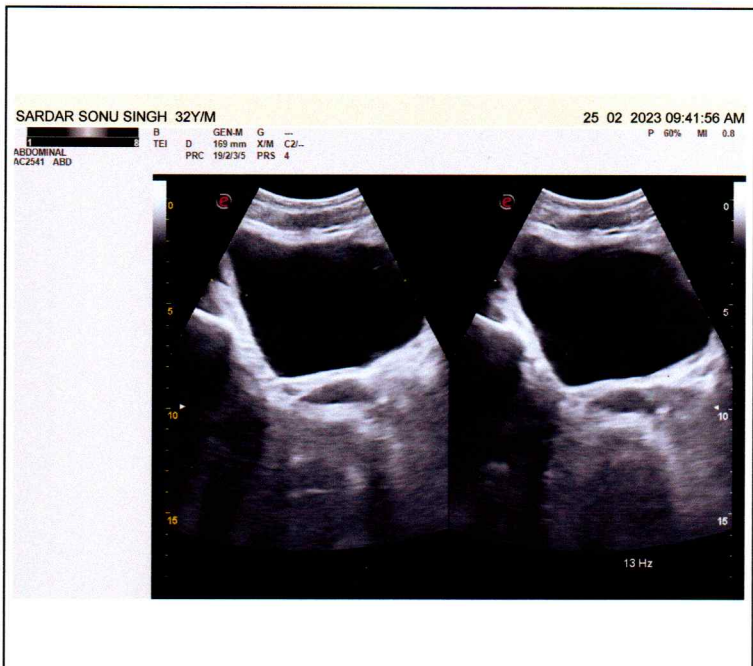
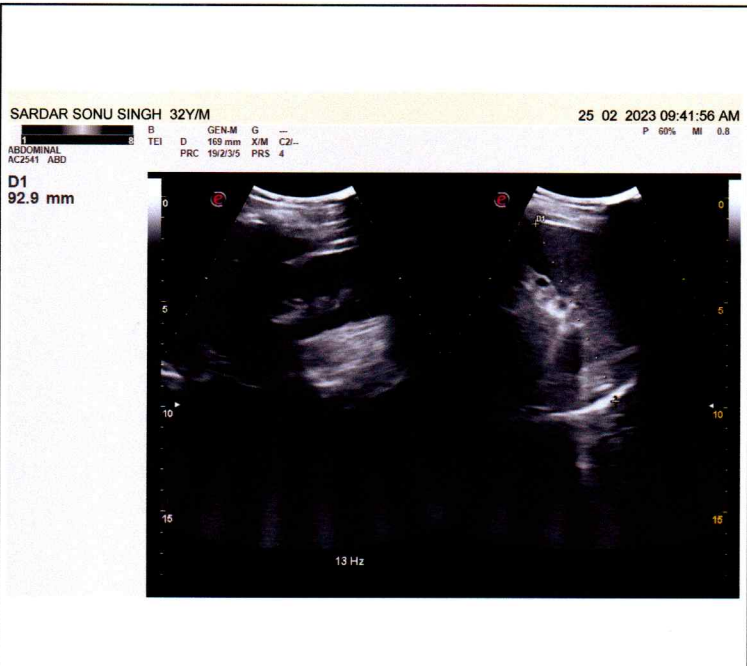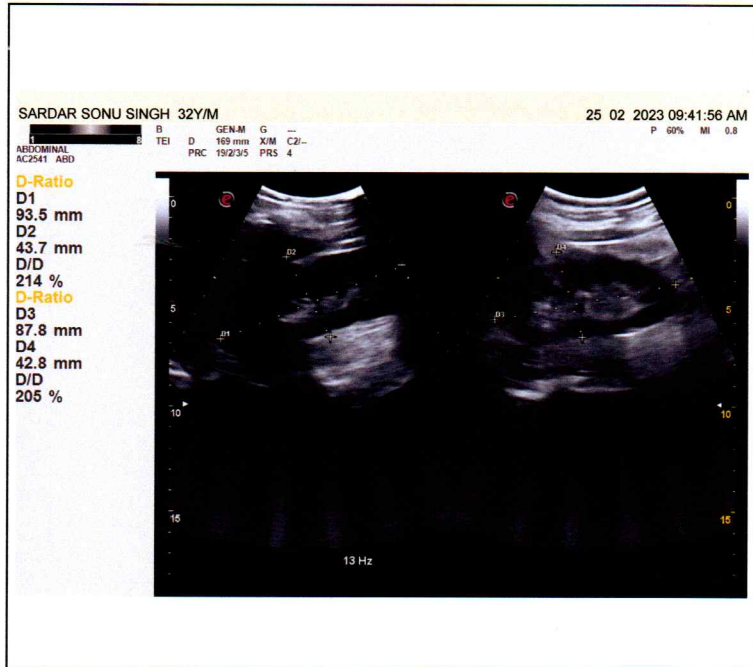
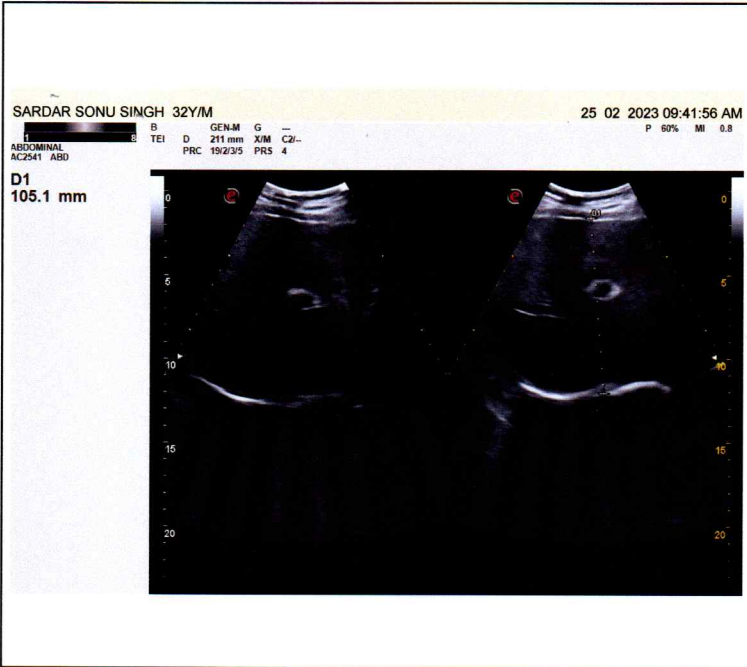
Please correlate clinically and further investigations.


REPORTED BY
DR. R. K. TIWARI
MD RADIODIAGNOSIS (GOLD MEDALIST)
KGMU,LUCKNOW
Reg.No. 57557

Address : Kabir Nagar (Near Sanjay Shiksha Niketan), Durgakund, Varanasi

Mobile : 9554572190 / 9453837595 / Recpn. 9389994334

E-mail : dramishra@gmail.com, drpallaviojha@gmail.com, Website: www.piire.org





Call Now - 1800-123-3070

PANACEA HOSPITAL

A shelter for many hearts A Home for many lives

(An ISO 9001:2008 Certified Organisation)

Lab Attached with CMC Vellore Under EQAS Scheme

ME: MR.SARDAR SONU SINGH

AGE/SEX: 32 YRS / MALE

F BY: DR. ASHUTOSH MISHRA (MD)

DATE: 25/02/2023

X-RAY CHEST PA

BOTH LUNG FIELDS AND PLEURAE:

Both lungs show normal bronchovascular pattern.

Right & left hila are normal

No focal mass or calcification is seen

There is no evidence of any fluid in the both the pleural cavities.

Both domes of diaphragms are normal in position.

MEDIASTINUM:

Trachea is central in position.

Cardiac silhouette is of normal size and configuration.

No evidence of pericardial effusion.

No significant lymphadenopathy is seen.

Visualized skeleton is normal.

NO SIGNIFICANT RADIOGRAPHIC ABNORMALITY.

R
REPORTED BY

DR. Rahul Kumar Tiwari

MBBS, MD (Radio Diagnosis)

Reg.No. 57557

Address : Kabir Nagar (Near Sanjay Shiksha Niketan), Durgakund, Varanasi

Mobile : 9554572190 / 9453837595 / Recpn. 9389994334

E-mail : dramishra@gmail.com, drpallaviojha@gmail.com, Website: www.piire.org