

ORIGINAL SEEN AND VERIFIED – 28.09.2024
MRS. SABAH NAIM, AGE: 30 YEARS

 **भारत सरकार**
Government of India 

Sabah Naim
Date of Birth/DOB: 20/10/1993
Female/ FEMALE

Download Date: 17/12/2019 Issue Date: 16/10/2019

 **5822 8100 6788**
VID : 9181 3939 7892 5819

मेरा आधार, मेरी पहचान

 **भारतीय विशिष्ट पहचान प्राधिकरण**
Unique Identification Authority of India 

Address:
C/O Amir Siddique, D 188, dargah shareef
jajmau, Shiwans Tenray, Kanpur Nagar,
Uttar Pradesh - 208010

5822 8100 6788
VID : 9181 3939 7892 5819



 1947 |  help@uidai.gov.in |  www.uidai.gov.in

Sabah Naim

POLICY HOLDER SIGNATURE



HOSPITAL SIGNATURE STAMP

Affiliated with CGHS/CAPF/TPA



TAURUS HOSPITAL

(A Unit of Taurus Medicare Pvt. Ltd.)

208. Safipur 1st Ramadevi G. T. Road, Kanpur-208 007



Phone
0512 -2400779
0512 -2400774
0512 -2400737
8601955058

Pathology Report

Lab. No. : 1137	Date : 2024-09-28 10:09:26
Patient Name : Mrs. SABAH NAIM	Guardian Name :
Age/Sex : 30 Years/Female	Address : KANPUR,
Referred By : SELF	
0	

Test Name	Observed Values	Unit	Normal Values
Blood Chemistry			
KFT			
CRET	0.65	mg/dl	0.60 - 1.20 mg/dl
UREA	35.77	mg/dl	15.00 - 45.00 mg/dl
BUN	16.31	mg/dl	5.00 - 25.00 mg/dl
UAC	5.11	mg/dl	2.50 - 7.50 mg/dl
Haematology			
CBC (Complete Blood Counts)			
HB	11.10	mg/dl	10.10 - 15.50 mg/dl
TLC	7400	/CU MM	4000-11000
DLC		%	
NEUTROPHILL	53	%	40.0-80.0
LYMPHOCYTE	38	%	20.0-40.0
MONOCYTE	04	%	2.0-10.0
EOSINOPHILL	05	%	1.0-6.0
BASOPHILL		%	2.00 - 2.00 %
RBC	4.35	U/L	4.7-7.1
PCV	35.2	%	36.0-46.0
MCV	80.9	FL	83.0-101.0
MCH	25.5	%	11-20
MCHC	31.5	g/dl	31.5-34.5
PLatelet count	2.55	lakh/cum	1.50-4.0
RDW-CV	13.5	%	11.6-14.0



Dr. Vishakha Pal
MBBS,DCP(PATH)



TAURUS HOSPITAL

(A Unit of Taurus Medicare Pvt. Ltd.)

208. Safipur 1st Ramadevi G. T. Road, Kanpur-208 007



Phone
0512 -2400779
0512 -2400774
0512 -2400737
8601955058

Pathology Report

Lab. No. : 1137	Date : 2024-09-28 10:09:26
Patient Name : Mrs. SABAH NAIM	Guardian Name :
Age/Sex : 30 Years/Female	Address : KANPUR,
Referred By : SELF	
0	

Test Name	Observed Values	Unit	Normal Values
Biochemistry			
Lipid Profile (With Direct - HDL & L)			
Cholestrol	121.73	mg/dl	0.00 - 200.00 mg/dl
triglycerides	55.79	mg/dl	0.00 - 150.00 mg/dl
HDL	60.21	mg/dl	35.00 - 80.00 mg/dl
LDL	88.47	mg/dl	0.00 - 130.00 mg/dl
VLDL	22.31	mg/dl	2.00-30.00
Cholesterol/HDL Ratio	2.02	.	<4.00
LDL/HDL cholesterol Ratio	1.46	.	<3.50
HDL/LDL Cholestrol Ratio	0.68	.	<3.50
Blood Chemistry			
L.F.T.			
BILI TOTAL	0.51	mg/dl	0-2.0 mg/dl
BILI DIRECT	0.12	mg/dl	0-0.20 mg/dl
BILI (IND)	0.39	mg/dl	0.20-0.60mg/dl
SGPT(ALT)	29.49	IU/L	up- 34 U/L
SGOT	23.69	IU/L	up-31 IU/L
ALP(ALKALINE PHOSPHATASE)	65.49	IU/L	54-369 IU/L
TOTAL PROTEIN	6.88	g/dl	6.4-8.3 g/dl
ALBUMIN(ALB)	3.55	g/dl	3.5-4.6 g/dl
Hormones & Related Test			
T3, T4 (Total) & TSH 3rd Generation			
T3	2.71	.	1.30-3.10nmol/L
T4	111.21	.	66.00-181.00nmol/L
TSH	3.79	.	0.45-4.50MIU/L



Dr. Vishakha Pal
MBBS,DCP(PATH)

Affiliated with CGHS/CAPF/TPA



TAURUS HOSPITAL

(A Unit of Taurus Medicare Pvt. Ltd.)

208. Safipur 1st Ramadevi G. T. Road, Kanpur-208 007



Phone
0512 -2400779
0512 -2400774
0512 -2400737
8601955058

Pathology Report

Lab. No. : 1138	Date : 2024-09-28 10:09:27
Patient Name : Mrs. SABAH NAIM	Guardian Name :
Age/Sex : 30 Years/Female	Address : KANPUR,
Referred By : SELF	
0	

Test Name	Observed Values	Unit	Normal Values
Biochemistry			
BLOOD SF	81.29	mg/dl	70-100

Dr. Vishakha Pal
MBBS, DCP (PATH)

Affiliated with CGHS/CAPF/TPA



TAURUS HOSPITAL

(A Unit of Taurus Medicare Pvt. Ltd.)

208. Safipur 1st Ramadevi G. T. Road, Kanpur-208 007



Phone
0512 -2400779
0512 -2400774
0512 -2400737
8601955058

Pathology Report

Lab. No. : 1137	Date : 2024-09-28 10:09:26
Patient Name : Mrs. SABAH NAIM	Guardian Name :
Age/Sex : 30 Years/Female	Address : KANPUR,
Referred By : SELF	
0	

Test Name	Observed Values	Unit	Normal Values
Biochemistry			
blood sugar (pp)	111.7	1	
Haematology			
HbA1C	6.5	g/dl	< 5.6 % Normal 5.7-6.4% Pre-Diabetes >6.5 % Diabetes 6.5-7.0% Good control 7.0-8.0% Poor control >8.0% Bad control



Dr. Vishakha Pal
MBBS, DCP (PATH)

Affiliated with CGHS/CAPF/TPA



TAURUS HOSPITAL

(A Unit of Taurus Medicare Pvt. Ltd.)

208. Safipur 1st Ramadevi G. T. Road, Kanpur-208 007



Phone
0512 -2400779
0512 -2400774
0512 -2400737
8601955058

Pathology Report

Lab. No. : 1137	Date : 2024-09-28 10:09:26
Patient Name : Mrs. SABAH NAIM	Guardian Name :
Age/Sex : 30 Years/Female	Address : KANPUR,
Referred By : SELF	
0	

Test Name	Observed Values	Unit	Normal Values
Clinical			
URINE R/M			
Colour	STRAW	.	
Appearance	CLEAR	.	
Specific Gravity	1.015	.	1.005-1.030
Ph	5.0	.	4.5-8.0
Protien	Nil	.	Nil
Glucose	Nil	.	Nil
Pus Cells	2-3	/hpf	0-5
Epithelial Cells	1-2	/hpf	0-5
RBC	Nil	/hpf	Nil
Casts	Not Seen	.	Not Seen
Crystals	Not Seen	.	Not Seen



Dr. Vishakha Pal
MBBS, DCP (PATH)



Affiliated with CGHS / CAPF TOURUS HOSPITAL

(A Unit of Taurus Medicare Pvt. Ltd.)

208, Safipur 1st Ramadevi, G. T. Road, Kanpur-208 007

Ph.: 0512-2400779, 2400774, 2400737, 8601955058 • E-mail: tourushospital@gmail.com



<i>Patient Name</i>	SABAH NAIM	<i>Patient ID</i>	280924-2
<i>Age/D.O.B</i>	30 YRS	<i>Gender</i>	F
<i>Ref Doctor</i>	SELF	<i>Date</i>	28 Sep 24

XRAY RADIOGRAPH CHEST - PA

Observations

Visualised lung fields:- Appear normal.
Bones and soft tissue shadows:- Appear normal.
Hilar Shadows:- Are within normal limits.
Both Costophrenic Recesses:- Are clear.
Domes of Diaphragm:- Are smooth.
Cardia:- Is normal in size.
Pulmonary vasculature:- Appears normal.

Impression

Essentially normal study.

Reported By,

M. Farid Khan





RAJNI HOSPITAL



A Unit of Shrimati Rajani Dwivedi Charitable Society
1518/5, Daheli Sujapur, By Pass Road, Kanpur-208013
(Near Koyla Nagar Police Chowki)
GST NO:- 09AARTS9188A1ZR

Helpline No.:

+91 -8004991414

+91 -8004991515

+91 -8004991616

+91 -8933048215

Web : www.rajnihospitalin
Email : rajnihospitalknp@gmail.com

Patient Name : Mrs. SABAH NAIM

Age : 30years/F

Referred by : Dr. SELF

Date : 28/09/2024

Investigation : USG Whole Abdomen

Liver:

- Liver is normal in size mea(135mm). with hyper echoic Echogenicity fatty change. No focal or diffuse lesion seen. Hepatic veins appear normal. No dilation of intrahepatic biliary ducts is seen.

Gall bladder:

- Gall bladder is normal in size and show echo free lumen. Wall thickness is within normal limit. No calculus is seen in GB.

Portal vein:

- Normal in size (mm) and shows normal appearance.

C.B.D.:

- Normal in size (mm) and shows normal caliber.

Pancreas:

- Pancreas is normal in size. No calcification or mass lesion seen.

Spleen:

- Spleen is normal in size. Splenic vein appears normal. No mass lesion or calcification seen.

Right kidney:

- Normal in size (101x42mm) seen in respective renal areas.

- Cortico - medullary differentiation appears to be normal.

- **Single calculus seen in right kidney. It nea(5.7mm).**

- No hydronephrosis is seen.





RAJNI HOSPITAL

A Unit of Shrimati Rajani Dwivedi Charitable Society
1518/5, Daheli Sujapur, By Pass Road, Kanpur-208013
(Near Koyla Nagar Police Chowki)
GST NO:- 09AARTS9188A1ZR



Helpline No.:

+91 -8004991414

+91 -8004991515

+91 -8004991616

+91 -8933048215

Web : www.rajnihospitalin
Email : rajnihospitalknp@gmail.com

Left kidney:

- Normal in size (105x42mm) seen in respective renal areas.
- Cortico - medullary differentiation appears to be normal.
- No calculus or mass lesion seen. No hydronephrosis is seen.

Ureter:

- Both ureters are normal.

Urinary bladder:

- Normal in size & shape, Wall thickness is normal limit.
- No calculus or mass lesion seen.

Uterus:

- **Anteverted with emlarged in size (106x64x40mm) and morphology.**
Endometrial cavity is within normal limit. Cervix shows normal sonography.
No focal mass lesion noted.

Ovaries/ Adnexa:

- **Minimum enlarged in size with Single hypo echoic simple cyst seen in left ovary. It mea(41x37mm).** Left ovary is normal.

Peritoneum/Retroperitoneum:

- **Bowel inflammation loops with gas seen in whole abdomen.**
- No free fluid seen with cul-de-sac. No lymphadenopathy is seen.

Impression:

- **FATTY LIVER**
- **RIGHT RENAL CALCULUS**
- **BULKY UTERUS**
- **LEFT OVARIAN SIMPLE CYST**
- **BOWEL INFLAMMATION LOOPS WITH GAS**

ADV: CT- Scan, LFT, KUB X-Ray, TVS Please correlate clinically.



SONOLOGIST



Affiliated with CGHS / CAPF TOURUS HOSPITAL

(A Unit of Taurus Medicare Pvt. Ltd.)

208, Safipur 1st Ramadevi, G. T. Road, Kanpur-208 007

Ph.: 0512-2400779, 2400774, 2400737, 8601955058 • E-mail: tourushospital@gmail.com



28/9/24

SABAH NAIM

30/F

2DECMO

Normal size LA, LV, RA, RV

• NO RWMA

• NO MR/TRIAR

• NO PE / Apical clot

• IVC ~ 12 mm collapse
75% Resp.

• LVEF - 60%

↓

Dr. Alor



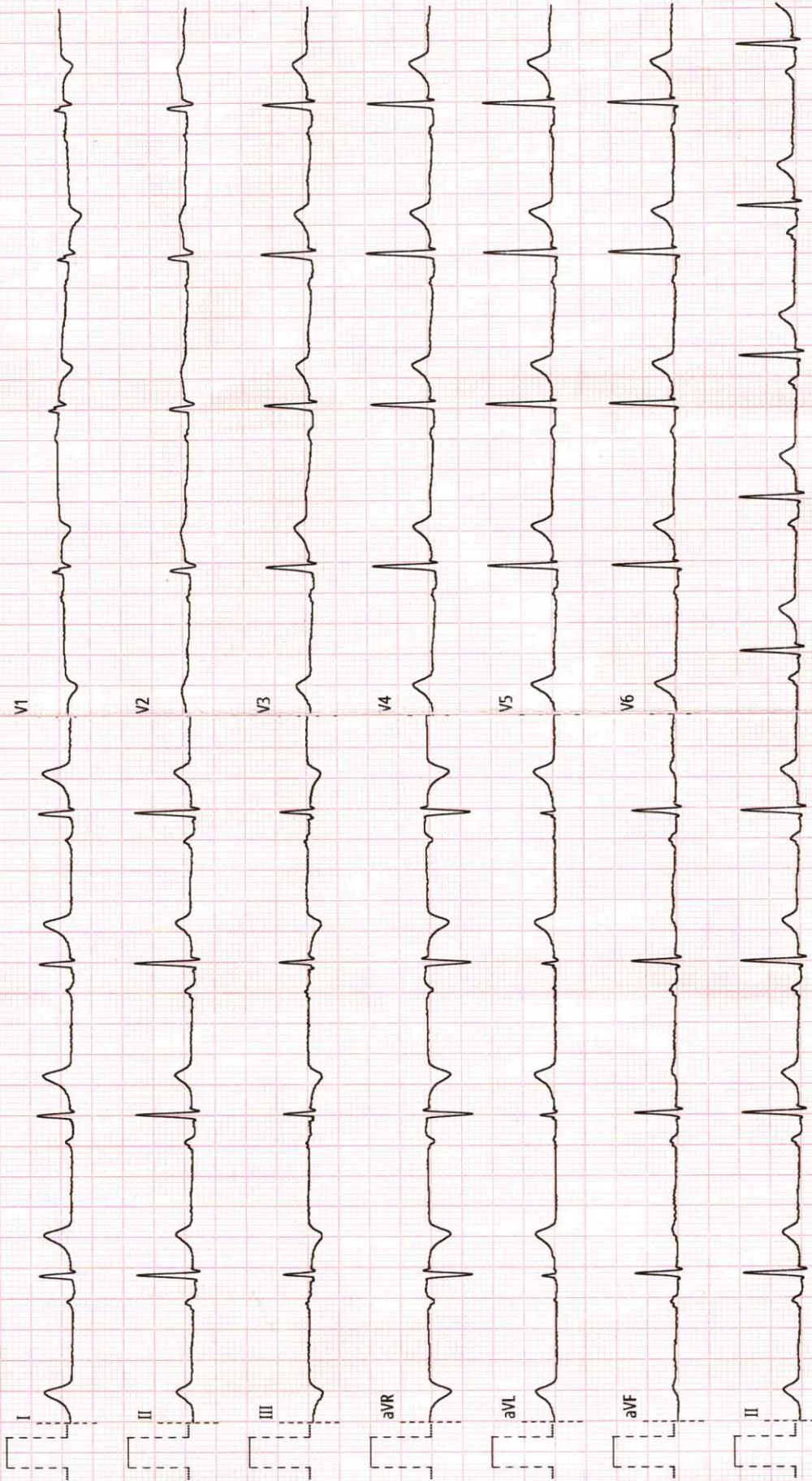
ID : 20240928074717
Name : mrs sabah
Gender: F
Age : 30 Years
Dept :
Bed No:

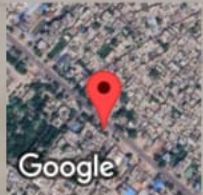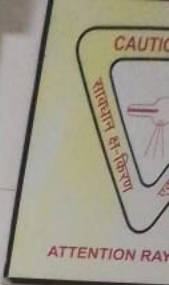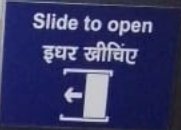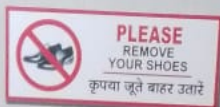HR : 59 bpm
PR : 192 ms
QRS : 90 ms
QT/QTc : 396/394 ms
P/QRS/T : 53/52/5°
RV5/SV1 : 1.112/0.104 mV
RV5+SV1 : 1.216 mV

ECG report

<<Interpretations >>
Sinus bradycardia
Normal ECG except for rate

Confirm and sign:





Kanpur, Uttar Pradesh, India
208, SAFIPUR 2, RAMA DEVI, Ramadevi, Ayodhya Market, Near Malik Complex, Lal Bungalow, Jajmau Sub Metro City, Kanpur, Uttar Pradesh 208007, India
Lat 26.413919°
Long 80.384277°
28/09/24 09:50 AM GMT +05:30