

--- A MEDALL COMPANY ---

Date 12-Feb-2022 9:49 AM

Customer Name : **MRS.RITIKA GUPTA**DOB : **09 Dec 1988**Ref Dr Name : **MediWheel**Age : **33Y/FEMALE**Customer Id : **MED110941245**Visit ID : **422009711**

Email Id :

Phone No : **8756384001**Corp Name : **MediWheel**

Address :

Package Name : **Mediwheel Full Body Health Checkup Female Below 40***(Complementary
Breakfast)**Medi*

S.No	Modality	Study	Accession No	Time	Seq	Signature
1	LAB	BLOOD UREA NITROGEN (BUN)				
2	LAB	CREATININE				
3	LAB	GLUCOSE - FASTING				
4	LAB	GLUCOSE - POSTPRANDIAL (2 HRS)				
5	LAB	GLYCOSYLATED HAEMOGLOBIN (HbA1c)				
6	LAB	URIC ACID				
7	LAB	LIPID PROFILE				
8	LAB	LIVER FUNCTION TEST (LFT)				
9	LAB	THYROID PROFILE/ TFT(T3, T4, TSH)				
10	LAB	URINE GLUCOSE - FASTING				
11	LAB	URINE GLUCOSE - POSTPRANDIAL (2 Hrs)				
12	LAB	COMPLETE BLOOD COUNT WITH ESR				
13	LAB	STOOL ANALYSIS - ROUTINE				
14	LAB	URINE ROUTINE				
15	LAB	BUN/CREATININE RATIO				
16	LAB	BLOOD GROUP & RH TYPE (Forward Reverse)				
17	OTHERS	Treadmill / 2D Echo ✓	IND129206514690			
18	OTHERS	physical examination	IND129206515279			
19	US	ULTRASOUND ABDOMEN	IND129206515292			
20	OTHERS	EYE CHECKUP	IND129206517756			
21	X-RAY	X RAY CHEST	IND129206518659			
22	ECG	ELECTROCARDIOGRAM ECG	IND129206518721			
23	OTHERS	Consultation Physician	IND129206518735			

Hb - 15.6
 Wb - 55.9
 BP - 100/70
 Pulse - 75
 Weight - 30
 H.P. - 30



ಶ್ರೀ ಪಾರ್ವತಿ ಆಪ್ಟಿಕ್ಸ್

Mahesh
Mob: 8648385220
9901569756

SRI PARVATHI OPTICS

Multi Branded Optical Store

Computerized Eye Testing & Spectacles Clinic

333.8th Main 5th Cross Near Cambridge & Miranda School HAL 3rd Stage
Behind Vishveshvariah Park New Thippasandra, Bangalore - 560075,
Email: parvathiopticals@gmail.com

SPECTACLE PRESCRIPTION

Name: Rithika Gupta

No. 209

Mobil No: 8756384001

Date: 12/02/2022

Age / Gender 334/F

Ref. No.

	RIGHT EYE				LEFT EYE			
	SPH	CYL	AXIS	VISION	SPH	CYL	AXIS	VISION
DISTANCE	3.50	1.00	5	6/6	2.75	1.25	1.75	6/6
NEAR								

PD 58mm

Advice to use glasses for:

DISTANCE FAR & NEAR READING COMPUTER PURPOSE

We Care Your Eyes

SRI PARVATHI OPTICS

NEW THIPPASANDRA

Customer Name	MRS.RITIKA GUPTA	Customer ID	MED110941245
Age & Gender	33Y/FEMALE	Visit Date	12/02/2022
Ref Doctor	MediWheel		

ABDOMINO-PELVIC ULTRASONOGRAPHY

LIVER shows normal in shape, size and has uniform echopattern. No evidence of focal lesion or intrahepatic biliary ductal dilatation. Hepatic and portal vein radicals are normal.

GALL BLADDER shows normal shape and has clear contents. Gall bladder wall is of normal thickness. CBD is of normal calibre.

PANCREAS has normal shape, size and uniform echopattern. No evidence of ductal dilatation or calcification.

SPLEEN shows normal shape, size and echopattern. No demonstrable Para -aortic lymphadenopathy.

KIDNEYS move well with respiration and have normal shape, size and echopattern. Cortico- medullary differentiations are well madeout. No evidence of calculus or hydronephrosis. A well defined hyperechoic lesion measuring about 1.3 x 1.4cms is noted in the mid pole cortex of the right kidney, suggestive of angiomyolipoma.

The kidney measures as follows:

	Bipolar length (cms)	Parenchymal thickness (cms)
Right Kidney	10.0	1.6
Left Kidney	10.2	1.2

URINARY BLADDER shows normal shape and wall thickness. It has clear contents. No evidence of diverticula.

UTERUS is anteverted and normal in size.

Anterior intramural fibroid measuring about 2.9 x 2.2 cms is noted in the mid uterine segment. Posterior subserosal fibroid measuring about 2.2 x 1.4cms is noted in the upper uterine segment.

Endometrial thickness measures 6mm

Uterus measures as follows: LS: 6.7cms AP: 4.2cms TS: 5.2cms.

OVARIES are normal in size, shape and echotexture. No focal lesion seen.

Ovaries measure as follows: **Right ovary:** 2.8 x 1.3cms **Left ovary:** 3.2 x 1.6cms


POD & adnexae are free.

No evidence of ascites/pleural effusion.

IMPRESSION:

- WELL DEFINED HYPERECHOIC LESION IN THE MID POLE CORTEX OF THE RIGHT KIDNEY SUGGESTS ANGIOMYOLIPOMA.
- UTERINE FIBROIDS.

DR. H.K. ANAND
CONSULTANT RADIOLOGISTS:
A/an


DR. APARNA



Customer Name	MRS.RITIKA GUPTA	Customer ID	MED110941245
Age & Gender	33Y/FEMALE	Visit Date	12/02/2022
Ref Doctor	MediWheel		

2 D ECHOCARDIOGRAPHIC STUDY

M mode measurement:

AORTA		: 2.3cms
LEFT ATRIUM		: 2.5cms
AVS		: ----
LEFT VENTRICLE	(DIASTOLE)	: 3.9cms
	(SYSTOLE)	: 2.6cms
VENTRICULAR SEPTUM	(DIASTOLE)	: 0.8cms
	(SYSTOLE)	: 1.1cms
POSTERIOR WALL	(DIASTOLE)	: 0.8cms
	(SYSTOLE)	: 1.2cms
EDV		: 67ml
ESV		: 24ml
FRACTIONAL SHORTENING		: 35%
EJECTION FRACTION		: 65%
EPSS		: ---
RVID		: 1.4cms

DOPPLER MEASUREMENTS:

MITRAL VALVE	: 'E' 0.66 m/s	'A' 0.46 m/s	NO MR
AORTIC VALVE	: 0.99 m/s		NO AR
TRICUSPID VALVE	: 'E' 2.22 m/s	'A' - m/s	NO TR
PULMONARY VALVE	: 0.72 m/s		NO PR



Customer Name	MRS.RITIKA GUPTA	Customer ID	MED110941245
Age & Gender	33Y/FEMALE	Visit Date	12/02/2022
Ref Doctor	MediWheel		

2D ECHOCARDIOGRAPHY FINDINGS:

Left ventricle	: Normal size, Normal systolic function. No regional wall motion abnormalities.
Left Atrium	: Normal.
Right Ventricle	: Normal.
Right Atrium	: Normal.
Mitral valve	: Normal, No mitral valve prolapsed.
Aortic valve	: Normal, Trileaflet.
Tricuspid valve	: Normal.
Pulmonary valve	: Normal.
IAS	: Intact.
IVS	: Intact.
Pericardium	: No pericardial effusion.

IMPRESSION:

- NORMAL SIZED CARDIAC CHAMBERS.
- NORMAL LV SYSTOLIC FUNCTION. EF: 65%.
- NO REGIONAL WALL MOTION ABNORMALITIES.
- NORMAL VALVES.
- NO CLOTS / PERICARDIAL EFFUSION / VEGETATION.

DR. K.S. SUBRAMANI, MBBS, MD, DM (CARDIOLOGY) FESC
SENIOR CONSULTANT INTERVENTIONAL CARDIOLOGIST
Kss/an

Note:

- * Report to be interpreted by qualified medical professional.
- * To be correlated with other clinical findings.
- * Parameters may be subjected to inter and intra observer variations.

SUBRAMANI.K.S.
MD, DM (CARDIOLOGY)
Consultant Cardiologist
KMC
Climax Diagnostics

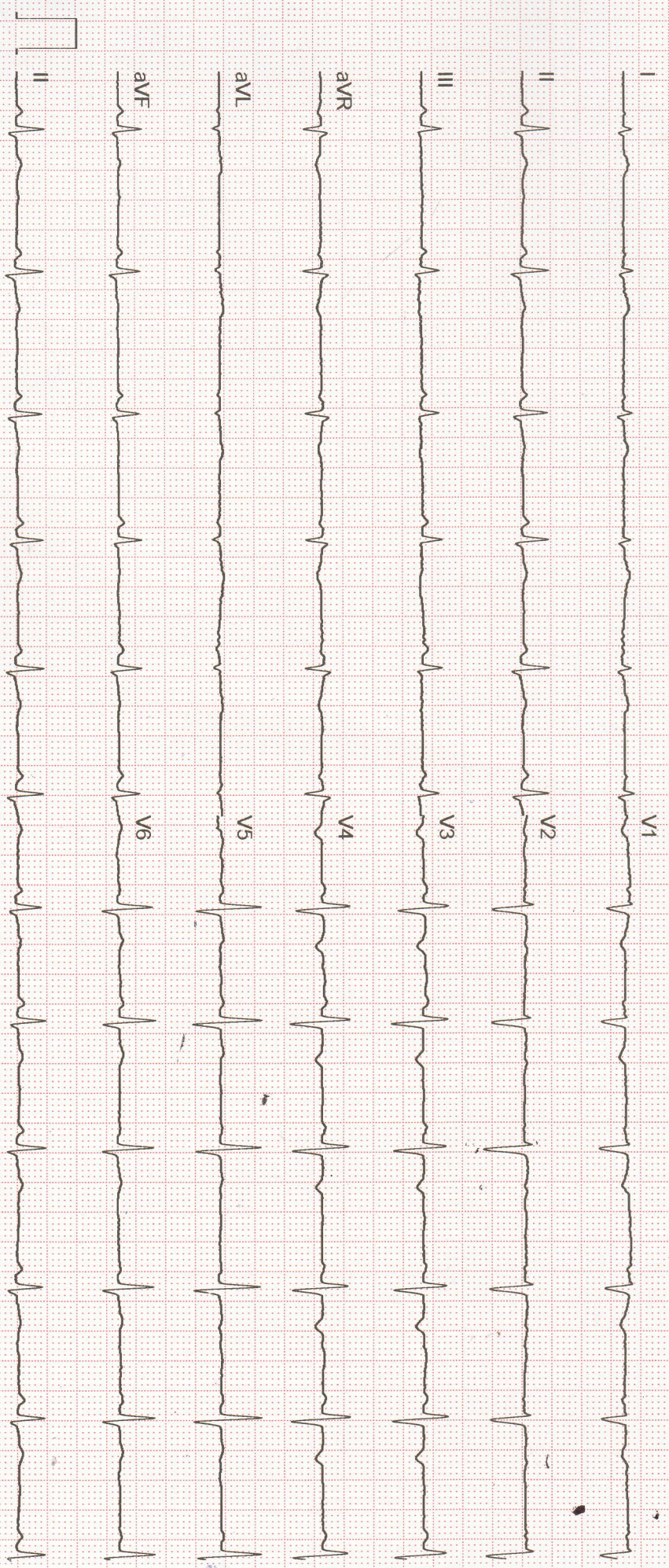
You can also conveniently view the reports and trends through our App. Scan QR code to download the App.



Please produce bill copy at the time of collecting the reports. Request you to provide your mobile number or customer id during your subsequent visits.

33 Years Female

QRS : 78 ms
QT / QTcBaz : 362 / 387 ms
PR : 136 ms
P : 96 ms
RR / PP : 866 / 869 ms
P / QRS / T : 78 / 73 / 19 degrees



Normal ECG
Insane
Chaper
W

Unconfirmed

Name	RITIKA GUPTA	Customer ID	MED110941245
Age & Gender	33Y/F	Visit Date	Feb 12 2022 9:49AM
Ref Doctor	MediWheel		

X - RAY CHEST PA VIEW

Bilateral lung fields appear normal.

Cardiac size is within normal limits.

Bilateral hilar regions appear normal.

Bilateral domes of diaphragm and costophrenic angles are normal.

Visualised soft tissues appear normal.

Right cervical rib is noted.

Impression: NO LUNG OPACITY

DR. H.K. ANAND

DR. SHWETHA S

DR. CHARUL

DR. APARNA

CONSULTANT RADIOLOGISTS

