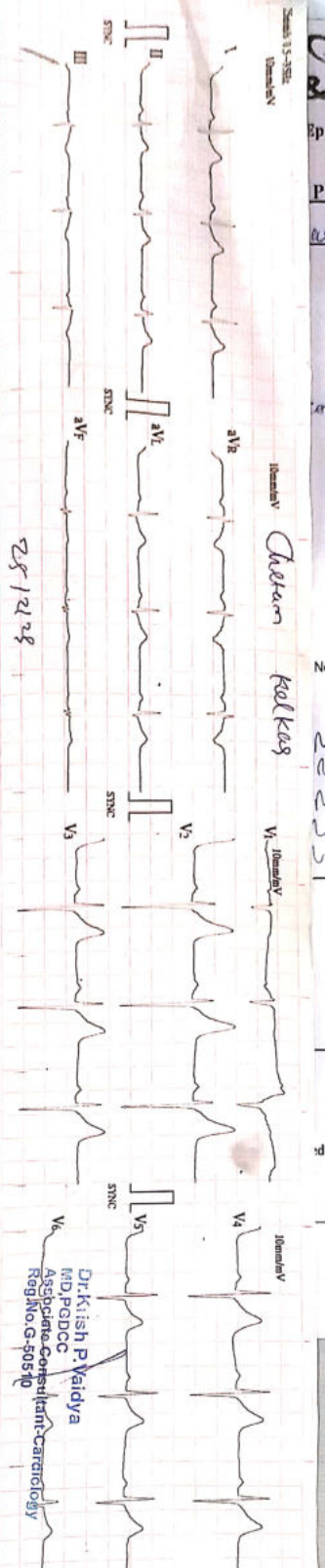


VI -006-REC: VI-010 2011-01-15 02:15



HR : 71 bpm
 R-R : 836 ms
 P-R : 163 ms
 QRS : 89 ms
 QT/QTc : 349/381 ms
 P/QRS/T : 31/14/8 °
 RV5/SVI : 0.730/0.540 mV
 RV5/SVL : 1.270 mV

ID : 0110
 Name :
 Sex :
 Age :

CONC
 Sinus BRV/Dbr
 Mild Left Axis Deviation

Dr. Kish P Vaidya
 MD, PDDCC
 Assigment Consultant-Cardiologist
 Reg.No.G-50510

iCure
 Mild Left Axis Deviation
 Uncont. Report Verified by:

28/1/21/28

Heart & General Clinic

Icure Heart & Diet Clinic, 402, Epsilon tower, opp Pasha bhai park, Race course, Vadodara

:: PERSONAL HEALTH REPORT ::

Chetan Kelkar		*DATE 25/2/23
		SR. NO. SEX. male AGE 42yrs HEIGHT 163cm WEIGHT 77kg

HISTORY

Present History : Tomalis met (ro) since 1yr
 Past Hlness History : Diabetes/Hypertension/Tuberculosis/Asthma/Epilepsy
 Past Occupational History : no
 Family History : Parents - Diabetic
 Personal History : no
 Addiction : No Tobacco/Gutkha/Smoking/Alcohol

GENERAL EXAMINATION

T.P.R. : B.P. : 122/80 mm Hg
 Pallor/Icterus/Cyanosis/Varicosity/Lymph Nodes/Thyroid/Oedema/NVE/Other :

SYSTEMIC EXAMINATION

R.S. : NAD
 C.V.S : NAD
 C.N.S : NAD
 A.S. : NAD
 Musculo-skelet System : NAD

E.N.T. Ex.	NAD	ACUITY OF VISION		RT EYE +1.75	LT EYE +1.75
		Without Glass	DISTANT	6/	6/
Dental Ex.	NAD		Near	6/	6/
		With Glass	DISTANT	6/ 6	6/ 6
Skin Ex.	NAD		Near	6/ 6	6/ 6
		Psychic Ex.	NAD	COLOUR BLINDNESS NAD	

REMARK

ADVICE

The Worker is FIT/UNFIT for the assigned job.





Dr. Krish P. Vaidya
 MD, PDCC
 Associate Consultant-Cardiology
 Reg. No. G-50510

DR. KRISH VAIDYA

MD G-50510, CIH

बैंक ऑफ बड़ौदा
Bank of Baroda

नाम **CHETAN KELKAR**
Name

कर्मचारी कूट क्र.
E.C. No **75221**

P. Banthia
आयुक्त अधिकारी
Issuing Authority

Chetkar
रजक के हस्ताक्षर
Signature of Holder

भारत सरकार
GOVERNMENT OF INDIA




चेतन केलकर
Chetan Kelkar
जन्म तिथि/ DOB: 10/02/1981
पुरुष / MALE

6725 1694 6591

आधार-आम आदमी का अधिकार



Chetkar



BARODA DIAGNOSTIC LABORATORY



* 2 7 3 1 4 *

Patient's name : Chetan Kelkar
Age/Sex : 42 Years/Male
Referred by : C/o. I Cure Heart & Diet Clinic
Sample From : LAB
UHID :

Reg. ID : icure-704-19
Accession : 27314
Reg. Date : 25/02/2023
Collection Time : 25/02/2023 16:10

COMPLETE BLOOD COUNT

Sample Type: EDTA

Test Name	Result	Units	Biological Reference Interval
<u>Blood Counts</u>			
Haemoglobin :	13.7	Gms%	13.5 - 18.0
Total R.B.C. :	4.19	mill/c.mm	4.7 - 6.0
Total W. B. C. :	6500	/cu mm	4000 - 10500
Platelet Count :	308000	/cu.mm	1,50,000 - 4,50,000
<u>Differential Count</u>			
Neutrophils :	66	%	40 - 70
Lymphocytes :	31	%	20 - 40
Eosinophils :	01	%	1 - 4
Monocytes :	02	%	2 - 6
Basophils :	00	%	0 - 01
<u>Blood Indices</u>			
P. C. V :	37.1	%	42 - 52
M. C. V. :	88.5	fl	78 - 100
M.C.H :	32.7	pg	27 - 31
M. C. H. C :	36.9	%	32 - 36
R.D.W :	13.6	%	11.5 - 14.0

E.S.R.(Westergren Method)

After one hour : **10** mm 1 - 7



Dr Harsh Pandya
(MD)
Consultant Pathologist
Reg. No.: G-32582

Dr. Priya Kriplani
(MD)
Consultant Pathologist
Reg. No.: G-46004

302, Trivia Complex, Natubhai Circle, Race Course, Vadodara. ☎: +91 88660 09950 / 74050 09950 ✉: bdl95950@gmail.com

Laboratory results serve as an aid to diagnosis & should be interpreted in relation to clinical findings. Please refer back to laboratory in case of any discrepancy.



Scanned with OKEN Scanner



BARODA DIAGNOSTIC LABORATORY



Patient's name : Chetan Kelkar
Age/Sex : 42 Years/Male
Referred by : C/o. I Cure Heart & Diet Clinic
Sample From : LAB
UHID :

Reg. ID : icure-704-19
Accession : 27314
Reg. Date : 25/02/2023
Collection Time : 25/02/2023 16:10

Sample Type: Serum

THYROID FUNCTION

Test Name	Result	Units	Biological Reference Interval
TOTAL T3 :	1.95	ng/ml	0.84 - 2.0
TOTAL T4 :	9.09	ug/dl	5.1 - 14.0
TSH :	3.01	mIU/L	0.25 - 5.0

Method : CLIA

RENAL FUNCTION TEST

Test Name	Result	Units	Biological Reference Interval
Urea :	18	mg/dl	10 - 50
Bun (Calculated) :	8.4	mg/dl	0 - 18
Creatinine :	0.99	mg/dl	0.4 - 1.5
Uricacid :	5.10	mg/dl	3.4 - 7.0
BUN CREAT RATIO :			10:1 - 20:1

Done on Fully automated biochemistry analyser - COBAS C 111

LAB

LAB USE ONLY (Entered by :OP1 Enter Date/Time:25/02/2023 4:39:00 PM) (Verify by :OP1 Verify Date/Time:25/02/2023 4:39:00 PM)



Dr Harsh Pandya
(MD)
Consultant Pathologist
Reg. No.: G-32582

Dr. Priya Kriplani
(MD)
Consultant Pathologist
Reg. No.: G-46004



302, Trivia Complex, Natubhal Circle, Race Course, Vadodara. ☎: +91 88660 09950 / 74050 09950 ✉: bdl95950@gmail.com

Laboratory results serve as an aid to diagnosis & should be interpreted in relation to clinical findings. Please refer back to laboratory in case of any discrepancy.



BARODA DIAGNOSTIC LABORATORY



* 2 7 3 1 4 *

Patient's name : Chetan Kelkar
Age/Sex : 42 Years/Male
Referred by : C/o. I Cure Heart & Diet Clinic
Sample From : LAB
UHID :

Reg. ID : icure-704-19
Accession : 27314
Reg. Date : 25/02/2023
Collection Time : 25/02/2023 16:10

Sample Type: Serum

PSA

Test Name	Result	Units	Biological Reference Interval
PSA :	2.05	ng/ml	0 - 4.5

Interpretation guide :

: PSA is a Glycoprotein found in prostate acinar cells,
Ref. range <4.5 ng/ml. increased with age < 6.5 ng/ml, if more than 70yrs.

* Use:

-Monitor response to therapy of ca. prostate.
-PSA of >100 ng/ml predicts bone metastasis with 73% positive predictive value.

* Increased in ->

-Prostate cancer.
-Prostatitis.
-Prostatic ischemia (Sometime too high level).
-Prostate massage.
-Needle biopsy/TUR.
-Indwelling catheter.
-Vigorous bicycle exercise.
-Radiation therapy.

Method : Electrochemiluminescence Immunoassay "ECLIA"



LAB USE ONLY (Entered by :OP1 Enter Date/Time:25/02/2023 4:38:00 PM) (Verify by :OP1 Verify Date/Time:25/02/2023 4:38:00 PM)



Dr Harsh Pandya
(MD)
Consultant Pathologist
Reg. No.: G-32582

Dr. Priya Kriplani
(MD)
Consultant Pathologist
Reg. No.: G-46004

302, Trivia Complex, Natubhai Circle, Race Course, Vadodara. ☎: +91 88660 09950 / 74050 09950 ✉: bdi95950@gmail.com

Laboratory results serve as an aid to diagnosis & should be interpreted in relation to clinical findings. Please refer back to laboratory in case of any discrepancy.



Scanned with OKEN Scanner



BARODA DIAGNOSTIC LABORATORY



* 2 7 3 1 4 *

Patient's name : Chetan Kelkar
Age/Sex : 42 Years/Male
Referred by : C/o. I Cure Heart & Diet Clinic
Sample From : LAB
UHID :

Reg. ID : icure-704-19
Accession : 27314
Reg. Date : 25/02/2023
Collection Time : 25/02/2023 16:10

Sample Type: Serum

LIVER FUNCTION TEST

Test Name	Result	Units	Biological Reference Interval
S.G.P.T (ALT) :	18	U/L	0 - 40
S.G.O.T (AST) :	21	U/L	0 - 37
ALK.PHOSPHATASE :	49	U/L	40 - 130
G.G.T :	14.9	U/L	8 - 78
<u>Bilirubin</u>			
Total :	0.40	mg/dl	0.2 - 1.0
Direct :	0.25	mg/dl	0 - 0.6
Indirect :	0.15	mg/dl	0 - 0.5
<u>Serum Proteins</u>			
Total Protein :	6.99	gms/dl	6.4 - 8.3
Albumin :	4.10	gms/dl	3.8 - 4.4
Globulins :	2.89	gms/dl	2.3 - 3.5
A/G Ratio :	1.42		0.9 - 2.9

Done on Fully automated biochemistry analyser - COBAS C 111



LAB

LAB USE ONLY (Entered by :OP1 Enter Date/Time:25/02/2023 4:39:00 PM) (Verify by :OP1 Verify Date/Time:25/02/2023 4:39:00 PM)



Dr Harsh Pandya
(MD)
Consultant Pathologist
Reg. No.: G-32582

Dr. Priya Kriplani
(MD)
Consultant Pathologist
Reg. No.: G-46004

302, Trivia Complex, Natubhai Circle, Race Course, Vadodara. ☎: +91 88660 09950 / 74050 09950 ✉: bdl95950@gmail.com

Laboratory results serve as an aid to diagnosis & should be interpreted in relation to clinical findings. Please refer back to laboratory in case of any discrepancy.



Scanned with OKEN Scanner



BARODA DIAGNOSTIC LABORATORY



* 2 7 3 1 3 *

Patient's name : Chetan Kelkar
Age/Sex : 42 Years/Male
Referred by : C/o. I Cure Heart & Diet Clinic
Sample From : LAB
UHID :

Reg. ID : icure-703-19
Accession : 27313
Reg. Date : 25/02/2023
Collection Time : 25/02/2023 16:06

HbA1C REPORT


Sample Type: EDTA

Test Name	Result	Units	Biological Reference Interval
HbA1C :	6.65	%	Excellent control: 4.2-6.2 Good Control : 6.3-7.2 Fair Control : 7.3-8.2 Poor Control : >8.3
Mean Blood Glucose levels : of last 03months	144	mg/dl	

NOTE

*As per the new 2009 update of American Diabetes Association regarding HbA1C & Mean Blood Glucose relationship.

This test is used to monitor diabetic patients compliance with the therapeutic regimen and long term blood glucose control. It's level is proportional to both the average blood glucose concentration and the life span of the red blood cells (RBC) in circulation. HbA1c values are free of day to day glucose fluctuations and are unaffected by exercise or recent food intake.



LAB

LAB USE ONLY (Entered by :NITI Enter Date/Time:25/02/2023 6:01:00 PM) (Verify by :NITI Verify Date/Time:25/02/2023 6:01:00 PM)

BARODA DIAGNOSTIC LABORATORY



Dr Harsh Pandya
(MD)
Consultant Pathologist
Reg. No.: G-32582

Dr. Priya Kriplani
(MD)
Consultant Pathologist
Reg. No.: G-46004

302, Trivia Complex, Natubhai Circle, Race Course, Vadodara. ☎: +91 88660 09950 / 74050 09950 ✉: bdi95950@gmail.com

Laboratory results serve as an aid to diagnosis & should be interpreted in relation to clinical findings. Please refer back to laboratory in case of any discrepancy.



Scanned with OKEN Scanner



BARODA DIAGNOSTIC LABORATORY



* 2 7 3 1 3 *

Patient's name : Chetan Kelkar
Age/Sex : 42 Years/Male
Referred by : C/o. I Cure Heart & Diet Clinic
Sample From : LAB
UHID :

Reg. ID : icure-703-19
Accession : 27313
Reg. Date : 25/02/2023
Collection Time : 25/02/2023 16:06

LIPID PROFILE

Sample Type: Serum

Test Name	Result	Units	Biological Reference Interval
Cholesterol :	208	mg/dl	0 - 200
Triglyceride :	180	mg/dL	0 - 150
HDL - Cholesterol :	48	mg/dL	35 - 65
LDL - Cholesterol :	124	mg/dL	0 - 130
VLDL - Cholesterol :	36	mg/dL	0 - 30
Total Cholesterol/HDL Ratio :	4.33		1 - 6
LDL / HDL Cholesterol Ratio :	2.58		0 - 3.5

Done on Fully automated biochemistry analyser - COBAS C 111



LAB

LAB USE ONLY (Entered by :NITI Enter Date/Time:25/02/2023 6:02:00 PM) (Verify by :NITI Verify Date/Time:25/02/2023 6:02:00 PM)



Dr Harsh Pandya
(MD)
Consultant Pathologist
Reg. No.: G-32582

Dr. Priya Kriplani
(MD)
Consultant Pathologist
Reg. No.: G-46004

302, Trivia Complex, Natubhai Circle, Race Course, Vadodara. ☎: +91 88660 09950 / 74050 09950 ✉: bd195950@gmail.com

Laboratory results serve as an aid to diagnosis & should be interpreted in relation to clinical findings. Please refer back to laboratory in case of any discrepancy.



Scanned with OKEN Scanner


Heart & General Clinic

iCure Heart& Diet Clinic, 402, Epsil on tower, opp Pasha bhai park, Race course, Vadodara

Name : CHETAN KELKAR
Ref By : ICURE HEART & DIET CLINIC

Age/Sex : 42 Yrs./M
Date : 26/02/2023
Report ID. : 5

HAEMOGRAM PROFILE

<u>TEST</u>	<u>RESULT</u>
Blood Group	: * A *
Rh Factor (Anti D.)	: * POSITIVE *

BIOCHEMISTRY

FASTING (FBS)

Blood Glucose : **120.0** mg/dL 70 - 110 mg/dL

POST-PRANDIAL

Blood Glucose : **180.0** mg/dL 80 - 140 mg/dL

Done By Fully Auto Analyzer MIURA, A-1004

END OF REPORT




Heart & General Clinic

iCure Heart& Diet Clinic, 402, Epsil on tower, opp Pasha bhai park, Race course, Vadodara

Name : CHETAN KELKAR
Ref By : ICURE HEART & DIET CLINIC

Age/Sex : 42 Yrs./M
Date : 26/02/2023
Report ID. : 5

EXAMINATION OF URINE

<u>TEST</u>	<u>RESULT</u>	<u>UNIT</u>
Sample	: FASTING	
<u>PHYSICAL EXAMINATION</u>		
Quantity	: 10	mL
Colour	: YELLOW	
Transperancy	: CLEAR	
Specific Gravity	: 1.003	
Reaction	: ACIDIC	
Deposits	: ABSENT	
<u>CHEMICAL EXAMINATION</u>		
Albumin	: NIL	
Sugar	: NIL	
Acetone	: ABSENT	
Bile Salts	: ABSENT	
Bile Pigments	: ABSENT	
Urobilinogen	: NORMAL : ~ < 1.0 mg/dL	
Occult Blood	: ABSENT	
Nitrate	: ABSENT	
<u>MICROSCOPIC EXAMINATION</u>		
Pus Cells	: 0-1 / hpf	
RBC	: NIL	
Epithelial Cells	: NIL	
Crystals	: NIL	
Amorphous Phosphate	: NIL	
Cast	: NIL	



END OF REPORT

 **iCure™**
Heart & General Clinic

2D Echocardiography & Color Doppler Report

iCure Hear care, 402, Epsilon tower, opp Pasha bhai park, Race course, Vadodara

Patient Name: Mr Chetan Kelkar

Date: 25 / 02 / 2023

Age Gender: male - 42 Years

M. Mode Study:

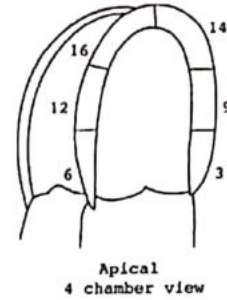
LA	35	IVS	09	PWD	09
AO	24	LVDs	23	LVDd	45

Doppler Study:

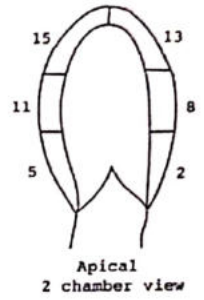
Mitral Valve	E: 0.98 A: 0.55
Aortic Valve	Normal
Tricuspid Valve	Normal
Pulmonary Valve	Normal

Conclusion:

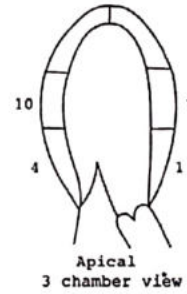
- **Normal LV Systolic function**
- **LVEF: 58 % ,No RWMA**
- **Cardiac Chambers: Normal**
- **Diastolic function: Normal**
- **TR: No PAH: No RVSP: 17mmhg**
- **No Ms , No MR**
- **Mild AR , No AS**
- **ASD/VSD/PDA/Co-A : No**
- **No Clots or vegetations found**
- **IVC: 11mm size with Normally collapsive**



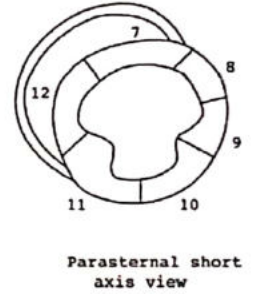
Apical
4 chamber view



Apical
2 chamber view



Apical
3 chamber view



Parasternal short
axis view



Dr. Krish P. Vaidya
MD, PGCC
Associate Consultant-Cardiology
Reg.No.G-50510

Note:

Normal 2D echo report does not rule out cardiac diseases
this report shall not be used for Medico legal purposes,
Clinical Correlation advisable.

Dr. Krish P Vaidya
Consultant Cardiologist, Diabetologis
& General Physician


Heart & General Clinic

NAME : Mr Chetan kelkar	AGE : 42Y/M	DATE : 25/02/2023
-------------------------	-------------	-------------------

ULTRASONOGRAPHY OF WHOLE ABDOMEN
(Screening Only)

Liver is normal in size and echotexture and shows normal parenchymal reflectivity. No focal lesion is seen. Hepatic veins appear normal. There is no evidence of any dilated intra hepatic biliary radicals.

Portal Vein appears normal in diameter.

Common Bile Duct is of normal diameter.

Gallbladder is physiologically distended with normal wall thickness. There is no evidence of gallstones. No evidence of peri-cholecystic fluid or probe tenderness.

Pancreas is normal in size and shows homogenous reflectivity. There is no evidence of any calcification or ductal dilatation.

Spleen is normal size and shows a homogenous echotexture. There is no evidence of any focal lesion.

Both Kidneys are normal in position and size. They show normal cortical reflectivity and cortico-medullary distinction. Right kidney measures 93x40mm. Left kidney measures 102x49mm. There is no evidence of renal calculi, hydronephrosis or mass seen.

Bladder is well distended and shows normal wall thickness. No evidence of intra-luminal mass or calculi.

Prostate gland is normal in size . it has smooth outlines and normal reflectivity

There is no evidence of ascites.

No evidence of any gross bowel mass seen.

No evidence of any aorto-caval or mesenteric root lymphadenopathy.

No mass or collection in right iliac fossa.

CONCLUSION: No sonographic abnormality is seen.



Mehul Prajapati

DR. MEHUL PRAJAPATI
CONSULTANT RADIOLOGIST


Heart & General Clinic

iCure Heart& Diet Clinic, 402, Epsil on tower, opp Pasha bhai park, Race course, Vadodara

NAME	CHETAN KELKAR	AGE/SEX	42Y/MALE
REF BY	I CURE HEART & DIET CLINIC	DATE	25/02/22

X-RAY CHEST PA VIEW

BOTH LUNGS FIELDS ARE NORMAL .

REMAINING LUNG FIELDS ARE NORMAL.

BOTH COSTOPHRENIC RECESS ARE CLEAR.

CARDIAC SIZE WITHIN NORMAL LIMITS.

MEDIASTINUM AND BONY THORACIC CAGE REVEAL NO ABNORMALITY.

IMPRESSION : NORMAL LUNGS HEART AND MEDIASTUINUM..



DR.HIMANI VIRAPARA
Regn. No: G.28771
M.D. [Radiodiagnosis]
(CONSULTANT RADIOLOGIST)

