



Aakriti Labs

3 Mahatma Gandhi Marg, Gandhi Nagar Mod
Tonk Road, Jaipur (Raj.) Ph.: 0141-2710661
www.aakritilabs.com
CIN NO.: U85195RJ2004PTC019563



Name : **Mr. NIRBHAY ROCHWANI**
Age/Gender: 30 Y/Male
Patient ID : 012203190017
BarcodeNo : 10040365
Referred By : Self

Registration No: 26822
Registered : 19/Mar/2022 09:06AM
Analysed : 20/Mar/2022 01:58PM
Reported : 20/Mar/2022 01:58PM
Panel : Medi Wheel (ArcoFemi
Healthcare Ltd)

DIGITAL X-RAY CHEST PA VIEW

Soft tissue shadow and bony cages are normal.

Trachea is central.

Bilateral lung field and both CP angle are clear.

Domes of diaphragm are normally placed.


Transverse diameter of heart appears with normal limits.

IMPRESSION:- NO OBVIOUS ABNORMALITY DETECTED.

*** End Of Report ***

wellness
partner




Dr. Neera Mehta
M.B.B.S., D.M.R.D.
RMCNO.005807/14853



Aakriti Labs

3 Mahatma Gandhi Marg, Gandhi Nagar Mod
Tonk Road, Jaipur (Raj.) Ph.: 0141-2710661
www.aakritilabs.com
CIN NO.: U85195RJ2004PTC019563

PATIENT NAME: MR NIRBHAY ROCHWANI	AGE & SEX: 30Y/M
REF. by: MEDIWHEEL	DATE: 19.03.2022

USG: WHOLE ABDOMEN (Male)

- LIVER** : Is normal in size, shape and echogenecity.
The IHBR and hepatic radicals are not dilated.
No evidence of focal echopoor/echorich lesion seen.
Portal vein diameter and common bile duct appear normal.
- GALL BLADDER** : Is normal in size, shape and echotexture. Walls are smooth and regular with normal thickness. There is no evidence of cholelithiasis.
- PANCREAS** : Is normal in size, shape and echotexture. Pancreatic duct is not dilated.
- SPLEEN** : Is normal in size, shape and echogenecity. Splenic hilum is not dilated.
- KIDNEYS** : Right Kidney:-Size: 100x50 mm, Left Kidney:-Size: 109x54 mm.
Bilateral Kidneys are normal in size, shape and echotexture,
corticomedullary differentiation is fair and ratio appears normal.
Pelvi calyceal system is normal. No evidence of hydronephrosis/ nephrolithiasis.
- URINARY BLADDER** : Bladder walls are smooth, regular and normal thickness.
No evidence of mass or stone in bladder lumen.
- PROSTATE**: Is normal in size, shape and echotexture,
measures: 34x29x22 mm, wt: 11 gms.
Its capsule is intact and no evidence of focal lesion.
- SPECIFIC** : No evidence of retroperitoneal mass or free fluid seen in peritoneal cavity.
: NO evidence of lymphadenopathy or mass lesion in retroperitoneum.
: Visualized bowel loop appear normal. Great vessels appear normal.

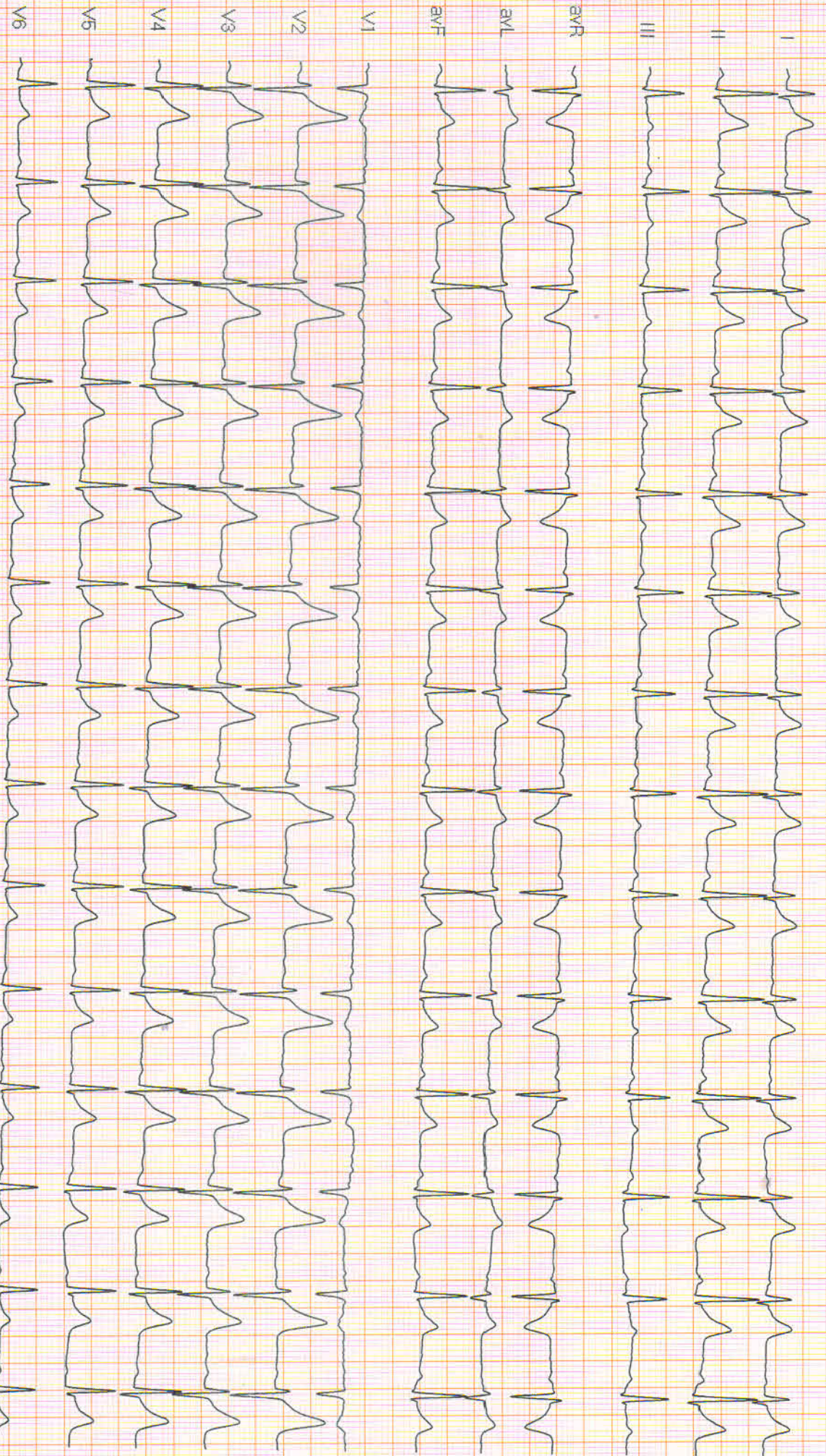
IMPRESSION:- NORMAL STUDY


DR NEERA MEHTA
MBBS, DMRD
RMCNO.005807/14853



3987MH NIRBHAY ROCHAWANI / 30 Yrs / M

Date: 19-Mar-2022 10:50:44 AM



75mm

Dr. NITIZ GOYAL

M.B.B.S., M.D.

RMC - 023319

(GEM21170525) Gemini A-DX by Allengers



	Time	Duration	Belt Speed (mph)	Elevation	METS	Rate	% THR Achieved	BP	RPP	PVC	Comments
Standing	00:03	0:01	01.1	00.0	01.0	82	43%	125/85	102	00	
	00:10	0:01	00.0	00.0	01.0	83	44%	125/85	103	00	
	00:20	0:01	00.0	00.0	01.0	114	60%	125/85	142	00	
Warm Up	00:26	0:04	01.7	10.0	01.1	078	41%	125/85	097	00	
ExStart	00:29	0:07	01.7	10.0	01.1	092	48%	125/85	115	00	
BRUCE Stage 1	03:29	3:00	01.7	10.0	04.7	122	64%	125/85	152	00	
BRUCE Stage 2	06:29	3:00	02.5	12.0	07.1	150	79%	125/85	187	00	
PeakEx	07:18	0:49	03.4	14.0	08.0	164	86%	125/85	205	00	
Recovery	08:17	1:00	00.0	00.0	01.1	114	60%	125/85	142	00	
Recovery	09:17	2:00	00.0	00.0	01.0	110	58%	158/90	173	00	
Recovery	10:17	3:00	00.0	00.0	01.0	104	55%	132/95	137	00	
Recovery	10:20				00.0	000	0%	---/---	000	00	

Findings :

Exercise Time : 06:50
 Max HR Attained : 164 bpm 86% of Target 190
 Max BP Attained : (Sys) 158/90, (Dis) 132/95
 Max Workload Attained : 8
 Test End Reasons : Test Complete, Heart Rate Achieved, Test Complete, Heart Rate Achieved

Report : FINAL IMPRESSION - TEST IS NEGATIVE FOR INDUCIBLE ISCHAEMIA

Dr. NITIZ GOYAL
 M.B.B.S., M.D.
 RMC - 0233319
 Doctor : DR. NITIZ GOYAL