

# CHIRAG

## IMAGING CENTRE

Opp. Dr. Manke Hospital, Lic Godhra-389001. Ph : 02672-252425



Name: SAKSHI 28 Years / Female Date: 06/01/2022

Ref By: SELF

### ULTRASOUND WHOLE ABDOMEN

**LIVER:** 153mm in mid axillary line and appears normal in size and in echo pattern.  
No focal intra-hepatic lesion detected. Intra-hepatic biliary radicals are not dilated.  
Portal vein appears normal in course and caliber.

**GALL BLADDER:** Appears echo free with normal wall thickness.  
Common Bile duct measures 5mm. No evidence of calculus or mass lesion seen within CBD.

**PANCREAS:** Appears normal in size and echo pattern.  
**SPLEEN:** 92mm along long axis and appears normal in size & echo pattern.


**KIDNEYS:**  
Right kidney measures 85 X 35 mm and appears normal in position, size and in outline.  
Corticomedullary differentiation maintained. No e/o focal mass lesion.  
No evidence of calculus or hydronephrosis seen.

Left kidney measures 89 X 31 mm and appears normal in position, size and in outline.  
Corticomedullary differentiation maintained. No e/o focal mass lesion.  
No evidence of calculus or hydronephrosis seen.

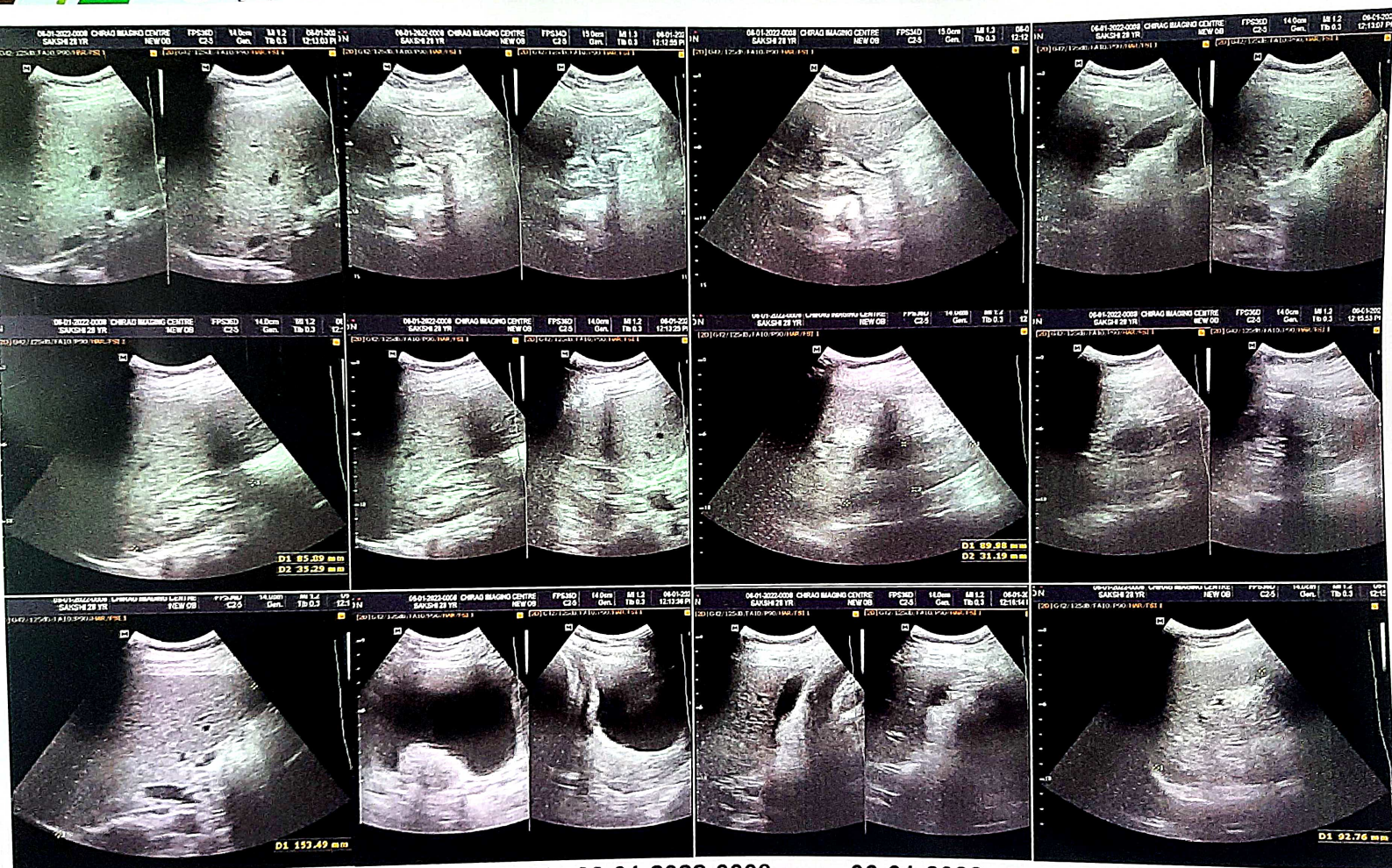
**URINARY BLADDER:** Appears distended with clear contents and wall thickness WNL.  
No evidence of calculus or mass lesion seen.

Intra uterine live fetus seen.  
No evidence of adnexal mass lesion seen on either side.  
No free fluid detected in pouch of Douglas and Morrison's pouch.  
Visualized parts of retro peritoneum do not reveal any lymphadenopathy.  
No evidence of abnormal dilatation or wall thickening of bowel loops seen.  
No evidence of collection or mass lesion seen in RIF

**IMPRESSION :** No significant abnormality seen in this study.

  
**Dr. Chirag J. Muniya**  
M.D., Radiology  
Reg No. 18177





SAKSHI 28 YR 06-01-2022-0008 06-01-2022

CHIRAG IMAGING CENTRE

Life begins with hope



સૂર્યોદય  
હોસ્પિટલ

આઇ.સી.યુ. - આઇ.સી.સી.યુ.

## ડૉ. નિશાંત જે. શેઠ

એમ.ડી. (મેડીસીન), એફ.સી.સી.એસ., સી.સી.ઇ.બી.ડી.એમ.  
કન્સલ્ટીંગ ફીઝીશીયન, કાર્ડિયોલોજિસ્ટ, ડાયાબીટીસ સ્પેશીયાલીસ્ટ  
રજી. નં. જી-૨૦૩૧૭

Name Sakshi

Sex Female

rel.

Age 28

Date 06/01/2022

### 2D

### M MODE

IVSd	1.0 cm
LVIDd	4.8 cm
LVPWd	1.0 cm
IVSs	1.1 cm
LVIDs	3.0 cm
LVPWs	1.2 cm
EDV(Teich)	108 ml
ESV(Teich)	35 ml
EF(Teich)	67 %
%FS	37 %
SV(Teich)	73 ml
Ao Diam	2.4 cm
LA Diam	3.1 cm
LA/Ao	1.27

### DOPPLER

MV E Vel	0.60 m/s
MV DecT	189 ms
MV Dec Slope	3.2 m/s <sup>2</sup>
MV A Vel	0.52 m/s
MV E/A Ratio	1.15
AV Vmax	0.86 m/s
AV maxPG	2.96 mmHg
PV Vmax	0.95 m/s
PV maxPG	3.59 mmHg
TR Vmax	1.73 m/s
TR maxPG	11.97 mmHg

### Comments

POOR ECHO WINDOW.  
NORMAL SYSTOLIC FUNCTION. EF=67%  
NO RWMA.  
NO DIASTOLIC DYSFUNCTION.  
TRIVIAL MR,TR.  
ALL CARDIAC CHAMBERS AND VALVES ARE NORMAL.  
NO CLOT/VEGETATION/PERICARDIAL EFFUSION.

SURYODAY HOSPITAL  
Dr. Nishant J. Sheth  
M.D. Medicine, FCCS, CCEBDM  
Reg. No. G - 20317 GODHRA

દિવજયોત એમ્બર્સ, પહેલો માળ, સેન્ટ્રલ બેન્ક ઓફ ઇન્ડિયાની બાજુમાં, ચર્ચની સામે, ગોધરા ૩૮૬૦૦૧, ડિ. પંચમહાલ, ગુજરાત  
ફોન: ૦૨૬૭૨-૨૫૨૬૩૬ Email: suryodayhospitals@gmail.com

સમય : સોમ થી શનિ સવારે ૯.૦૦ થી બપોરે ૧.૦૦, સાંજે ૪.૦૦ થી ૭.૦૦ રવિવારે રજા રહેશે.

દવા ડોક્ટરને બતાવીને વાપરવી.








06-01-2022 12:52:46  
ID: 1700

CARDIART

Female      Years



HR : 96 bpm  
P : 80 ms  
PR : 104 ms  
QRS : 84 ms  
QT/QTc : 340/430 ms  
P/QRS/T : 26/31/-7 °  
RV5/SV1 : 0.521/0.896 mV

Diagnosis Information:  
Sinus Rhythm  
Short PR Interval  
Poor R Wave Progression(V3,V4)  
Biphasic T Wave(V2)  
Slight ST Depression(V2)

Sukesh  
IF

Report Confirmed by:

