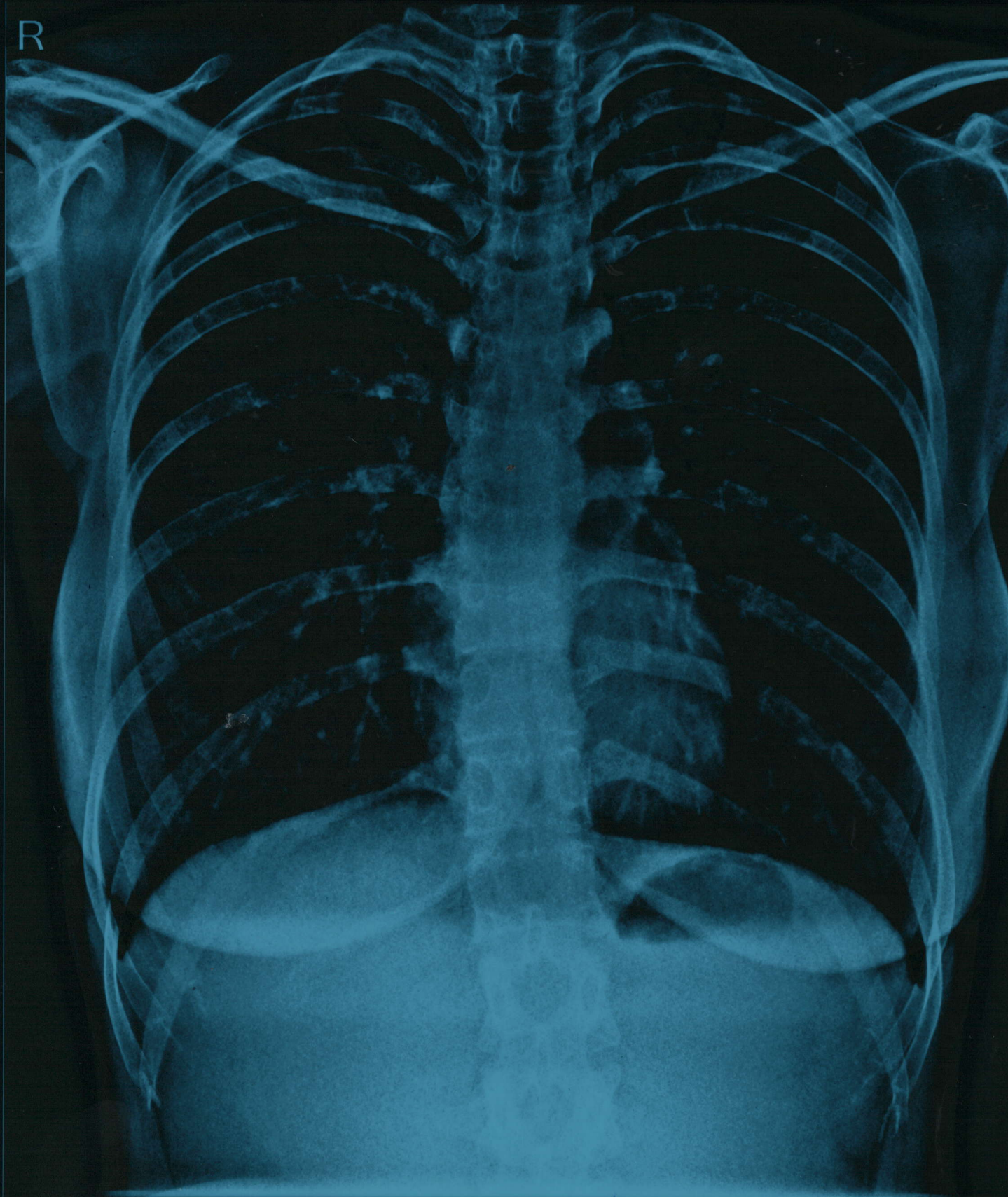
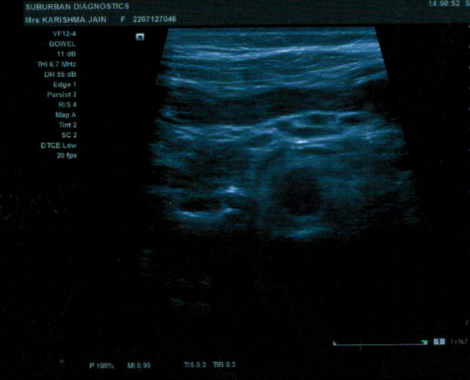
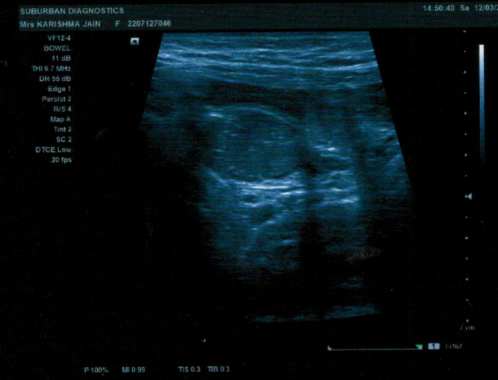
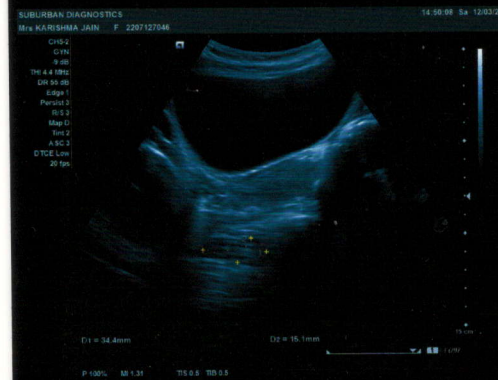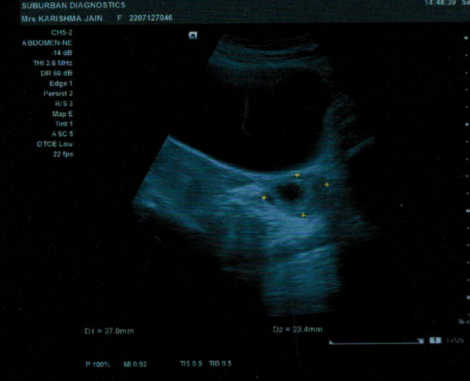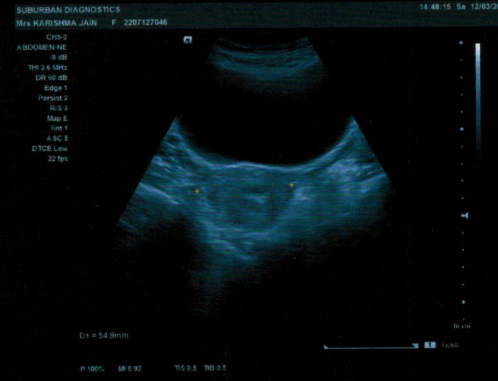
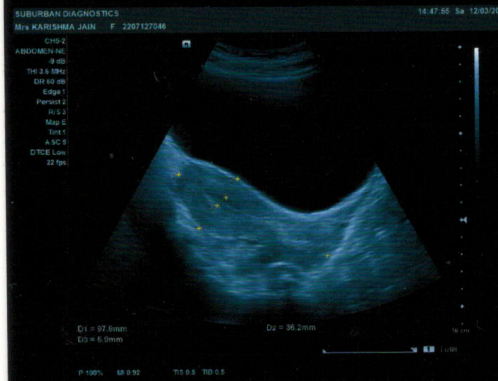
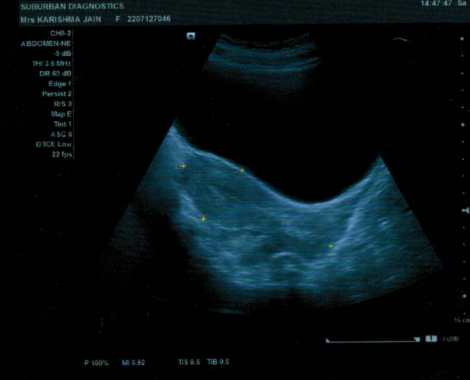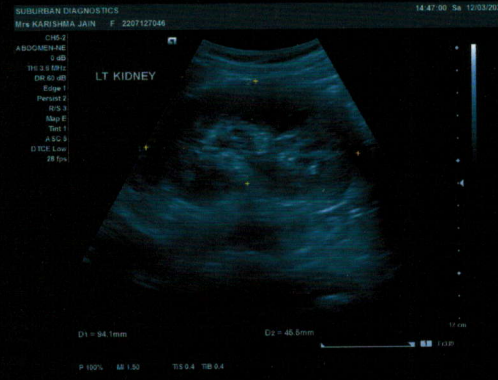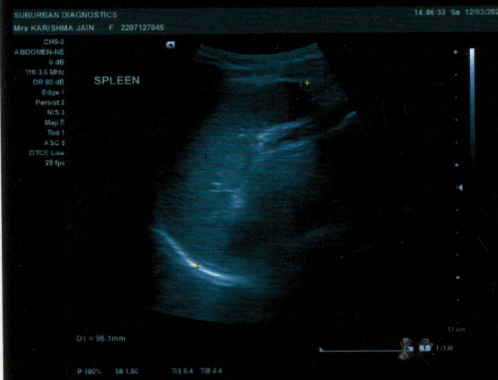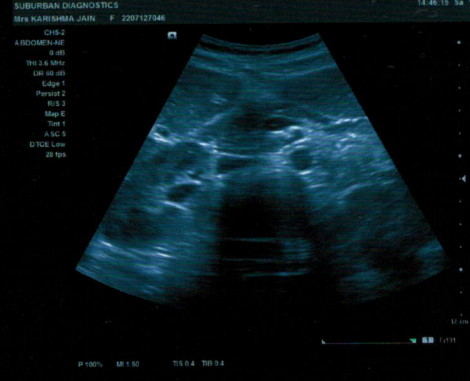
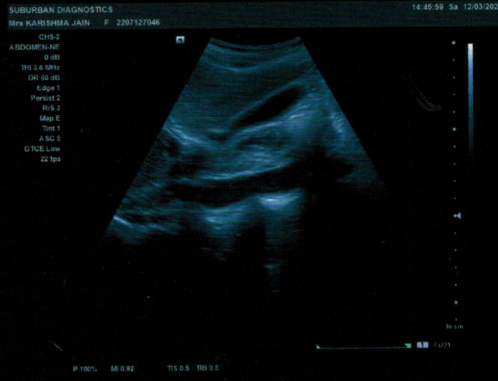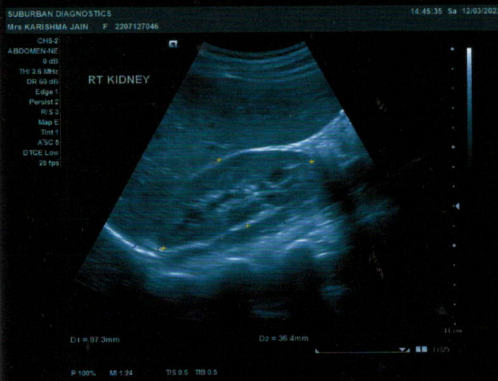


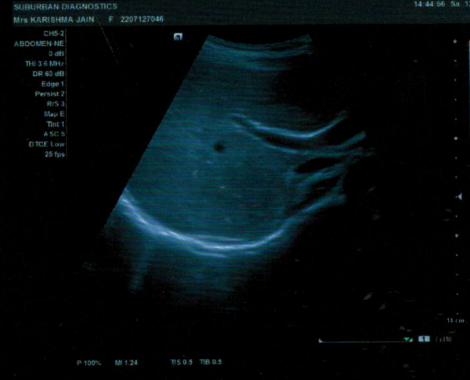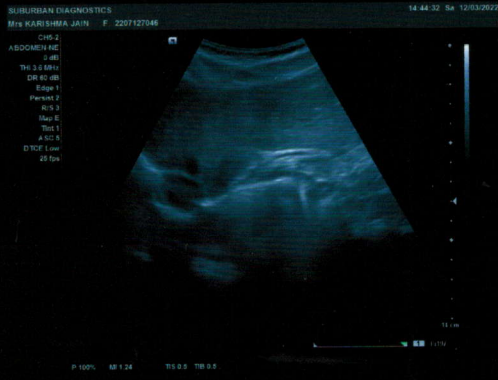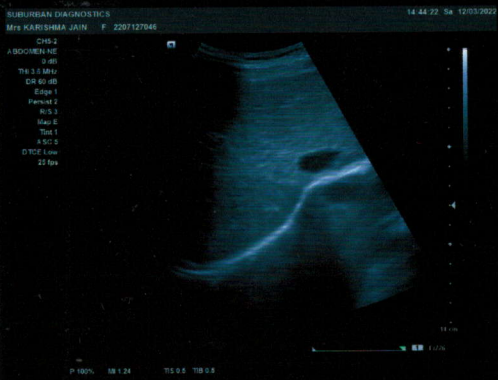R



Mrs KARISHMA JAIN F 31 YRS 2207127046 CHEST PA 3/12/2022  
SUBURBAN DIAGNOSTICS PIMPLE SAUDAGAR



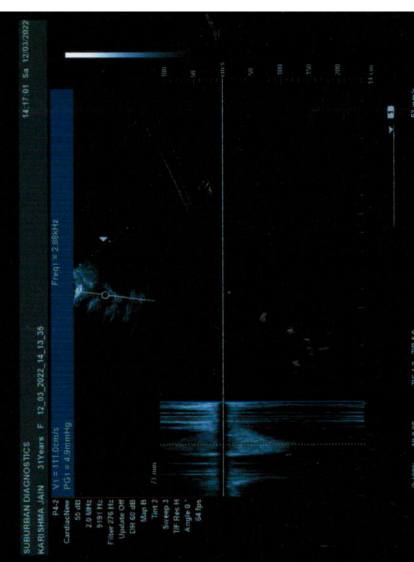
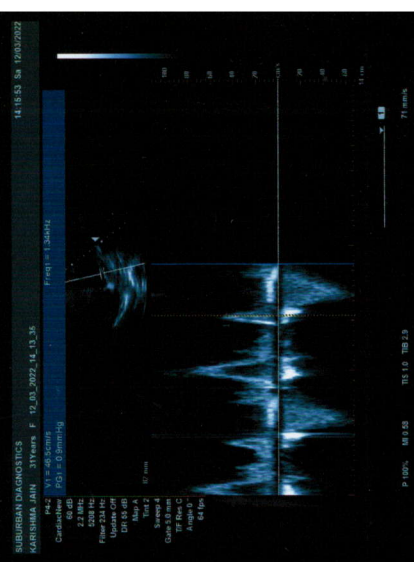
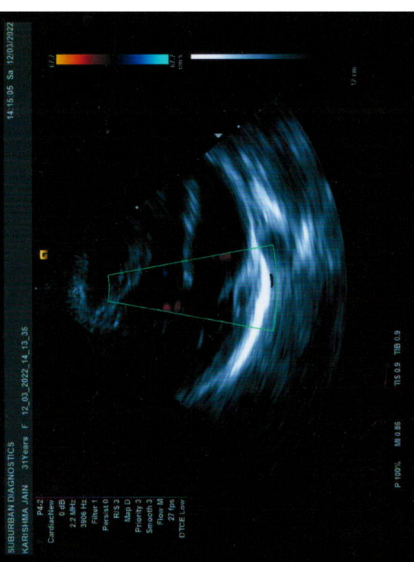
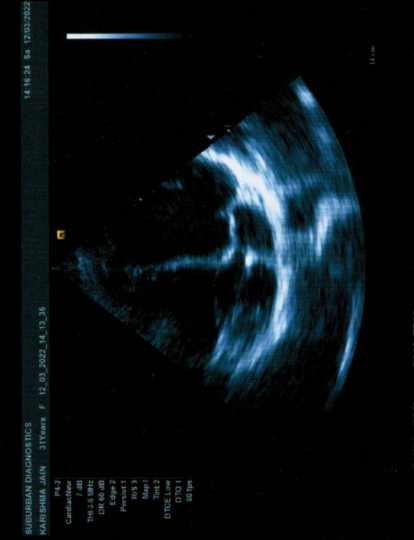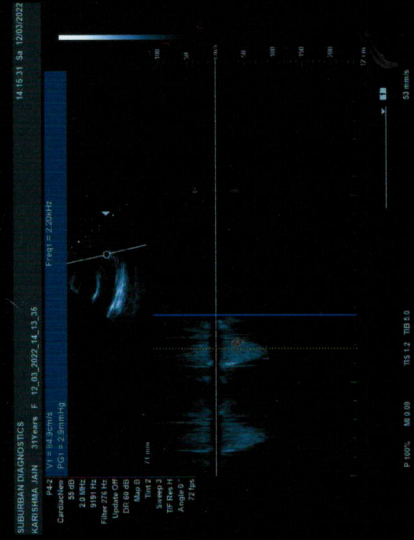
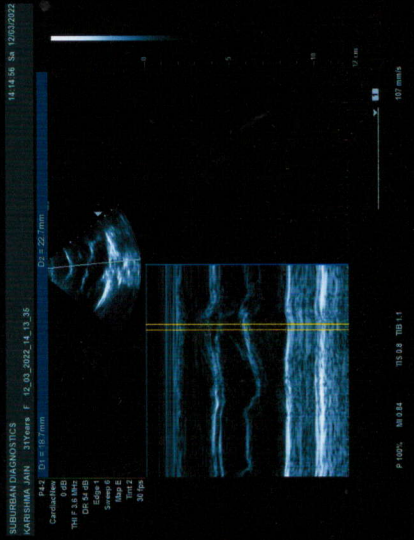
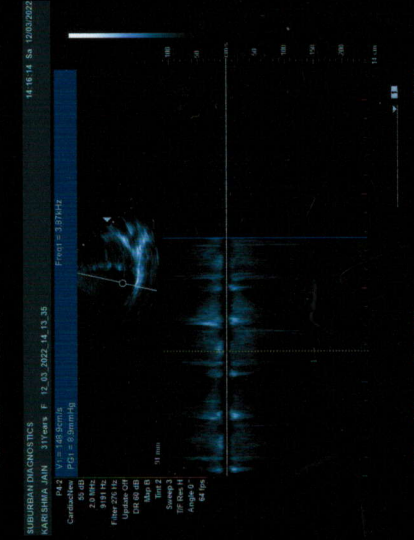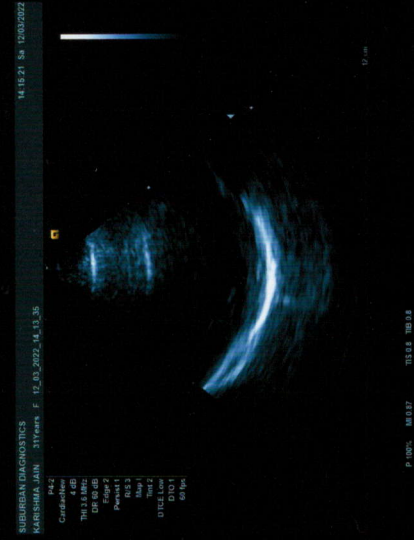
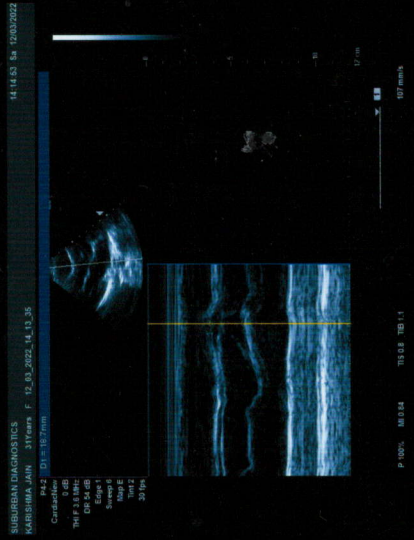
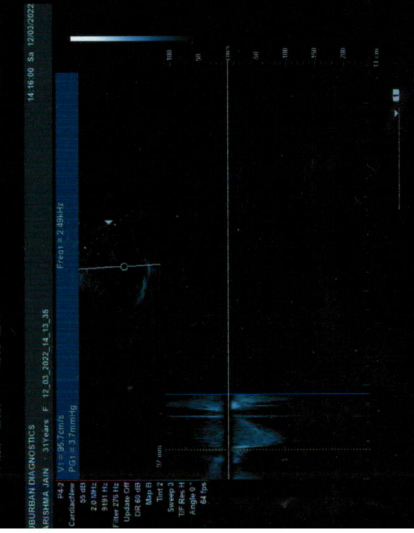
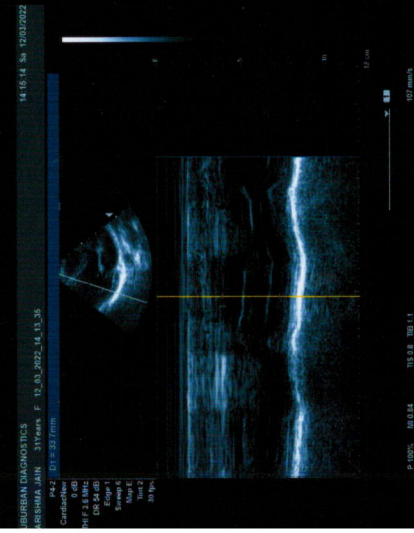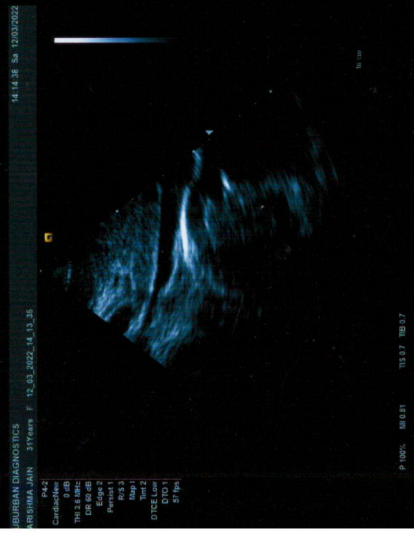




# SUBURBAN DIAGNOSTIC CENTRE

Name : KARISHMA JAIN 031Y / F

12 Mar 2022 Study : Cardiac





Karishma Jain.  
2 Decho.  
DAP  
Gynae.

PHY2.

**History and Complaints:**

NIL

**EXAMINATION FINDINGS:**

Height (cms):	162	Weight (kg):	47	BMI
Temp (0c):	Afebrile	Skin:	Normal	GMA
Blood Pressure (mm/hg):	110/80	Nails:	Healthy	
Pulse:	82	Lymph Node:	Not Palpable	

**Systems**

Cardiovascular: S1,S2 Normal No Murmurs  
Respiratory: Air Entry Bilaterally Equal  
Genitourinary: Normal  
GI System: Soft non tender No Organomegaly  
CNS: Normal

**IMPRESSION:**

FIT  
All reports normal.

**ADVICE:**

- NIL -

**CHIEF COMPLAINTS:**

- 1) Hypertension:
- 2) IHD:
- 3) Arrhythmia:
- 4) Diabetes Mellitus :
- 5) Tuberculosis :
- 6) Asthama:



8)	Thyroid/ Endocrine disorders :	} NIL	
9)	Nervous disorders :		
10)	GI system :		
11)	Genital urinary disorder :		
12)	Rheumatic joint diseases or symptoms :		
13)	Blood disease or disorder :		
14)	Cancer/lump growth/cyst :		
15)	Congenital disease :		
16)	Surgeries : <i>USCG</i>		
<b>PERSONAL HISTORY:</b>			
1)	Alcohol		} info
2)	Smoking		
3)	Diet		} yes
4)	Medication		} NIL

*Krutika Ingle*

Dr. KRUTIKA INGLE

MBBS, D.DM, PG in Diabetology (USA)  
MMC Regd - 2012 103018

**2D ECHO / COLOUR DOPPLER**

NAME : Mrs KARISHMA JAIN  
REF BY: ARCOFEMI HEALTHCARE  
CID NO : 220712870

Age: 31Y/FEMALE  
DATE :12.03.2022  
REG LOC: PIMPLE SAUDAGAR PUNE

**M - Mode values**

**Doppler Values**

AORTIC ROOT (mm)	18	PULMONARY VEL (m/sec)	0.8
LEFT ATRIUM (mm)	22	PG (mmHg)	3
RV (mm)	26	AORTIC VEL (m/sec)	0.9
IVS - D (mm)	11	PG (mmHg)	3
LVID - D (mm)	34	MITRAL E VEL (m/sec)	0.7
LVID - S (mm)	18	A VEL (m/sec)	0.4
LVPW - D (mm)	11	TRICUSPID VEL. (m/sec)	1.5
EJECTION FRACTION (%)	60	PG (mmHg)	15

**OBSERVATION:**

Mitral valve prolapse.  
Rest other cardiac valves are structurally normal.  
All four cardiac chambers normal in dimensions.  
Normal left ventricle size with Good ventricle systolic function .(LVEF-65%)  
No Regional wall motion abnormality.  
Left atrium, Right atrium & Right ventricle are normal in size.  
No pulmonary artery hypertension. RVSP = 25 mmHg.  
Interatrial septum & Interventricular septum are intact.  
No clot/vegetation /pericardial effusion.  
Doppler study revealed mild mitral regurgitation , mild tricuspid regurgitation.  
IVC 1.5 cm, more than 50% pulsatile.  
Left sided aortic arch, No coarctation of aorta.  
No diastolic dysfunction.

**CONCLUSION:**

**Normal left ventricle size with Good ventricle systolic function .(LVEF-65%)  
No pulmonary artery hypertension. RVSP = 25 mmHg.  
Mitral valve prolapse.**

-----End of Report-----

**Dr. Sonam Shah**  
MBBS MD DM Cardiology  
Interventional Cardiologist  
MMC 2010 / 06 / 2218

**DR SONAM SHAH**  
MD DM CARDIOLOGY





**CID** : 2207127046  
**Name** : Mrs KARISHMA JAIN  
**Age / Sex** : 31 Years/Female  
**Ref. Dr** : **Reg. Date** : 12-Mar-2022 / 14:43  
**Reg. Location** : Pimple Saudagar, Pune Main Centre **Reported** : 12-Mar-2022 / 14:48

### USG WHOLE ABDOMEN

**Liver-** Normal in size, shape and echo pattern. No focal lesion. Intrahepatic biliary and portal radicals appear normal. Visualised portion of CBD appears normal in calibre. Portal vein appears normal.

**Gall bladder-** partially distended with normal wall thickness. No calculus or mass lesion is visualized. No pericholecystic collection.

**Pancreas-** Head and body are visualized and appear normal in size, shape and echo pattern. No focal lesion seen. No peripancreatic collection noted.

**Spleen** – Appears normal in size (9.5cm), Shape & echo pattern. No focal lesion seen.

**Kidneys-** Right kidney - 8.7 x 3.6 cm, Left kidney - 9.4 x 4.5 cm, Both kidneys appear normal in size, shape, position & echo pattern with maintained cortico-medullary differentiation. Tiny papillary concretions are noted in both the kidneys. No hydronephrosis, hydroureter or calculus noted.

**Urinary bladder-** Is distended & shows normal wall thickness. No calculus or mass lesion is noted.

**Uterus-** measures 9.5 x 3.6 x 5.4 cm; appears normal in size, shape and myometrial echopattern. No obvious focal lesion. ET: 6.9 mm

**Ovaries:** Left ovary- 3.7 x 2.3 cm Right ovary- 3.4 x 1.5 cm normal in size and appearance. No focal lesion.

No free fluid in abdomen and pelvis.

Visualized bowel loops appear normal and show normal peristalsis. No evidence of enlarged lymph nodes.

### CONCLUSION:

**No significant sonological abnormality detected.**

*Advice – clinical correlation and further evaluation if clinically indicated*

-----End of Report-----

This report is prepared and physically checked by DR SATYAJEET before dispatch.

**Dr. SATYAJEET S. GHODAKE**  
MBBS, MD, DNB, MNAMS.  
Regd. No. 2013/05/1417  
Consultant Radiologist

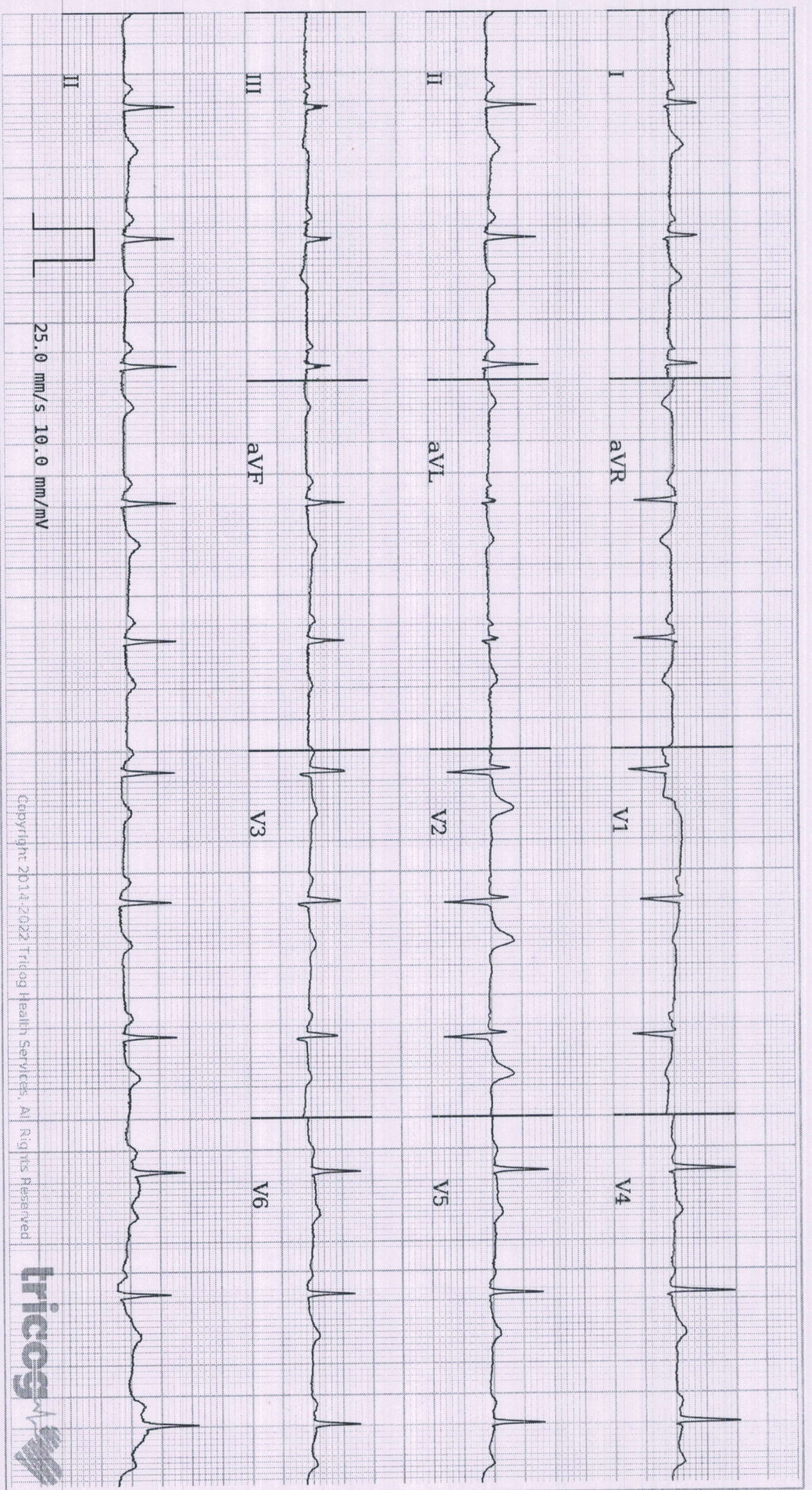
Click here to view images <http://202.143.96.162/Suburban/Viewer?ViewerType=3&AccessionNo=2022031210091919>



Patient Name: **KARISHMA JAIN**

Date and Time: **12th Mar 22 11:59 AM**

Patient ID: **2207127046**



25.0 mm/s 10.0 mm/mV

Copyright 2014-2023 Tricog Health Services, All Rights Reserved



Age **31** **5** **9**  
 years months days

Gender **Female**

Heart Rate **70bpm**

**Patient Vitals**

BP: **110/80 mmHg**

Weight: **47 kg**

Height: **162 cm**

Pulse: **82 bpm**

SpO2: **NA**

Resp: **NA**

Others: \_\_\_\_\_

**Measurements**

QSRD: **68ms**

QT: **390ms**

QTc: **421ms**

PR: **140ms**

P-R-T: **59° 57° 20°**

REPORTED BY

*[Signature]*

Dr. Krutika Ingle

MBBS, DDM, PG in Diabetology (USA)

2012103018

ECG Within Normal Limits: Sinus Rhythm, Normal Axis. Please correlate clinically.

Disclaimer: 1) Analysis in this report is based on ECG alone and should be used as an adjunct to clinical history, symptoms, and results of other invasive and non-invasive tests and must be interpreted by a qualified physician. 2) Patient vitals are as entered by the clinician and not derived from the ECG.



REGN DATE : 12-3-22

AGE / SEX: 31 / F

NAME : Karishma Jain

CID :

**GYNAEC CHECK-UP**

History

MH - Past  
Present

Obs. History -

Prev Illness -

Prev Op -

Drugs -

Breasts:

R -

L -

PA -

PS -

PV -

Impression -

LMP - 1/03/2022

4/30, Regular.

}  
}

MIL

LSCS - 2020.

Unscarred.

}  
}

MAD

- NIL

*Krutika Ingle*

Dr. KRUTIKA INGLE

MBBS, D.DM, PG in Diabetology (USA)  
MMC Regd - 2012 103018



**CID** : 2207128720  
**Name** : Mrs KARISHMA JAIN  
**Age / Sex** : 31 Years/F  
**Ref. Dr** :  
**Reg. Location** : Pimple Saudagar, Pune Main Centre

**Reg. Date** : 12-Mar-2022 / 13:13  
**Reported** : 12-Mar-2022 / 17:09

Use a QR Code Scanner  
Application To Scan the Code

### X-RAY CHEST PA VIEW

Patient is minimally rotated.  
Trachea is central.  
Slightly prominent bronchovascular markings are noted bilaterally.  
Visualized bilateral lung fields otherwise appear grossly normal.  
Both hila appear normal.  
Cardio-aortic silhouette has grossly normal appearance for age.  
Diaphragmatic domes have normal contours and positions.  
Bilateral costophrenic and cardiophrenic angles appear normal.  
Visualized bony thorax and soft-tissues are grossly normal for age.

#### **IMPRESSION :**

No other significant abnormality detected.

*Advice - Clinical correlation and further evaluation if clinically indicated.*

*Ghoda*

**Dr. SATYAJEET S. GHODAKE**  
MBBS, MD, DNB, MNAMS.  
Regd. No. 2013/05/1417  
Consultant Radiologist

*investigations have their own limitations. Solitary radiological investigation never leads to a final diagnosis. They should be always correlated with clinical and pathological examinations.*

**This report is prepared and physically checked by DR SATYAJEET before dispatch.**

**Click here to view images <<ImageLink>>**



SHREYAS DIAGNOSTICS LTD.  
Hotel, Pimple

SUBURBAN  
"Fortuna" Ground  
Garden Chowk,  
Hotel, Pimple



**Bank of Baroda**  
Name: Karishma Jain  
E.C.No.: 177785

*Karishma Jain*  
સચિવાલય સંચાલક

**Bank of Baroda**  
સચિવાલય સંચાલક

*Karishma*