

17
209

Dr. Vandana G. Powar M.B.B.S., D.C.P.
Consultant Pathologist



PARTH
PATHOLOGY LABORATORY
(Computerised)

LAB - Shop No. 7, "Diwan Towers" Mangalwar Peth, Near Mirajkar Tikti, Opp. Nutan Marathi High School, Kolhapur. Mob. 9158529408, 9422047480, 9921285167

DATE – 31/03/2023

PATIENT NAME- Deepali Pavane

AGE – 33 Y/FEMALE

HEIGHT – 152 cm


WEIGHT – 60 kg

BLOOD PRESSURE – 130 /68 mmHg

PULSES – 84 / Min

FIT TO PERFORM ALL DUTIES

Dr. Vandana G. Powar
M.B.B.S., D.C.P.
Reg. No. 68137



All Biochemistry Tests Done By Computerised Auto Analyser

HAEMATOLOGY | CLINICAL PATHOLOGY | BIOCHEMISTRY | SEROLOGY | MICROBIOLOGY | HISTOPATHOLOGY

24 Hours Emergency Service

Home Service Available

Dr

भारत सरकार
Government of India

भारत

भारत

Deepali Raghunath Pavane
जन्म तारीख / DOB: 07/07/1988
महिला / Female

3293 1408 1482

मेरा आधार, मेरी पहचान

Dr. Vandana G. Powar
H.M.B.S., D.C.P.
Reg. No. 68137



LAB - Shop No. 7, "Diwan Towers" Mangalwar Peth, Near Mirajkar Tikti, Opp. Nutan Marathi High School, Kolhapur. Mob. 9158529408, 9422047480, 9921285167

NAME : MRS. DEEPALI PAVANE

DATE : 04/04/2023 PT.NO. : 204 04042

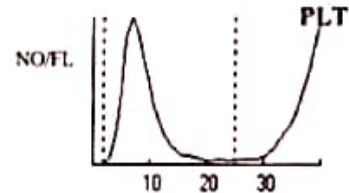
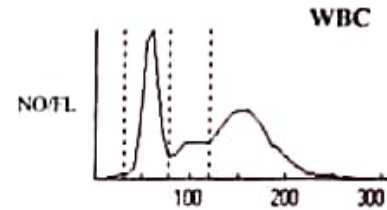
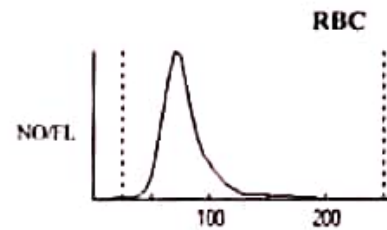
REF BY : Dr. MEDIWHEEL LIFE INS

AGE : 33. Yrs. SEX : F

HAEMOGRAM WITH INDICES

Test	Result	Units	Normal Range
Haemoglobin	- 10.7	g/dl	12-16
RBC Count	- 4.55	millions / cu-mm	4.5 - 6.5
PCV	- 40.2	%	40 - 54
MCV	- 88.4	fL	80 - 96
MCH	- 23.5	Pg	27 - 33
MCHC	- 26.6	gm/dl	33 - 36
RDW CV	- 14.4	%	11.0 - 14.5
WBC Count	- 6800	/cumm	4000 - 11000
Neutrophils	- 61	%	55 - 75
Lymphocytes	- 34	%	20 - 50
Eosinophils	- 03	%	1 - 6
Monocytes	- 02	%	2-10
Basophils	- 00	%	0 - 1
Platelet Count	- 268000	/ul	150000 - 450000
MPV	- 7.9	fL	7.4 - 10.4
PDW	- 8.9	%	8-12
P-LCR	- 10.7	%	15-35
E.S.R. (By Wintrobe Method)	- 09	mm at 1hr	0-15
RBC Morphology	- Normochromic, Normocytic.		
WBC Morphology	- Within Normal Limits		
Platelets	- Adequate		
* Blood group	- 'O' Rh Negative		

Histogram



Dr. Vandana G. Powar
M.B.B.S., D.C.P.
PATHOLOGIST
DR. VANDANA POWAR
M.B.B.S., D.C.P.

All Biochemistry Tests Done By Computerised Auto Analyser

HAEMATOLOGY | CLINICAL PATHOLOGY | BIOCHEMISTRY | SEROLOGY | MICROBIOLOGY | HISTOPATHOLOGY

24 Hours Emergency Service

Home Service Available



LAB - Shop No. 7, "Diwan Towers" Mangalwar Peth, Near Mirajkar Tikli, Opp. Nutan Marathi High School, Kolhapur. Mob. 9158529408, 9422047480, 9921285167

PT.NAME : MRS. DEEPALI PAVANE
REF. BY : DR. MEDIWHEEL LIFE INS

DATE : 04/04/2023
AGE : 33 Yrs. SEX : F
PT.NO. : 204 040423

BIOCHEMISTRY TEST REPORT

			<u>Normal Range</u>
Fasting Plasma Glucose	: 86.4	mg/dl	60-110 mg/dl
2 Hrs. Plasma Glucose	: 101.2	mg/dl	90-140 mg/dl
S. Creatinine	: 0.8	mg/dl	0.6 - 1.4 mg/dl
Blood Urea	: 26.5	mg/dl	12-42 mg/dl
Blood Urea Nitrogen	: 12.38	mg/dl	5 - 21 mg/dl
S. Uric acid	: 3.9	mg/dl	2.6 -6.0 mg/dl
CHOLESTEROL	: 157.9	mg/dl	0-250 mg/dl
HDL Cholesterol	: 33.2	mg/dl	30 - 70 mg/dl
S. Triglycerides	: 80.6	mg/dl	0-170 mg/dl
LDL Cholesterol	: 108.6	mg/dl	60 - 150 mg/dl
TC/HDLC Ratio	: 4.8		0 - 5
LDLC/HDLC Ratio	: 3.3		2.5 - 3.5

Dr. Vandana G. Powar
M.B.B.S., D.C.P.
PATHOLOGIST
DR. VANDANA G. POWAR
M.B.B.S., D.C.P.

All Biochemistry Tests Done By Computerised Auto Analyser

HAEMATOLOGY | CLINICAL PATHOLOGY | BIOCHEMISTRY | SEROLOGY | MICROBIOLOGY | HISTOPATHOLOGY

24 Hours Emergency Service

Home Service Available



LAB - Shop No. 7, "Diwan Towers" Mangalwar Peth, Near Mirajkar Tikli, Opp. Nutan Marathi
High School, Kolhapur. Mob. 9158529408, 9422047480, 9921285167

PT.NAME : MRS. DEEPALI PAVANE

DATE : 04/04/2023

REF. BY : DR. MEDIWHEEL LIFE INS

AGE : 33 Yrs. SEX : F

PT.NO. : 204 040423

BIOCHEMISTRY TEST REPORT

			<u>Normal Range</u>
S. Bilirubin (Total)	: 0.27	mg/dl	0 - 1.0 mg/dl
S. Bilirubin (Direct)	: 0.12	mg/dl	0 - 0.25 mg/dl
S. Bilirubin (Indirect)	: 0.15	mg/dl	0 - 0.75 mg/dl
S.G.O.T	: 23.9	IU/L	0 - 42 IU/L
S.G.P.T	: 18.3	IU/L	0 - 42 IU/L
S. Alkaline Phosphatase	: 97.9	IU/L	37 - 147 IU/L
Total Proteins	: 7.9	g/dl	6.6 - 8.3 g/dl
S. Albumin	: 4.8	g/dl	3.5 - 5.0 g/dl
S. Globulin	: 3.1	g/dl	1.5 - 3 g/dl
A/G Ratio	: 1.5 : 1		0.90 - 2.00

Dr. Vandana G. Powar
M.B.B.S., D.C.P.

Reg. No. 68137

PATHOLOGIST

DR. VANDANA POWAR
M.B.B.S., D.C.P.

All Biochemistry Tests Done By Computerised Auto Analyser

HAEMATOLOGY | CLINICAL PATHOLOGY | BIOCHEMISTRY | SEROLOGY | MICROBIOLOGY | HISTOPATHOLOGY

24 Hours Emergency Service

Home Service Available

Dr. Vandana G. Powar M.B.B.S., D.C.P.
Consultant Pathologist



PARTH
PATHOLOGY LABORATORY
(Computerised)

LAB - Shop No. 7, "Diwan Towers" Mangalwar Peth, Near Mirajkar Tikli, Opp. Nutan Marathi
High School, Kolhapur. Mob. 9158529408, 9422047480, 9921285167

PT.NAME : MRS. DEEPALI PAVANE
REF. BY : DR. MEDIWHEEL LIFE INS

DATE : 04/04/2023
AGE : 33 Yrs. SEX : F
PT.NO. : 204 040423

REPORT ON % GLYCOHAEMOGLOBIN OF BLOOD

% Glycohaemoglobin of blood : 5.0 %
Estimated mean blood glucose : 97.5 mg/dl

(Reference For Guideline)

- < 6.0 - Normal
- 6.0 - 7.0 % - Good Control
- 7.0 - 8.0 % - Fair Control
- 8.0-10.0% - Unsatisfactory control
- >10.0% - Poor control

Dr. Vandana G. Powar
M.B.B.S., D.C.P.
Reg. No. 60137

PATHOLOGIST

DR. VANDANA POWAR
M.B.B.S., D.C.P.

All Biochemistry Tests Done By Computerised Auto Analyser

HAEMATOLOGY | CLINICAL PATHOLOGY | BIOCHEMISTRY | SEROLOGY | MICROBIOLOGY | HISTOPATHOLOGY

24 Hours Emergency Service

Home Service Available

Dr. Vandana G. Powar M.B.B.S., D.C.P.
Consultant Pathologist



PARTH
PATHOLOGY LABORATORY
(Computerised)

LAB - Shop No. 7, "Diwan Towers" Mangalwar Peth, Near Mirajkar Tikti, Opp. Nutan Marathi High School, Kolhapur. Mob. 9158529408, 9422047480, 9921285167

PT.NAME : MRS. DEEPALI PAVANE
REF. BY : DR. MEDIWHEEL LIFE INS

DATE : 04/04/2023
AGE : 33 Yrs. SEX : F
PT.NO. : 204 040423

EXAMINATION OF URINE

Normal Range

PHYSICAL EXAMINATION

Quantity : 05 ml
Colour : Pale Yellow
Appearance : Clear
Deposit : Absent
Reaction (pH) : Acidic
Specific Gravity : 1.024

CHEMICAL EXAMINATION

Proteins : Absent
Glucose : Absent
Ketone Bodies : --
Bile Salts : Absent Absent
Bile Pigments : Absent Absent
Urobilinogen : --
Occult Blood : Absent

MICROSCOPIC EXAMINATION

Epithelial Cells : 1 - 2 /hpf
Pus Cells : 2 - 3 /hpf
Red Blood Cells : Absent /hpf
Casts : Absent
Crystals : Absent
Amorphous Deposits : Absent

OTHER FINDINGS

Yeast Cells : Absent
Trichomonas vaginalis : Absent
Bacteria : Absent
Mucus Threads : Absent
Spermatozoa : Absent

Dr. Vandana G. Powar
M.B.B.S., D.C.P.
Reg No. 68137

PARTH LABORATORY
PATHOLOGIST
DR. VANDANA POWAR
M.B.B.S., D.C.P.

All Biochemistry Tests Done By Computerised Auto Analyser

HAEMATOLOGY • CLINICAL PATHOLOGY • BIOCHEMISTRY • SEROLOGY • MICROBIOLOGY • HISTOPATHOLOGY

24 Hours Emergency Service

Home Service Available

Dr. Vandana G. Powar M.B.B.S., D.C.P.
Consultant Pathologist



PARTH
PATHOLOGY LABORATORY
(Computerised)

LAB - Shop No. 7, "Diwan Towers" Mangalwar Peth, Near Mirajkar Tikli, Opp. Nutan Marathi High School, Kolhapur. Mob. 9158529408, 9422047480, 9921285167

PATIENT NAME:- DEEPALI PAVANE

AGE -33SEX/FEMALE

REFERANCE= MEDIWHEEL LIFE INS.

DATE - 04/04/2023

BIOCHEMISTRY

NORMAL VALUE

S. GAMMA.G.T : 23.1 mmol/L

10-50 mmol / L

Dr. Vandana G. Powar
M.B.B.S., D.C.P.
Reg. No. 60137



All Biochemistry Tests Done By Computerised Auto Analyser

HAEMATOLOGY | CLINICAL PATHOLOGY | BIOCHEMISTRY | SEROLOGY | MICROBIOLOGY | HISTOPATHOLOGY

24 Hours Emergency Service

Home Service Available

Dr. Vandana G. Powar **M.B.B.S., D.C.P.**
Consultant Pathologist



PARTH
PATHOLOGY LABORATORY
(Computerised)

LAB - Shop No. 7, "Diwan Towers" Mangalwar Peth, Near Mirajkar Tikli, Opp. Nutan Marathi High School, Kolhapur. Mob. 9158529408, 9422047480, 9921285167

PATIENT NAME:- DEEPALI PAVANE

AGE -33SEX-FEMALE

REFERANCE= MEDIWHEEL LIFE INS.

DATE - 04/04/2023


BIOCHEMISTRY

SERUM VLDL : 13.0

NORMAL VALUE

10-50 mmol / L

Dr. Vandana G. Powar
M.B.B.S., D.C.P.



All Biochemistry Tests Done By Computerised Auto Analyser

HAEMATOLOGY | CLINICAL PATHOLOGY | BIOCHEMISTRY | SEROLOGY | MICROBIOLOGY | HISTOPATHOLOGY

24 Hours Emergency Service

Home Service Available

Dr. Vandana G. Powar MBBS, DCP
Consultant Pathologist



PARTH
PATHOLOGY LABORATORY
(Computerised)

LAB - Shop No. 7, "Diwan Towers" Mangalwar Peth, Near Mirajkar Tikli, Opp. Nutan Marathi High School, Kolhapur. Mob. 9158529408, 9422047480, 9921285167

04/04/2023

THE ECG OF CLIENT – DEEPALI PAVANE
IS WITHIN NORMAL LIMIT

NO ABNORMAL FINDINGS ARE DETECTED

Dr. Vandana G. Powar
MBBS, DCP
Reg No. E8137



All Biochemistry Tests Done By Computerised Auto Analyser

HAEMATOLOGY | CLINICAL PATHOLOGY | BIOCHEMISTRY | SEROLOGY | MICROBIOLOGY | HISTOPATHOLOGY

24 Hours Emergency Service

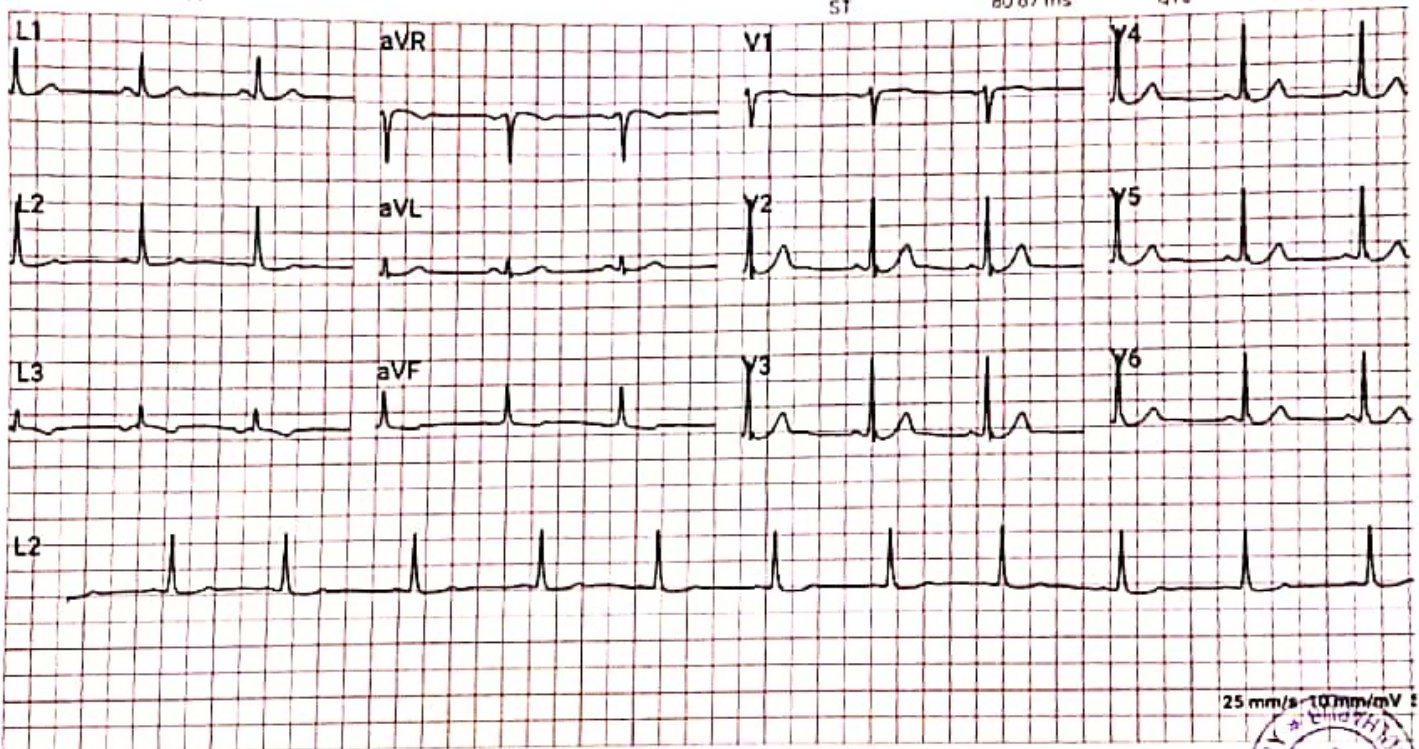
Home Service Available

Wellness

12 lead simultaneous EC

Name Deepali Pawane
Gender | Age 53 | female
Date & Time 04 APRIL 2023 09:30 AM

Heart Rate	68 bpm	QT	360.29 ms
QRS	151.71 ms	PR	142.0 ms
ST	80.67 ms	QTc	376.29 ms



Comments: Normal


Reported By:

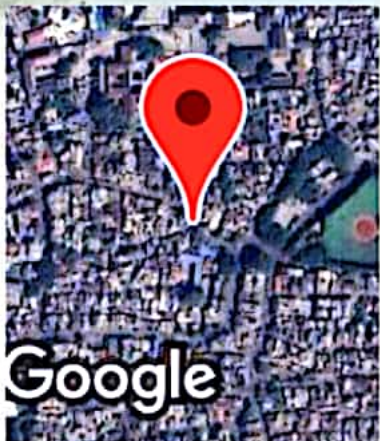25 mm/s 10 mm/mV

Dr. Vandana G. Powar
MBBS, D.C.P.
Reg No 66737

Defused By: Dr. CHANTAKHEDKAR SIDDC SAVONDEWAR VOLKARDIN KAMARADUTRA 1.03 84330 70000



 GPS Map Camera



Kolhapur, Maharashtra, India

**Rajghat Rd, Mangalwar Peth, C Ward, Kolhapur,
Maharashtra 416002, India**

Lat 16.692781°

Long 74.2243°

04/04/23 11:23 AM GMT +05:30

डॉ. बी.जी.जाधव-ढेकळे

एम. बी. बी. एस.
(जनरल फिजिशियन)

डॉ. नेहा घोरपडे

एम. बी. बी. एस., डी.एम.आर.ई
कन्सल्टिंग रेडीओलॉजिस्ट



अस्मिता क्लिनिक
आणि सोनोग्राफी सेंटर

१००४/३अ/२, फिरंगाई देवळासमोर, शिवाजी पेठ, कोल्हापूर - ४१६०१२.

Ph. : (0231) 2621071 | E mail: asmitadiagno.neha@gmail.com

Patient Name : MRS. DEEPALI PAVANE
Referred By : Dr. VANDANA POWAR

Date : 04 Apr 2023
Age : 33 YEARS Sex : F

Clinically - For Health check up.

Abdomen Sonography

LIVER : is normal in size, shape, position and shows normal echogenicity. The contours are smooth. The parenchyma shows homogeneous echo texture. The intra - hepatic portal and venous system appears normal. The portal vein is normal and show hepatopetal flow. The intra-hepatic biliary radicals are not dilated. There is no focal mass lesion.

GALL BLADDER: is physiologically distended, normal in size and echotexture. There is no evidence of echoreflexive calculus in gall bladder. There is no abnormal biliary tree dilation noted. The portal vein & C.B.D appear normal. Wall thickness is normal. No e/o cholecystitis/calculus seen. PV measures -11 mm, CBD measures - 3 mm

PANCREAS: is not well visualized due to overlying bowel gases. The contours are smooth. There is no focal mass lesion seen. No pancreatitis or calcification.

SPLEEN: is normal in size, shape and echopattern. The contours are smooth. The splenic vein and portal vein are normal in calibre.

KIDNEYS: Both the kidneys are normal in size, shape and position and contours. There is no echoreflexive obstructing calculus seen on either sides nor hydronephrosis. Both visualized ureters appear to be normal. Parenchymal thickness and cortical thickness is normal. Cortico - medullary differentiation is well maintained.

Right kidney measures- 107 X 38 mm, **Left kidney** measures -116 X 43 mm.

Urinary bladder is physiologically distended, appears normal. No intraluminal abnormality.

Aorta and IVC are normal. No e/o free fluid in peritoneal cavity. No ascites. No significant lymphadenopathy. Bowel loops appear normal in size with good peristalsis.

Appendix is not appreciated in today's study. Terminal ileum is well seen. No probe tenderness in right iliac fossa or anywhere in abdomen.

IMPRESSION : < NO SIGNIFICANT ABNORMALITY DETECTED.

ADVICE - Clinical correlation and follow up if clinically needed.
THANKS FOR REFERRAL. FEEDBACK IS WELCOME.

Neha S

DR. NEHA S. GHORPADE
MBBS DMRE Reg. No. 79916
Consulting Radiologist

डॉ. नेहा घोरपडे

एम. बी. बी. एस., डी.एम.आर.ई (रेडीओलॉजिस्ट)
रजि.नं. 79916

परत येताना सर्व जुने रिपोर्ट्स, सोनोग्राफी रिपोर्ट्स अथवा एक्स-रे असल्यास बरोबर घेऊन येणे.

डॉ.बी.जी.जाधव-ढेकळे

एम. बी. बी. एस.
(जनरल फिजिशियन)

डॉ. नेहा घोरपडे

एम. बी. बी. एस., डी.एम.आर.ई
कन्सल्टिंग रेडीओलॉजिस्ट



अस्मिता क्लिनिक
आणि सोनोग्राफी सेंटर

१००४/३अ/२, फिरंगाई देवळासमोर, शिवाजी पेठ, कोल्हापूर - ४१६०१२.

Ph. : (0231) 2621071 | E mail: asmitadiagno.neha@gmail.com

Patient Name : MRS. DEEPALI PAVANE
Referred By : Dr. VANDANA POWAR

Date : 04 Apr 2023
Age : 33 YEARS Sex : F

LMP : 28-3-2023
CLINICALLY : For Health check up.

PELVIC SONOGRAPHY

UTERUS - has smooth outlines
and normal echo-appearance
The endometrial echo is 8 mm thick.
Uterus ante- verted, bulky measures are 100 x 33 x 56 mm.

The ovaries are normal.
Right ovary size is 26 x 24 mm.
Left ovary size is 25 x 17 mm.

There is no abnormal adnexal mass.

There is no free fluid in cul de sac.

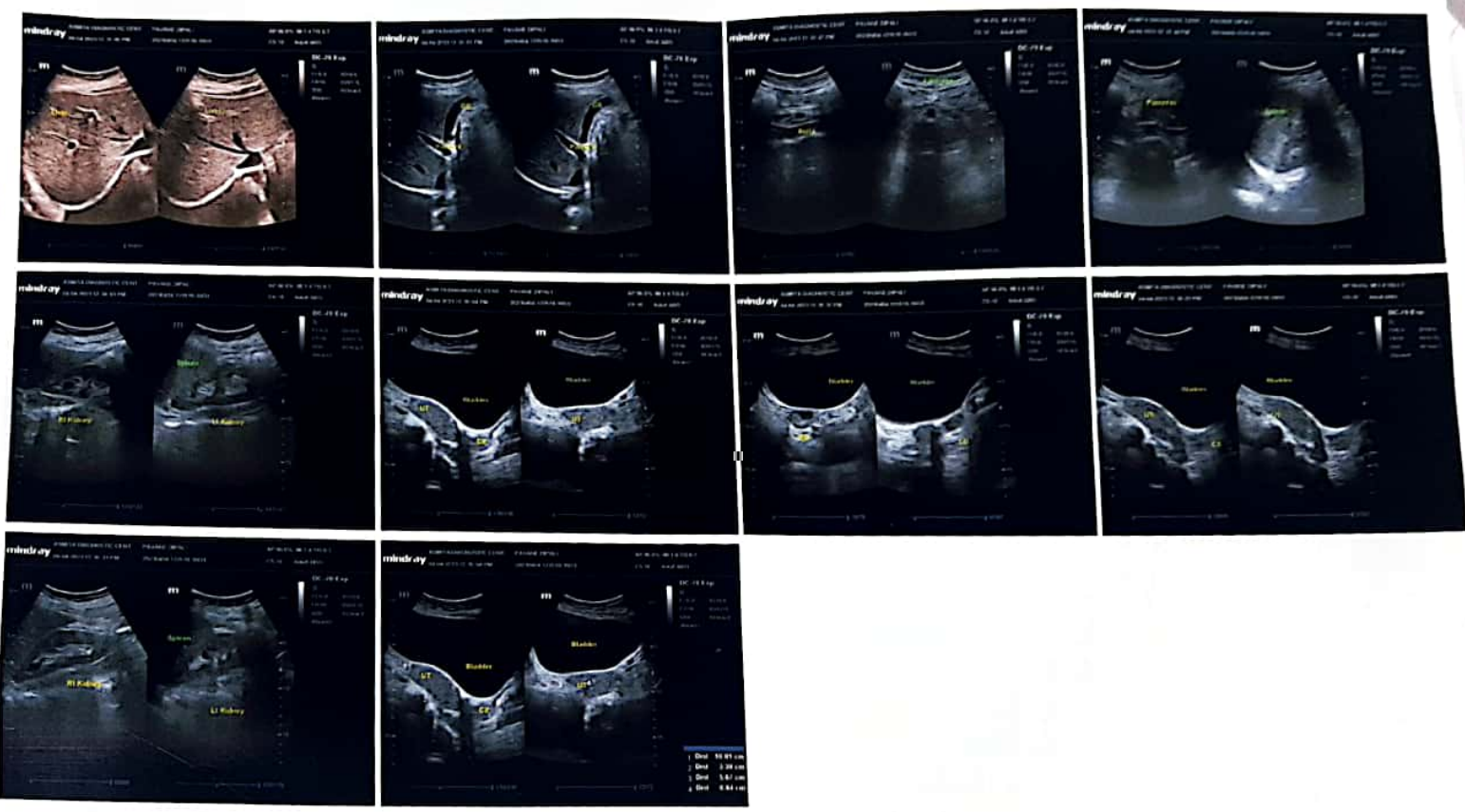
IMPRESSION : < BULKY UTERUS.

Nehas

DR. NEHA S. GHORPADE
MBBS DMRE Reg. No. 79916
Consulting Radiologist

डॉ. नेहा घोरपडे
एम. बी. बी. एस., डी.एम.आर.ई (रेडीओलॉजिस्ट)
रजि.नं.79916

परत येताना सर्व जुने रिपोर्ट्स, सोनोग्राफी रिपोर्ट्स अथवा एक्स-रे असल्यास बरोबर घेऊन येणे.



Name : MRS. DEEPALI PAVANE
Ref By : Dr. VANDANA POWAR

Age/Sex : 33 YEARS/F
Date : 04 Apr 2023

CHEST RADIOGRAPH

No radiological pulmonary parenchymal abnormality seen

The hilar structures are normal.

The heart size and outlines are normal.

The diaphragm contour and costophrenic angles are normal.

Bony rib cage and soft tissues of chest wall are normal.

IMPRESSION:

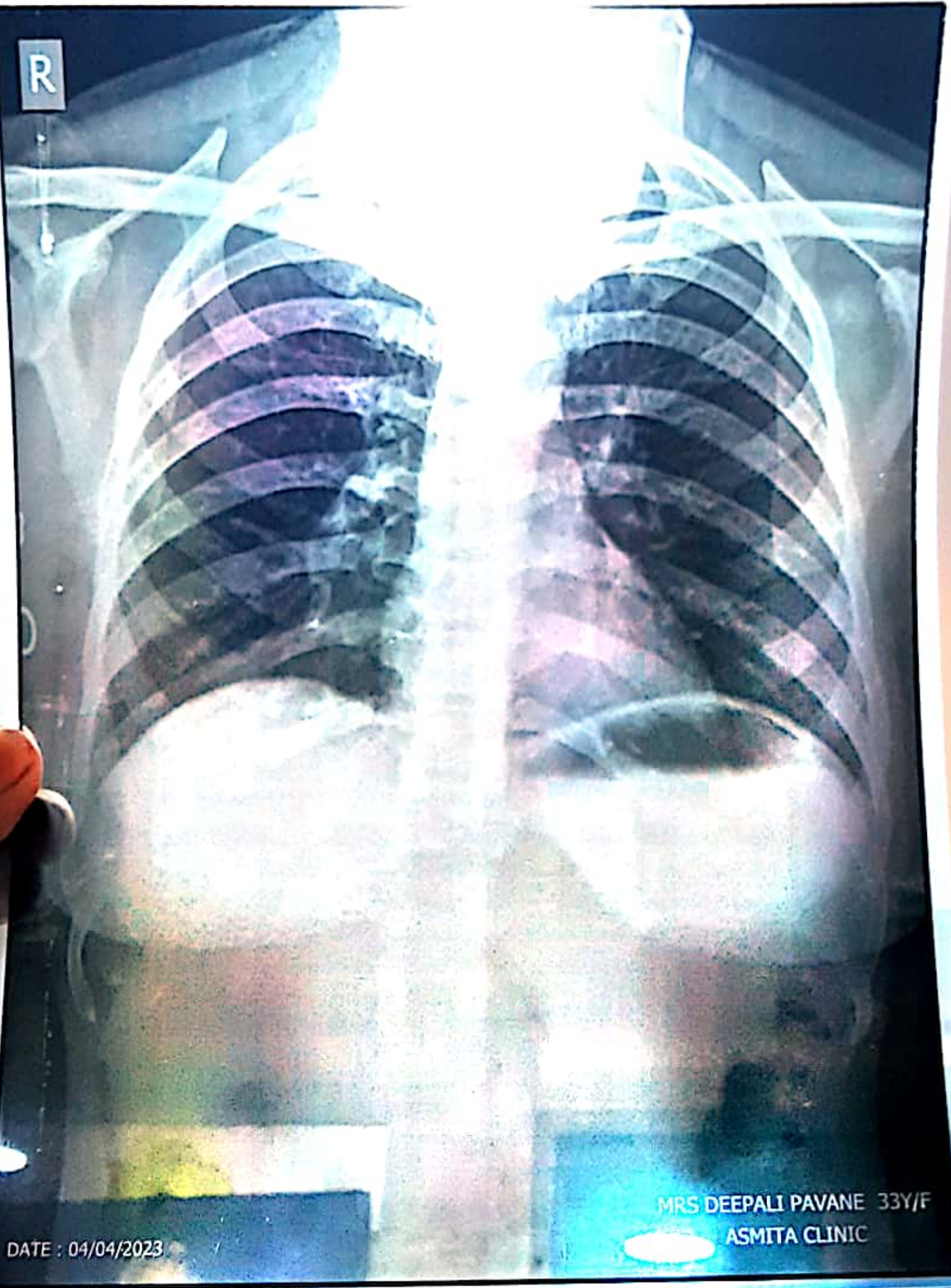
- Radiograph shows no significant abnormality.
- ADVICE - Clinical correlation and follow up if clinically needed.
- THANKS FOR REFERRAL.FEEDBACK IS WELCOME

Neha

डॉ. नेहा घोरपडे
एम. बी. बी. एस., डी.एन.आर.ई (रेडीओलॉजिस्ट)
रजि.नं.79916

परत येताना सर्व जुने रिपोर्ट्स, सोनोग्राफी रिपोर्ट्स अथवा एक्स-रे असल्यास बरोबर घेऊन येणे.

R



DATE : 04/04/2023

MRS DEEPAI PAVANE 33Y/F

ASMITA CLINIC