

Health Check up Booking Request(bobE1740),Package Code(PKG10000243),Beneficiary Code(5174)

1 message

Mediwheel <noreply@mediwheel.in>

12 July 2021 at 13:03

To: "vidhidiagnostics@gmail.com" <vidhidiagnostics@gmail.com>

Cc: Mediwheel CC <wellness@mediwheel.in>, Mediwheel CC <customercare@mediwheel.in>, Mediwheel CC <customercare@policywheel.com>, Mediwheel CC <santosh@policywheel.com>



Mediwheel
...Your wellness partner



011-41195959

Email:wellness@mediwheel.in

Dear Vidhi Diagnostics,
City : Ahmedabad . Location : .New Wadaj,

We have received the following request for Health Check up from

Name : MS. SATISH ANITHA
Age : 47
Gender : Female
Member Relations : Employee
Package Name : Metro Bob Full Body Health Checkup Female Above 40
Package Code : PKG10000243
User Location : Gujarat,AHMEDABAD,380001
Contact Details : 9820434245
Booking Date : 12-07-2021
Appointment Date : 17-07-2021

Member Information			
Booked Member Name	Age	Gender	Cost(In INR)
MS. SATISH ANITHA	47	Female	Cashless
Total amount to be paid			Cashless

Please login to your account to confirm the same. Also you mail us for confirmation

Package Name : Metro Bob Full Body Health Checkup Female Above 40 - Includes (41) Tests

Tests included in this Package

Ecg, TSH, X-ray Chest, Stress Test (tmt)/ 2d Echo, Gynec Consultation, Blood Sugar Postprandial, Dental Consultation, A:g Ratio, Blood Group, Total Cholesterol, Triglycerides, Pap Smear, Fasting Blood Sugar, Ultrasound Whole Abdomen , Glycosylated Haemoglobin (hba1c), Mammography, Hdl, Vldl, Urine Analysis, LDL, Total Protine, General Consultation, HDL/ LDL ratio, GGT(Gamma-glutamyl Transferase), Eye Check-up consultation, ALP (ALKALINE PHOSPHATASE), Uric Acid, AST/ALT Ratio, Serum Protein, CBC with ESR, Stool Analysis, Urine Sugar Fasting, Urine Sugar PP, T3, T4, Cholesterol Total / HDL Ratio, BUN, BUN/Creatinine Ratio, Bilirubin Total & Direct and Indirect, Albumin, Globulin



भारत सरकार
GOVERNMENT OF INDIA



अनिता सतीश
Anitha Satish
जन्म वर्ष/YoB: 1973
महिला Female

4469 3695 7400



आधार - सामान्य भाणसाचा अधिकार

Dr. Dinēsh S. Modh

M.D., D.M.R.E. (Radiodiagnosis)
Consultant Radiologist & Sonologist
Ex. Junior Lecturer, B.J. Medical College, Civil Hospital, A'bad.
Panel Doctor of L.I.C.



Ms Satish Amitha 47 yr / Female 17/7/2021

Eye-Vision! - Eye vision normal with specs
-0.25 in both eye
No night & colour blindness

BP! - 104/70 mm Hg

Height! - 160 cm

Weight! - 72 kg

T! - (N)

RS & normal.
CVS

Sto 1 - 98

Pulse! - 62 per min.

Asymptomatic

No H/o HIV, DM, Thyroid or TB

Advice

She is medically fit &
normal eye vision with
specs - 0.25 in both eye

Dental! -

Teeth - extraction
in. Upper and lower
molar teeth.
No caries noted.

Dr. Vidhi D. Modh
MBBS
Reg. No. G-74540

ISO 9001:2015 Certified Diagnostics Center
Vidhi Imaging Center

L-86, Swatantra Senani Nagar, Opp. Akhbaragar Petrol Pump, Nr. Akhbaragar Circle, Nava-Vadaj, Ahmedabad - 380 013.
Phone : 079-2762 1406, Mobile : 98799 29406, 98250 09406, E-mail : vidhidiagnostics@gmail.com, Website : www.vidhidiagnostics.com
Time : Mon. to Sat. 9.00 am to 2.00 pm, 5.00 pm to 9.00 pm, Sunday 9.00 am to 12.00 Noon

EMPANNELLED WITH HEALTH INDIA TPA & APOLLO HEALTH CHECK NETWORK

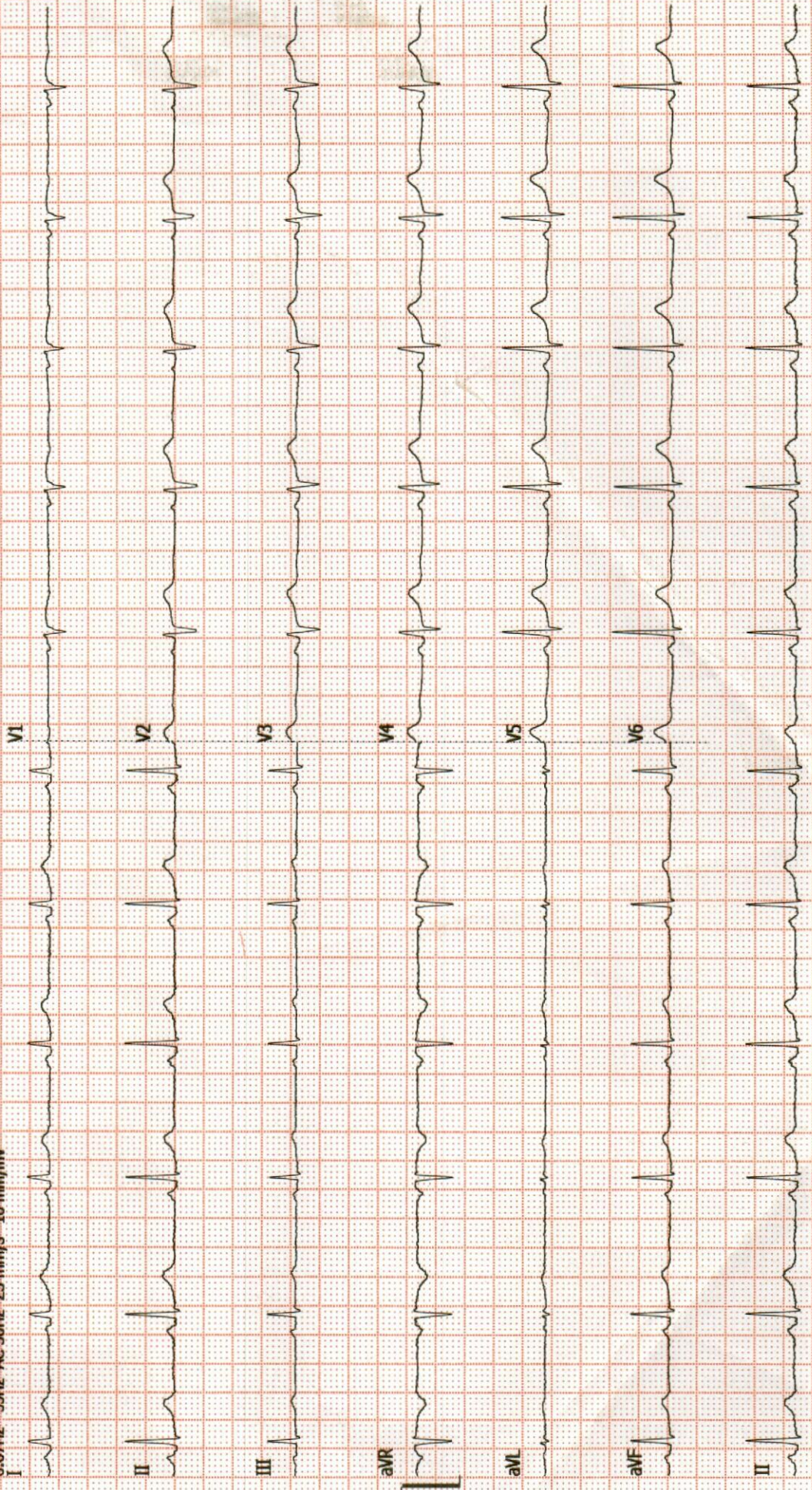
FACILITIES : Live 3D-4D Sonography | Colour Doppler | Echo Cardiography | Interventional Radiology | Fetal Medicine | Digital X-Ray
Digital Mammography | Digital OPG/TMJ | ECG/TMT/PFT/EEG/EMG | Pathology Laboratory | Health Check Up Plans | Pre Employment Check Up

HR : 64 bpm
 PR : 126 ms
 QRS : 78 ms
 QT/QTc : 386/398 ms
 P/QRS/T : 48/61/45 deg
 RV5/SV1 : 0.809/-0.310 mv
 RV5+SV1 : 1.119 mv

ID: 1844
 Name: anitha
 Age: 47yrs
 Sex: Female
 Hospital:

Need to be confirmed by doctor. Doctor Name:

0.67Hz 35Hz AC 50Hz 25 mm/s 10 mm/mv



Dr. Dinesh S. Modh

M.D., D.M.R.E. (Radiodiagnosis)

Consultant Radiologist & Sonologist

Ex. Junior Lecturer, B.J. Medical College, Civil Hospital, A'bad.

Panel Doctor of L.I.C.



Patient's name : ANITHA SATISH
Reg. ID : R-3855-21
Referred by : Dr. MEDIWHEEL

Age/Sex : 47 Years/Female
Accession : 27453
Date : 17/07/2021

Report of ECG

Conclusion

- Normal sinus rhythm.
- HR - 62/per minute.
- Normal PR interval.
- Normal QRS interval.
- Normal QT interval.

Dr. Avinash Bhaskar

M.B.S. D Cardiac
Reg. No.: G-45946

DR.AVINASH BHASKAR

ISO 9001:2015 Certified Diagnostics Center

Vidhi Imaging Center

L-86, Swatantra Senani Nagar, Opp. Akhbarnagar Petrol Pump, Nr. Akhbarnagar Circle, Nava-Vadaj, Ahmedabad - 380 013.

Phone : 079-2762 1406, Mobile : 98799 29406, 98250 09406, E-mail : vidhidiagnostics@gmail.com, Website : www.vidhidiagnostics.com

Time : Mon. to Sat. 9.00 am to 2.00 pm, 5.00 pm to 9.00 pm, Sunday 9.00 am to 12.00 Noon

EMPANNELLED WITH HEALTH INDIA TPA & APOLLO HEALTH CHECK NETWORK

FACILITIES : Live 3D-4D Sonography | Colour Doppler | Echo Cardiography | Interventional Radiology | Fetal Medicine | Digital X-Ray
Digital Mammography | Digital OPG / TMJ | ECG / TMT / PFT / EEG / EMG | Pathology Laboratory | Health Check Up Plans | Pre Employment Check Up

Dr. Dinesh S. Modh

M.D., D.M.R.E. (Radiodiagnosis)

Consultant Radiologist & Sonologist

Ex. Junior Lecturer, B.J. Medical College, Civil Hospital, A'bad.

Panel Doctor of L.I.C.



Patient's name: ANITHA SATISH
Reg. ID : R-3855-21
Referred by : Dr. MEDIWHEEL

Age/Sex : 47 Years/Female
Accession : 27453
Date : 17/07/2021

USG ABDOMEN

LIVER:- Liver shows normal in size & normal echotexture. No e/o diffuse or focal lesion is seen. IHBR appear normal. PV & CBD (4mm) appears normal. No e/o calculus is seen in bile duct.

GALL BLADDER: - Gall bladder is distended and shows multiple mobile calculi. GB wall thickness appears normal.

SPLEEN:- Spleen appears normal in size & shows normal echotexture. No evidence of diffuse or focal lesion is seen.

PANCREAS:- Pancreas appears normal size and echopattern. No e/o diffuse or focal lesion is seen. Main pancreatic duct appears normal.

KIDNEY:-Both Kidneys appear normal in size & echotexture.

No e/o calculus or hydronephrosis or hydroureter is seen in both sides.

Cortico-medullary differentiation is maintained on either side.

Both suprarenal regions appear normal.

No evidence of pre & para aortic lymphadenopathy is seen.

No evidence of free fluid is seen in abdomen.

No evidence of dilated or thickened bowel loops is seen.

Urinary bladder: - appear normal. No e/o calculus or mass lesion is seen in bladder.

Uterus is post-menopausal state.

Both adenexal regions appear normal.

No e/o free fluid is seen in pouch of Douglas.

Dr. Dinesh S. Modh
MD DMRE (Radiodiagnosis)
G-23825

Thanks for reference.

DR DINESH S. MODH

M.D. DMRE(RADIODIAGNOSIS)

ISO 9001:2015 Certified Diagnostics Center

Vidhi Imaging Center

L-86, Swatantra Senani Nagar, Opp. Akhbarnagar Petrol Pump, Nr. Akhbarnagar Circle, Nava-Vadaj, Ahmedabad - 380 013.

Phone : 079-2762 1406, Mobile : 98799 29406, 98250 09406, E-mail : vidhidiagnostics@gmail.com, Website : www.vidhidiagnostics.com

Time : Mon. to Sat. 9.00 am to 2.00 pm, 5.00 pm to 9.00 pm, Sunday 9.00 am to 12.00 Noon

EMPANNELLED WITH HEALTH INDIA TPA & APOLLO HEALTH CHECK NETWORK

FACILITIES : Live 3D-4D Sonography | Colour Doppler | Echo Cardiography | Interventional Radiology | Fetal Medicine | Digital X-Ray
Digital Mammography | Digital OPG / TMJ | ECG / TMT / PFT / EEG / EMG | Pathology Laboratory | Health Check Up Plans | Pre Employment Check Up

Dr. Dinesh S. Modh

M.D., D.M.R.E. (Radiodiagnosis)

Consultant Radiologist & Sonologist

Ex. Junior Lecturer, B.J. Medical College, Civil Hospital, A'bad.

Panel Doctor of L.I.C.



Patient's name : ANITHA SATISH
Reg. ID : R-3855-21
Referred by : Dr. MEDIWHEEL

Age/Sex : 47 Years/Female
Accession : 27453
Date : 17/07/2021

2D- ECHO REPORT

FINAL CONCLUSION:

LV IS NORMAL SIZE. GOOD LV SYSTOLIC FUNCTION.NO RWMA
LVEF - 60%. NO CONCENTRIC LVH.
NORMAL LV COMPLANCE.
LA IS NORMAL SIZE. NO LA CLOT.
RV IS NORMAL SIZE. GOOD RV SYSTOLIC FUNCTION.
RA IS NORMAL SIZE.
MITRAL VALVE IS NORMAL. NO MS. MILD MR (10%). NO MVP.
AORTIC VALVE IS NORMAL. NO AS. NO AR.
TRICUSPID VALVE IS NORMAL. NO TR. RVSP-22 mmHg. NO PAH.

NO CLOT, NO VEGETATION, NO PERICARDIAL EFFUSION.

DIMENSIONS:

AORTA	2.4 C.M
LEFT ATRIUM	2.8 C.M
LVDD	4.2 C.M.
IVSD	1.0 C.M
PWD	1.0 C.M
LVDS	2.6 C.M.

COLOUR DOPPLER FINDING:

STRUCTURE	VELOCITY m/sec
	Max
PULMONARY VALVE	0.7
MITRAL VALVE	E : 0.6 A: 0.4
AORTIC VALVE	1.0

Dr. Avinash Bhaskar
MBBS, D Cardio

Reg. No.: G-45946

DR AVINASH BHASKAR

ISO 9001:2015 Certified Diagnostics Center

Vidhi Imaging Center

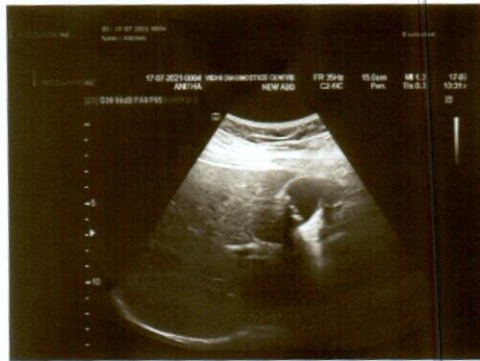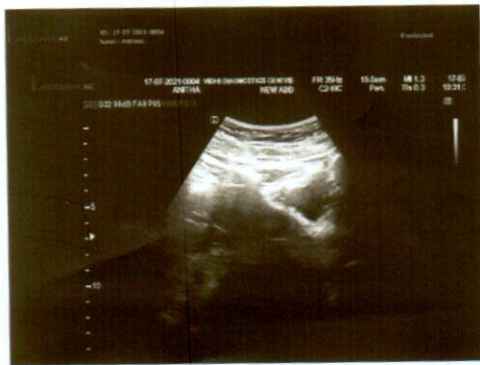
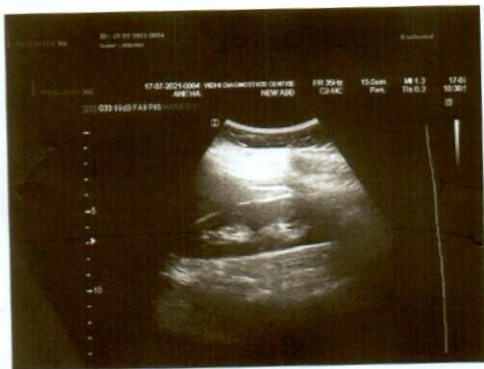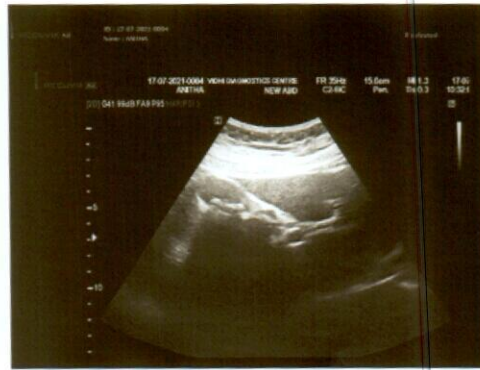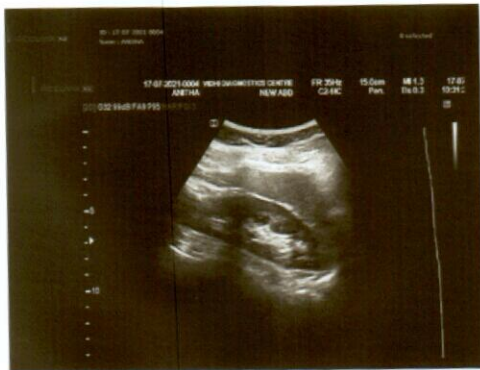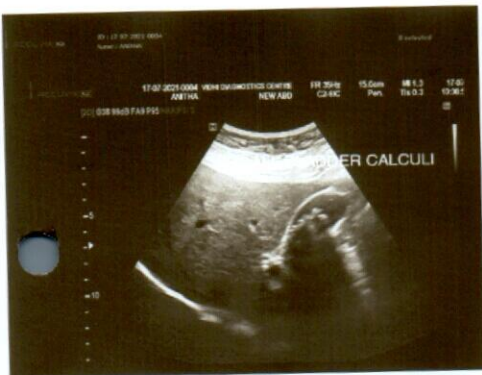L-86, Swatantra Senani Nagar, Opp. Akhbarnagar Petrol Pump, Nr. Akhbarnagar Circle, Nava-Vadaj, Ahmedabad - 380 013.

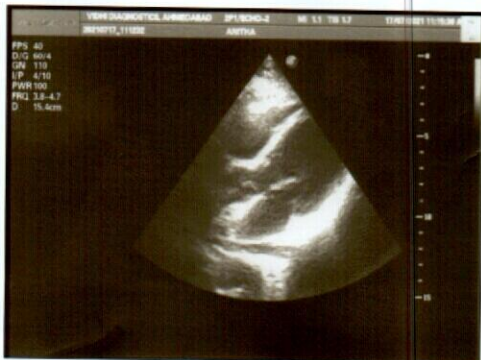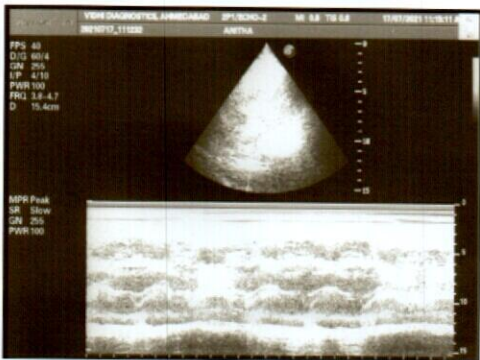
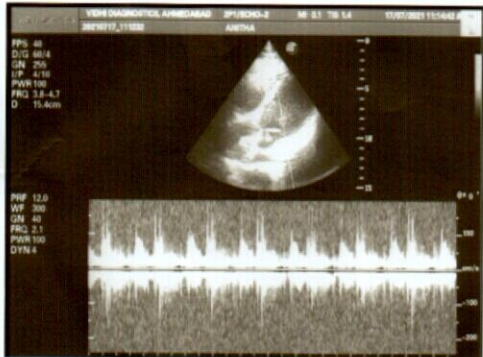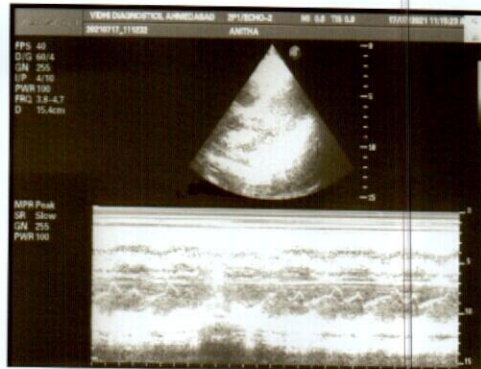
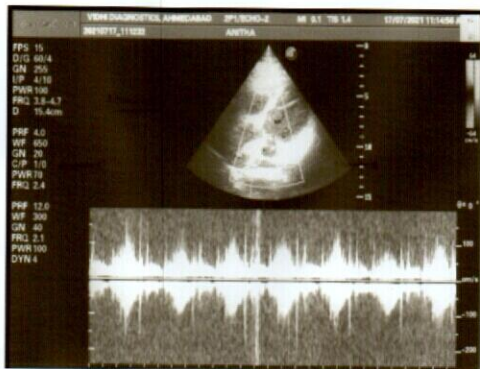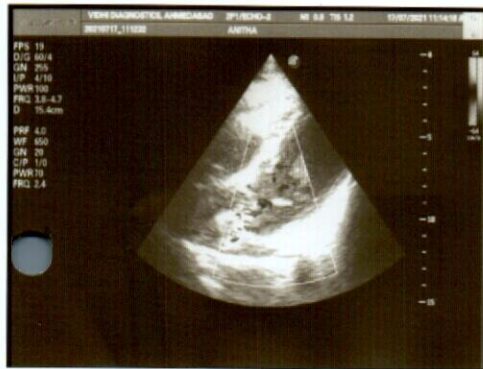
Phone : 079-2762 1406, Mobile : 98799 29406, 98250 09406, E-mail : vidhidiagnostics@gmail.com, Website : www.vidhidiagnostics.com

Time : Mon. to Sat. 9.00 am to 2.00 pm, 5.00 pm to 9.00 pm, Sunday 9.00 am to 12.00 Noon

EMPANNELLED WITH HEALTH INDIA TPA & APOLLO HEALTH CHECK NETWORK

FACILITIES : Live 3D-4D Sonography | Colour Doppler | Echo Cardiography | Interventional Radiology | Fetal Medicine | Digital X-Ray
Digital Mammography | Digital OPG / TMJ | ECG / TMT / PFT / EEG / EMG | Pathology Laboratory | Health Check Up Plans | Pre Employment Check Up





Dr. Dinesh S. Modh

M.D., D.M.R.E. (Radiodiagnosis)

Consultant Radiologist & Sonologist

Ex. Junior Lecturer, B.J. Medical College, Civil Hospital, A'bad.

Panel Doctor of L.I.C.



Patient's name : ANITHA SATISH
Reg. ID : R-3855-21
Referred by : Dr. MEDIWHEEL

Age/Sex : 47 Years/Female
Accession : 27453
Date : 17/07/2021

DIGITAL MAMMOGRAPHY

Digital mammography was done on Siemens mammomat-3000.

Reason for exam: - Screening.

Bilateral digital cranio-caudal and medio-lateral oblique views were taken. The breast tissue is homogeneously dense with fibro-fatty tissue on both sides. No masses, no architectural distortion, no suspicious calcifications, no asymmetries or other abnormalities are seen. No e/o radio-opaque or radiolucent mass lesion is seen. No e/o skin thickening is seen. Nipple and sub-areolar tissue appear normal. Axillary tail appears normal.

USG:-Normal.

Assessment:-Negative (BI-RADS category-1)

BI-RADS category

- 0- incomplete
- 1- Negative
- 2- Benign
- 3- Probably benign
- 4- Suspicious abnormality.
- 5- Highly suggestive of malignancy
- 6- Known biopsy-proven malignancy.

The false negative mammography is approximately 10%. Management of palpable abnormality must be based upon clinical grounds.

Thanks for reference.

DR DINESH S. MODH
M.D. DMRE(RADIODIAGNOSIS)

Dr. Dinesh S. Modh
MD DMRE (Radiodiagnosis)
G-23825

ISO 9001:2015 Certified Diagnostics Center

Vidhi Imaging Center

L-86, Swatantra Senani Nagar, Opp. Akhbarnagar Petrol Pump, Nr. Akhbarnagar Circle, Nava-Vadaj, Ahmedabad - 380 013.

Phone : 079-2762 1406, Mobile : 98799 29406, 98250 09406, E-mail : vidhidiagnostics@gmail.com, Website : www.vidhidiagnostics.com

Time : Mon. to Sat. 9.00 am to 2.00 pm, 5.00 pm to 9.00 pm, Sunday 9.00 am to 12.00 Noon

EMPANNELLED WITH HEALTH INDIA TPA & APOLLO HEALTH CHECK NETWORK

FACILITIES : Live 3D-4D Sonography | Colour Doppler | Echo Cardiography | Interventional Radiology | Fetal Medicine | Digital X-Ray
Digital Mammography | Digital OPG / TMJ | ECG / TMT / PFT / EEG / EMG | Pathology Laboratory | Health Check Up Plans | Pre Employment Check Up

Dr. Dinesh S. Modh

M.D., D.M.R.E. (Radiodiagnosis)

Consultant Radiologist & Sonologist

Ex. Junior Lecturer, B.J. Medical College, Civil Hospital, A'bad.

Panel Doctor of L.I.C.



Patient's name: ANITHA SATISH
Reg. ID : R-3855-21
Referred by : Dr. MEDIWHEEL

Age/Sex : 47 Years/Female
Accession : 27453
Date : 17/07/2021

X-RAY CHEST (PA VIEW)

Both lung fields appear normal.
No e/o consolidation or cavitations is seen.
Both costo-phrenic angles appear clear.
Cardiac size is with in normal limits.
Both domes of diaphragm appear normal.
Bony thoracic cage appears normal.

Thanks for reference.

Dr. Dinesh S. Modh
MD DMRE (Radiodiagnosis)
G-23825

DR DINESH S. MODH
M.D. DMRE(RADIODIAGNOSIS)

ISO 9001:2015 Certified Diagnostics Center

Vidhi Imaging Center

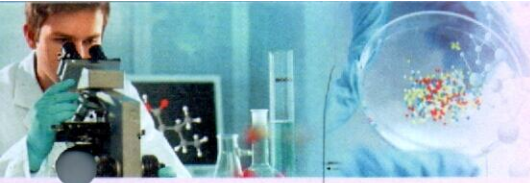L-86, Swatantra Senani Nagar, Opp. Akhbarnagar Petrol Pump, Nr. Akhbarnagar Circle, Nava-Vadaj, Ahmedabad - 380 013.

Phone : 079-2762 1406, Mobile : 98799 29406, 98250 09406, E-mail : vidhidiagnostics@gmail.com, Website : www.vidhidiagnostics.com

Time : Mon. to Sat. 9.00 am to 2.00 pm, 5.00 pm to 9.00 pm, Sunday 9.00 am to 12.00 Noon

EMPANNELLED WITH HEALTH INDIA TPA & APOLLO HEALTH CHECK NETWORK

FACILITIES : Live 3D-4D Sonography | Colour Doppler | Echo Cardiography | Interventional Radiology | Fetal Medicine | Digital X-Ray
Digital Mammography | Digital OPG/TMJ | ECG/TMT/PFT/EEG/EMG | Pathology Laboratory | Health Check Up Plans | Pre Employment Check Up



Pathology Department

Creating Life in Images

Patient's name : ANITHA SATISHKUMAR
 Age/Sex : 47 Years/Female
 Referred by : -
 Collection Time : 21:44
 Reg. ID : P-2504-21
 Accession : 27450
 Order Dt/time : 17/07/2021 21:44

Complete Blood Count

Sample Type: EDTA

Test Name	Result	Units	Biological Reference Interval
-----------	--------	-------	-------------------------------

Blood Counts

Haemoglobin :	13.4	Gms%	12.5 - 16.0
Total R.B.C. :	4.67	mill/c.mm	4.2 - 5.4
Total W. B. C. :	7,020	/cu mm	4000 - 10500
Platelet Count :	2,61,000	/cu.mmm	1,50,000 - 4,50,000

Differential Count

Neutrophils :	55	%	40 - 70
Lymphocytes :	40	%	20 - 40
Eosinophils :	03	%	1 - 4
Monocytes :	02	%	2 - 6
Basophils :	00	%	0 - 01

Blood Indices

P. C. V :	42.3	%	37 - 47
M. C. V. :	90.4	fl	78 - 100
M.C.H :	28.7	pg	27 - 31
M. C. H. C :	<u>31.8</u>	%	32 - 36
R.D.W :	<u>14.4</u>	%	11.5 - 14.0

E.S.R.(Westergren Method)

After one hour :	04	mm/hr	3 - 12
------------------	----	-------	--------

TESTS DONE ON FULLY AUTOMATED HEMATOLOGY ANALYZER.

DR GAYATRI MEHTA
MD(PATHOLOGY)

Dr. Gayatri M. Mehta
 M.D. (Patho)
 Reg. No. G-32215

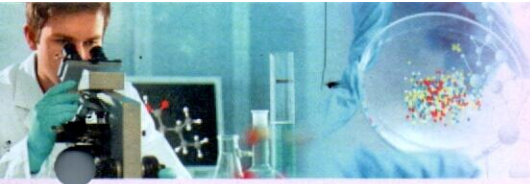DR. ANAND D. PARIKH
MD(PATHOLOGY)

LAB USE ONLY (Entered by :AP Enter Date/Time:17/07/2021 1:15:00 PM) (Verify by :DM Verify Date/Time:17/07/2021 5:20:00 PM)

ISO 9001:2015 Certified Diagnostics Center
Vidhi Imaging Center

L-86, Swatantra Senani Nagar, Opp. Akharnagar Petrol Pump, Nr. Akharnagar Circle, Nava-Vadaj, Ahmedabad - 380 013.
 Phone : 079-2762 1406, Mobile : 98799 29406, 98250 09406, E-mail : vidhidiagnostics@gmail.com, Website : www.vidhidiagnostics.com
 Time : Mon. to Sat. 9.00 am to 2.00 pm, 5.00 pm to 9.00 pm, Sunday 9.00 am to 12.00 Noon

Pathology means science behind medicine



Creating Life in Science

Pathology Department

Patient's name : ANITHA SATISHKUMAR
 Age/Sex : 47 Years/Female
 Referred by : -
 Collection Time : 21:44

Reg. ID : P-2504-21
 Accession : 27450
 Order Dt/time : 17/07/2021 21:44

Blood Group

Sample Type: EDTA sample.

Test Name	Result
BG :	" O "
RH :	POSITIVE
Remarks	Done by forward grouping method.

Blood Glucose

Sample Type: Serum

Test Name	Result	Units	Biological Reference Interval
Fasting Blood Glucose :	89.19	mg/dl	70 - 110
Urine Sugar :	NIL		Absent
<i>GOD-POD Method.</i>			

Blood Glucose

Sample Type: Serum

Test Name	Result	Units	Biological Reference Interval
Post Prandial Blood Glucose After 2hr. :	95.77	mg/dl	80 - 140
Urine Sugar :	S.N.R		Absent
<i>GOD-POD Method.</i>			

DR GAYATRI MEHTA
MD(PATHOLOGY)

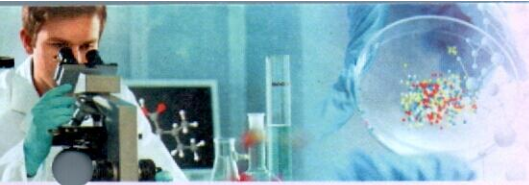Dr. Gayatri M. Mehta
 M.D. (Pathology)
 Reg. No. G-32215

DR. ANAND D. PARIKH
MD(PATHOLOGY)

LAB USE ONLY (Entered by :DM Enter Date/Time:17/07/2021 1:54:00 PM) (Verify by :DM Verify Date/Time:17/07/2021 5:20:00 PM)

ISO 9001:2015 Certified Diagnostics Center
Vidhi Imaging Center

L-86, Swatantra Senani Nagar, Opp. Akhbarnagar Petrol Pump, Nr. Akhbarnagar Circle, Nava-Vadaj, Ahmedabad - 380 013.
 Phone : 079-2762 1406, Mobile : 98799 29406, 98250 09406, E-mail : vidhidiagnostics@gmail.com, Website : www.vidhidiagnostics.com
 Time : Mon. to Sat. 9.00 am to 2.00 pm, 5.00 pm to 9.00 pm, Sunday 9.00 am to 12.00 Noon



Pathology Department



Patient's name : ANITHA SATISHKUMAR
Age/Sex : 47 Years/Female
Referred by : -
Collection Time : 21:44

Reg. ID : P-2504-21
Accession : 27450
Order Dt/time : 17/07/2021 21:44

Lipid Profile

Sample Type: Serum

Test Name	Result	Units	Biological Reference Interval
S. Cholesterol : Oxidase-esterase method.	<u>208.00</u>	mg/dl	0 - 200
S. Triglyceride : Enzymatic Colorimetry method	88.77	mg/dL	0 - 200
S. HDL - Cholesterol : Serum by Enzymatic method.	47.23	mg/dL	35 - 65
S. LDL - Cholesterol : Serum by Enzymatic method	<u>143.016</u>	mg/dL	0 - 130
S. VLDL - Cholesterol :	17.75	mg/dL	0 - 30
S. Chole/HDL.Ratio :	4.4		1 - 6
S. LDL / HDL Cholesterol Ratio :	3.03		0 - 3.5

Thyroid Function Test

Sample Type: Serum

Test Name	Result	Units	Biological Reference Interval
TOTAL T3 :	1.06	ng/ml	0.84 - 2.0
TOTAL T4 :	5.68	ug/dl	5.1 - 14.0
TSH(Ultra sensitive) :	1.066	mIU/L	0.27 - 4.2

Method Electrochemiluminescence Immunoassay "ECLIA"

Test done on Roche Cobas e411 Immunoassay Analyser

Dr. Gayatri M. Mehta

DR GAYATRI MEHTA
MD(PATHOLOGY)

M.D. (Pathology)
Reg. No. G-32215

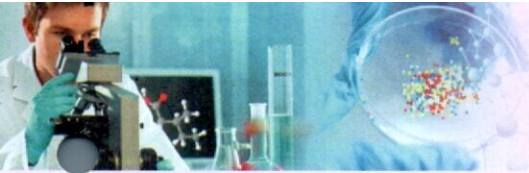DR. ANAND D. PARIKH
MD(PATHOLOGY)

LAB USE ONLY (Entered by :DM Enter Date/Time:17/07/2021 1:56:00 PM) (Verify by :DM Verify Date/Time:17/07/2021 5:20:00 PM)

ISO 9001:2015 Certified Diagnostics Center
Vidhi Imaging Center

L-86, Swatantra Senani Nagar, Opp. Akhbarnagar Petrol Pump, Nr. Akhbarnagar Circle, Nava-Vadaj, Ahmedabad - 380 013.
Phone : 079-2762 1406, Mobile : 98799 29406, 98250 09406, E-mail : vidhidiagnostics@gmail.com, Website : www.vidhidiagnostics.com
Time : Mon. to Sat. 9.00 am to 2.00 pm, 5.00 pm to 9.00 pm, Sunday 9.00 am to 12.00 Noon

Pathology means science behind medicine



Patient's name : ANITHA SATISHKUMAR
Age/Sex : 47 Years/Female
Referred by : -
Collection Time : 21:44

Reg. ID : P-2504-21
Accession : 27450
Order Dt/time : 17/07/2021 21:44

BIOCHEMISTRY

Sample type :Serum

Test Name	Result	Units	Biological Reference Interval
Urea, (Serum by GLDH method) :	26.98	mg/dl	10 - 50
S.Uric acid, (Serum by Uricase method) :	4.56	mg/dl	2.4-5.7
Bun :	12.6	mg/dl	6-20
Creatinine, (Serum by Jaffe reaction) :	0.96	mg/dl	0.5-1.2
S.G.P.T (ALT) : (Serum by IFCC method)	13.45	U/L	0 - 40
S.G.O.T (AST) : (Serum by IFCC method)	19.07	U/L	0 - 37
ALK.PHOSPHATASE : (Serum by PNP method)	88.32	U/L	35-104
G.G.T :	15.25	U/L	8 - 78
<u>BILIRUBIN</u>			
Total :	0.35	mg/dl	Up to 1.2
Direct :	0.14	mg/dl	0-0.7
Indirect :	0.21	mg/dl	0 - 0.5
<u>SERUM PROTEINS</u>			
Total Protein (Serum by Biuret method) :	6.99	gms/dl	
Albumin (Serum by BCG method) :	4.37	gms/dl	3.97-4.94
Globulins :	2.62	gms/dl	2.3 - 3.5
A/G Ratio :	1.668		0.9 - 2.9

DR GAYATRI MEHTA
MD(PATHOLOGY)

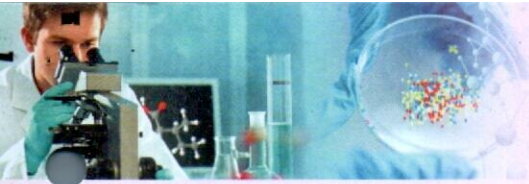Dr. Gayatri M. Mehta
M. D. (PATHOLOGY)
Reg. No. G-22215

DR. ANAND D. PARIKH
MD(PATHOLOGY)

LAB USE ONLY (Entered by :DM Enter Date/Time:17/07/2021 1:56:00 PM) (Verify by :DM Verify Date/Time:17/07/2021 5:20:00 PM)

ISO 9001:2015 Certified Diagnostics Center
Vidhi Imaging Center

L-86, Swatantra Senani Nagar, Opp. Akhbarnagar Petrol Pump, Nr. Akhbarnagar Circle, Nava-Vadaj, Ahmedabad - 380 013.
Phone : 079-2762 1406, Mobile : 98799 29406, 98250 09406, E-mail : vidhidiagnostics@gmail.com, Website : www.vidhidiagnostics.com
Time : Mon. to Sat. 9.00 am to 2.00 pm, 5.00 pm to 9.00 pm, Sunday 9.00 am to 12.00 Noon



Pathology Department

Name: ANITHA SATISHKUMAR Age: 47 Years
Referred by: - Sex: Female
Date: 17/07/2021

AST/ALT RATIO

Test	Result	Unit	Normal Value
SGOT:SGPT	1.1	Ratio	0.8-1.2

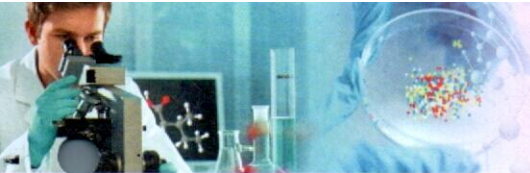BUN/CREAT RATIO

Test	Result	Unit	Normal Value
BUN:CREAT	13.1	Ratio	13-20

Dr. Gayatri M. Mehta
M.D. (Patho)
Reg. No. G-32215
For Dr. GAYATRI MEHTA

ISO 9001:2015 Certified Diagnostics Center
Vidhi Imaging Center

L-86, Swatantra Senani Nagar, Opp. Akhbarnagar Petrol Pump, Nr. Akhbarnagar Circle, Nava-Vadaj, Ahmedabad - 380 013.
Phone : 079-2762 1406, Mobile : 98799 29406, 98250 09406, E-mail : vidhidiagnostics@gmail.com, Website : www.vidhidiagnostics.com
Time : Mon. to Sat. 9.00 am to 2.00 pm, 5.00 pm to 9.00 pm, Sunday 9.00 am to 12.00 Noon



Patient's name : ANITHA SATISHKUMAR
Age/Sex : 47 Years/Female
Referred by : -
Collection Time : 21:44

Reg. ID : P-2504-21
Accession : 27450
Order Dt/time : 17/07/2021 21:44

HbA1C

Sample Type: Serum

Test Name	Result	Units	Biological Reference Interval
HbA1C :	5.9	%	Non-diabetic: 4.2-6.2 Pre-diabetic : 6.3-7.2 Diabetic : 7.3-8.2
Mean Blood Glucose of Last 03 months.	122.63	mg/dl	

Comment

*As per the new 2009 update of American Diabetes Association regarding HbA1C & Mean Blood Glucose relationship.

NOTE:

This test is used to monitor diabetic patients compliance with the therapeutic regimen and logo It's level is proportional to both the average blood glucose concentration and the life span of the red blood cells (RBC) in circulation. HbA1c values are free of day to day glucose fluctuations and are unaffected by exercise or recent food intake.

DR GAYATRI MEHTA
MD(PATHOLOGY)

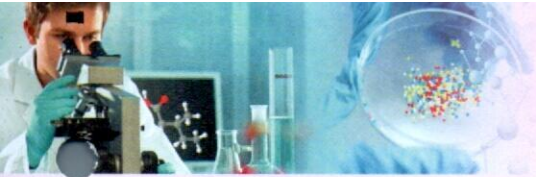Dr. Gayatri M. Mehta
M.D. (Pathology)
Reg. No. G-32215

DR. ANAND D. PARIKH
MD(PATHOLOGY)

LAB USE ONLY (Entered by : DM Enter Date/Time:17/07/2021 5:14:00 PM) (Verify by : DM Verify Date/Time:17/07/2021 5:20:00 PM)

ISO 9001:2015 Certified Diagnostics Center
Vidhi Imaging Center

L-86, Swatantra Senani Nagar, Opp. Akhbarnagar Petrol Pump, Nr. Akhbarnagar Circle, Nava-Vadaj, Ahmedabad - 380 013.
Phone : 079-2762 1406, Mobile : 98799 29406, 98250 09406, E-mail : vidhidiagnostics@gmail.com, Website : www.vidhidiagnostics.com
Time : Mon. to Sat. 9.00 am to 2.00 pm, 5.00 pm to 9.00 pm, Sunday 9.00 am to 12.00 Noon



Pathology Department

Patient's name : ANITHA SATISHKUMAR
 Age/Sex : 47 Years/Female
 Referred by : -
 Collection Time : 21:44

Reg. ID : P-2504-21
 Accession : 27450
 Order Dt/time : 17/07/2021 21:44

Urine Analysis

Sample Type: Urine

Test Name	Result	Units	Biological Reference Interval
<u>Physical Examination</u>			
Quantity :	20	ml	0 - 500 ml
Colour :	Pale Yellow		Pale Yellow
Transparency :	Slight Turbid.		Clear
Reaction :	Acidic		4.6 - 8.0
Specific Gravity :	1.019		1.016 - 1.022
Sediment :	Present		
<u>Chemical Examination</u>			
Albumin :	Absent		Absent
Sugar :	NIL		Absent
Acetone :	Absent		Absent
Bile Salts :	Absent		Absent
Bile Pigments :	Absent		Absent
Urobilogen :	Absent		Absent
Nitrites :	Absent		Absent
<u>Microscopic Examination</u>			
Red blood Cells :	2-3	/h.p.f	Absent
Pus Cells :	1-2	/h.p.f	Absent
Epithelial Cells :	2-3	/h.p.f	< 10.0
Amorphous :	Absent	/h.p.f	Absent
Bacteria :	Absent	/h.p.f	Absent
Crystals :	Absent	/h.p.f	Absent
Casts :	Absent	/h.p.f	Absent
Fungus :	Not seen	/h.p.f	Absent

DR GAYATRI MEHTA
MD(PATHOLOGY)

Dr. Gayatri M. Mehta
 M. D. (Patho)
 Reg. No. G-22215

DR. ANAND D. PARIKH
MD(PATHOLOGY)

LAB USE ONLY (Entered by :DM Enter Date/Time:17/07/2021 1:56:00 PM) (Verify by :DM Verify Date/Time:17/07/2021 5:20:00 PM)

ISO 9001:2015 Certified Diagnostics Center
 Vidhi Imaging Center

L-86, Swatantra Senani Nagar, Opp. Akhbarnagar Petrol Pump, Nr. Akhbarnagar Circle, Nava-Vadaj, Ahmedabad - 380 013.
 Phone : 079-2762 1406, Mobile : 98799 29406, 98250 09406, E-mail : vidhidiagnostics@gmail.com, Website : www.vidhidiagnostics.com
 Time : Mon. to Sat. 9.00 am to 2.00 pm, 5.00 pm to 9.00 pm, Sunday 9.00 am to 12.00 Noon