

DR. NETRAVALKAR'S ASHWINI PATHOLOGY LABORATORY

(For all Investigation in Histopathology, Cytopathology, Haematology, Clinical Pathology, Microbiology & Hormonal Chemistry)
Consultant Pathologist : **Dr. Prasad Netravalkar** MBBS, MD. (Path) BOM.

(HOME COLLECTION FACILITY AVAILABLE)

Panaji : 1st, Floor, Rizvi Sadan, Above Saroj Emporium, Near Inox Theatre, Opp. Municipal Market, Panaji.
Ph.: 2229142, 8407912840, 8390242524

E-mail: ashwinilabpanaji@gmail.com, drprasadnetravalkar@gmail.com

Mapusa : F8, Ramchandra Chambers, 1st Floor, Mapusa Clinic Road, Mapusa - Bardez, Goa. Ph.: 2252320, 2250709

Sanquelim : 1st floor, Shanta Commercial Complex, Sanquelim - Goa. Ph.: 2364524, 9119574524

Pt.No. : 63 231223

Pt.Name : - Jharna Kumari

Ref. By : -

Age : 31 Yrs. Sex : F

Date : 23-12-2023

Normal Range

COMPLETE HEMOGRAM

Haemoglobin	: 11.3	g/dl	
W.B.C Count	: 5000	cells/ cu-mm	11.5 - 16.5 g/dl
R.B.C Count	: 4.76	millions / cu-mm	4000 - 11000 cells/ cu-mm
MCV	: 67.9	fl	3.8 - 4.5 millions / cu-mm
MCH	: 23.7	Pg	80 - 99 fl
MCHC	: 34.9	%	27 - 33 Pg
PCV	: 32.4	%	32 - 37 %
Platelet Count	: 1.99	lakhs /cu mm	37 - 47 %
E.S.R (Westergren)	: 12	mm/hr	1.5 - 4.5 lakhs /cu mm
			0 - 20 mm/hr

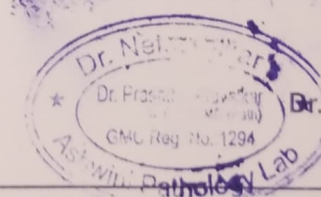
DIFFERENTIAL COUNT

Stab Cells	: 03	%	1-5 %
Neutrophils	: 57	%	40- 60 %
Lymphocytes	: 31	%	20 - 45 %
Eosinophils	: 02	%	1 - 6 %
Monocytes	: 07	%	0 - 10 %
Basophils	: 00	%	0 - 1 %
Abnormal Cells	: Nil		

SMEAR EXAMINATION

RBC Morphology	:	Mild Hypochromia + in RBCs , Microcytes + , Mild Anisocytosis , and Poikilocytosis +	
W.B.C Morphology	:	Within Normal Limits	
Platelets on Smear	:	Adequate	
Parasites	:	Absent	
Blood Group	:	'A' Rh Positive	

Pathologist



Dr. Prasad Netravalkar
MBBS, MD (Bom)
GMC Reg. No. 1294

We Care

All Diagnostic facilities under one roof in Panaji centre - Lab. ultrasound, X ray, ECG, TMT, ECHO

DR. NETRAVALKAR'S ASHWINI PATHOLOGY LABORATORY

For all Investigation in Histopathology, Cytopathology, Haematology, Clinical Pathology, Microbiology & Hormonal Chemistry)

Consultant Pathologist : **Dr. Prasad Netravalkar** MBBS, MD. (Path) BOM.

(HOME COLLECTION FACILITY AVAILABLE)

Panaji : 1st, Floor, Rizvi Sadan, Above Saroj Emporium, Near Inox Theatre, Opp. Municipal Market, Panaji.

Ph.: 2229142, 8407912840, 8390242524

E-mail: ashwinilabpanaji@gmail.com, drprasadnetravalkar@gmail.com

Mapusa : F8, Ramchandra Chambers, 1st Floor, Mapusa Clinic Road, Mapusa - Bardez, Goa. Ph.: 2252320, 2250709

Sanquelim : 1st floor, Shanta Commercial Complex, Sanquelim - Goa. Ph.: 2364524, 9119574524

Pt.No. : 63 231223

Pt.Name : - Jharna Kumari

Age : 31 Yrs. Sex : F

Ref. By : -

Date : 23-12-2023

			<u>Normal Range</u>
Fasting Blood Sugar	: 95.0	mg/dl	70-110 mg/dl
2 Hrs. Blood Sugar	: 120.0	mg/dl	110-140 mg/dl

GLYCOSYLATED HAEMOGLOBIN IN BLOOD (HPLC METHOD)

HbA1C : 4.90 %

Mean Blood Glucose : 94 mg %

INTERPRETATION:

HbA1c %

NORMAL

Below 6.5 %

GOOD DIABETIC CONTROL

6.5 % - 7.5 %

FAIR CONTROL


7.5 % - 8.0 %

UNSATISFACTORY CONTROL

8.0 % - 10.0 %

POOR CONTROL

Above 10.0 %



Pathologist

Dr. Prasad Netravalkar
MBBS, MD (Bom)
GMC Reg. No. 1294

We Care

All Diagnostic facilities under one roof in Panaji centre - Lab, ultrasound, X ray, ECG, TMT, ECHO

DR. NETRAVALKAR'S ASHWINI PATHOLOGY LABORATORY

For all Investigation in Histopathology, Cytopathology, Haematology, Clinical Pathology, Microbiology & Hormonal Chemistry)

Consultant Pathologist : **Dr. Prasad Netravalkar** MBBS, MD. (Path) BOM.

(HOME COLLECTION FACILITY AVAILABLE)

Panaji : 1st, Floor, Rizvi Sadan, Above Saroj Emporium, Near Inox Theatre, Opp. Municipal Market, Panaji.

Ph.: 2229142, 8407912840, 8390242524

E-mail: ashwinilabpanaji@gmail.com, drprasadnetravalkar@gmail.com

Mapusa : F8, Ramchandra Chambers, 1st Floor, Mapusa Clinic Road, Mapusa - Bardez, Goa. Ph.: 2252320, 2250709

Sanquelim : 1st floor, Shanta Commercial Complex, Sanquelim - Goa. Ph.: 2364524, 9119574524

Pt.No. : 63 231223

Pt.Name : - Jharna Kumari

Age : 31 Yrs. Sex : F


Ref. By : -

Date : 23-12-2023

Normal Range

LIPID PROFILE

Total Cholesterol	: 163.0 mg/dl	130 - 220 mg/dl
S. Triglycerides	: 101.0 mg/dl	35 - 170 mg/dl
HDL Cholesterol	: 38.0 mg/dl	> 45 mg/dl
LDL Cholesterol	: 105 mg/dl	< 130 mg/dl
VLDL Cholesterol	: 20 mg/dl	Upto 35 mg/dl
TC/HDLC Ratio	: 4.3	< 4.5
LDLC/HDLC Ratio	: 2.8	2.5 - 3.5



Pathologist

Dr. Prasad Netravalkar
MBBS, MD (Bom)
GMC Reg. No. 1294

We Care

All Diagnostic facilities under one roof in Panaji centre - Lab. ultrasound, X ray, ECG, TMT, ECHO

DR. NETRAVALKAR'S ASHWINI PATHOLOGY LABORATORY

for all investigation in Histopathology, Cytopathology, Haematology, Clinical Pathology, Microbiology & Hormonal Chemistry)
Consultant Pathologist : **Dr. Prasad Netravalkar** MBBS, MD. (Path) BOM.

(HOME COLLECTION FACILITY AVAILABLE)

Panaji : 1st, Floor, Rizvi Sadan, Above Saroj Emporium, Near Inox Theatre, Opp. Municipal Market, Panaji.
Ph.: 2229142, 8407912840, 8390242524
E-mail: ashwinilabpanaji@gmail.com, drprasadnetravalkar@gmail.com
Mapusa : F8, Ramchandra Chambers, 1st Floor, Mapusa Clinic Road, Mapusa - Bardez, Goa. Ph.: 2252320, 2250709
Sanquelim : 1st floor, Shanta Commercial Complex, Sanquelim - Goa. Ph.: 2364524, 9119574524


Pt.No. : 63 231223
Pt.Name : - Jharna Kumari
Ref. By : -

Age : 31 Yrs. Sex : F
Date : 23-12-2023

Normal Range

LIVER FUNCTION TEST

S. Bilirubin (Total)	: 0.60	mg/dl	0 - 1 mg/dl
S. Bilirubin (Direct)	: 0.21	mg/dl	0 - 0.25 mg/dl
S. Bilirubin (Indirect)	: 0.39	mg/dl	0 - 0.75 mg/dl
S.G.O.T	: 22.0	U/L	0 - 42 U/L
S.G.P.T	: 26.0	U/L	0 - 42 U/L
S. Alkaline Phosphatase	: 85.0	IU/L	15 - 112 IU/L
GGTP	: 26.0	U/L	9-37 U/L
Total Proteins	: 6.81	g/dl	6.0 - 10.0 g/dl
S. Albumin	: 3.94	gm%	3.2 - 5.5 gm%
S. Globulin	: 2.9	g/dl	2.3 - 3.5 g/dl
A/G Ratio	: 1.4 : 1		



[Handwritten Signature]

Pathologist

Dr. Prasad Netravalkar
MBBS, MD (Bom)
GMC Reg. No. 1294

We Care

All Diagnostic facilities under one roof in Panaji centre - Lab, ultrasound, X ray, ECG, TMT, ECHO

DR. NETRAVALKAR'S ASHWINI PATHOLOGY LABORATORY

For all Investigation in Histopathology, Cytopathology, Haematology, Clinical Pathology, Microbiology & Hormonal Chemistry)

Consultant Pathologist : **Dr. Prasad Netravalkar** MBBS, MD. (Path) BOM.

(HOME COLLECTION FACILITY AVAILABLE)

Panaji : 1st, Floor, Rizvi Sadan, Above Saroj Emporium, Near Inox Theatre, Opp. Municipal Market, Panaji.
Ph.: 2229142, 8407912840, 8390242524

E-mail: ashwinilabpanaji@gmail.com, drprasadnetravalkar@gmail.com

Mapusa : F8, Ramchandra Chambers, 1st Floor, Mapusa Clinic Road, Mapusa - Bardez, Goa. Ph.: 2252320, 2250709

Sanquelim : 1st floor, Shanta Commercial Complex, Sanquelim - Goa. Ph.: 2364524, 9119574524

Pt.No. : 63 231223

Pt.Name : - Jharna Kumari

Age : 31 Yrs. Sex : F


Ref. By : -

Date : 23-12-2023

Normal Range

KIDNEY FUNCTION TESTS

Blood Urea	: 18.0 mg/dl	15 - 40 mg/dl
S. Creatinine	: 0.81 mg/dl	0.5 - 1.2 mg/dl
S. Uric Acid.	: 4.10 mg/dl	1.5 - 6.0 mg/dl
S. Sodium	: 137.6 mEq/L	135 - 155 mEq/L
S. Potassium	: 3.68 mEq/L	3.5 - 5.5 mEq/L
S. Chlorides	: 102.9 mEq/L	99 - 108 mEq/L



Pathologist

Dr. Prasad Netravalkar
MBBS, MD (Bom)
GMC Reg. No. 1294

We Care

All Diagnostic facilities under one roof in Panaji centre - Lab. ultrasound, X ray, ECG, TMT, ECHO

DR. NETRAVALKAR'S ASHWINI PATHOLOGY LABORATORY

For all Investigation in Histopathology, Cytopathology, Haematology, Clinical Pathology, Microbiology & Hormonal Chemistry)
Consultant Pathologist : **Dr. Prasad Netravalkar** MBBS, MD. (Path) BOM.

(HOME COLLECTION FACILITY AVAILABLE)

Panaji : 1st, Floor, Rizvi Sadan, Above Saroj Emporium, Near Inox Theatre, Opp. Municipal Market, Panaji.
Ph.: 2229142, 8407912840, 8390242524

E-mail: ashwinilabpanaji@gmail.com, drprasadnetravalkar@gmail.com

Mapusa : F8, Ramchandra Chambers, 1st Floor, Mapusa Clinic Road, Mapusa - Bardez, Goa. Ph.: 2252320, 2250709

Sanquelim : 1st floor, Shanta Commercial Complex, Sanquelim - Goa. Ph.: 2364524, 9119574524

Pt.No. : 63 231223
Pt.Name : - Jharna Kumari
Ref. By : -

Age : 31 Yrs. Sex : F
Date : 23-12-2023

EXAMINATION OF URINE

PHYSICAL EXAMINATION


Quantity : 20 ml
Colour : Pale Yellow
Appearance : Slightly Hazy
pH : 6.5
Specific Gravity : 1.010

CHEMICAL EXAMINATION

Proteins : Present (+)
Glucose : Absent
Ketone Bodies : Absent
Bile Salts : Absent
Bile Pigments : Absent
Occult Blood : Negative
Urobilinogen : Normal

MICROSCOPIC EXAMINATION [As per hpf]

Epithelial Cells : 3 - 4 /hpf
Pus Cells : 2 - 3 /hpf
Red Blood Cells : Occasional /hpf
Casts : Absent
Crystals : Absent



[Signature]
Pathologist

Dr. Prasad Netravalkar
MBBS, MD (Bom)
GMC Reg. No. 1294

We Care

All Diagnostic facilities under one roof in Panaji centre - Lab, ultrasound, X ray, ECG, TMT, ECHO

DR. NETRAVALKAR'S ASHWINI PATHOLOGY LABORATORY

Full Investigation in Histopathology, Cytopathology, Haematology, Clinical Pathology, Microbiology & Hormonal Chemistry)
Consultant Pathologist : **Dr. Prasad Netravalkar** MBBS, MD. (Path) BOM.

(HOME COLLECTION FACILITY AVAILABLE)

Panaji : 1st, Floor, Rizvi Sadan, Above Saroj Emporium, Near Inox Theatre, Opp. Municipal Market, Panaji.
Ph.: 2229142, 8407912840, 8390242524

E-mail: ashwinilabpanaji@gmail.com, drprasadnetravalkar@gmail.com

Mapusa : F8, Ramchandra Chambers, 1st Floor, Mapusa Clinic Road, Mapusa - Bardez, Goa. Ph.: 2252320, 2250709

Sanquelim : 1st floor, Shanta Commercial Complex, Sanquelim - Goa. Ph.: 2364524, 9119574524

Patient Name : JHARNA KUMARI

Age / Gender : 31 / Female


Patient ID : 29605

Source : DIRECT

Referral : SELF

Reporting Time : Dec 23, 2023, 01:44 p.m.


Sample ID :



233570014

Test Description	Value(s)	Reference Range	Unit
Thyroid Profile			
T3 (Total) Method : Serum ECL	1.83	1.30 - 3.10	nmol/l
T4 (Total)* Method : Serum ECL	109.0	66.0 - 181.0	nmol/l
TSH(Ultrasonensitive)* Method : Serum ECL	4.75	0.270 - 4.20	uIU/ml

END OF REPORT



Pathologist

Dr. Prasad Netravalkar
MBBS, MD (Bom)
GMC Reg. No. 1294

We Care

All Diagnostic facilities under one roof in Panaji centre - Lab, ultrasound, X ray, ECG, TMT, ECHO

DR. NETRAVALKAR'S ASHWINI PATHOLOGY LABORATORY

For all Investigation in Histopathology, Cytopathology, Haematology, Clinical Pathology, Microbiology & Hormonal Chemistry)

Consultant Pathologist : **Dr. Prasad Netravalkar** MBBS, MD. (Path) BOM.


(HOME COLLECTION FACILITY AVAILABLE)

Panaji : 1st, Floor, Rizvi Sadan, Above Saroj Emporium, Near Inox Theatre, Opp. Municipal Market, Panaji.
Ph.: 2229142, 8407912840, 8390242524

E-mail: ashwinilabpanaji@gmail.com, drprasadnetravalkar@gmail.com

Mapusa : F8, Ramchandra Chambers, 1st Floor, Mapusa Clinic Road, Mapusa - Bardez, Goa. Ph.: 2252320, 2250709

Sanquelim : 1st floor, Shanta Commercial Complex, Sanquelim - Goa. Ph.: 2364524, 9119574524



Pathologist

Dr. Prasad Netravalkar
MBBS, MD (Bom)
GMC Reg. No. 1294

We Care

All Diagnostic facilities under one roof in Panaji centre - Lab, ultrasound, X ray, ECG, TMT, ECHO


CERTIFICATE OF MEDICAL FITNESS

This is to certify that I have conducted the clinical examination


of Jharna Kumari on 23/12/23

After reviewing the medical history and on clinical examination it has been found that he/she is

	Tick
<ul style="list-style-type: none">• Medically Fit	<input checked="" type="checkbox"/>
<ul style="list-style-type: none">• Fit with restrictions/recommendations <p>Though following restrictions have been revealed, in my opinion, these are not impediments to the job.</p> <p>1.....</p> <p>2.....</p> <p>3.....</p> <p>However the employee should follow the advice/medication that has been communicated to him/her.</p> <p>Review after _____</p>	<input type="checkbox"/>
<ul style="list-style-type: none">• Currently Unfit. Review after _____ recommended	<input type="checkbox"/>
<ul style="list-style-type: none">• Unfit	<input type="checkbox"/>


Dr. 
Medical Officer
The Apollo Clinic, (Location)

This certificate is not meant for medico-legal purposes.



MER- MEDICAL EXAMINATION REPORT

Date of Examination	23/12/23	
NAME	Jharna Kumari	
AGE	31	Gender: F
HEIGHT(cm)	166	WEIGHT (kg): 65
B.P.	100/68	
ECG	- Normal	
X Ray	- Normal	
Vision Checkup	Color Vision : Normal	
	Far Vision Ratio : 6/6	
	Near Vision Ratio : 6/6	
Present Ailments	- NO -	
Details of Past ailments (If Any)	- NO -	
Comments / Advice : She /He is Physically Fit	She is Physically Fit	



Me

Signature with Stamp of Medical Examiner

Dr. Prasad Netravalkar






GPS Map Camera



Google

Panaji, Goa, India
B 165, New Municipal Market, Panaji, Goa 403001, India
Lat 15.498449°
Long 73.822358°
23/12/23 10:43 AM GMT +05:30



201,202,203, Rizvi Sadan, 2nd Floor, Near Municipal Market, Next to Vaidya Hospital, Panaji - Goa.
Tel.: 0832 2238122 | Email : drashanetravalkar@gmail.com

Cardiology Report

Page 1/2

ASHWINI LABORATORY

Date of Exam: 27.12.2023

Patient / Exam Information


Patient ID VS8802280-23-12-27-3
Name JHARNA KUMARI 31
DOB, Age
Sex Other
Height
Weight
BSA
HR

Perf. Phys. Ref. Phys. Sonographer
Comment Indication

M-Mode Measurements	Value	m1	m2	m3	m4	m5	m6	Meth.
AVILA								
Ao Root Diam.	2.46 cm	2.46						avg.
LA Diam.	2.14 cm	2.14						avg.
Left Ventricle								
IVSd	0.76 cm	0.76						avg.
LVDd	4.02 cm	4.02						avg.
LVPWd	0.80 cm	0.80						avg.
IVSs	1.07 cm	1.07						avg.
LVDs	2.86 cm	2.86						avg.
LVPWs	1.03 cm	1.03						avg.
EDV (Teich)	70.834 ml	70.834						
EDV (Cubed)	64.965 ml	64.965						
ESV (Teich)	31.132 ml	31.132						
ESV (Cubed)	23.394 ml	23.394						
SV (Teich)	39.702 ml	39.702						
SV (Cube)	41.571 ml	41.571						
EF (Teich)	56.05 %	56.05						
EF (Cube)	63.99 %	63.99						
Fract. Short.	28.86 %	28.86						
LV Mass	99.53 g	99.53						

Comment

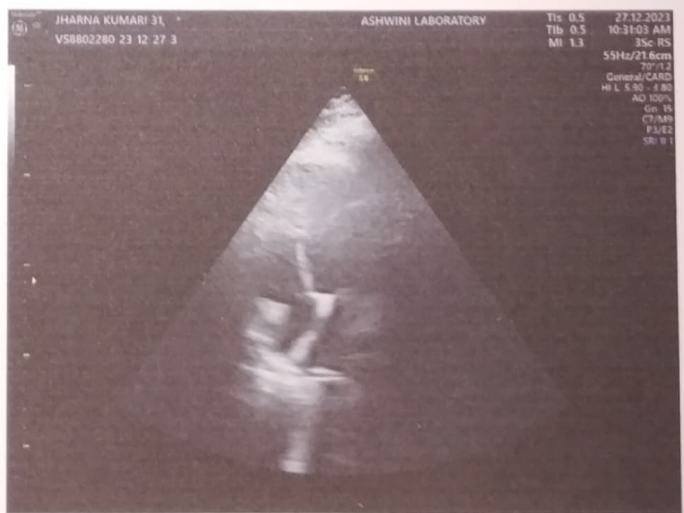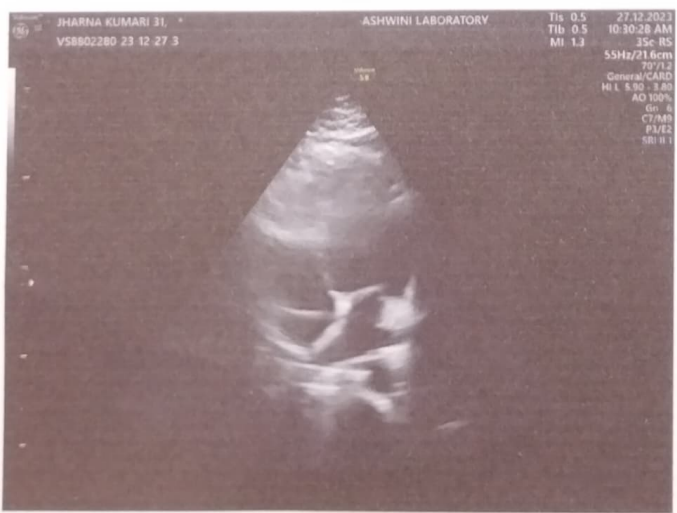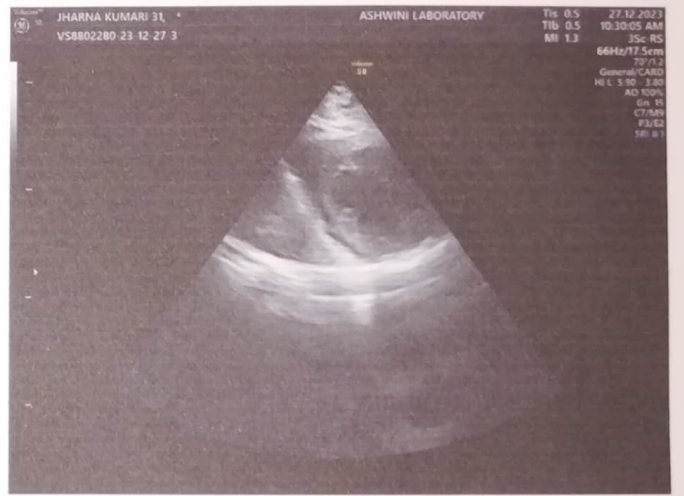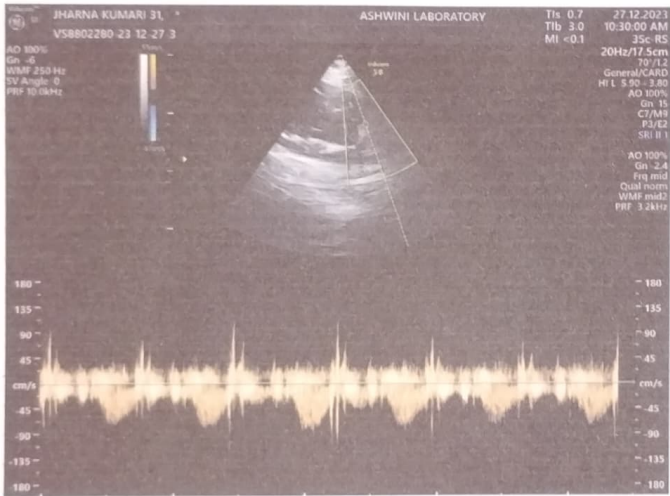
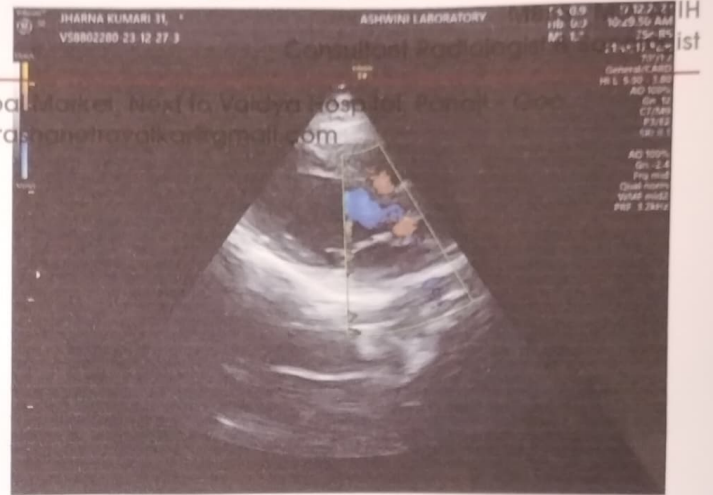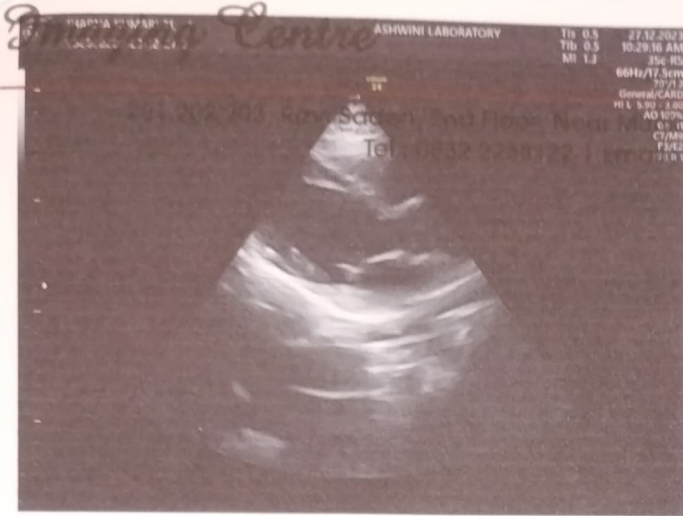NORMAL CARDIAC CHAMBERS DIMENSIONS. NORMAL BI VENTRICLE SYSTOLIC FUNCION. NO REGIONAL WALL MOTION ABNORMALITIES. VALVES ARE GROSSLY NORMAL. AORTIC ROOT IS NORMAL. PERICARDIUM IS NORMAL.

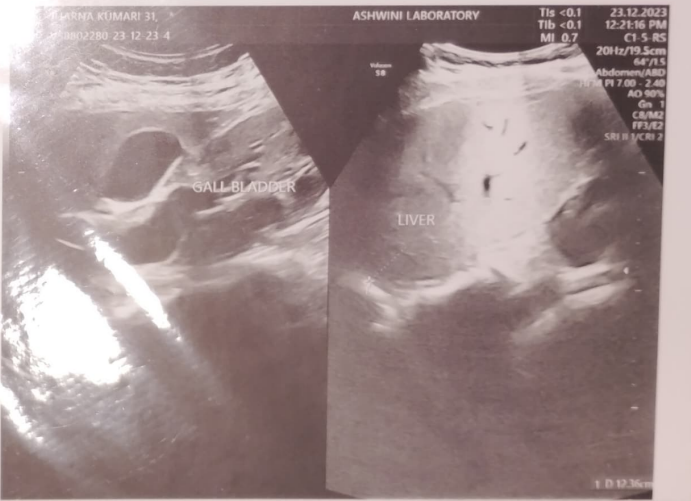
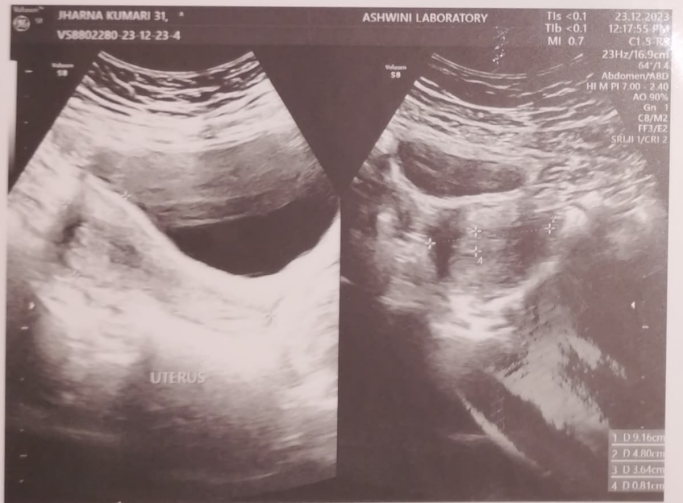
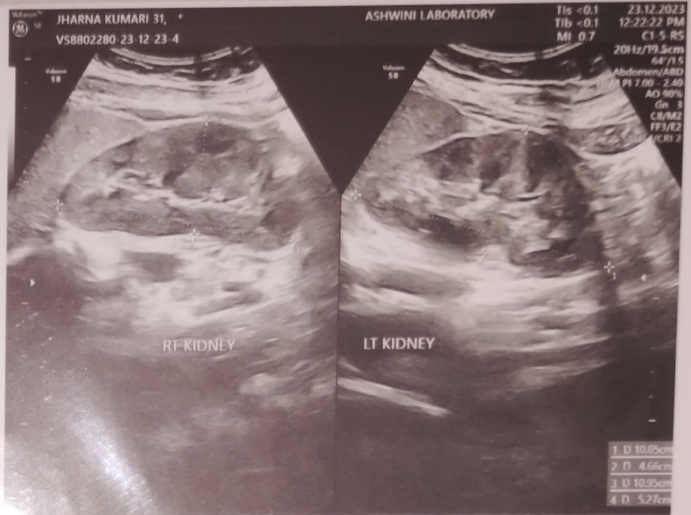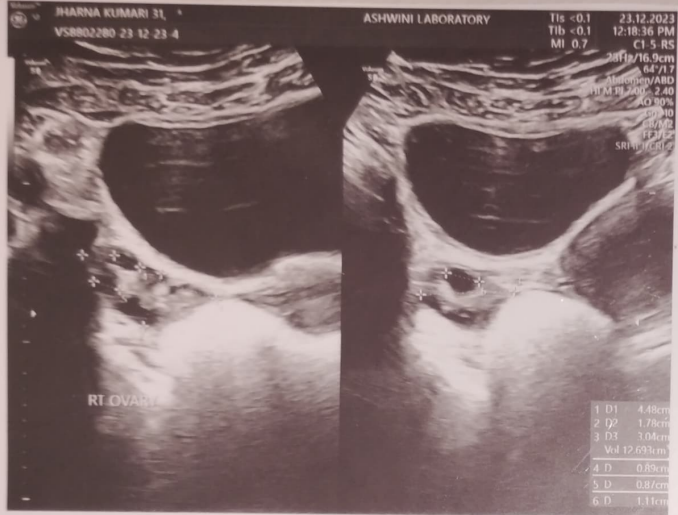


1/2
27.12.2023 10:34:28 AM

Dr. Neftravalakar's

Dr. Ashadevi Neftravalakar



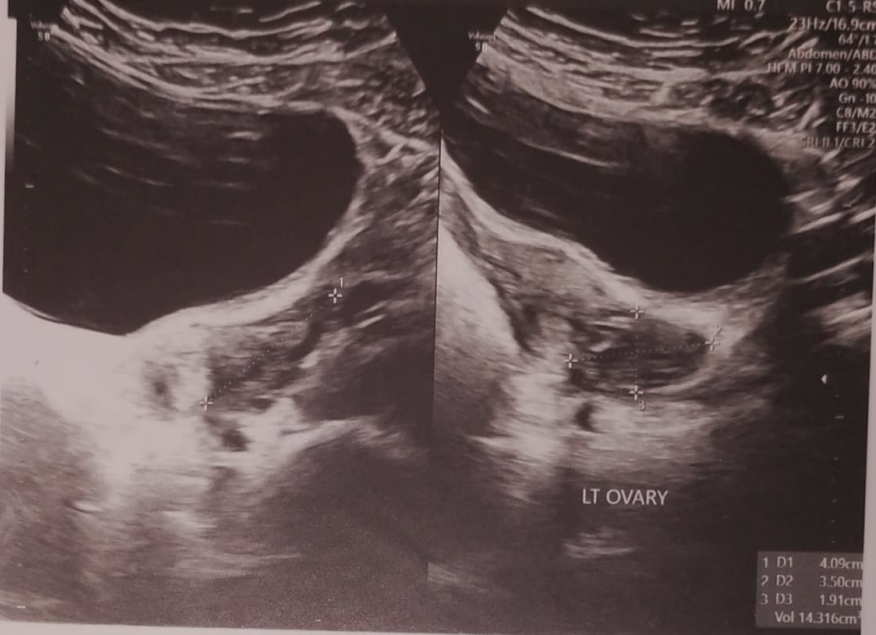




JHARNA KUMARI 31,
VSB802280 23 12 23 4

ASHWINI LABORATORY

TIs <0.1 23.12.2023
TIB <0.1 12:19:10 PM
MI 0.7 C1 5 RS
23Hz/16.9cm
64/717
Abdomen/ABD
MIM PI 7.00 - 2.40
AO 90%
Gr - 10
CB/M2
FF3/E2
RLI1/CRI 2



LT OVARY

1 D1 4.09cm
2 D2 3.50cm
3 D3 1.91cm
Vol 14.316cm

201,202,203, Rizvi Sadan, 2nd Floor, Near Municipal Market, Next to Vaidya Hospital, Panaji - Goa.
Tel.: 0832 2238122 | Email : drashanetravalkar@gmail.com

NAME: MRS.JHARNA KUMARI
AGE: 31/YRS
REF BY: DR.SELF

DATE: 23/12/2023
SEX: F

ULTRASONOGRAPHY OF ABDOMEN AND PELVIS

LIVER – It shows mild increased echotexture and normal size. No focal lesions are seen.

Intrahepatic biliary and portal radicals appear normal. Length of liver is 12.3cm.PV -9mm.

PANCREAS— It shows normal echotexture and size. No focal lesions are seen.

GALL BLADDER---It is moderately distended. No calculus is seen. Pericholecystic space is normal.CBD is normal.

SPLEEN----- It shows normal echotexture and size. Length of spleen is 8.7cm.

BOTH KIDNEYS Both kidneys show normal echotexture and size. Perirenal space is normal.

Corticomedullary differentiation is seen well .No calculus or hydronephrosis is seen .

Right kidney--measures 10cm x 4.6cms .

Left kidney—measures 10.9cms x5.2cms.

Urinary Bladder is well distended .No calculus and mass is seen.Both vesicoureteric junctions are normal.

UTERUS : It is anteverted and It measures 9.1cms x4.8cms x 3.6cms.

Myometrium shows normal echotexture .No mass is seen.Endometrial thickness is 8mm.

Both ovaries show multiple follicles measuring 2mm-5mm at the periphery .


Right ovary—measures 4.4cms x 3cms x1.7cms. Volume is 13ml.

Left ovary -measures 4cms x 3.5cms x1.9cms. Volume is 14ml.

No adnexal mass is seen. No free fluid is seen in pelvis. Plenty of bowel gases are seen.

Impression: Mild fatty liver.
Multicystic ovaries .

With regards,



DR.ASHADEVI NETRAVALKAR,MD
RADIOLOGIST

DR. ASHADEVI NETRAVALKAR
MBBS, MD, AFM
Consultant Radiologist
2nd Floor, Rizvi Sadan Panaji
Tel: 0832-2238122 / 9822125224

201,202,203, Rizvi Sadan, 2nd Floor, Near Municipal Market, Next to Vaidya Hospital, Panaji - Goa.
Tel.: 0832 2238122 | Email : drashanetravalkar@gmail.com

NAME: MRS.JHARNA KUMARI
AGE: 31/YRS
REF BY: DR.SELF

DATE: 23/12/2023
SEX: F

X-RAY CHEST--- PA VIEW

Lung fields are clear.

Both costophrenic angles are clear.


Cardiac size is normal

Both domes of diaphragm are normal.

Rib cage is normal.

IMPRESSION : *Normal study*

With regards,



RADIOLOGIST

DR.ASHADEVI NETRAVALKAR,MD

DR. ASHADEVI NETRAVALKAR

MBBS, MD, AFIH

Consultant Radiologist

2nd Floor, Rizvi Sadan Panaji

Tel: 0832-2238122 / 9822125224

Dr. Netravalkar's Imaging Centre

Dr. Ashadevi Netravalkar

MBBS., MD, AFIH

Consultant Radiologist & Sonologist

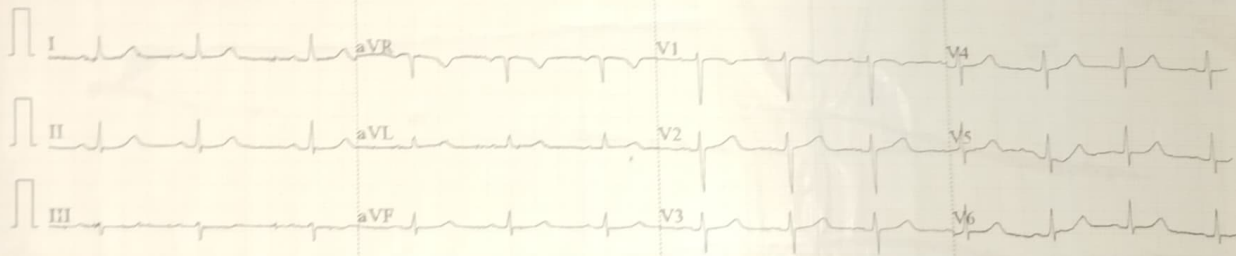
Name : Jharna Kumari
Age : 31 M/F F Date : 23-12-23
Investigation : ECG
Ref. by Dr. : _____

201,202,203, Rizvi Sadan, 2nd Floor, Near Municipal Market,
Next to Vaidya Hospital, Panaji - Goa.

Tel.: 0832 2238122 | Email : drashanetravalkar@gmail.com

Timing : 8.00 am to 1.00 pm | 4.00 pm to 7.00 pm

ID: 3933 23-12-2023 18:51:07




0.5-100Hz 25mm/s 10mm/mV ♥72 V1.0 SEMIP V1.7

ID: 3933

Female / mmHg
31Years
cm kg

HR : 76 bpm
P : 107 ms
PR : 157 ms
QRS : 70 ms
QT/QTc : 386/436 ms
P/QRS/T : 49/20/31 °
RV5/SV1 : 0.611/0.965 mV

ECG is Normal



DR. SIGN.