

CONCLUSION OF HEALTH CHECKUP

ECU Number : 9653
Age : 30
Weight : 50
Date : 24/02/2024

MR Number : 23229238
Sex : Male
Ideal Weight : 71

Patient Name : RONAK MAHESHBHAI
Height : 176
BMI : 16.14

Fit



Dr. Manish Mittal

Internal Medicine

Note : General Physical Examination & routine Investigations included in the Health Checkup have certain limitations and may not be able to detect all the latent and asymptomatic diseases.

ECU Number : 9653 MR Number : 23229238 Patient Name : RONAK MAHESHBHAI
Age : 30 Sex : Male Height : 176
Weight : 50 Ideal Weight : 71 BMI : 16.14
Date : 24/02/2024

Past H/O : NO P/H/O ANY MAJOR ILLNESS

Present H/O : NO MEDICAL COMPLAIN AT PRESENT

Family H/O : NO F/H/O ANY MAJOR ILLNESS

Habits : NO

Gen.Exam. : G.C.GOOD

B.P : 110/80

Pulse : 98

Others : SPO2 99%

C.V.S : NAD

R.S. : NAD

Abdomen : NP

Spleen : NP

Skin : NAD

D.N.S : NAD

Advice :



BHAILAL AMIN GENERAL HOSPITAL

ESTD. 1964



ECU Number : 9653
Age : 30
Weight : 50
Date : 24/02/2024

MR Number : 23229238
Sex : Male
Ideal Weight : 71

Patient Name : RONAK MAHESHBHAI
Height : 176
BMI : 16.14

Ophthalmic Check Up :	Right	Left
Ext Exam		NORMAL
Vision Without Glasses		
Vision With Glasses	6/6 N.5	6/6 N.5
Final Correction	SAME AS OWN	SAME AS OWN
Fundus	NORMAL	
Colour Vision	NORMAL	
Advice	NIL	

Orthopaedic Check Up :

Ortho Consultation

Ortho Advice

ENT Check Up :

Ear

Nose

Throat

Hearing Test

ENT Advice

General Surgery Check Up :

General Surgery

Abdominal Lump

Hernia

External Genitals

PVR

Proctoscopy

Any Other

Surgical Advice





Patient Name : Mr. RONAK MAHESHBHAI PRAJAPATI
 Gender / Age : Male / 30 Years 4 Months 9 Days
 MR No / Bill No. : 23229238 / 242085112
 Consultant : Dr. Manish Mittal
 Location : OPD

Type : OPD
 Request No. : 202443
 Request Date : 24/02/2024 09:03 AM
 Collection Date : 24/02/2024 09:29 AM
 Approval Date : 24/02/2024 02:52 PM

CBC + ESR

Test	Result	Units	Biological Ref. Range
Haemoglobin.			
Haemoglobin	14.9	gm/dL	13 - 17
Red Blood Cell Count (T-RBC)	5.47	mill/cmm	4.5 - 5.5
Hematocrit (HCT)	46.4	%	40 - 50
Mean Corpuscular Volume (MCV)	84.8	fl	83 - 101
Mean Corpuscular Haemoglobin (MCH)	27.2	pg	27 - 32
MCH Concentration (MCHC)	32.1	%	31.5 - 34.5
Red Cell Distribution Width (RDW-CV)	12.0	%	11.6 - 14
Red Cell Distribution Width (RDW-SD)	37.4	fl	39 - 46
Total Leucocyte Count (TLC)			
Total Leucocyte Count (TLC)	10.80	thou/cmm	4 - 10
Differential Leucocyte Count			
Polymorphs	78	%	40 - 80
Lymphocytes	15	%	20 - 40
Eosinophils	01	%	1 - 6
Monocytes	06	%	2 - 10
Basophils	00	%	0 - 2
Polymorphs (Abs. Value)	8.44	thou/cmm	2 - 7
Lymphocytes (Abs. Value)	1.73	thou/cmm	1 - 3
Eosinophils (Abs. Value)	0.06	thou/cmm	0.2 - 0.5
Monocytes (Abs. Value)	0.54	thou/cmm	0.2 - 1
Basophils (Abs. Value)	0.03	thou/cmm	0.02 - 0.1
Immature Granulocytes	0.2	%	1 - 3 : Borderline > 3 : Significant
Platelet Count			
Platelet Count	330	thou/cmm	150 - 410
Remarks	This is counter generated CBC report, smers review is not done		
ESR	8	mm/1 hr	0 - 10

Test Results are dependent on a number of variables & technical limitations. Hence, it is advised to correlate with clinical findings and other related investigations before any firm opinion is made. Recheck / retest may be requested.

365 Days / 24 Hours Laboratory Services

Home Collection Facility Available
(Mon To Sat 8:00 am to 5:00 pm)



BHAILAL AMIN
GENERAL HOSPITAL

📍 Bhailal Amin Marg, Gorwa, Vadodra, Gujarat 390003.

🌐 www.baghospital.com | 📞 : 080 69 70 70 70 | Follow us : 📺 📷

DEPARTMENT OF LABORATORY MEDICINE

Patient Name	: Mr. RONAK MAHESHBHAI PRAJAPATI	Type	: OPD
Gender / Age	: Male / 30 Years 4 Months 9 Days	Request No.	: 202443
MR No / Bill No.	: 23229238 / 242085112	Request Date	: 24/02/2024 09:03 AM
Consultant	: Dr. Manish Mittal	Collection Date	: 24/02/2024 09:29 AM
Location	: OPD	Approval Date	: 24/02/2024 02:52 PM

CBC + ESR

Immature Granulocyte (IG) count is a useful early marker of infection or inflammation, even when other markers are normal. It is an early and rapid discrimination of bacterial from viral infections. It is also increased in patients on steroid therapy / chemotherapy or haematological malignancy. High IG is always pathological; except in pregnancy and neonates of < 7 days.
Method : HB by Non-Cyanide Hemoglobin analysis method. HCT by RBC pulse height detection method. RBC, TLC & PLC are by Particle Count by Electrical Impedance in Cell Counter by Fluorescent flow cytometry using a semi-conductor laser and hydrodynamic focusing in dedicated channels. Optical Platelets by Fluorescent + Laser Technology. MCV, MCH, MCHC, RDW (CV & SD) are calculated parameter. DLC by Flowcytometry method using semi-conductor Laser+Smear verification.

SR on ESL-30, comparable to Westergrens method and in accordance to ICSH reference method.

---- End of Report ----

Dr. Ameer Soni
MD (Path)

Test Results are dependent on a number of variables & technical limitations. Hence, it is advised to correlate with clinical findings and other related investigations before any firm opinion is made. Recheck / retest may be requested.



Patient Name : Mr. RONAK MAHESHBHAI PRAJAPATI
 Gender / Age : Male / 30 Years 4 Months 9 Days
 MR No / Bill No. : 23229238 / 242085112
 Consultant : Dr. Manish Mittal
 Location : OPD

Type : OPD
 Request No. : 202443
 Request Date : 24/02/2024 09:03 AM
 Collection Date : 24/02/2024 09:29 AM
 Approval Date : 24/02/2024 03:44 PM

Haematology

<u>Test</u>	<u>Result</u>	<u>Units</u>	<u>Biological Ref. Range</u>
Blood Group			
ABO system	O		
Rh system	Positive		

By Gel Technology / Tube Agglutination Method

Note :

- This blood group has been done with new sensitive Gel Technology using both Forward and Reverse Grouping Card with Autocontro
- This method check's group both on Red blood cells and in Serum for "ABO" group.

---- End of Report ----

Dr. Ameer Soni
MD (Path)

365 Days / 24 Hours Laboratory Services

Home Collection Facility Available
(Mon To Sat 8:00 am to 5:00 pm)



BHAILAL AMIN
GENERAL HOSPITAL

📍 Bhalal Amin Marg, Gorwa, Vadodara, Gujarat 390003.

🌐 www.baghospital.com | ☎ : 080 69 70 70 70 | Follow us : f @

DEPARTMENT OF LABORATORY MEDICINE

Patient Name : Mr. RONAK MAHESHBHAI PRAJAPATI
Gender / Age : Male / 30 Years 4 Months 9 Days
MR No / Bill No. : 23229238 / 242085112
Consultant : Dr. Manish Mittal
Location : OPD

Type : OPD
Request No. : 202443
Request Date : 24/02/2024 09:03 AM
Collection Date : 24/02/2024 09:29 AM
Approval Date : 24/02/2024 02:52 PM

Fasting Plasma Glucose

Test	Result	Units	Biological Ref. Range
<i>Fasting Plasma Glucose</i>			
Fasting Plasma Glucose	90	mg/dL	70 - 110
Post Prandial 2 Hr. Plasma Glucose	109	mg/dL	70 - 140

By Hexokinase method on EXL Dade Dimension

---- End of Report ----

Dr. Rakesh Vaidya
MD (Path), DCP.

Test Results are dependent on a number of variables & technical limitations. Hence, it is advised to correlate with clinical findings and other related investigations before any firm opinion is made. Recheck / retest may be requested.



Patient Name : Mr. RONAK MAHESHBHAI PRAJAPATI
 Gender / Age : Male / 30 Years 4 Months 9 Days
 MR No / Bill No. : 23229238 / 242085112
 Consultant : Dr. Manish Mittal
 Location : OPD

Type : OPD
 Request No. : 202443
 Request Date : 24/02/2024 09:03 AM
 Collection Date : 24/02/2024 09:29 AM
 Approval Date : 24/02/2024 02:52 PM

HbA1c (Glycosylated Hb)

Test	Result	Units	Biological Ref. Range
HbA1c (Glycosylated Hb)			
Glycosylated Heamoglobin (HbA1c)	5.2	%	
estimated Average Glucose (e AG) *	102.54	mg/dL	

(Method:

By Automated HPLC analyser on D-10 Biorad. NGSP Certified, US-FDA approved, Traceable to IFCC reference method.

* Calculated valued for past 60 days, derived from HbA1c %, based on formula recommended by the A1c - Derived Average Glucose study from ADA and EASD funded The ADAG trial.

Guidelines for Interpretation:

Indicated Glycemic control of previous 2-3 months

HbA1c%	e AG (mg/dl)	Glycemic control
> 8	> 183	Action suggested...High risk of developing long-term complications. Action suggested, depends on individual patient circumstances
7 - 8	154 - 183	Good
< 7	< 154	Goal...Some danger of hypoglycemic reaction in type I Diabetics. Some Glucose intolerant individuals and Sub-Clinical diabetics may demonstrate (elevated) HbA1c in this area.
6 - 7	126 - 154	Near Normal
< 6	< 126	Nondiabetic level)

--- End of Report ---

Dr. Rakesh Vaidya
MD (Path). DCP.



Patient Name : Mr. RONAK MAHESHBHAI PRAJAPATI
 Gender / Age : Male / 30 Years 4 Months 9 Days
 MR No / Bill No. : 23229238 / 242085112
 Consultant : Dr. Manish Mittal
 Location : OPD

Type : OPD
 Request No. : 202443
 Request Date : 24/02/2024 09:03 AM
 Collection Date : 24/02/2024 09:29 AM
 Approval Date : 24/02/2024 02:52 PM

Complete Lipid Profile

Test	Result	Units	Biological Ref. Range
Complete Lipid Profile			
Appearance	Clear		
Triglycerides	105	mg/dL	1 - 150
<i>(Done by Lipase /Glycerol kinase on Vitros 5600)</i>			
<i>< 150 Normal</i>			
<i>150-199 Borderline High</i>			
<i>200-499 High</i>			
<i>> 499 Very High</i>			
Total Cholesterol	178	mg/dL	1 - 200
<i>(Done by Colorimetric - Cholesterol Oxidase, esterase, peroxidase on Vitros 5600.)</i>			
<i><200 mg/dL - Desirable</i>			
<i>200-239 mg/dL - Borderline High</i>			
<i>> 239 mg/dL - High</i>			
HDL Cholesterol	49	mg/dL	40 - 60
<i>(Done by Colorimetric: non HDL precipitation method PTA/MgCl2 on Vitros 5600)</i>			
<i>< 40 Low</i>			
<i>> 60 High</i>			
Non HDL Cholesterol (calculated)	129	mg/dL	1 - 130
<i>(Non- HDL Cholesterol)</i>			
<i>< 130 Desirable</i>			
<i>139-159 Borderline High</i>			
<i>160-189 High</i>			
<i>> 191 Very High</i>			
LDL Cholesterol	117	mg/dL	1 - 100
<i>(Done by Enzymatic (Two Step CHE/CHO/POD) on Vitros 5600)</i>			
<i>< 100 Optimal</i>			
<i>100-129 Near / above optimal</i>			
<i>130-159 Borderline High</i>			
<i>160-189 High</i>			
<i>> 189 Very High</i>			
VLDL Cholesterol (calculated)	21	mg/dL	12 - 30
LDL Ch. / HDL Ch. Ratio	2.39		2.1 - 3.5
T. Ch./HDL Ch. Ratio	3.63		3.5 - 5
<i>(Recent NECP / ATP III Guidelines / Classification (mg/dl) :)</i>			

--- End of Report ---

Dr. Rakesh Vaidya
MD (Path). DCP.



Patient Name : Mr. RONAK MAHESHBHAI PRAJAPATI
 Gender / Age : Male / 30 Years 4 Months 9 Days
 MR No / Bill No. : 23229238 / 242085112
 Consultant : Dr. Manish Mittal
 Location : OPD

Type : OPD
 Request No. : 202443
 Request Date : 24/02/2024 09:03 AM
 Collection Date : 24/02/2024 09:29 AM
 Approval Date : 24/02/2024 03:03 PM

Liver Function Test (LFT)

Test	Result	Units	Biological Ref. Range
Bilirubin			
Bilirubin - Total	1.06	mg/dL	0 - 1
Bilirubin - Direct	0.28	mg/dL	0 - 0.3
Bilirubin - Indirect	0.78	mg/dL	0 - 0.7
<i>(Done by Dual Wavelength - Reflectance Spectrophotometry on Vitros 5600)</i>			
Aspartate Aminotransferase (SGOT/AST)	27	U/L	15 - 40
<i>(Done by Multipoint Rate Colorimetric with P-5-P on Vitros 5600)</i>			
Alanine Aminotransferase (SGPT/ALT)	28	U/L	16 - 63
<i>(Done by Multipoint-Rate/Colorimetric with P-5-P (pyridoxa-5-phosphate) on Vitros 5600)</i>			
Alkaline Phosphatase	74	U/L	53 - 128
<i>(Done by Multipoint-Rate - p-nitrophenyl Phosphate, AMP buffer on Vitros 5600)</i>			
Gamma Glutamyl Transferase (GGT)	17	U/L	15 - 85
<i>(Done by Multipoint Rate - L-γ-glutamyl-p-nitroanilide on Vitros 5600)</i>			
Total Protein			
Total Proteins	8.22	gm/dL	6.4 - 8.2
Albumin	4.85	gm/dL	3.4 - 5
Globulin	3.37	gm/dL	3 - 3.2
A : G Ratio	1.44		1.1 - 1.6
<i>(Done by Biuret endpoint and Bromocresol green method on vitros 5600.)</i>			

---- End of Report ----

Dr. Rakesh Vaidya
MD (Path). DCP.



Patient Name : Mr. RONAK MAHESHBHAI PRAJAPATI
 Gender / Age : Male / 30 Years 4 Months 9 Days
 MR No / Bill No. : 23229238 / 242085112
 Consultant : Dr. Manish Mittal
 Location : OPD

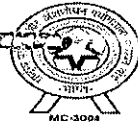Type : OPD
 Request No. : 202443
 Request Date : 24/02/2024 09:03 AM
 Collection Date : 24/02/2024 09:29 AM
 Approval Date : 24/02/2024 02:53 PM

Renal Function Test (RFT)

Test	Result	Units	Biological Ref. Range
Urea (Done by Endpoint/Colorimetric - Urease on Vitros 5600)	13	mg/dL	10 - 45
BUN	6.07	mg/dL	5 - 21
Creatinine (By Modified Kinetic Jaffe Technique)	0.64	mg/dL	0.9 - 1.3
Estimate Glomerular Filtration rate (Ref. range : > 60 ml/min for adults between age group of 18 to 70 yrs. EGFR Calculated by IDMS Traceable MDRD Study equation. Reporting of eGFR can help facilitate early detection of CKD. By Modified Kinetic Jaffe Technique)	More than 60		
Uric acid (Done by Colorimetric - Uricase, Peroxidase on Vitros 5600)	5.2	mg/dL	3.4 - 7.2

---- End of Report ----

Dr. Rakesh Vaidya
MD (Path). DCP.



Patient Name : Mr. RONAK MAHESHBHAI PRAJAPATI
 Gender / Age : Male / 30 Years 4 Months 9 Days
 MR No / Bill No. : 23229238 / 242085112
 Consultant : Dr. Manish Mittal
 Location : OPD

Type : OPD
 Request No. : 202443
 Request Date : 24/02/2024 09:03 AM
 Collection Date : 24/02/2024 09:29 AM
 Approval Date : 24/02/2024 02:53 PM

Thyroid Hormone Study

Test	Result	Units	Biological Ref. Range
Triiodothyronine (T3)	1.53	ng/ml	
<i>(Done by CLIA based method on automated immunoassay Vitros 5600.)</i>			
<i>Reference interval (ng/ml)</i>			
1 - 3 days	: 0.1 - 7.4		
1-11 months	: 0.1 - 2.45		
1-5 years	: 0.1 - 2.7		
6-10 years	: 0.9 - 2.4		
11-15 years	: 0.8 - 2.1		
16-20 years	: 0.8 - 2.1		
Adults (20 - 99 years)	: 1.07 - 1.85		
Pregnancy (in last 5 months)	: 1.2 - 2.5		
<i>(Reference : Tietz - Clinical guide to laboratory test, 4th edition)</i>			
Thyroxine (T4)	9.46	mcg/dL	
<i>(Done by CLIA based method on automated immunoassay Vitros 5600.)</i>			
<i>Reference interval (mcg/dL)</i>			
1 - 3 days	: 11.8 - 22.6		
1 - 2 weeks	: 9.8 - 16.6		
1 - 4 months	: 7.2 - 14.4		
4 - 12 months	: 7.8 - 16.5		
1-5 years	: 7.3 - 15.0		
5 - 10 years	: 6.4 - 13.3		
10 - 20 years	: 5.6 - 11.7		
Adults (20-99 years)	: 5.91 - 12.98		
<i>(Reference : Tietz - Clinical guide to laboratory test, 4th edition)</i>			
Thyroid Stimulating Hormone (US-TSH)	1.08	microIU/ml	
<i>(Done by CLIA based method on automated immunoassay Vitros 5600.)</i>			
<i>Reference interval (microIU/ml)</i>			
Infants (1-4 days)	: 1.0 - 39		
2-20 weeks	: 1.7 - 9.1		
5 months - 20 years	: 0.7 - 6.4		
Adults (20-99 years)	: 0.4001 - 4.049		
Pregnancy :			
1st trimester	: 0.3 - 4.5		
2nd trimester	: 0.5 - 4.6		
3rd trimester	: 0.8 - 5.2		
<i>(Reference : Tietz - Clinical guide to laboratory test, 4th edition)</i>			

Test Results are dependent on a number of variables & technical limitations. Hence, it is advised to correlate with clinical findings and other related investigations before any firm opinion is made. Recheck / retest may be requested.

--- End of Report ---

Dr. Rakesh Vaidya
MD (Path), DCP.



Patient Name : Mr. RONAK MAHESHBHAI PRAJAPATI
 Gender / Age : Male / 30 Years 4 Months 9 Days
 MR No / Bill No. : 23229238 / 242085112
 Consultant : Dr. Manish Mittal
 Location : OPD

Type : OPD
 Request No. : 202443
 Request Date : 24/02/2024 09:03 AM
 Collection Date : 24/02/2024 09:29 AM
 Approval Date : 24/02/2024 02:51 PM

Urine routine analysis (Auto)

Test	Result	Units	Biological Ref. Range
Physical Examination			
Quantity	30	mL	
Colour	Pale Yellow		
Appearance	Clear		
Chemical Examination (By Reagent strip method)			
pH	8.0		
Specific Gravity	1.007		
Protein	Negative	gm/dL	0 - 5
Glucose	Negative	mg/dL	0 - 5
Ketones	Negative		0 - 5
Bilirubin	Negative		Negative
Urobilinogen	Negative		Negative (upto 1)
Blood	Negative		Negative
Leucocytes	Negative		Negative
Nitrite	Negative		Negative
Microscopic Examination (by Microscopy after Centrifugation at 2000 rpm for 10 min or on fully automated Sysmex urine sedimentation analyzer UF4000)			
Red Blood Cells	0 - 1	/hpf	0 - 2
Leucocytes	0 - 1	/hpf	0 - 5
Epithelial Cells	0 - 1	/hpf	0 - 5
Casts	Nil	/lpf	Nil
Crystals	Nil	/hpf	Nil
Mucus	Absent	/hpf	Absent
Organism	Absent		

---- End of Report ----

Dr. Ameer Soni
MD (Path)



**BHAILAL AMIN
GENERAL HOSPITAL**



ADVANCED DIGITAL SOLUTIONS

Computerized Radiography

Ultra Sensitive Colour Doppler

Ultra High Resolution Sonography

Multi-Detector CT Scan

Magnetic Resonance Imaging (MRI)

Mammography

Interventional Radiology

Digital Subtraction Angiography (DSA)

Foetal Echocardiography

Echocardiography

4D USG & Doppler

DEPARTMENT OF DIAGNOSTIC RADIOLOGY

Patient No. : 23229238 . Report Date : 24/02/2024
Request No. : 190104659 24/02/2024 9.03 AM
Patient Name : **Mr. RONAK MAHESHBHAI PRAJAPATI**
Gender / Age : Male / 30 Years 4 Months 9 Days

X-Ray Chest AP

Both lung fields are clear.
Both costophrenic sinuses appear clear.
Heart size is normal.
Hilar shadows show no obvious abnormality.
Aorta is normal.

• ULTRA SONOGRAPHY CANNOT DETECT ALL ABNORMALITIES
• NOT VALID FOR MEDICO-LEGAL PURPOSES
• CLINICAL CORRELATION RECOMMENDED

Dr. Sharad Rungta, M.D DNB

Consultant Radiologist





**BHAILAL AMIN
GENERAL HOSPITAL**



ADVANCED DIGITAL SOLUTIONS

Computerized Radiography

Ultra Sensitive Colour Doppler

Ultra High Resolution Sonography

Multi-Detector CT Scan

Magnetic Resonance Imaging (MRI)

Mammography

Interventional Radiology

Digital Subtraction Angiography (DSA)

Foetal Echocardiography

Echocardiography

4D USG & Doppler

DEPARTMENT OF DIAGNOSTIC RADIOLOGY

Patient No. : 23229238 Report Date : 24/02/2024
Request No. : 190104740 24/02/2024 9.03 AM
Patient Name : **Mr. RONAK MAHESHBHAI PRAJAPATI**
Gender / Age : Male / 30 Years 4 Months 9 Days

USG : Screening for Abdomen (excluding Pelvis) Or Upper Abdomen

Liver is normal in size and echopattern. No mass lesion identified. The hepatic veins are clear and patent.No dilated IHBR.

Gall bladder shows no obvious abnormality. Common bile duct is not dilated.

Pancreas shows no obvious abnormality. Tail obscured.
Spleen is normal in size and echopattern.

Both kidneys are normal in shape and position. Normal echogenicity and cortico medullary differentiation is noted. No hydronephrosis or mass lesion seen.

No ascites.

COMMENT:

No obvious abnormality seen.

Kindly correlate clinically.

• ULTRA SONOGRAPHY CANNOT DETECT ALL ABNORMALITIES
• NOT VALID FOR MEDICO-LEGAL PURPOSES
• CLINICAL CORRELATION RECOMMENDED

Dr.Kaushal V Sheth,
Consultant Radiologist





**BHAILAL AMIN
GENERAL HOSPITAL**



ADVANCED DIGITAL SOLUTIONS

Computerized Radiography

Ultra Sensitive Colour Doppler

Ultra High Resolution Sonography

Multi-Detector CT Scan

Magnetic Resonance Imaging (MRI)

Mammography

Interventional Radiology

Digital Subtraction Angiography (DSA)

Foetal Echocardiography

Echocardiography

4D USG & Doppler

DEPARTMENT OF DIAGNOSTIC RADIOLOGY

Patient No. : 23229238 Report Date : 24/02/2024
Request No. : 190104740 24/02/2024 9.03 AM
Patient Name : **Mr. RONAK MAHESHBHAI PRAJAPATI**
Gender / Age : Male / 30 Years 4 Months 9 Days

USG : Screening for Abdomen (excluding Pelvis) Or Upper Abdomen

• ULTRA SONOGRAPHY CANNOT DETECT ALL ABNORMALITIES
• NOT VALID FOR MEDICO-LEGAL PURPOSES
• CLINICAL CORRELATION RECOMMENDED

Liver is normal in size and echopattern. No mass lesion identified. The hepatic veins are clear and patent.No dilated IHBR.

Gall bladder shows no obvious abnormality. Common bile duct is not dilated.

Pancreas shows no obvious abnormality. Tail obscured.
Spleen is normal in size and echopattern.

Both kidneys are normal in shape and position. Normal echogenicity and cortico medullary differentiation is noted. No hydronephrosis or mass lesion seen.

No ascites.

COMMENT:

No obvious abnormality seen.

Kindly correlate clinically.

Dr.Kaushal V Sheth,
Consultant Radiologist



Patient No. : 23229238 Report Date : 24/02/2024
Request No. : 190104681 24/02/2024 9.03 AM
Patient Name : **Mr. RONAK MAHESHBHAI PRAJAPATI**
Gender / Age : Male / 30 Years 4 Months 9 Days

Echo Doppler Screening

MITRAL VALVE : NORMAL, NO MR, NO MS
AORTIC VALVE : NORMAL, NO AR, NO AS
TRICUSPID VALVE : NORMAL, NO TR, NO PAH
PULMONARY VALVE : NORMAL
LEFT ATRIUM : NORMAL
AORTA : NORMAL
LEFT VENTRICLE : NORMAL LV SIZE AND SYSTOLIC FUNCTION LVEF -- 65%, NO
RESTING REGIONAL WALL MOTION ABNORMALITY
RIGHT ATRIUM : NORMAL
RIGHT VENTRICLE : NORMAL
I.V.S. : INTACT
I.A.S. : INTACT
PULMONARY ARTERY : NORMAL
PERICARDIUM : NORMAL
COLOUR/DOPPLER FLOW MAPPING : NO MR // AR // TR, NO PAH

FINAL CONCLUSION:

1. NORMAL SIZED ALL CARDIAC CHAMBERS, NO LVH
2. NORMAL LV SYSTOLIC FUNCTION, LVEF -- 65%
3. NO RESTING REGIONAL WALL MOTION ABNORMALITY
4. NORMAL DIASTOLIC FUNCTION
5. NORMAL RIGHT HEART SIZE AND RV PRESSURES
6. NORMAL CARDIAC VALVES, NO MITRAL // AORTIC STENOSIS
7. NO PERICARDIAL EFFUSION, CLOT OR VEGETATION SEEN, SR+.

Dr. KILLOJ KANERIA, D.M., CARD.

Name: Mr. Ronak M. Prajapati
Patient ID: ECU/23229238

24.02.2024 12:35:40
Standard 12-Lead

BHAJAL AMIN GENERAL HOSPITAL

Age: 030Y
Gender: Male

Ref: phys

HR: 98 bpm

RR: 611 ms
P: 92 ms
PR: 145 ms

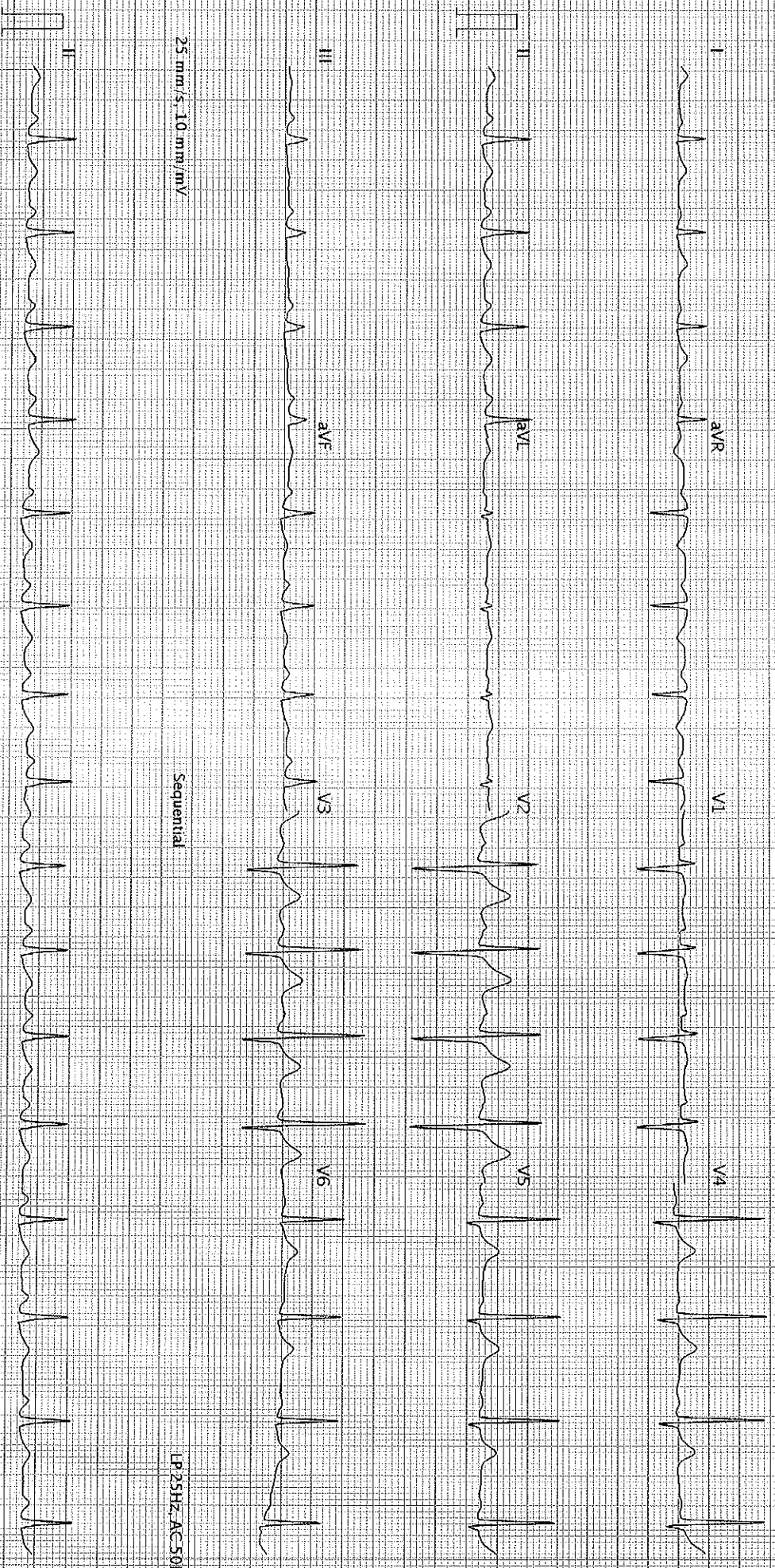
Unconfirmed report

Pacemaker: Unknown

P axis: 64°
QRS axis: 57°
T axis: 32°

QRS: 83 ms
QT: 329 ms
QTcB: 421 ms

Remark:



25 mm/s, 10 mm/mV

Sequential

LP 25Hz, AC 50Hz

25 mm/s, 10 mm/mV

LP 25Hz, AC 50Hz

AT 102-G2-I-2-0 (1080:011030)

BHAJAL AMIN GENERAL HOSPITAL Printed on 24.02.2024 12:35:57

Page 1 of 1

SCHILLER

Part No.2.157048M C6 0123

SBD