

ID: 212 CASE: 1
AGE: 32 Y 0M 08D
167 Cms 81K9

DIIRAJ KUMAR
MALE

23/04/2022 09:42:51
ALC ADVANCE IMAGING DIAGNOSTICS
E95 PC COLONY KANKARBAGH PATNA

RATE : 83 bpm SINUS RHYTHM
R-R : 716 ms LEAD(S) UNSUITABLE FOR ANALYSIS: V1
P-R : 160 ms POOR R WAVE PROGRESSION
QRS : 84 ms
QT : 352 ms
QTc : 392 ms

--AXIS--
P : 45°
QRS : 47°
T : 29°

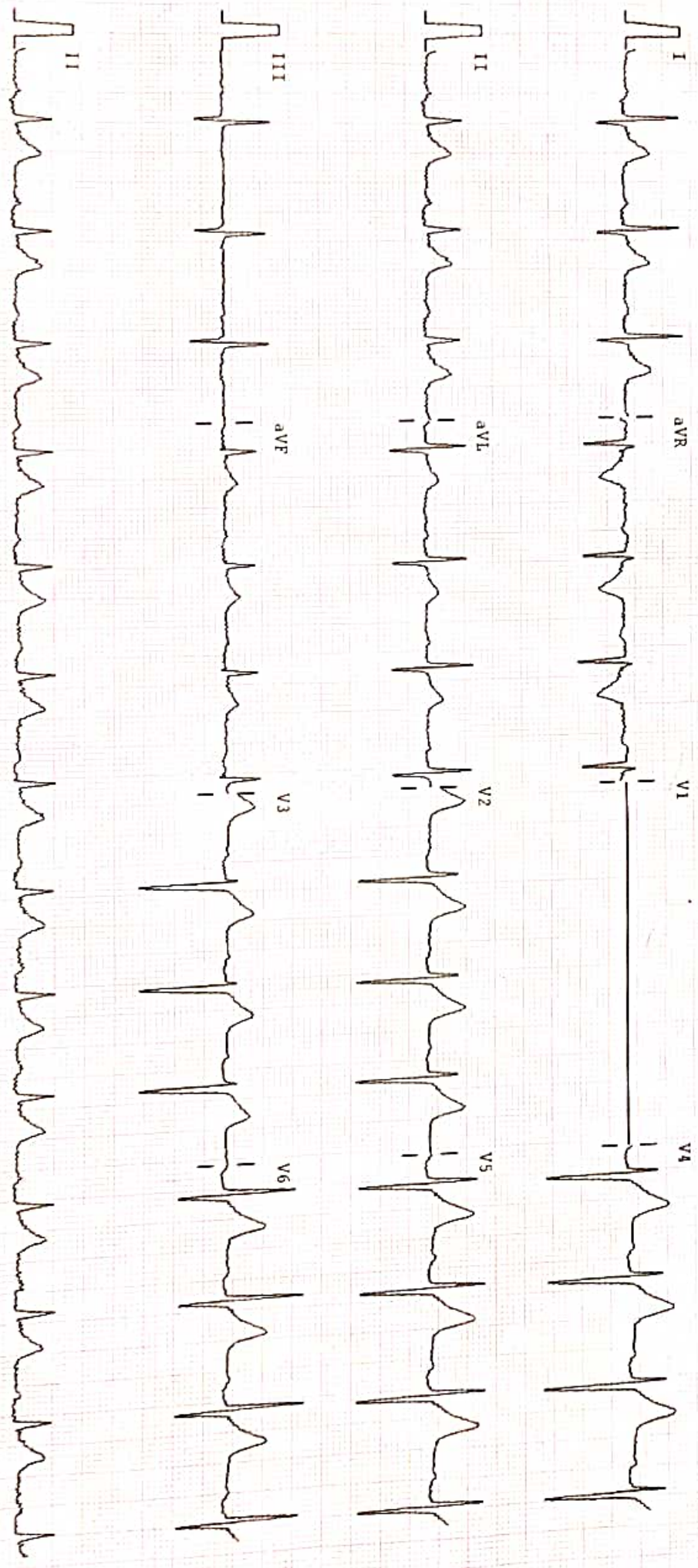
12 SL: REPORT FORMAT: 3x4+1L SQ

REF: DR MEDHHEEL

DR. DR ABHISHEK KUMAR MBBS MD



Dr. Abhishek Kumar
MBBS, MD





A.L.C. Advance Imaging Diagnostics

ISO 9001:2015 Certified center

(A Unit of P.K.Arogyam Health & Wellness Center)

E-95, P.C. Colony, Near Sai Netryalaya Transformer, Kankarbagh, Patna - 20

alcdiagnostics@gmail.com

www.pkarogyamhealthcheckup.com

7050037694, 8271206196

OPINION MUST BE CORRELATES WITH CLINICALLY & OTHER INVESTIGATION FOR FINAL DIAGNOSIS. NOT FOR MEDICO LEGAL PURPOSE

PATIENT NAME : Mr. KUMAR DHIRAJ

PATIENT ID: 212

COL DATE : 24/04/2022 REPORTING DATE: 24/04/2022 AGE SEX : 32 YRS/M

REF.BY : DR. /MEDIWHEEL.

TEST NAME	RESULT	Unit	REF.RANGE
BLOOD SUGAR (F)	91.0 mg/dl		70 - 110 mg/dl
BLOOD SUGAR (PP)	113.0 mg/dl		70 - 140 mg/dl

LIPID PROFILE:-

TOTAL CHOLESTROL	172.1 mg/dl		130 -250 mg/dl
TRIGLYCERIDE	112.4 mg/dl		50 -160 mg/dl
HDL CHOLESTROL	44.0 mg/dl		30 - 60 mg/dl
LDL CHOLESTROL	105.7 mg/dl		80 -130 mg/dl
VLDL CHOLESTROL	22.4 mg/dl		15 - 40 mg/dl
T.CH./HDL RATIO	3.9:1		Upto 5:1
LDL./HDL RATIO	2.4:1		2 - 4:1



Dr. Ankur Kumar
MBBS, MD
Consultant Pathologist
Reg No 50840

Consultant Radiologist

ESTD BY:-

Dr. P. K. Tiwari

MD, M.Sc (Radio Imaging)

Ph.D (Alt Nuclear Medicine)

Consultant Imaginologist & Sonologist

Dr. S. Kumar

MD (Pat)

Consultant Pathologist

Dr. Abhishek Kumar

MBBS, MD

Consultant Neuropathology Physiologist

Dr. Anjali

MBBS, MD

Consultant(TMT,EEG Specialist)

Dr. Kumari Suman

MBBS, DGO, MD

Consultant (TVS & HSG Specialist)

PRINTING MISTAKE SHOULD BE REPORTED BACK IMMEDIATELY/यहाँ जन्म से पहले भ्रुण का लिंग जाँच नहीं होता है ।



A.L.C. Advance Imaging Diagnostics

ISO 9001:2015 Certified center

(A Unit of P.K.Arogyam Health & Wellness Center)

E-95, P.C. Colony, Near Sai Netryalaya Transformer, Kankarbagh, Patna - 20

alcdiagnostics@gmail.com

www.pkarogayamhealthcheckup.com

7050037694, 8271206196

OPINION MUST BE CORRELATES WITH CLINICALLY & OTHER INVESTIGATION FOR FINAL DIAGNOSIS. NOT FOR MEDICO LEGAL PURPOSE

PATIENT NAME : Mr. KUMAR DHIRAJ

PATIENT ID: 212

COL DATE : 24/04/2022 REPORTING DATE: 24/04/2022 AGE SEX:- 32 YRS/F

REF.BY : DR./ MEDIWHEEL.

TEST NAME	RESULT	Unit	REF.RANGE
LFT:-			
SGPT	27.7 IU/L		5 - 48 IU/L
SGOT	19.8 IU/L		5 - 40 IU/L
ALKALINE PHOSPHATASE	91.0 IU/L		25 - 147 IU/L
TOTAL PROTIN	7.8 g/dl		6.0 - 8.7 g/dl
SERUM ALBUMIN	4.9 g/dl		3.5 - 5.4 g/dl
SERIUM GLUBLINE	2.9 g/dl		2.3 - 3.6 g/dl
AG RATIO	1.6 : 1		1.0 - 2.3 g/dl
BILIRUBIN			
TOTAL	0.70 mg/dl		0.1 - 1.1 mg/dl
IRECT	0.22 mg/dl		0.0 - 0.32 mg/dl
INDIRECT	0.48 mg/dl		0.0 - 0.78 mg/dl
KFT/RFT			
URIC ACID	4.4 mg/dl		3.2 - 7.0 mg/dl
SERUM CREATNINE	1.0 mg/dl		0.6 - 1.5 mg/dl
BLOOD URIA	29.9 mg/dl		5 - 45 mg/dl
BLOOD URIA NITROZEN(BUN).	13.9 mg/dl		13 - 39 mg/dl



Dr. Ankur Kumar
MBBS, MD
Consultant Pathologist
Reg No. 30540
Consultant Radiologist

ESTD BY:-

Dr. P. K. Tiwari
MD, M.Sc (Radio Imaging)
Ph.D (Art Nuclear Medicine)
Consultant Imagiologist & Sonologist

Dr. S. Kumar
MD (Pat)
Consultant Pathologist

Dr. Abhishek Kumar
MBBS, MD
Consultant Neuropathology Physiologist

Dr. Anjali
MBBS, MD
Consultant(TMT,EEG Specialist)

Dr. Kumari Suman
MBBS, DGO, MD
Consultant (TVS & HSG Specialist)

PRINTING MISTAKE SHOULD BE REPORTED BACK IMMEDIATELY/ यहाँ जन्म से पहले भ्रुण का लिंग जाँच नहीं होता है ।



A.L.C. Advance Imaging Diagnostics

ISO 9001:2015 Certified center

(A Unit of P.K.Arogyam Health & Wellness Center)

E-95, P.C. Colony, Near Sai Netryalaya Transformer, Kankarbagh, Patna - 20

alcdiagnostics@gmail.com

www.pkarogyamhealthcheckup.com

7050037694, 8271206196

OPINION MUST BE CORRELATES WITH CLINICALLY & OTHER INVESTIGATION FOR FINAL DIAGNOSIS. NOT FOR MEDICO LEGAL PURPOSE

PATIENT NAME : Mr. KUMAR DHIRAJ

PATIENT ID: 212

COL DATE : 24/04/2022 REPORTING DATE: 24/04/2022 AGE SEX:- 32 YRS/M

REF.BY : DR. / MEDIWHEEL

TEST NAME	RESULT	Unit	REF.RANGE
ESR	8 mm/hr		<20 mm/hr
CBC			
Total W.B.C. Count	8000 /cumm		4000-11,000 /cumm
R B C COUNT	4.34 Million/ CUmm		4 - 7 Million/ CUmm
Platelets count	1.65 Lakh/ cumm		1.5-5.0 Lakh/ cumm
Differential Count of W.B.C.			
Neutrophils	59 %		40-70%
Lymphocytes	36 %		25-40%
Eosinophils	04 %		01-05%
Mnonocytes	01 %		00-02%
Basophiles	00 %		00-0%
HAEMOGLOBIN	14.7 gm/dl (100.6 %)		14.6 gm/dl = 100%
PCV	42.0 %		35-47 %
MCV	96.7 fl		76-96 fl
MCH	33.8 pg		29-35 pg
MCHC	35.0 %		30-38 %



Dr. Ankur Kumar
MBBS, MD
Consultant Pathologist
Reg No 35540

ESTD BY:-

Consultant Radiologist

Dr. P. K. Tiwari

MD, M Sc (Radio Imaging)
Ph.D (AI Nuclear Medicine)
Consultant Imagnonologist & Sonologist

Dr. S. Kumar

MD (Pat)
Consultant Pathologist

Dr. Abhishek Kumar

MBBS, MD
Consultant Neuropatho Physiologist

Dr. Anjali

MBBS, MD
Consultant(TMT,EEG Specialist)

Dr. Kumari Suman

MBBS, DGO, MD
Consultant (TVS & HSG Specialist)

PRINTING MISTAKE SHOULD BE REPORTED BACK IMMEDIATELY/ यहाँ जन्म से पहले भ्रुण का लिंग जाँच नहीं होता है ।



A.L.C. Advance Imaging Dignostics

ISO 9001:2015 Certified center

(A Unit of P.K.Arogyam Health & Wellness Center)

E-95, P.C. Colony, Near Sai Netryalaya Transformer, Kankarbagh, Patna - 20

alcdiagnostics@gmail.com

www.pkarogayamhealthcheckup.com

7050037694, 8271206196

OPINION MUST BE CORRELATES WITH CLINICALLY & OTHER INVESTIGATION FOR FINAL DIAGNOSIS. NOT FOR MEDICO LEGAL PURPOSE

PATIENT NAME : Mr. KUMAR DHIRAJ

PATIENT ID : 212

COL DATE : 24/04/2022 REPORTING DATE: 24/04/2022 AGE SEX : 32 YRS/M

REF.BY : DR./ MEDIWHEEL.

GLYCOSYLATED HEMOGLOBIN

TEST NAME	RESULT	Unit	REF.RANGE
HbA1c	3.7 %		Below 5.7 % : Normal 5.7 – 6.4 % : Prediabetic > = 6.5 % : Diabetic
AVERAGE PLASMA GLUCOSE	89.0 mg/dl		90 – 120 mg/dl : Good Control 121 – 150 mg/dl : Fair Control 151- 180 mg/dl: Unsatisfactory Control >180 mg/dl : Poor Control



ESTD BY-

Dr. P. K. Tiwari

MD, M.Sc (Radio Imaging)
Ph.D (AI: Nuclear Medicine)
Consultant Imaginologist & Sonologist

Dr. S. Kumar

MD (Pat)
Consultant Pathologist

Dr. Abhishek Kumar

MBBS, MD
Consultant Neuropatho Physiologist

Dr. Anjali

MBBS, MD
Consultant(TMT, EEG Specialist)

Dr. Kumari Suman

MBBS, DGO, MD
Consultant (TVS & HSG Specialist)

Consultant Radiologist

PRINTING MISTAKE SHOULD BE REPORTED BACK IMMEDIATELY/ यहाँ जन्म से पहले भ्रुण का लिंग जाँच नहीं होता है ।



A.L.C. Advance Imaging Dignostics

ISO 9001:2015 Certified center

(A Unit of P.K.Arogyam Health & Wellness Center)

E-95, P.C. Colony, Near Sai Netryalaya Transformer, Kankarbagh, Patna - 20

alcdiagnostics@gmail.com

www.pkarogayamhealthcheckup.com

7050037694, 8271206196

OPINION MUST BE CORRELATES WITH CLINICALLY & OTHER INVESTIGATION FOR FINAL DIAGNOSIS. NOT FOR MEDICO LEGAL PURPOSE

PATIENT NAME : Mr. KUMAR DHIRAJ

PATIENT ID: 212

COL DATE : 24/04/2022 REPORTING DATE: 24/04/2022 AGE SEX:- 32 YRS/M

REF.BY : DR / MEDIWHEAL

TEST NAME	RESULT	Unit	REF.RANGE
Total Triiodothyronin T3	1.14	ng/mL	0.80 -2.00 ng/mL
Total Thyroxin T4	9.01	µg/dL	5.10 -14.10 µg/dL
Serum TSH	2.74	µIU/mL	0.27 - 4.20 µIU/mL

THYROID DISORDER (>: Increase: < Decrease: n Normal

1. T3(n) T4(n) TSH(n) :EUTHYROID STATE:
 2. T3(>) T4(>) TSH(<): HYPERTHYROIDISM:
 3. T3(<)T4(<) TSH(>): HYPOTHYROIDISM:
 4. T3(n)T4(n) TSH(>) : SUB-CLINICAL HYPO-THYROIDISM:
 5. T3(n)T4(n) TSH(<): SUB-CLINICAL HYPER-THYROIDISM:
 6. T3(>) T4(n) TSH(<): T3 THYROTOXICOSIS:
- Total T3/T4 level is dependent on Level:

So determination of free T3/T4is a better MARKER of Thyroid Function.



Dr. Ankur Kumar
MBBS, MD
Consultant Pathologist
Reg No. 19540

Consultant Radiologist

ESTD BY:-

Dr. P. K. Tiwari
MD, M.Sc (Radio Imaging)
Ph.D (Art Nuclear Medicine)
Consultant Imaginologist & Sonologist

Dr. S. Kumar
MD (Pat)
Consultant Pathologist

Dr. Abhishek Kumar
MBBS, MD
Consultant Neuropatho Physiologist

Dr. Anjali
MBBS, MD
Consultant (TMT, EEG Specialist)

Dr. Kumari Suman
MBBS, DGO, MD
Consultant (TVS & HSG Specialist)

PRINTING MISTAKE SHOULD BE REPORTED BACK IMMEDIATELY/ यहाँ जन्म से पहले भ्रुण का लिंग जाँच नहीं होता है ।



A.L.C. Advance Imaging Diagnostics

ISO 9001:2015 Certified center

(A Unit of P.K.Arogyam Health & Wellness Center)

E-95, P.C. Colony, Near Sai Netryalaya Transformer, Kankarbagh, Patna - 20

alcdiagnostics@gmail.com

www.pkarogayamhealthcheckup.com

7050037694, 8271206196

OPINION MUST BE CORRELATES WITH CLINICALLY & OTHER INVESTIGATION FOR FINAL DIAGNOSIS. NOT FOR MEDICO LEGAL PURPOSE

PATIENT NAME : Mr. KUMAR DHIRAJ PATIENT ID: 212
COL DATE : 24/04/2022 REPORTING DATE: 24/04/2022 AGE SEX:- 32 YRS/M
REF.BY : DR. / MEDIWHEEL.

TEST NAME	RESULT	Unit	REF.RANGE
BLOOD GROUP	: 'A'		
Rh Typing	: POSITIVE		

Note: Do always cross – matching before blood transfusion



Dr. Ankur Kumar
MBBS, MD
Consultant Pathologist
Reg No 39540

Consultant Radiologist

ESTB BY:-

Dr. P. K. Tiwari
MD, M.Sc (Radio Imaging)
Ph.D (AIH Nuclear Medicine)
Consultant Imagiologist & Sonologist

Dr. S. Kumar
MD (Pat)
Consultant Pathologist

Dr. Abhishek Kumar
MBBS, MD
Consultant Neuropatho Physiologist

Dr. Anjali
MBBS, MD
Consultant(TMT,EEG Specialist)

Dr. Kumari Suman
MBBS, DGO, MD
Consultant (TVS & HSG Specialist)

PRINTING MISTAKE SHOULD BE REPORTED BACK IMMEDIATELY/ यहाँ जन्म से पहले भ्रुण का लिंग जाँच नहीं होता है ।



A.L.C. Advance Imaging Dignostics

ISO 9001:2015 Certified center

(A Unit of P.K.Arogyam Health & Wellness Center)

E-95, P.C. Colony, Near Sai Netryalaya Transformer, Kankarbagh, Patna - 20

alcdiagnostics@gmail.com

www.pkarogyamhealthcheckup.com

7050037694, 8271206196

OPINION MUST BE CORRELATES WITH CLINICALLY & OTHER INVESTIGATION FOR FINAL DIAGNOSIS. NOT FOR MEDICO LEGAL PURPOSE

PATIENT NAME : Mr . KUMAR DHIRAJ PATIENT ID: 212
 COL DATE : 24/04/2022 REPORTING DATE: 24/04/2022 AGE SEX:- 32 YRS/M
 REF.BY : DR. / MEDIWHEEL.

ROUTINE EXAMINATION OF URINE

PHYSICAL EXAMINATION

Quantity	40 ml	Colour... .	Straw
Appearance...	Clear	Sediment ...	Nil
Specific gravity....	1.010		

CHEMICAL EXAMINATION

Reaction	6.0	Nitrite.....	Not done
Sugar	Nil	Bile Pigment	Not done
Albumin	Nil	Urobilinogen....	Not done
Excess of Phosphate....	Nil	Chile.....	Not done
Bile Salt	Not Done	Acetone...	Not done

MICROSCOPIC EXAMINATION

Erythrocytes....	Nil	Casts	Nil
Leucocytes	1-4 / HPE	Crystals....	Nil
Epith. Cell	A, Few	Others	Nil



Dr. Ankur Kumar
 MBBS, MD
 Consultant Pathologist
 Reg No 39540
 Consultant Radiologist

ESTB BY:-

Dr. P. K. Tiwari
 MD, M.Sc (Radio Imaging)
 Ph D (Air Nuclear Medicine)
 Consultant Imagonologist & Sonologist

Dr. S. Kumar
 MD (Pat)
 Consultant Pathologist

Dr. Abhishek Kumar
 MBBS, MD
 Consultant Neuropatho Physiologist

Dr. Anjali
 MBBS, MD
 Consultant(TMT,EEG Specialist)

Dr. Kumari Suman
 MBBS, DGO, MD
 Consultant (TVS & HSG Specialist)

PRINTING MISTAKE SHOULD BE REPORTED BACK IMMEDIATELY/ यहाँ जन्म से पहले भ्रुण का लिंग जाँच नहीं होता है ।



A.L.C. Advance Imaging Diagnostics

ISO 9001:2015 Certified center

(A Unit of P.K.Arogyam Health & Wellness Center)

E-95, P.C. Colony, Near Sai Netryalaya Transformer, Kankarbagh, Patna - 20

alcdiagnostics@gmail.com

www.pkarogyamhealthcheckup.com

7050037694, 8271206196

OPINION MUST BE CORRELATES WITH CLINICALLY & OTHER INVESTIGATION FOR FINAL DIAGNOSIS. NOT FOR MEDICO LEGAL PURPOSE

ECHOCARDIOGRAPHY & COLOR DOPPLER REPORT

Patient's Name : Mr.DHIRAJ KUMAR

Age/Sex : 32 Yrs /M

Ref. by : DR BOB

Date : 23-Apr-22

ECHOCARDIOGRAPHIC WINDOW: Fair

2D & M MODE ECHOCARDIOGRAPHY

Left ventricle

EDD:	32	mm (20 - 28 mm / m ²)	ESD:	21	mm(13 - 21 mm / m ²)
IVS :	11	mm (6 - 11 mm)	PW:	8	mm(6 - 11 mm)
Ejection fraction:	60% (61 ± 8%)		FS:	35	%(34 - 44 %)
IVS:	Intact		LV clot	Absent	

Left atrium/ Aorta 35/31 mm

Right ventricle Normal

Right atrium Normal

Pericardium Normal with no pericardial effusion

2D:

Normal LA/LV Size and normally contracting left ventricle. No RWMA, concentric LVH

Mitral valve

AML/ PML: Normal

Tricuspid valve Normal

Aortic valve Normal

Pulmonary valve Normal



Continuous & Pulse Wave Doppler study

Valve	Velocity (m/sec)			Gradient (mmHg)			Valve area (PHT Method)	Regurg.
	Peak	Mean	EDV	Peak	Mean	EDG		
Mitral	E=07 A=0.6			2.3	2.0			Nil
Tricuspid	E=0.5 A=0.3			1.9	0.2			Nil
Aortic	1.12			5.0	2.5			Nil
Pulmonary	0.9			3.5	1.7			Nil

ESTB BY:-

Consultant Radiologist

Dr. P. K. Tiwari

MD, M.Sc (Radio Imaging)
Ph.D (AIH Nuclear Medicine)
Consultant Imagingologist & Sonologist

Dr. S. Kumar

MD (Pat)
Consultant Pathologist

Dr. Abhishek Kumar

MBBS, MD
Consultant Neuropatho Physiologist

Dr. Anjali

MBBS, MD
Consultant(TMT,EEG Specialist)

Dr. Kumari Suman

MBBS, DGO, MD
Consultant (TVS & HSG Specialist)

PRINTING MISTAKE SHOULD BE REPORTED BACK IMMEDIATELY/यहाँ जन्म से पहले भुण का लिंग जाँच नहीं होता है ।

P.K.A.C. Advance Imaging Dignostics

ISO 9001:2015 Certified center

(A Unit of P.K.Arogyam Health & Wellness Center)

E-95, P.C. Colony, Near Sai Netryalaya Transformer, Kankarbagh, Patna - 20

pkadiagnostics@gmail.com

www.pkarogyamhealthcheckup.com

7050037694, 8271206196

OPINION MUST BE CORRELATES WITH CLINICALLY & OTHER INVESTIGATION FOR FINAL DIAGNOSIS. NOT FOR MEDICO LEGAL PURPOSE

Colour Flow Imaging

No TR, No MR/PR, No AR

No flow shunt

COMMENTS :

- ◆ Normal size all chamber
- ◆ Normal LV filling Pressure
- ◆ No RWMA
- ◆ Normal LV systolic function
- ◆ Grade I LV diastolic dysfunction.
- ◆ Global LVEF = 60%
- ◆ All cardiac valves are normal
- ◆ No PAH, Mild concentric LVH
- ◆ No MS / TS / AS / PS / PR
- ◆ No clot / vegetation / pericardial effusion.

IMPRESSION:

All chambers are normal

No RWMA, No PAH

Grade I LV diastolic dysfunction.

Normal LV systolic function, LVEF – 60%



Please correlate clinically

DR. SANDEEP KUMAR MBBS MD

ESTD BY:-

Consultant Radiologist

Dr. P. K. Tiwari

MD, M.Sc (Radio Imaging)

Ph.D (Air Nuclear Medicine)

Consultant Imaginologist & Sonologist

Dr. S. Kumar

MD (Pat)

Consultant Pathologist

Dr. Abhishek Kumar

MBBS, MD

Consultant Neuropatho Physiologist

Dr. Anjali

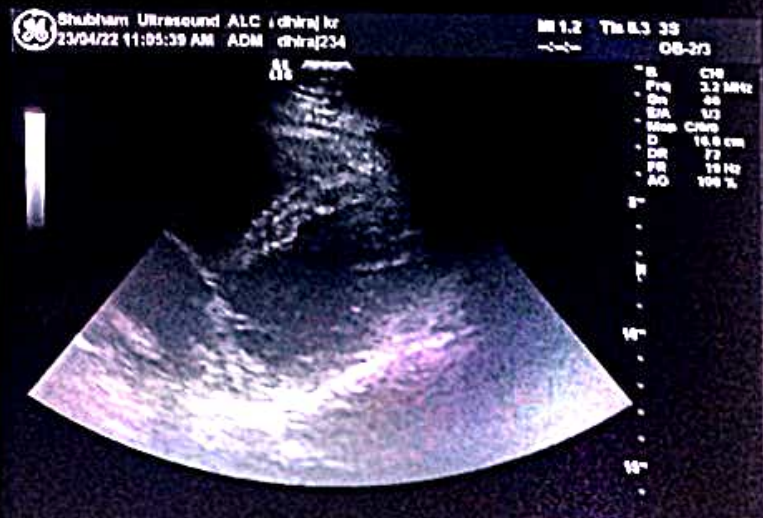
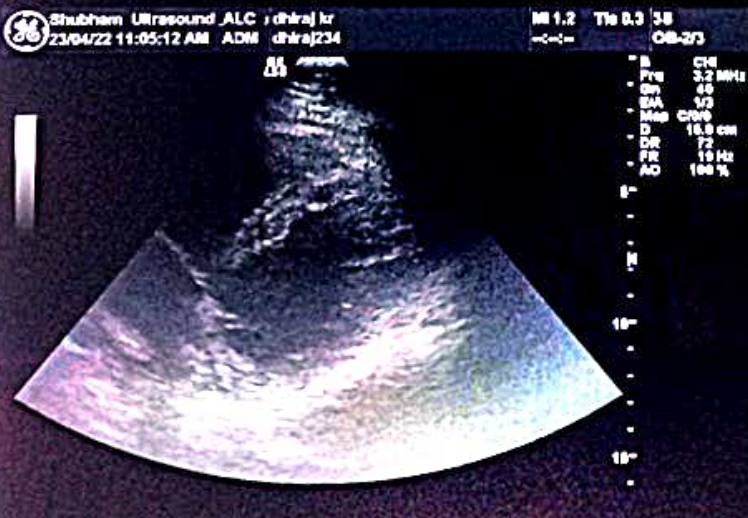
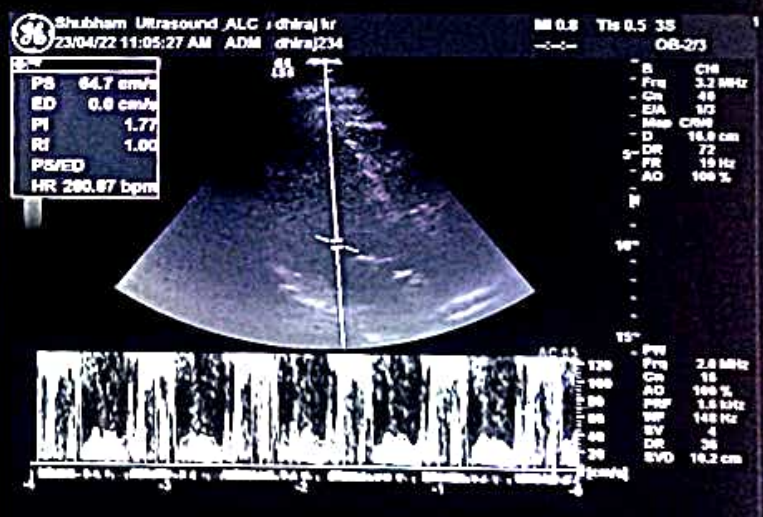
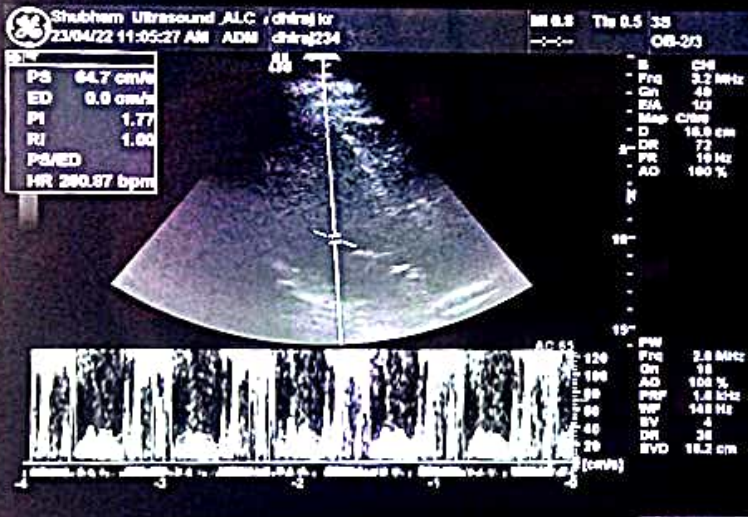
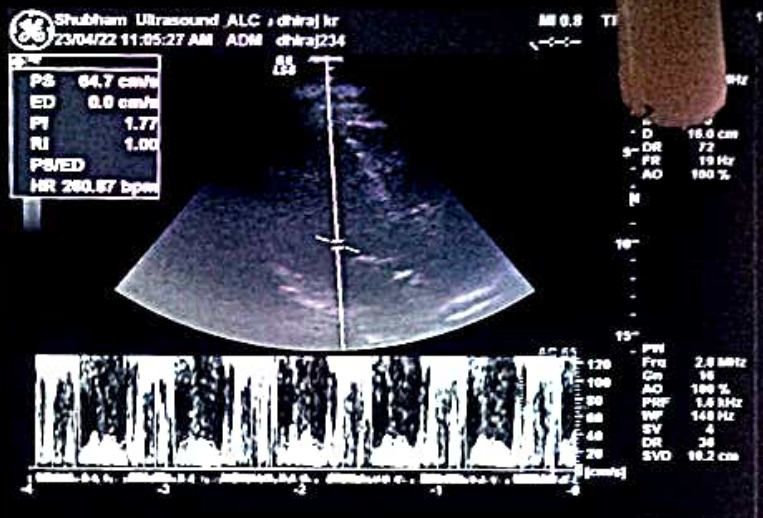
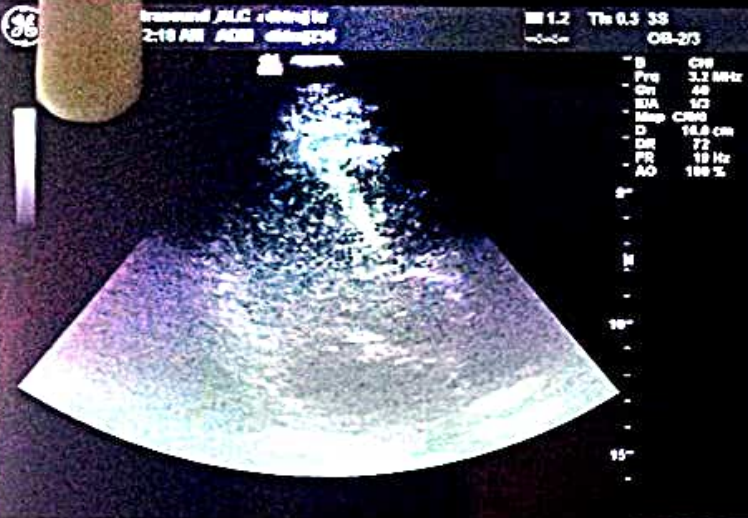
MBBS, MD

Consultant(TMT,EEG Specialist)

Dr. Kumari Suman

MBBS, DGO, MD

Consultant (TVS & HSG Specialist)





A.L.C. Advance Imaging Diagnostics

ISO 9001:2015 Certified center

(A Unit of P.K.Arogyam Health & Wellness Center)

E-95, P.C. Colony, Near Sai Netryalaya Transformer, Kankarbagh, Patna - 20

alcdiagnostics@gmail.com

www.pkarogyamhealthcheckup.com

7050037694, 8271206196

OPINION MUST BE CORRELATES WITH CLINICALLY & OTHER INVESTIGATION FOR FINAL DIAGNOSIS. NOT FOR MEDICO LEGAL PURPOSE

Pt. Name :- **DIHRAJ KUMAR**
Ref. By :- **DR /MEDIWHEEL**

Date:- **23-Apr-22**
Age / Sex - **48 Yrs. M.**

REAL TIME U.S.G. OF WHOLE ABDOMEN

Thanks for your kind referral

(Report.)

- LIVER** :- Measures 16.57 cm. Mild Enlarged in shape , size and echo texture fatty change seen in liver parenchyma .I.H.B.R. are not dilated.
Hepatic veins are normal. No SOL seen.
- G.BL. :- Lumen is echo free. Wall thickness appears normal.
- C.B.D. :- Measures 3.5 mm in diameter with echo free lumen. No calculi or mass seen.
- P.V. :- Measures 7.7 mm in diameter. Appears normal. No thrombus seen.
- PANCREAS :- Normal in shape, size and echo texture. No calcification mass seen.
- SPLEEN :- Measures 10.59 cm. Normal in shape, size and echo texture.
No SOL seen.
- KIDNEY** :- Both kidney shows normal shape, size & echotexture. C.M.D.intact.
P.C.S.is not dilated.
Right Kidney :- Measures 9.50 X 3.50 cm.
Left Kidney :- Measures 9.60 X 3.50 cm.
- URETER :- Not dilated .No apparent calculi seen.
- U.BLADDER:- Shows normal in outline with echo free lumen. No calculi or mass seen.
Pre void -320 ml. Post void - is in significant
- PROSTATE** :- Measures 15 gms.(approx). Appears Normal in size, shape, and echo texture.
No calcification , mass ,growth seen. capsule is intact.
- R.I.F. :- Son graphically no appendicular mass or collection seen.
- OTHERS** :- No Ascites . no Lymph Adenopathy. No pleural effusion seen on either side .

IMPRESSION

- **Mild Hepatomegaly With fatty liver G-I**
- **Adv:- Further work up other investigation**
Otherwise son graphically normal scan. of rest organs



Dr. Abhishek Kumar
MBBS, MD
Consultant (TMT, EEG Specialist)
Reg-23/44/22
Consultant Radiologist

ESTD BY:-

Dr. P. K. Tiwari
MD, M.Sc (Radio Imaging)
Ph.D (Altr Nuclear Medicine)
Consultant Imagonologist & Sonologist

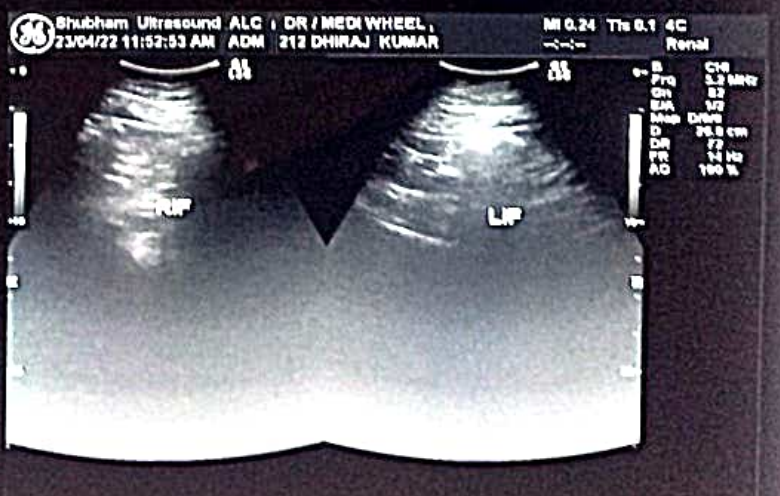
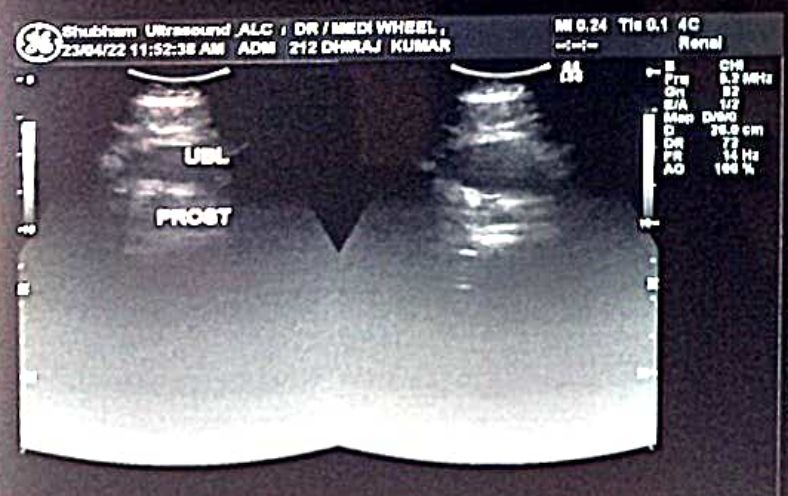
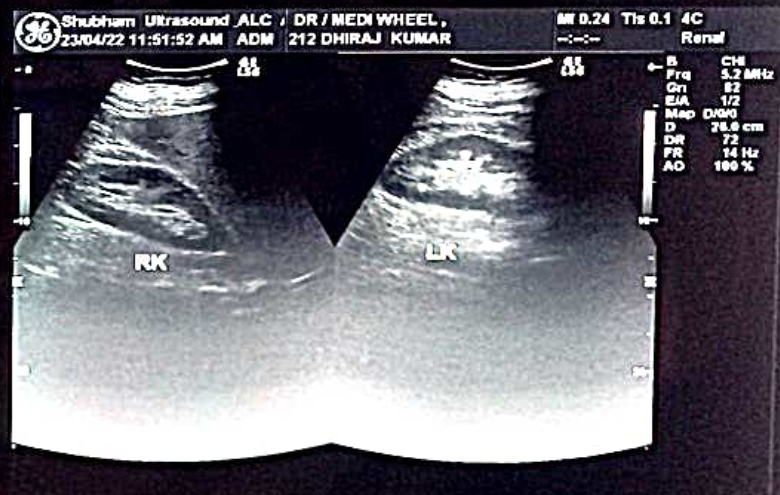
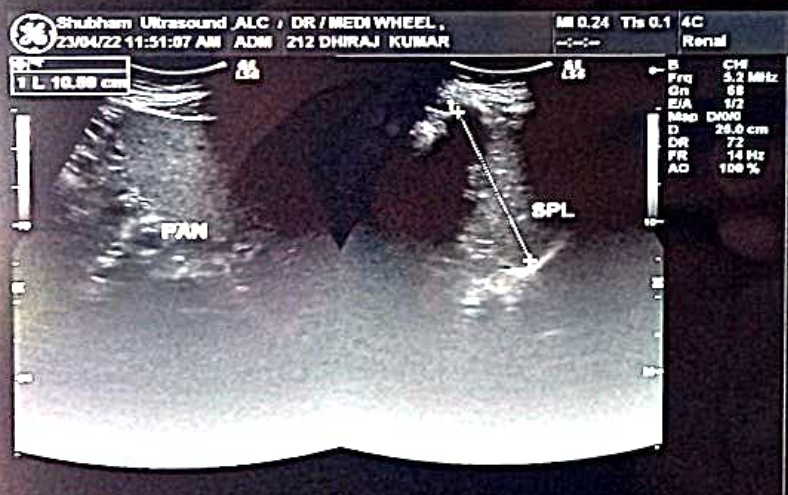
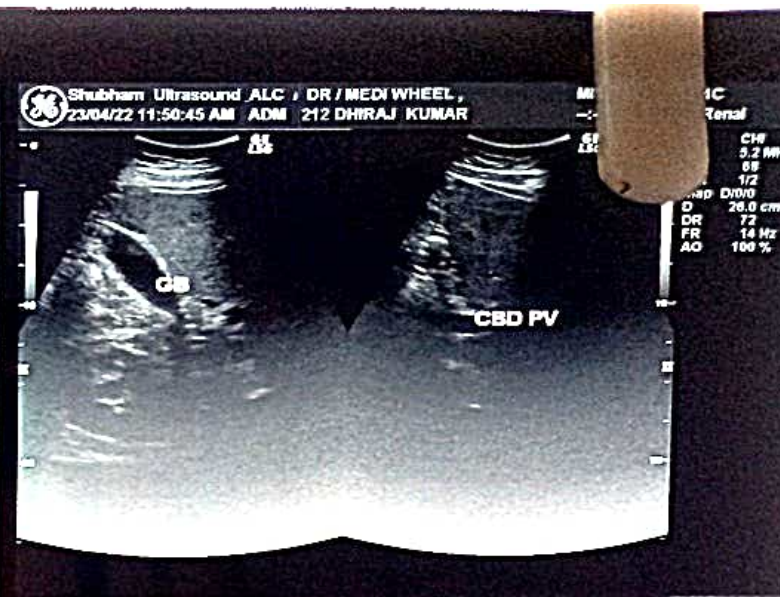
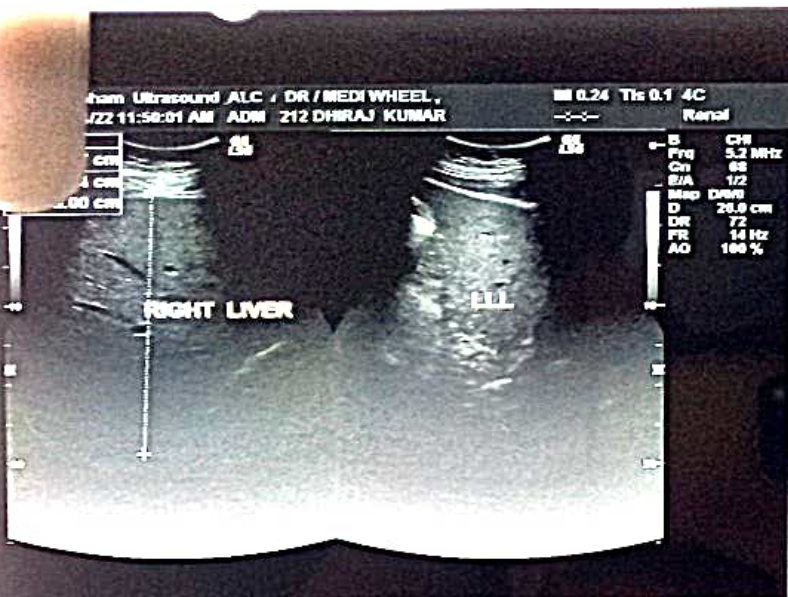Dr. S. Kumar
MD (Pat)
Consultant Pathologist

Dr. Abhishek Kumar
MBBS, MD
Consultant Neuropatho Physiologist

Dr. Anjali
MBBS, MD
Consultant(TMT, EEG Specialist)

Dr. Kumari Suman
MBBS, DGO, MD
Consultant (TVS & HSG Specialist)

PRINTING MISTAKE SHOULD BE REPORTED BACK IMMEDIATELY/ यहाँ जन्म से पहले भ्रुण का लिंग जाँच नहीं होता है ।





A.L.C. Advance Imaging Diagnostics

ISO 9001:2015 Certified center

(A Unit of P.K.Arogyam Health & Wellness Center)

E-95, P.C. Colony, Near Sai Netryalaya Transformer, Kankarbagh, Patna - 20

alcdiagnostics@gmail.com

www.pkarogyamhealthcheckup.com

7050037694 8271206196

OPINION MUST BE CORRELATES WITH CLINICALLY & OTHER INVESTIGATION FOR FINAL DIAGNOSIS. NOT FOR MEDICO LEGAL PURPOSE

Pt. Name :- **DHIRAJ KUMAR**
Ref. By :- **DR. MEDIWHEEL**

Date:- **25-Apr-22**
Age / Sex - **32 Yrs. M.**

Thanks for your kind referral

X-RAYCHEST (P.A.VIEW)

The lungs on the either side show equal translucency.

The peripheral pulmonary vasculature is normal.

No focal lung lesion is seen.

The pleural spaces are normal.

Both hila are normal in size, have equal density and bear normal relationship.

The heart and trachea are central in position and no mediastinal abnormality is visible.

The cardiac size is normal.

The domes of the diaphragms are normal in position, and show smooth outline.

IMPRESSION

- NO EVIDENCE OF PULMONARY OR CARDIAC PATHOLOGY IS NOTED.



[Handwritten signature]
23/4/22

Consultant Radiologist

ESTD BY:-

Dr. P. K. Tiwari
MD, M.Sc (Radio Imaging)
Ph.D (AIR Nuclear Medicine)
Consultant Imaginologist & Sonologist

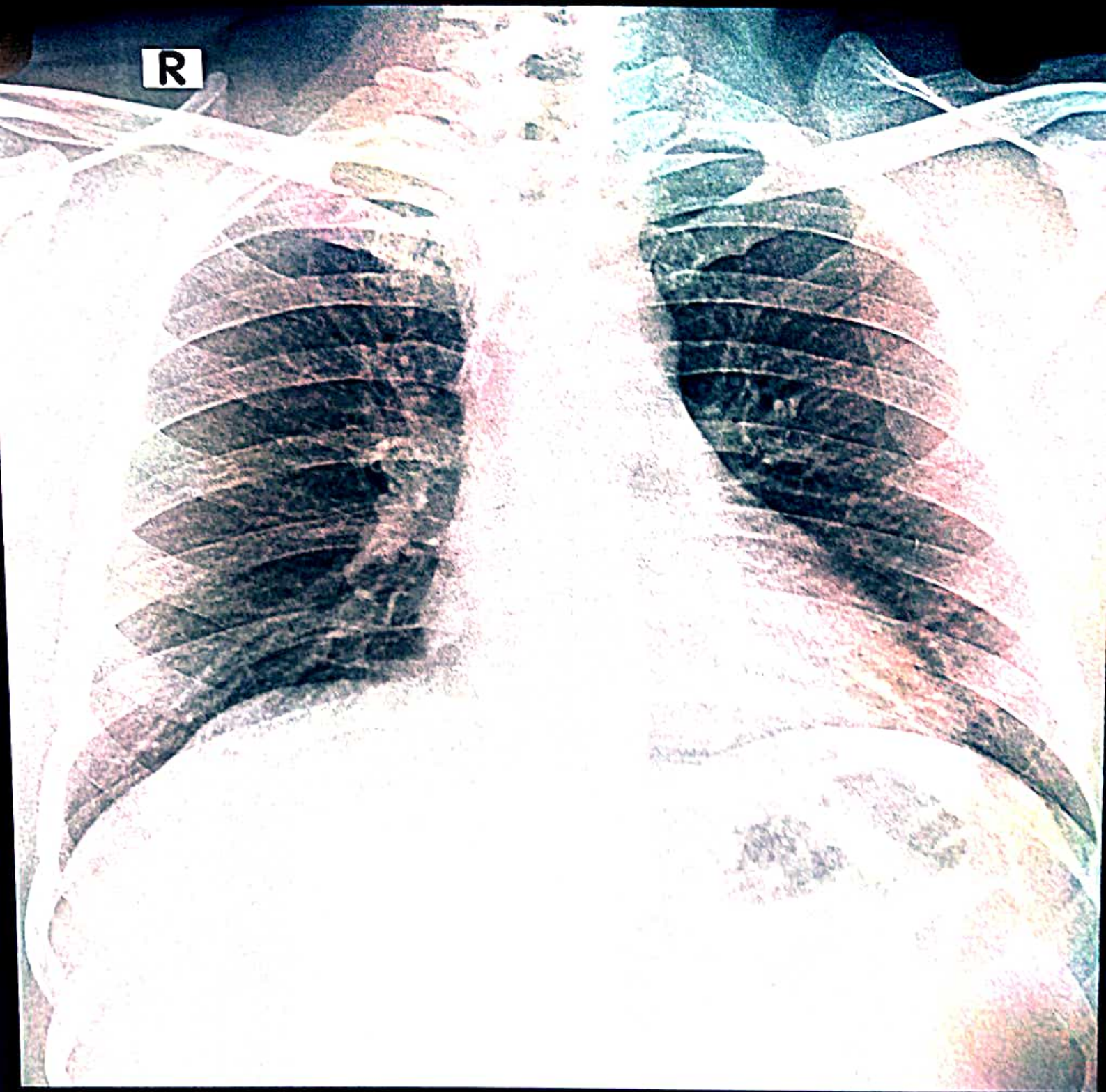
Dr. S. Kumar
MD (Pat)
Consultant Pathologist

Dr. Abhishek Kumar
MBBS, MD
Consultant Neuropathology Physiologist

Dr. Anjali
MBBS, MD
Consultant (TMT, EEG Specialist)

Dr. Kumari Suman
MBBS, DGO, MD
Consultant (TVS & HSG Specialist)

PRINTING MISTAKE SHOULD BE REPORTED BACK IMMEDIATELY/ यहाँ जन्म से पहले भ्रुण का लिए जाँच नहीं होता है ।



**DHIRAJ KUMAR AGE 32 YEARS 210 DR MEDIWHEEL CHEST,FRN P->A 4/23/2022
A.L.C. Advance Imaging Diagnostics Centre PATNA - 20**