

CID#	: 2132328067	SID#	: 177803839129
Name	: MR.VIPUL BHALARA	Registered	: 19-Nov-2021 / 10:22
Age / Gender	: 31 Years/Male	Collected	: 19-Nov-2021 / 10:22
Ref. Dr	: -	Reported	: 20-Nov-2021 / 08:16
Reg.Location	: Kandivali East (Main Centre)	Printed	: 20-Nov-2021 / 09:37

## PHYSICAL EXAMINATION REPORT

### History and Complaints:

No

### EXAMINATION FINDINGS:

Height (cms):	175 cms	Weight (kg):	66 kgs
Temp (0c):	Afebrile	Skin:	Normal
Blood Pressure (mm/hg):	140/90	Nails:	Normal
Pulse:	72/min	Lymph Node:	Normal

### Systems

Cardiovascular: Normal  
Respiratory: Normal  
Genitourinary: Normal  
GI System: Normal  
CNS: Normal

### IMPRESSION:

*- Dyslipidemia*

### ADVICE:

*↓ fatty diet  
Regular exercise*

ADDRESS: 2<sup>nd</sup> Floor, Aston, Sundervan Complex, Above Mercedes Showroom, Andheri West - 400053

HEALTHLINE - MUMBAI: 022-6170-0000 | OTHER CITIES: 1800-266-4343

For Feedback - customerservice@suburbandiagnosics.com | www.suburbandiagnosics.com

CID# : 2132328067  
Name : MR.VIPUL BHALARA  
Age / Gender : 31 Years/Male  
Ref. Dr : -  
Reg.Location : Kandivali East (Main Centre)

SID# : 177803839129  
Registered : 19-Nov-2021 / 10:22  
Collected : 19-Nov-2021 / 10:22  
Reported : 20-Nov-2021 / 08:16  
Printed : 20-Nov-2021 / 09:37

**CHIEF COMPLAINTS:**

- |  |    |
|--|----|
| 1) Hypertension:                         | No |
| 2) IHD                                   | No |
| 3) Arrhythmia                            | No |
| 4) Diabetes Mellitus                     | No |
| 5) Tuberculosis                          | No |
| 6) Asthama                               | No |
| 7) Pulmonary Disease                     | No |
| 8) Thyroid/ Endocrine disorders          | No |
| 9) Nervous disorders                     | No |
| 10) GI system                            | No |
| 11) Genital urinary disorder             | No |
| 12) Rheumatic joint diseases or symptoms | No |
| 13) Blood disease or disorder            | No |
| 14) Cancer/lump growth/cyst              | No |
| 15) Congenital disease                   | No |
| 16) Surgeries                            | No |
| 17) Musculoskeletal System               | No |

**PERSONAL HISTORY:**

- |               |     |
|---------------|-----|
| 1) Alcohol    | No  |
| 2) Smoking    | No  |
| 3) Diet       | Veg |
| 4) Medication | No  |

\*\*\* End Of Report \*\*\*

**SUBURBAN DIAGNOSTICS (INDIA) PVT. LTD.**  
Row House No. 3, Aangan,  
Thakur Viliage, Kandivali (east),  
Mumbai - 400101.  
Tel : 61700000

  
**Dr. Jagruti Dhale**  
MBBS  
Consultant Physician  
Reg. No. 69548

ADDRESS: 2<sup>nd</sup> Floor, Aston, Sundervan Complex, Above Mercedes Showroom, Andheri West - 400053

HEALTHLINE - MUMBAI: 022-6170-0000 | OTHER CITIES: 1800-266-4343

For Feedback - customerservice@suburbandiagnosics.com | www.suburbandiagnosics.com



CID : 2132328067  
Name : Mr Vipul Bhalara  
Age / Sex : 31 Years/Male  
Ref. Dr :  
Reg.Location : Kandivali East Main Centre

Reg. Date : 19-Nov-2021 / 10:58  
Report Date : 19-Nov-2021 / 14:51  
Printed : 19-Nov-2021 / 14:51

**X-RAY CHEST PA VIEW**

Both lung fields are clear.

Both costo-phrenic angles are clear.

The cardiac size and shape are within normal limits.

The domes of diaphragm are normal in position and outlines.

The skeleton under review appears normal.

**IMPRESSION:**

**NO SIGNIFICANT ABNORMALITY IS DETECTED.**

**Kindly correlate clinically.**

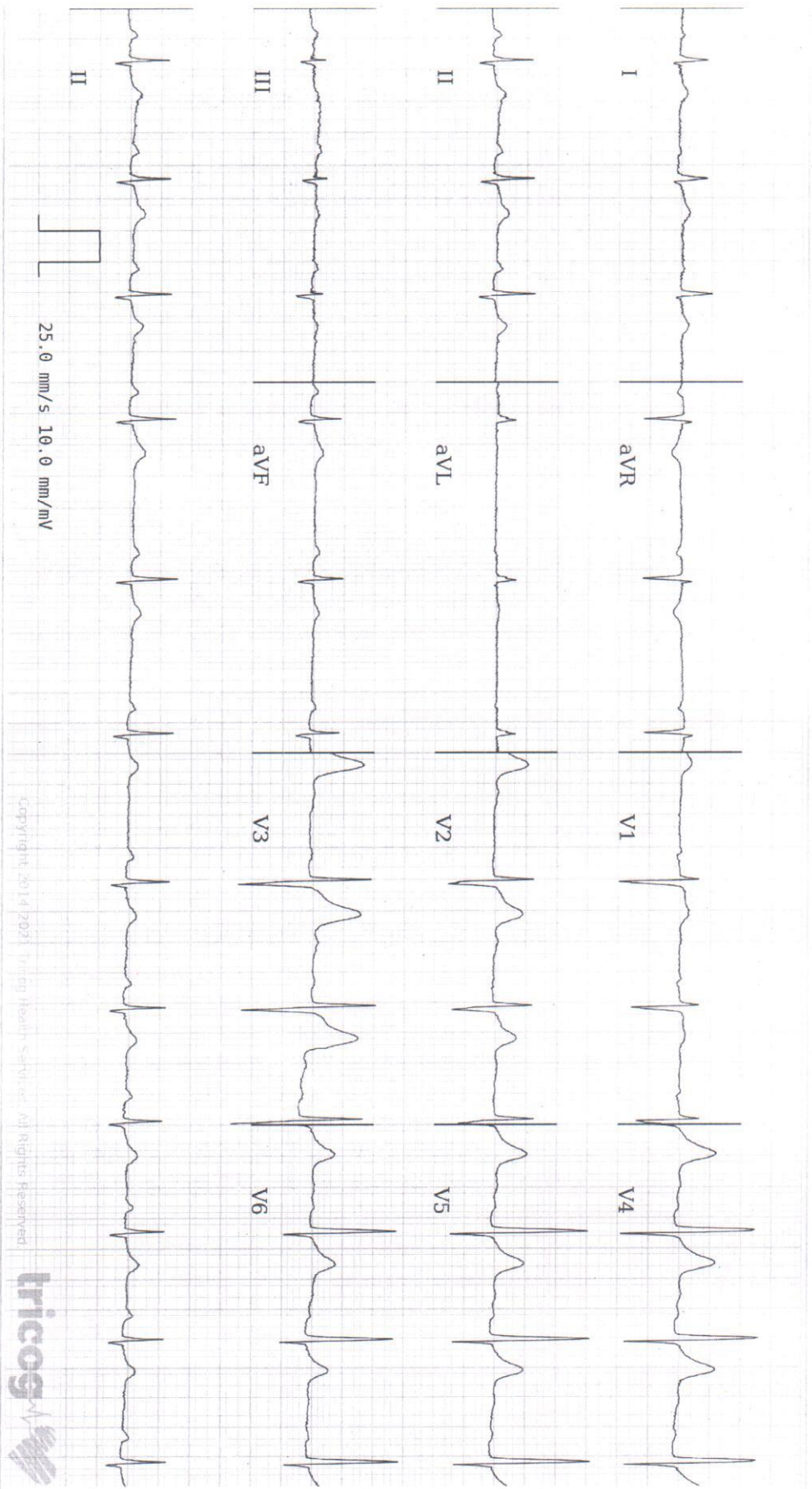
Note: Investigations have their limitations. Solitary radiological investigations never confirm the final diagnosis. They only help in diagnosing the disease in correlation to clinical symptoms and other related tests. X ray is known to have inter-observer variations. Further / follow-up imaging may be needed in some cases for confirmation / exclusion of diagnosis. Please interpret accordingly.

-----End of Report-----

Dr. Vivek Singh  
MD Radiodiagnosis  
Reg No: 2013/03/0388

Patient Name: **VIPUL BHALARA**  
Patient ID: **21332328067**

Date and Time: **19th Nov 21 11:13 AM**



Copyright © 2014 2021 Tricog Health Services. All Rights Reserved



Age **31** **2** **8**  
years months days

Gender **Male**

Heart Rate **73 bpm**

Patient Vitals

BP: **140/90 mmHg**

Weight: **66 kg**

Height: **175 cm**

Pulse: **NA**

Spo2: **NA**

Resp: **NA**

Others:

**Measurements**

QSRD: **74 ms**

QT: **342 ms**

QTc: **376 ms**

PR: **180 ms**

P-R-T: **67° 26° 49°**

REPORTED BY

*[Signature]*

**DR AKHIL PARULEKAR**

**MBBS, MD, MEDICINE, DNB Cardiology**  
Cardiologist  
2012082483

**SUBURBAN DIAGNOSTICS (INDIA) PVT. LTD.**

**Row House No. 3, Aangan,  
Thakur Village, Kandivalli (east),  
Mumbai - 400101.**  
Tel: **61760000**

**ECG Within Normal Limits: Sinus Rhythm, Normal Axis. Please correlate clinically.**

Disclaimer: 1) Analysis in this report is based on ECG alone and should be used as an adjunct to clinical history, symptoms, and results of other invasive and non-invasive tests. 2) Patient vitals are as entered by the clinician and not derived from the ECG.

Date:- 19/11/21

CID:  
2132328067

Name:- Mr. Vipul Bhalera

Sex/Age: m/39

**EYE CHECK UP**

Chief complaints: Routine ch-up

Systemic Diseases: no H/O SIZ

Past history: no H/O Ocular surgery

Contact lens power  
-4.25  
-4.75

Unaided Vision: -

<sup>CL</sup>  
Aided Vision: CLGP, 10/6      CLGP, 10/6

Refraction:

Const. Normal

	(Right Eye)				(Left Eye)			
	Sph	Cyl	Axis	Vn	Sph	Cyl	Axis	Vn
Distance								
Near								

Colour Vision: Normal / Abnormal

Remark: Vn within normal limit

*Ajay H.*  
SUBURBAN DIAGNOSTICS (INDIA) PVT. LTD. KAJAL NAGRECHA  
Row House No. 3, Aangan, OPTOMETRIST  
Thakur Village, Kandivali (east),  
Mumbai - 400101.  
Tel : 61700000

ADDRESS: 2<sup>nd</sup> Floor, Aston, Sundervan Complex, Above Mercedes Showroom, Andheri West - 400053

HEALTHLINE - MUMBAI: 022-6170-0000 | OTHER CITIES: 1800-266-4343

For Feedback - customerservice@suburbandiagnosics.com | www.suburbandiagnosics.com



**CID** : 2132328067  
**Name** : Mr Vipul Bhalara  
**Age / Sex** : 31 Years/Male  
**Ref. Dr** :  
**Reg.Location** : Kandivali East Main Centre

**Reg. Date** : 19-Nov-2021 / 17:30

**Report Date** : 19-Nov-2021 / 17:54

**Printed** : 19-Nov-2021 / 17:54

## USG WHOLE ABDOMEN

### LIVER:

The liver is normal in size (12.9 cm), shape and smooth margins. It shows normal parenchymal echo pattern. The intra hepatic biliary and portal radical appear normal. No evidence of any intra hepatic cystic or solid lesion seen. The main portal vein and CBD appears normal.

### GALL BLADDER:

The gall bladder is partially distended and apparently normal.

### PANCREAS:

The pancreas head and body is visualised and appears normal. No evidence of solid or cystic mass lesion. Rest of the pancreas is obscured due to bowel gas shadows.

### KIDNEYS:

Both the kidneys are normal in size, shape and echotexture.  
No evidence of any calculus, hydronephrosis or mass lesion seen.  
Right kidney measures 10.9 x 3.9 cm. Left kidney measures 10.3 x 5.0 cm.

### SPLEEN:

The spleen is normal in size (8.4 cm) and echotexture. No evidence of focal lesion is noted. There is no evidence of any lymphadenopathy or ascites.

### URINARY BLADDER:

The urinary bladder is well distended and reveal no intraluminal abnormality.

### PROSTATE:

The prostate is normal in size and volume is 16 cc.

### IMPRESSION:

**No significant abnormality is seen.**

### Suggestion: Clinicopathological correlation.

Note: Investigations have their limitations. Solitary radiological investigations never confirm the final diagnosis. They only help in diagnosing the disease in correlation to clinical symptoms and other related tests. USG is known to have inter-observer variations. Further / Follow-up imaging may be needed in some cases for confirmation / exclusion of diagnosis. Patient was explained in detail verbally about the USG findings, USG measurements and its limitations. In case of any typographical error in the report, patient is requested to immediately contact the centre for rectification. Please interpret accordingly. All safety precautions were taken before, during and after the USG examination in view of the ongoing Covid 19 pandemic.

-----End of Report-----

**Dr. Vivek Singh**  
**MD Radiodiagnosis**  
**Reg No: 2013/03/0388**