

**भारतीय विशिष्ट पहचान प्राधिकरण**  
Unique Identification Authority of India

पता: S/O: श्याम नंदन साह, स.न. 97 फ्लोर, पॉकेट 21, नजदीक  
बेस्ट मेगा मॉल, रोहिणी सेक्टर-24,  
रिजाला, रोहिणी सेक्टर ७, उत्तर  
पश्चिमो, दिल्ली, 110085

Address: S/O: Shyam Nandan Sah, H.NO  
97 1st Floor, POCKET 21, NEAR BEST  
MEGA MALL, ROHINI SECTOR-24,  
Ritahla, Rohini Sector-7, North West Delhi,  
Delhi, 110085

**6921 9428 8969**

1800 300 1947

help@uidai.gov.in

www.uidai.gov.in

*(Handwritten signature in blue ink)*

**Dr. NITIN AGARWAL**  
MBBS, MD  
Regn. No. DMC-R-1436

**ONEPLUS ULTRASOUND LAB**  
47, Harsh Vihar, Pitam Pura  
Delhi-110034  
Ph. 011-42480101, 9599913051  
E-mail: oneplusul@gmail.com


**भारत सरकार**  
Government of India

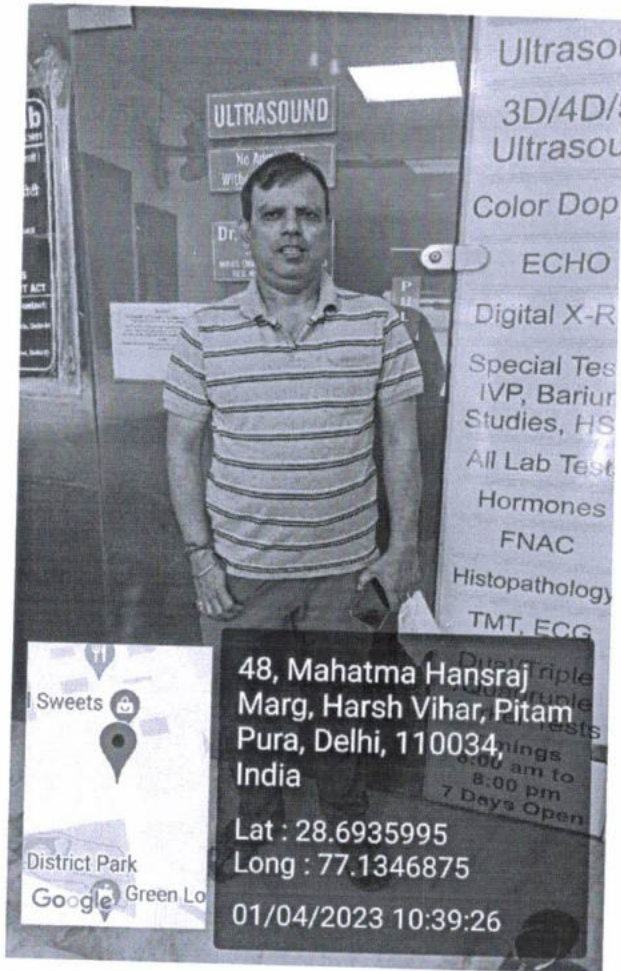सुनील कुमार  
Sunil Kumar  
जन्म तिथि / DOB : 14/06/1978  
पुरुष / Male

**6921 9428 8969**

**आधार - आम आदमी का अधिकार**







Dr. NITIN AGARWAL  
MBBS, MD  
Regn. No. DMC-R-1436

ONEPLUS ULTRASOUND LAB  
47, Harsh Vihar, Pitam Pura,  
Delhi-110034  
Ph. 011-42430101, 9599913051  
E-mail: oneplusul@gmail.com

# ONEPLUS ULTRASOUND LAB

47, HARSH VIHAR, PITAMPURA, DELHI- 110034

Mr. SUNIL KUMAR

Age : 45/M

Ref. by : MED/WHEEL

Indication1 :

Indication2 :

Indication3 :

COMMENTS : Normal ECG.

ID : 2188

H/Wt : 167/63

Recorded : 1-4-2023 10:02

Medication1 :

Medication2 :

Medication3 :

BPM : 88

BP : 136/88

P Axis : 90 deg

QRS Axis : 81 deg

T Axis : 54 deg

P duration : 90 msec

PR duration : 130 msec

QRS duration : 106 msec

QT interval : 310 msec

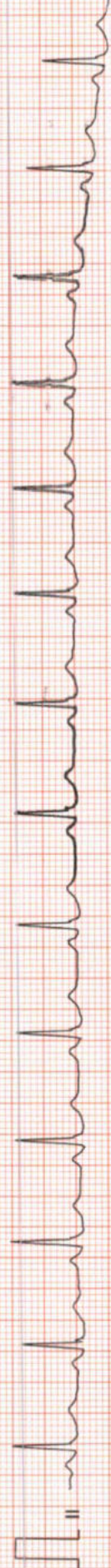
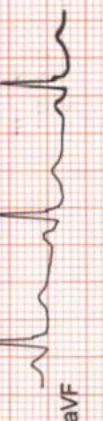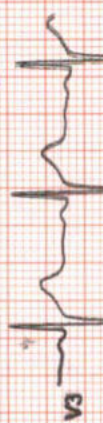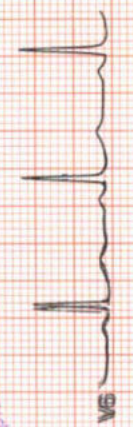
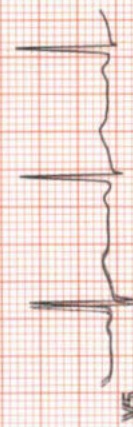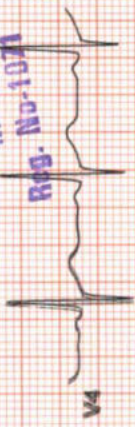
QTc interval : 359 msec

Raw E.C.G.(Seq)

Unconfirmed Report Reviewed By:

Cardiologist

*[Signature]*  
Dr. A.K. GUPTA  
MBBS, MD  
REG. No-1071



ONEPLUS ULTRASOUND LAB  
47, Harsh Vihar, Pitam Pura,  
Delhi-110034  
Ph. 011-42480101, 9599913051  
E-mail: oneplusul@gmail.com

# ONEPLUS ULTRASOUND LAB

47, HARSH VIHAR PITAMPURA DELHI 110034

Mr. SUNIL KUMAR  
Age/Sex : 45/M

ID : 995  
Ht/Wt : 167/63

TREADMILL TEST SUMMARY REPORT  
Protocol: BRUCE

Recorded : 1-4-2023 10:05

Ref. by : MEDIWHEEL  
Indication1 :  
Indication2 :  
Indication3 :

History:  
Medication1 :  
Medication2 :  
Medication3 :

PHASE	PHASE TIME	STAGE TIME	SPEED (Km./Hr.)	GRADE (%)	H.R. (BPM)	B.P. (mmHg)	RPP X100	II	ST LEVEL (mm) V2	V5	METS
SUPINE STANDING					87	136/88	118	0.0	20	0.2	
					86	136/88	116	0.0	20	0.2	
STAGE 1	2:59	2:59	2.70	10.00	103	136/88	140	0.3	21	0.4	4.80
STAGE 2	5:59	2:59	4.00	12.00	112	150/90	168	0.3	24	0.6	7.10
STAGE 3	8:59	2:59	5.40	14.00	141	150/90	211	0.3	29	0.4	10.00
STAGE 4	9:29	0:29	6.70	16.00	164	164/94	268	0.2	20	0.1	10.65
PEAK EXER	9:30	0:30			165	164/94	270	0.2	20	0.1	10.67
RECOVERY	2:59	2:59	0.00	0.00	97	164/94	159	-0.4	11.2	-0.1	

## RESULTS

Exercise Duration : 9:30 Minutes  
Max Heart Rate : 165 bpm 94 % of target heart rate 175 bpm  
Max Blood Pressure : 164/94 mmHg  
Max Work Load : 10.67 METS  
Reason of Termination :

## IMPRESSIONS

Negative for inducible ischemia.

ONEPLUS ULTRASOUND LAB  
47, Harsh Vihar, Pitampura  
Delhi-110034  
Phone: 011-2620740, TeleFax: 011-2431214  
E-mail: oneplus@gmail.com

Dr. P. K. GUPTA  
F.M.S., MD  
Cardiologist

# ONEPLUS ULTRASOUND LAB

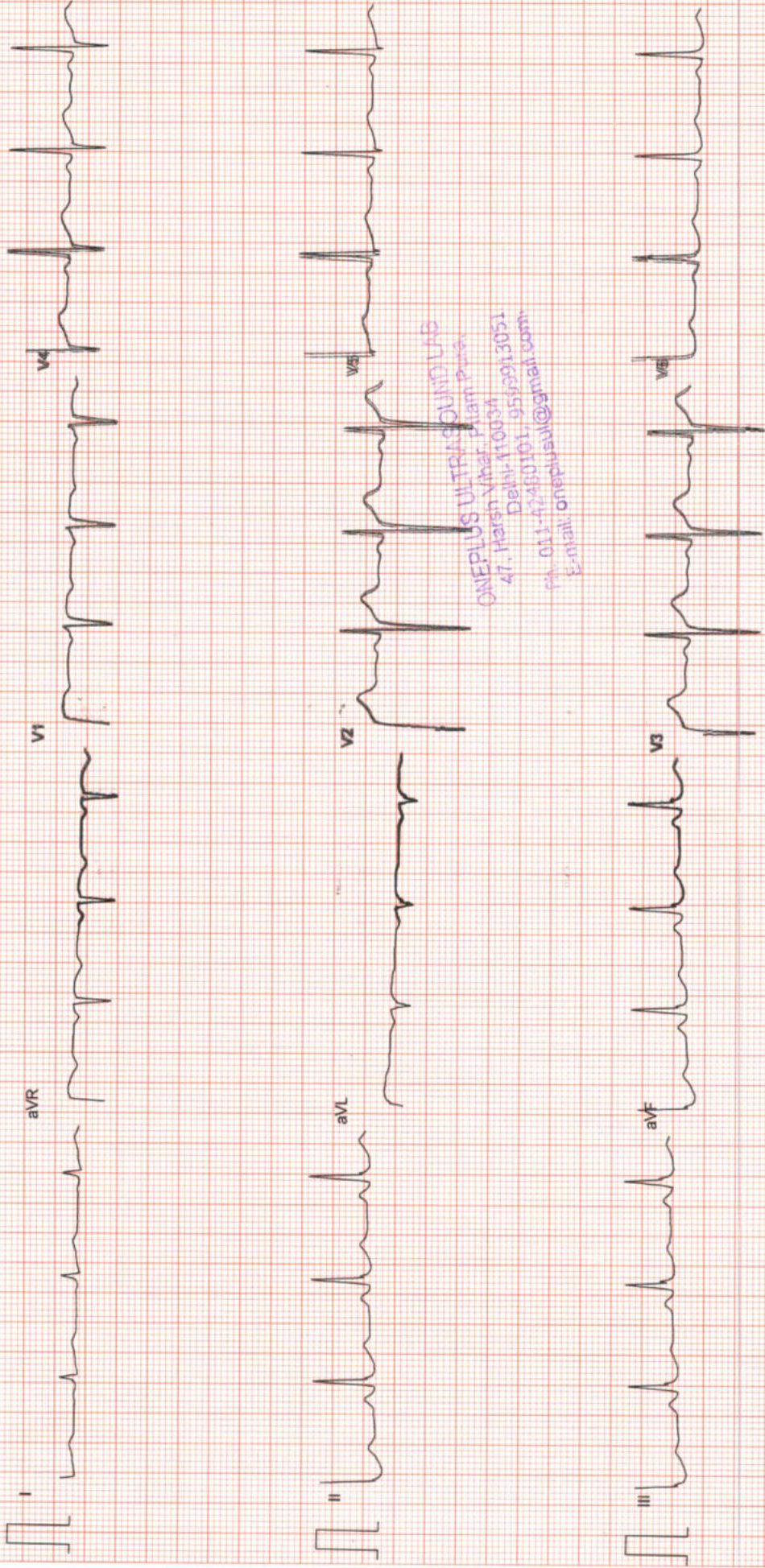
Mr. SUNIL KUMAR  
I.D. : 995  
AGE/SEX : 45/M

ST @ 10mm/mV  
80ms PostJ

SUPINE  
PRETEST

RECORDED : 1-4-2023 10:05  
RATE : 87 BPM  
B.P. : 136/88 mmHg

RAW E.C.G.



ONEPLUS ULTRASOUND LAB  
47, Harsih Vihar, Phase 1, Preeti,  
Delhi-110034  
Ph: 011-42460101, 9559913051  
E-mail: oneplusul@gmail.com

# ONEPLUS ULTRASOUND LAB

STANDING  
PRETEST

ST @ 10mm/mV  
80ms PostJ

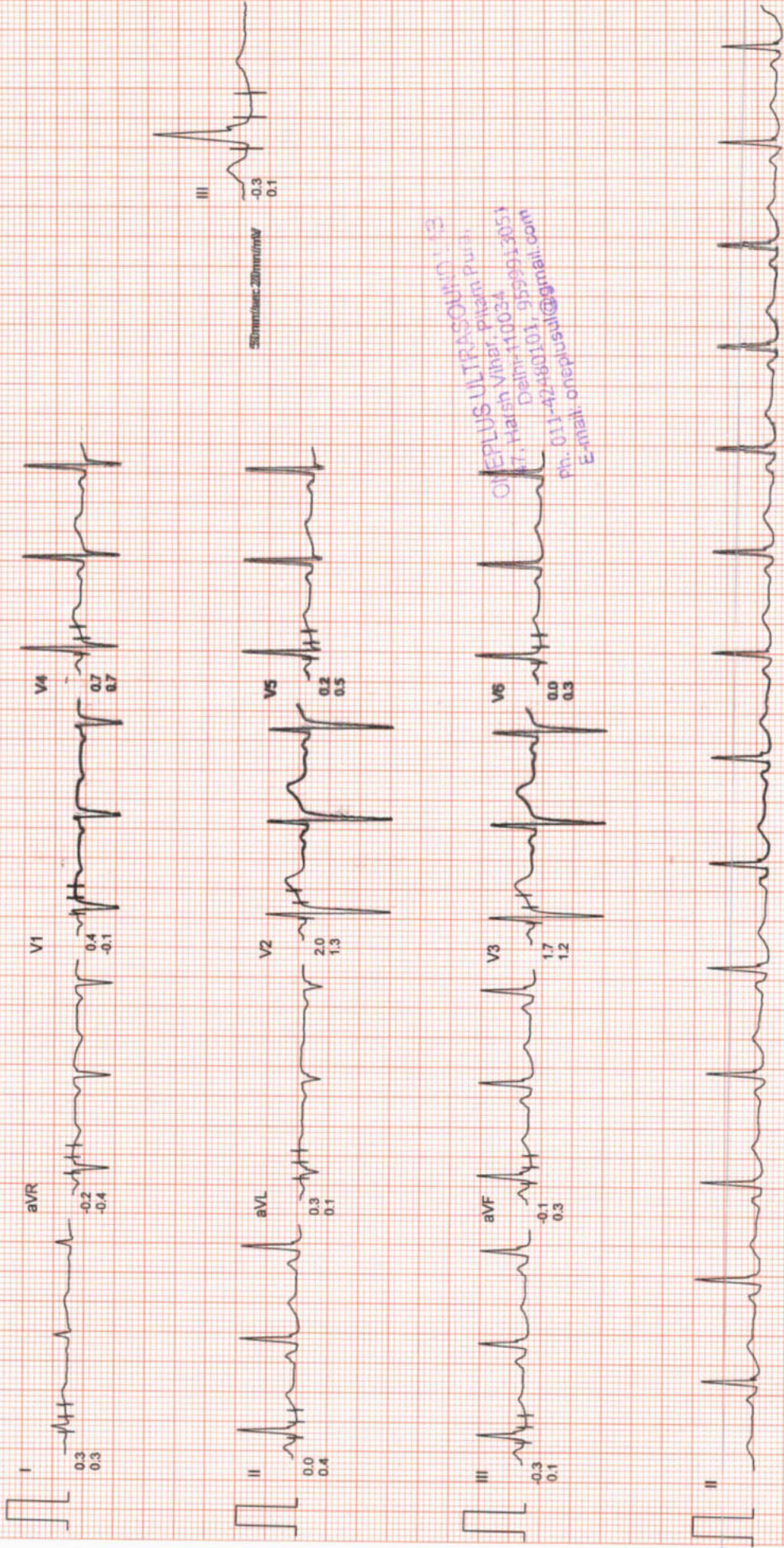
Mr. SUNIL KUMAR  
I.D. : 995  
AGE/SEX : 45/M

RECORDED : 1-4-2023 10:05

RATE : 86 BPM

B.P. : 136/88 mmHg

LINKED MEDIAN



ONEPLUS ULTRASOUND LAB  
W. Harsh Vihar, Pitam Puri  
Delhi-110034  
Ph: 011-42-60101, 9599913051  
E-mail: onepusul@gmail.com

Filtered

Computer Corrected Baseline

25mm/sec 10mm/mV

CardiCom, INDIA Ph: 091-731-2620740, TeleFax: 091-731-2431214

# ONEPLUS ULTRASOUND LAB

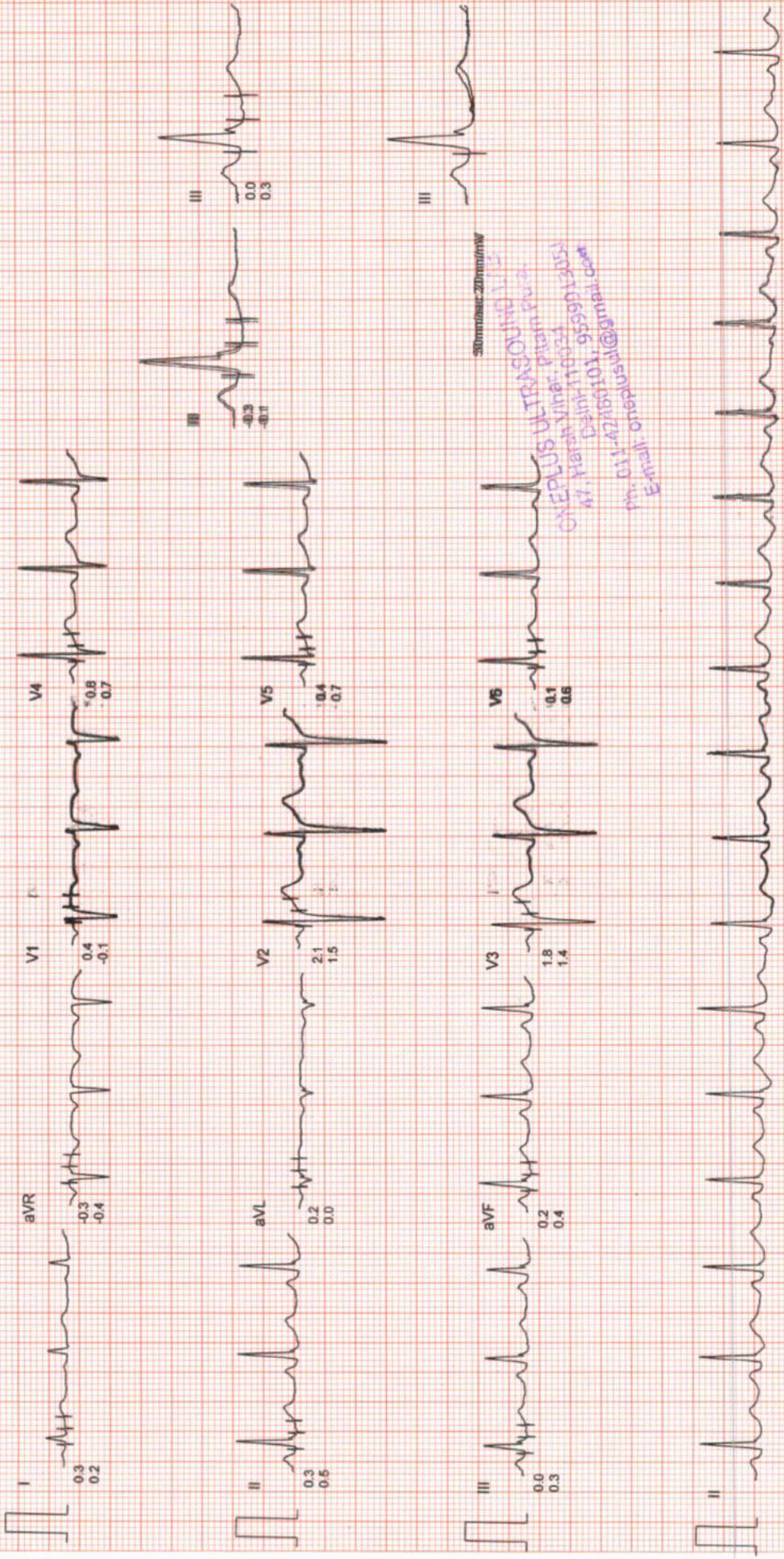
Mr. SUNIL KUMAR  
I.D. : 995  
AGE/SEX : 45/M

RECORDED : 1-4-2023 10:05  
RATE : 103 BPM  
B.P. : 136/88 mmHg

BRUCE  
EXERCISE 1  
PHASE TIME : 2:59  
STAGE TIME : 2:59

ST @ 10mm/mV  
80ms PostJ  
SPEED : 2.7 Km./Hr.  
GRADE : 10.0 %

LINKED MEDIAN



30mm/sec 20mm/mV  
ONEPLUS ULTRASOUND LAB  
Dr. Harsh Vihar : 9599013053  
Dr. Harsh Vihar : 9599013053  
Dr. Harsh Vihar : 9599013053





# ONEPLUS ULTRASOUND LAB

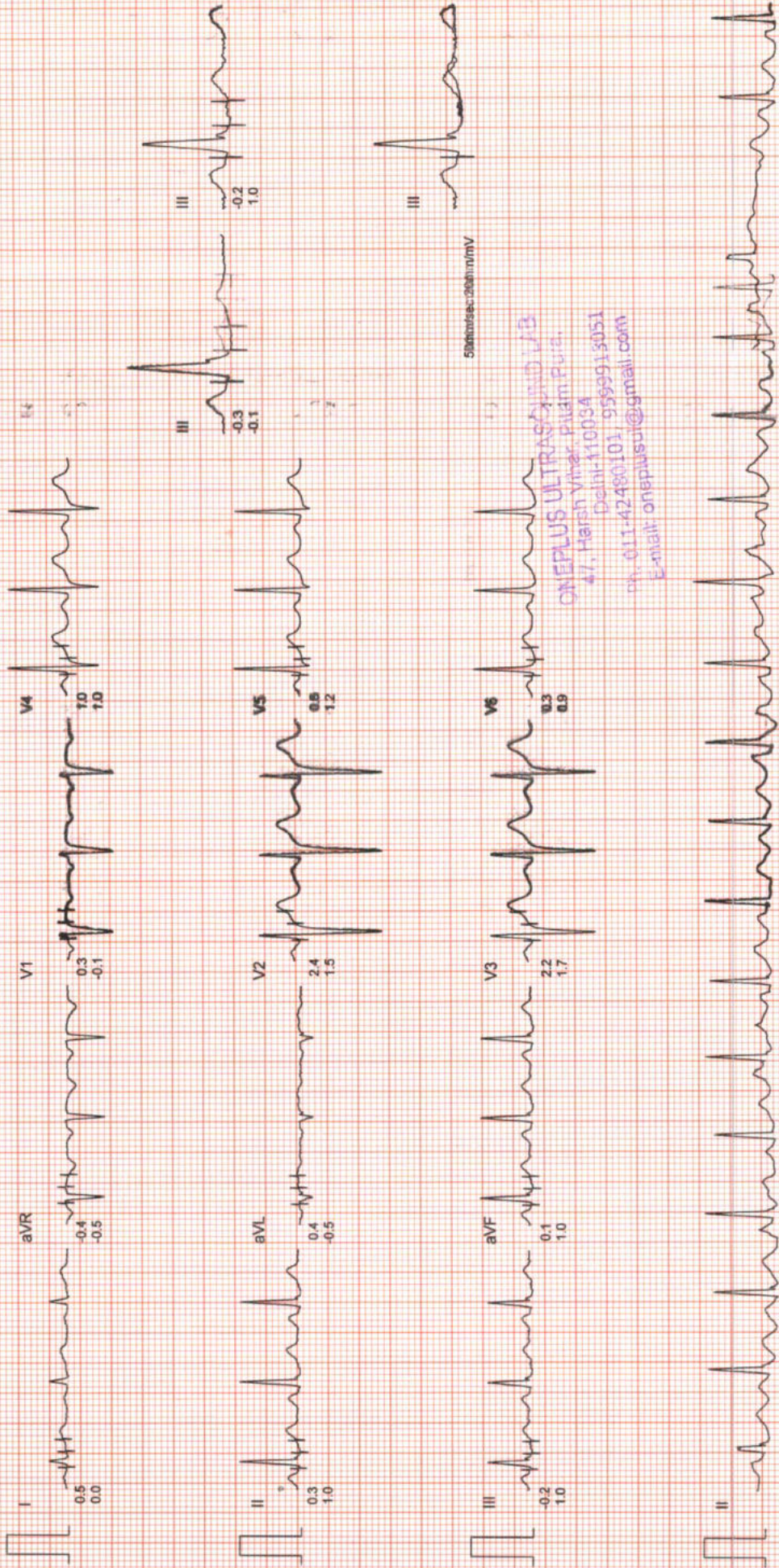
Mr. SUNIL KUMAR  
I.D. : 995  
AGE/SEX : 45/M

RECORDED : 1-4-2023 10:05  
RATE : 112 BPM  
B.P. : 150/90 mmHg

BRUCE  
EXERCISE 2  
PHASE TIME : 5:59  
STAGE TIME : 2:59

ST @ 10mm/mV  
80ms PostJ  
SPEED : 4.0 Km./Hr.  
GRADE : 12.0 %

LINKED MEDIAN





# ONEPLUS ULTRASOUND LAB

Mr. SUNIL KUMAR

I.D. : 995

AGE/SEX : 45/M

RECORDED : 1-4-2023 10:05

RATE : 141 BPM

B.P. : 150/90 mmHg

BRUCE

EXERCISE 3

PHASE TIME : 8:59

STAGE TIME : 2:59

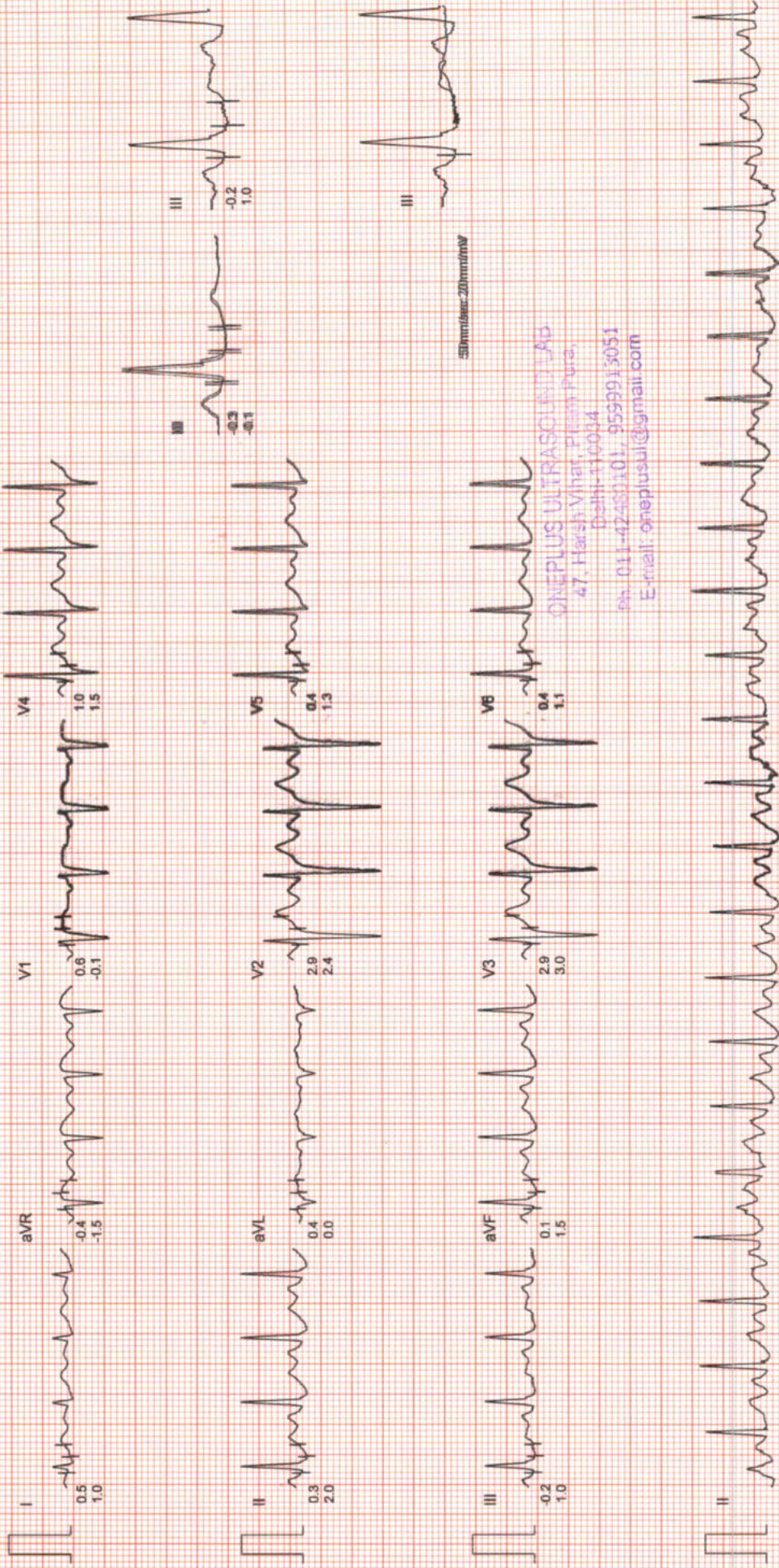ST @ 10mm/mV

80ms PostJ

SPEED : 5.4 Km./Hr.

GRADE : 14.0 %

LINKED MEDIAN





# ONEPLUS ULTRASOUND LAB

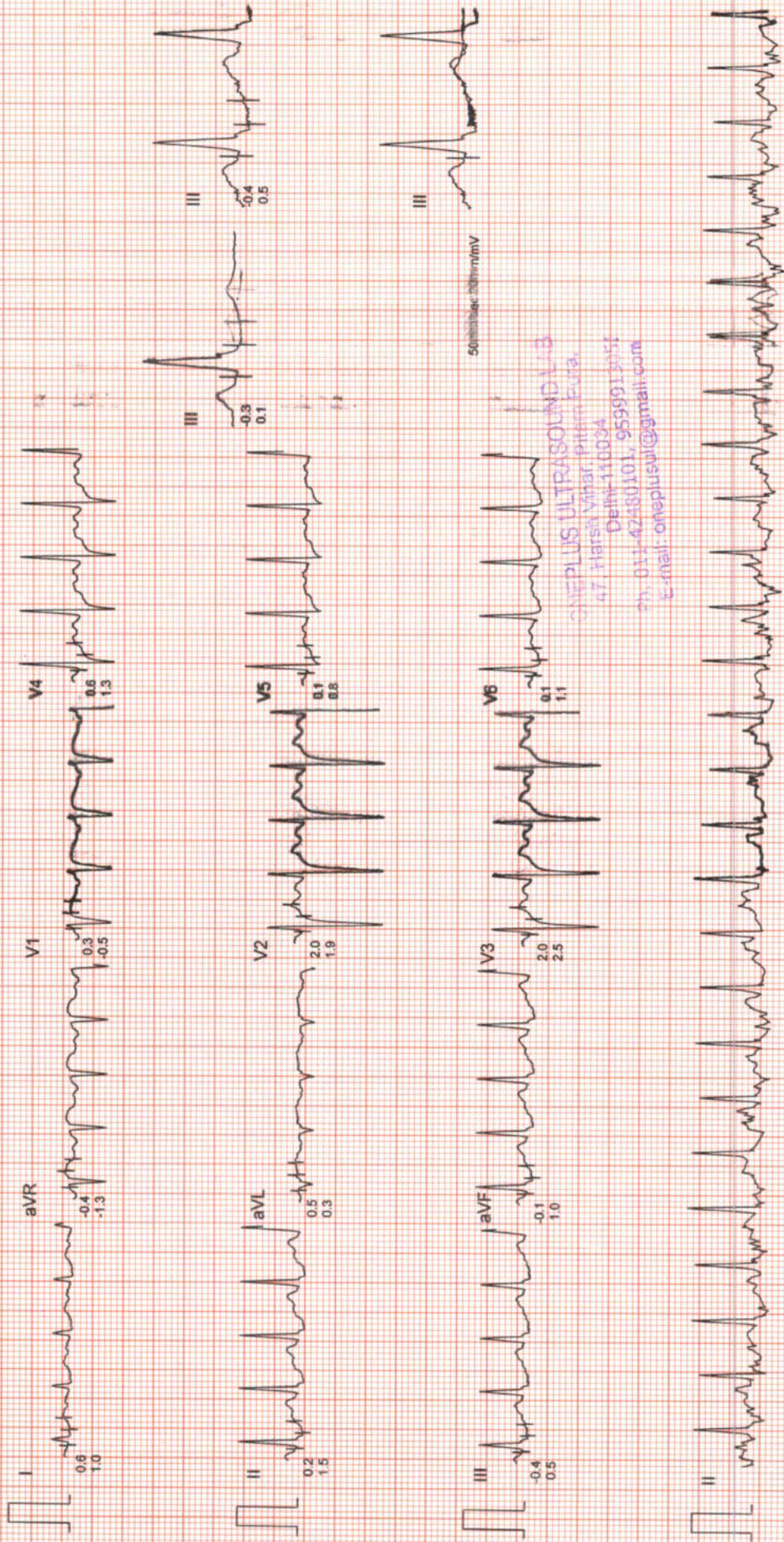
Mr. SUNIL KUMAR  
I.D. : 995  
AGE/SEX : 45/M  
RECORDED : 1-4-2023 10:05

RATE : 164 BPM  
B.P. : 164/94 mmHg

BRUCE  
EXERCISE 4  
PHASE TIME : 9:29  
STAGE TIME : 0:29

ST @ 10mm/mV  
80ms PostJ  
SPEED : 6.7 Km./Hr.  
GRADE : 16.0 %

LINKED MEDIUM



50mm/sec 10mm/mV

ONEPLUS ULTRASOUND LAB  
47, Harsih Vihar, Pitambara, Delhi-110034  
Ph. 011-42480101, 9599912051  
E-mail: oneplusul@gmail.com

# ONEPLUS ULTRASOUND LAB

Mr. SUNIL KUMAR  
I.D. : 995  
AGE/SEX : 45/M

BRUCE  
PEAK EXER

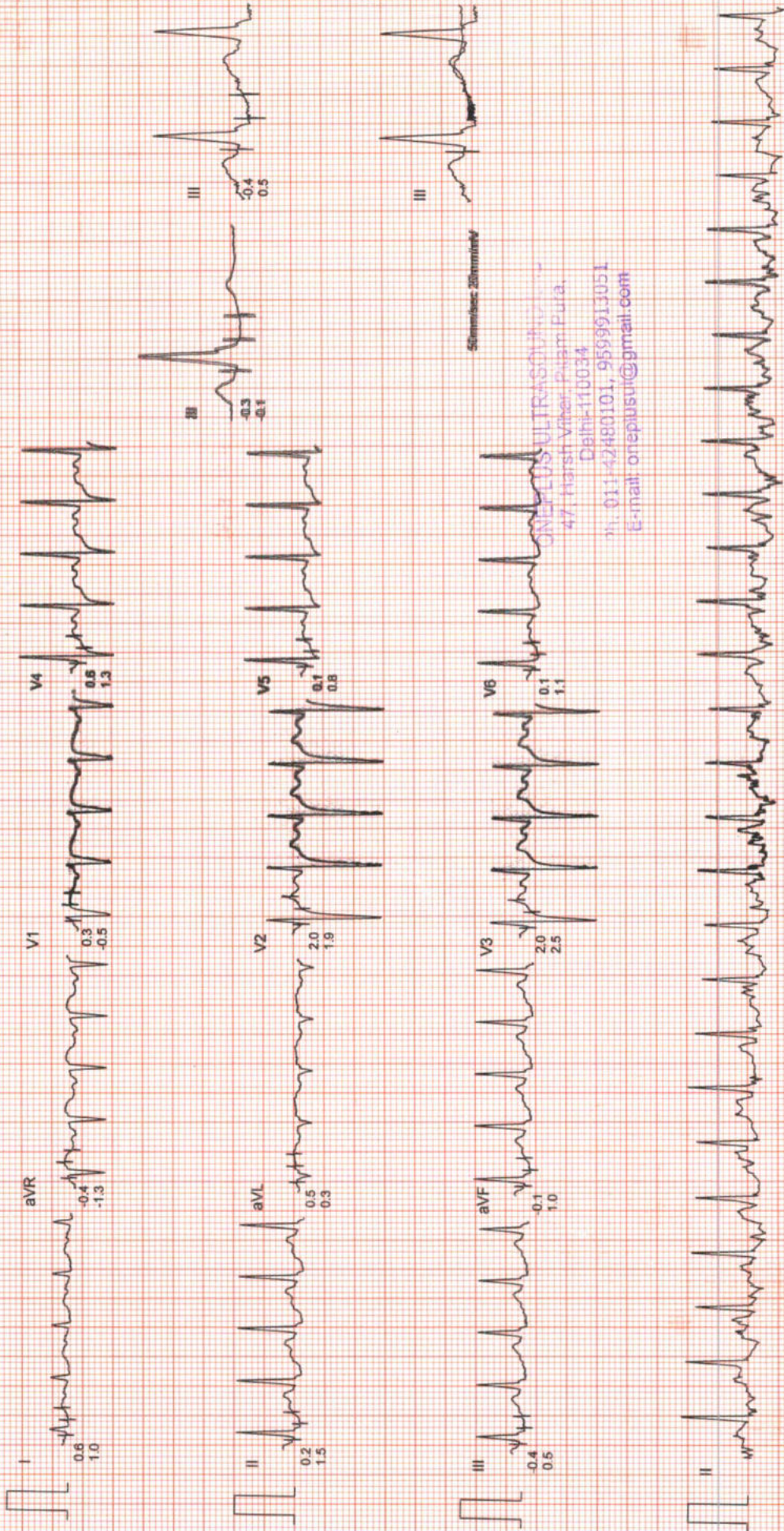
RATE : 165 BPM

RECORDED : 1-4-2023 10:05 B.P. : 164/94 mmHg

PHASE TIME : 9:30  
STAGE TIME : 0:30

ST @ 10mm/mV  
80ms PostJ  
SPEED : 6.7 Km./Hr.  
GRADE : 16.0 %

LINKED MEDIAN



50mm/sec 25mm/mV

ONEPLUS ULTRASOUND LAB  
47, Harsh Vihar, Puzam Pura,  
Delhi-110034  
Ph: 011-42480101, 9599913051  
E-mail: oneplusul@gmail.com

# ONEPLUS ULTRASOUND LAB

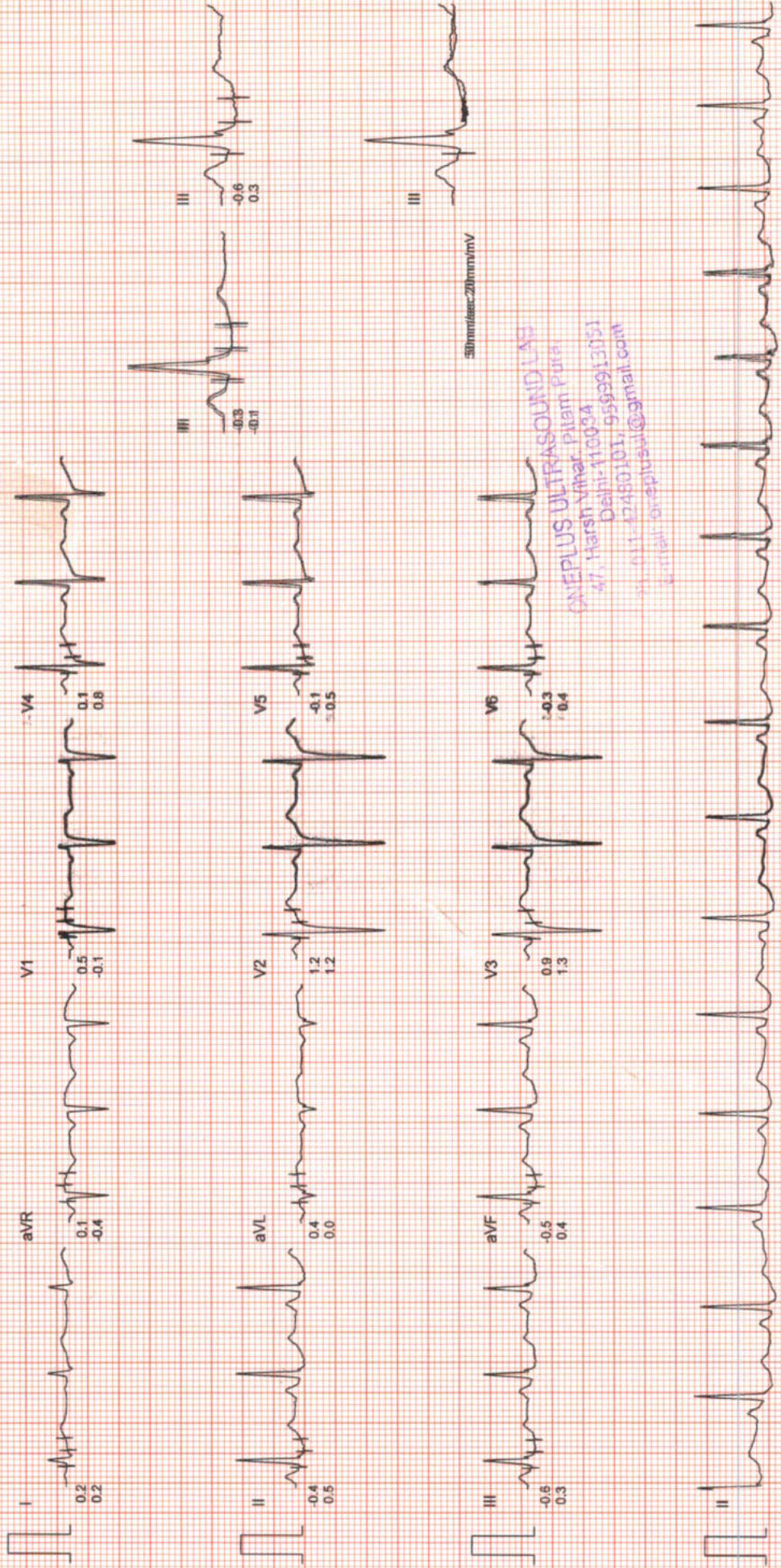
Mr. SUNIL KUMAR  
I.D. : 995  
AGE/SEX : 45/M

BRUCE  
RECOVERY  
PHASE TIME : 2:59

ST @ 10mm/mV  
80ms PostJ  
SPEED : 0.0 Km./Hr.  
GRADE : 0.0 %

RECORDED : 1-4-2023 10:05  
RATE : 97 BPM  
B.P. : 164/94 mmHg

LINKED MEDIAN



ONEPLUS ULTRASOUND LAB  
47, Harsh Vihar, Pitam Pura  
Delhi-110034  
91-11-27480101, 9999913051  
sunil@oneplusul@gmail.com

# ONEPLUS ULTRASOUND LAB

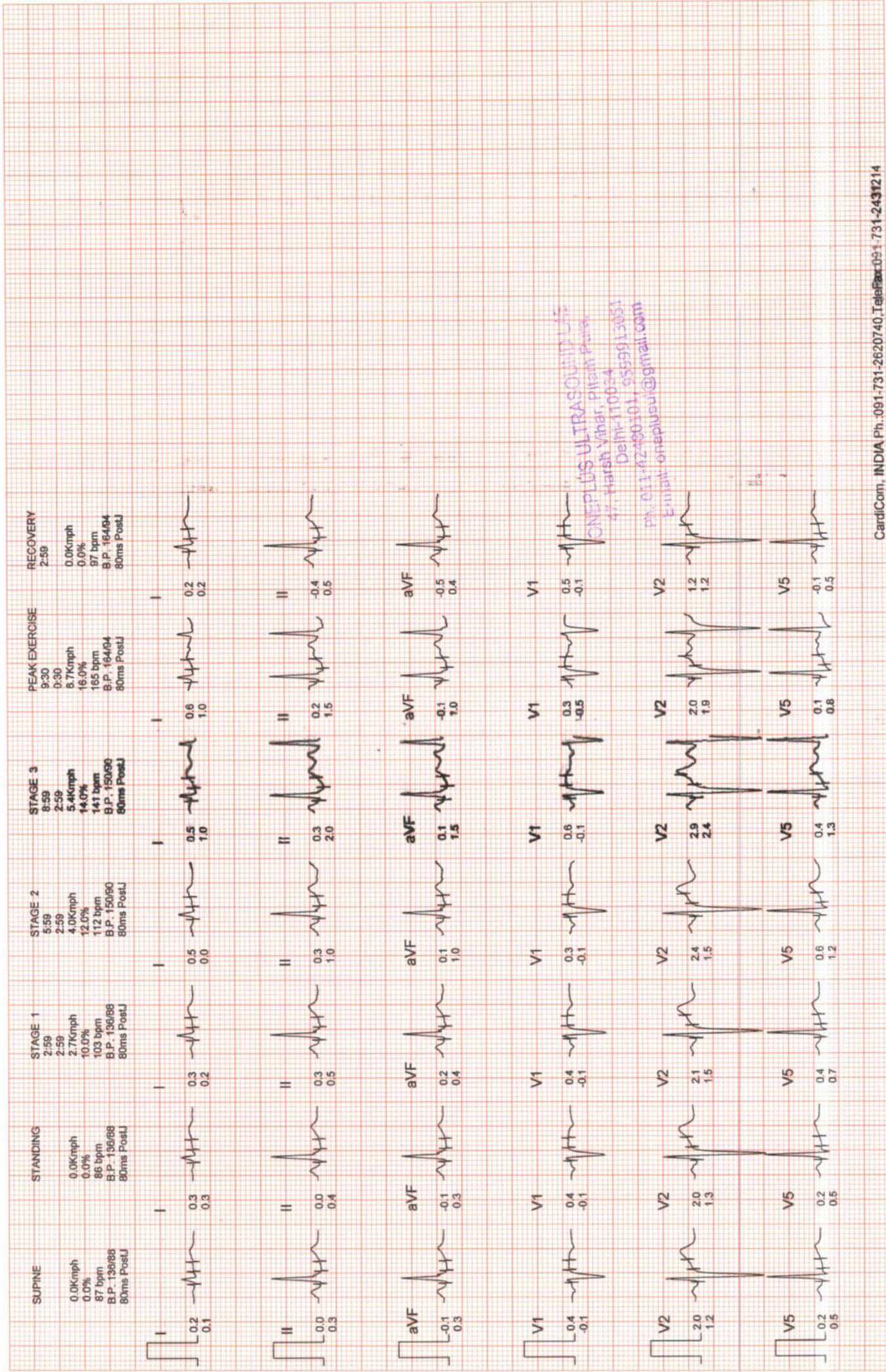
I.D. : 995

Mr. SUNIL KUMAR

AGE/SEX : 45/M

RECORDED : 1-4-2023 10:05

AVG. E.C.G.



ONEPLUS ULTRASOUND LAB  
 Dr. Harsh Vihar, Pitambara  
 Delhi-110034  
 Ph. 011-42400101, 9599913051  
 E-mail: oneplusul@gmail.com



# ONEPLUS ULTRASOUND LAB

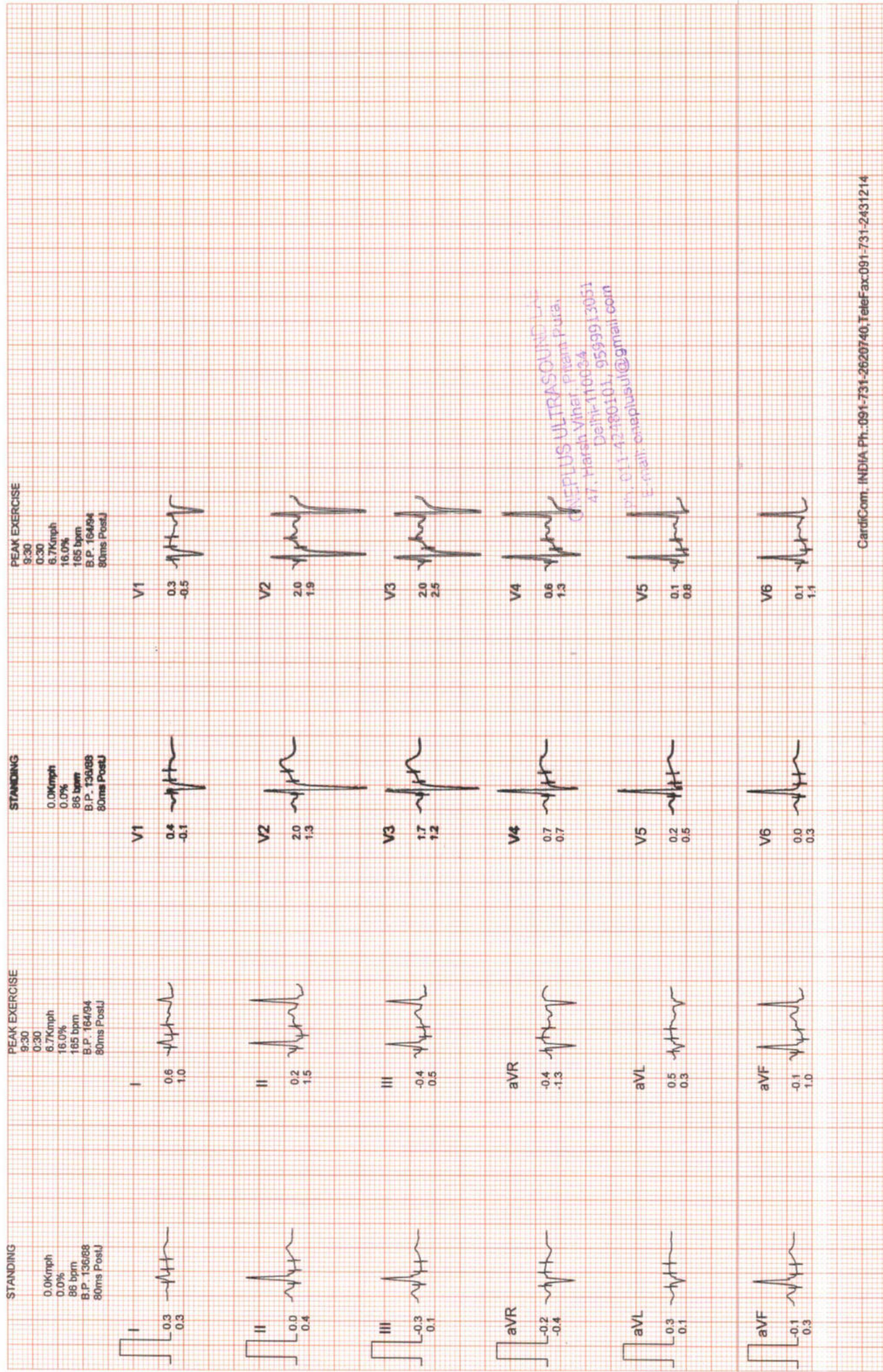
Mr. SUNIL KUMAR

I.D. : 995

AGE/SEX : 45/M

RECORDED : 1-4-2023 10:05

## COMPARISON REPORT



ONEPLUS ULTRASOUND LAB  
47, Harsh Vihar, Pitampura,  
Delhi-110034  
Ph: 011-42660101, 9599913051  
E-mail: onepplusul@gmail.com





**OnePLUS**  
Ultrasound Lab  
— QUALITY FIRST... ALWAYS! —

**Dr. Nitin Agarwal**

Pathologist & Director  
Ex. Sr. Res. MAMC  
& Lok Nayak Hospital  
Ex. Chief of Lab Dr. Lal Path Labs.

**Dr. Pooja (Garg) Agarwal**

Radiologist & Director  
MAMC & Lok Nayak Hospital

<b>Name</b>	: Mr. SUNIL KUMAR	<b>Age/Sex</b>	: 45 YRS/Male
<b>Ref. By</b>	: Dr. MEDIWHEEL	<b>Lab No</b>	: 012304010003
<b>Date</b>	: 01-Apr-2023	<b>Patient ID</b>	: LSHHI111717

**ULTRASOUND EXAMINATION----WHOLE ABDOMEN**

**Liver** is normal in size (13.8 cm) and outline with altered echopattern. Diffuse increase in echogenicity of liver parenchyma is noted, suggestive of fatty infiltration (grade I). No abscess or mass lesion seen. Hepatic veins, portal vein, IVC and aorta are normal. Intrahepatic biliary radicles are not dilated. CBD is normal in caliber.

**Gall bladder** is well distended with anechoic lumen. Wall thickness is normal.

**Both kidneys** are normal in size, shape, position, outline and echopattern. Corticomedullary differentiation is maintained. No pelvicalyceal dilation or calculus or mass lesion is seen.

**Spleen** is normal in size and echotexture. No mass lesion seen.

**Pancreas** is normal in size, outline and echotexture.

**Urinary bladder** is normal in shape and position. No evidence of intravesical stone or mass seen.

**Prostate is enlarged in size**, normal in shape and echopattern.

**Prostate measures** 4.6 x 4.2 x 3.6 cm. **Weight of prostate is 37.7 grams.**

No abnormal bowel wall thickening seen in right iliac fossa.

No free fluid seen anywhere in abdomen.

**IMPRESSION:**

- Fatty infiltration of liver (grade I) with no hepatomegaly.
- Prostatic hypertrophy.

**DR. POOJA GARG**  
RADIOLOGIST

Dr. POOJA GARG  
M.B.B.S., D.M.R.D.  
Reg No DMC/R/03398  
Radiologist

Type By : darshita

47, Harsh Vihar, Pitampura, New Delhi-110034 | Ph.: 011-42480101, 9599913051

E-mail: oneplusul@gmail.com | Web.: www.oneplusul.in

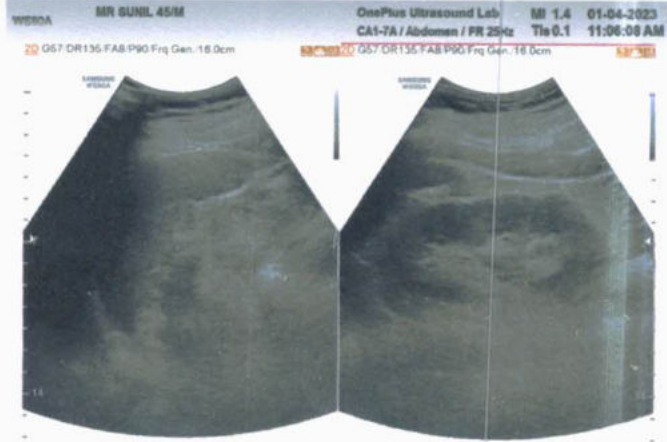
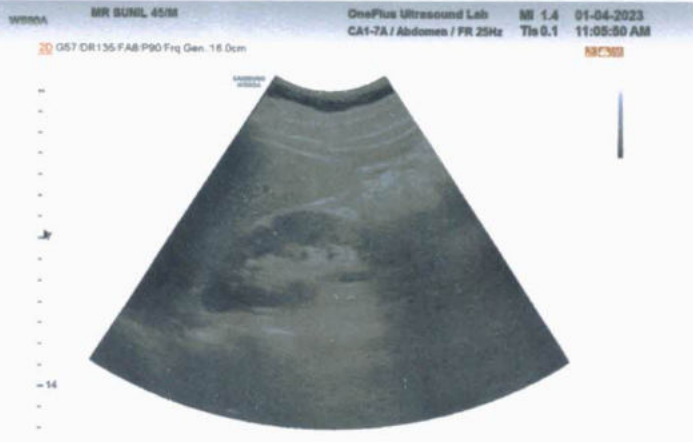
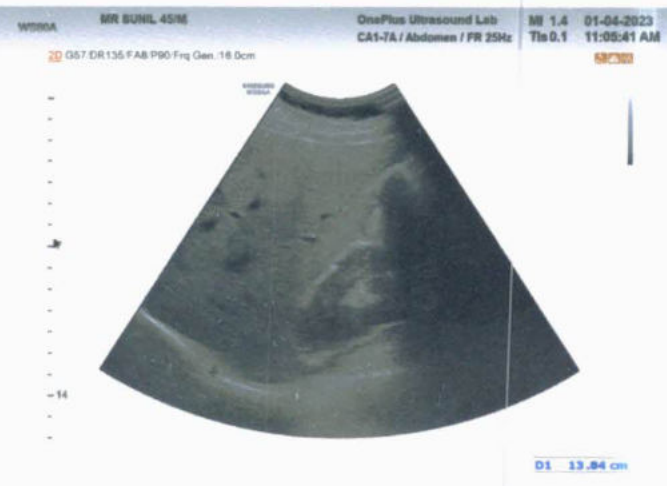
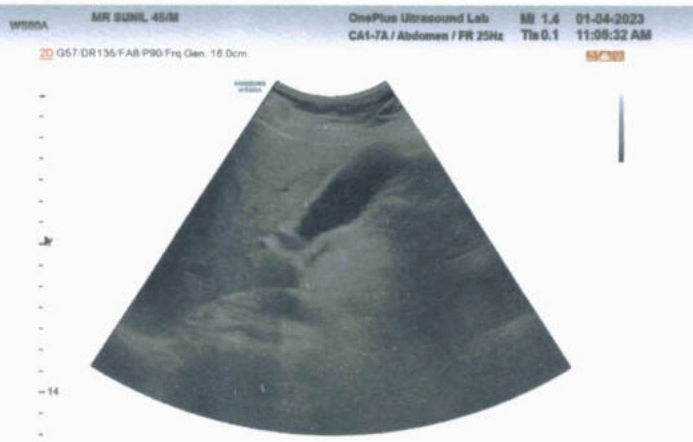
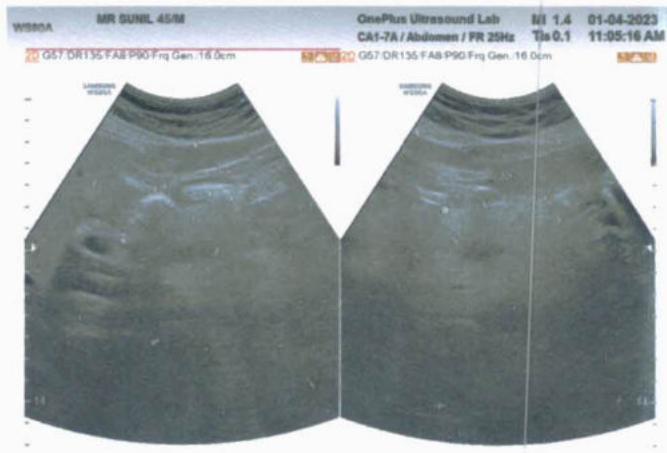
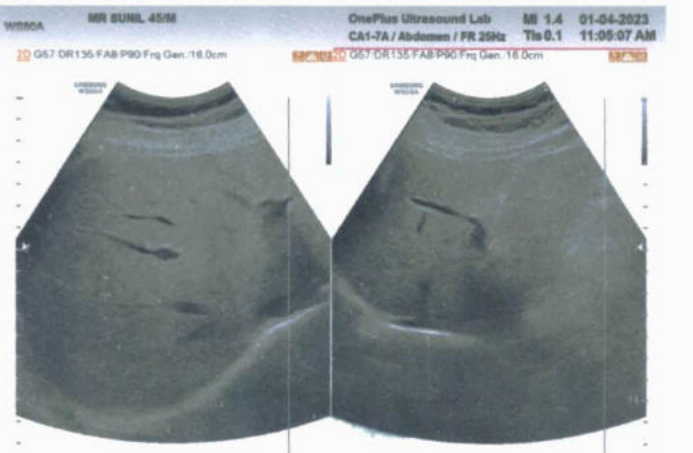
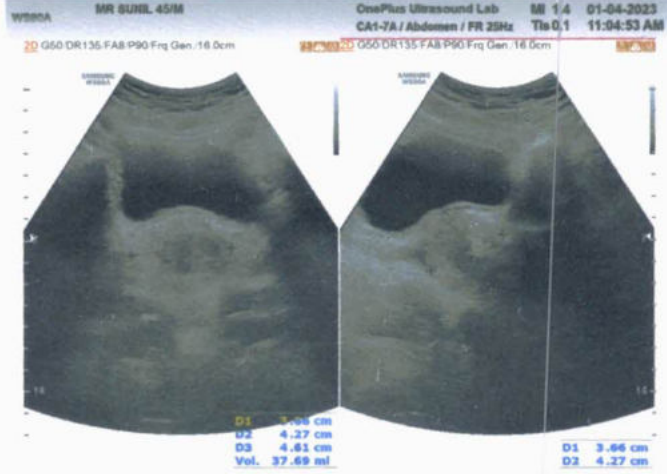
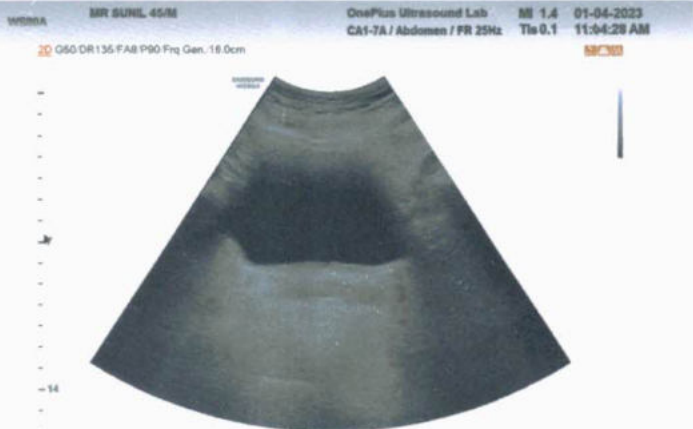




Figure 1: Micrograph of a single fan-shaped biological specimen, possibly a leaf or petal, showing internal cellular structure.




Figure 2: Micrograph of two fan-shaped biological specimens joined at their bases, showing internal cellular structure.



Figure 3: Micrograph of a single fan-shaped biological specimen, similar to Figure 1, showing internal cellular structure.



Figure 4: Micrograph of a single fan-shaped biological specimen, similar to Figure 1, showing internal cellular structure.



Figure 5: Micrograph of two fan-shaped biological specimens joined at their bases, with a small green stain on the top surface.

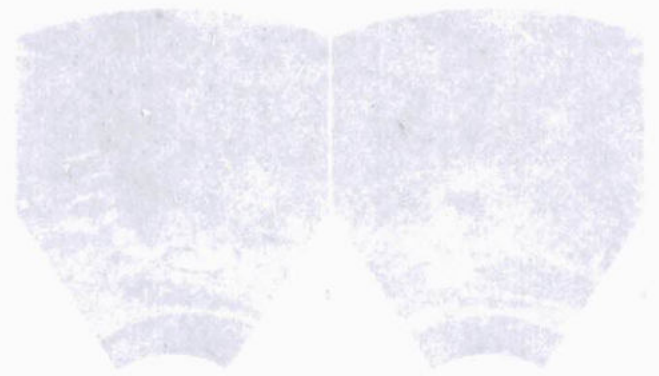


Figure 6: Micrograph of two fan-shaped biological specimens joined at their bases, showing internal cellular structure.




Figure 7: Micrograph of a single fan-shaped biological specimen, showing internal cellular structure.




Figure 8: Micrograph of two fan-shaped biological specimens joined at their bases, showing internal cellular structure.



# OnePLUS Ultrasound Lab

— QUALITY FIRST... ALWAYS! —

**Dr. Nitin Agarwal**  
Pathologist & Director  
Ex. Sr. Res. MAMC  
& Lok Nayak Hospital  
Ex. Chief of Lab Dr. Lal Path Labs.

**Dr. Pooja (Garg) Agarwal**  
Radiologist & Director  
MAMC & Lok Nayak Hospital



NAME	:Mr. SUNIL KUMAR	Barcode No	:10141377
AGE/GENDER	:45 YRS/Male	SPECIMEN DATE	:01/Apr/2023 08:37AM
PATIENT ID	:111717	SPECIMEN RECEIVED	:01/Apr/2023 08:51AM
REFERRED BY	:Dr. MEDIWHEEL	REPORT DATE	:01/Apr/2023 04:08PM
CENTRE NAME	:ONEPLUS ULTRASOUND LAB	LAB NO.	:012304010003

Test Name	Result	Unit	Ref. Range
-----------	--------	------	------------

## HAEMATOLOGY

### Medi Wheel Health Checkup >40 Male

<b>Glycosylated Hemoglobin (HbA1c)</b>	5.2	%	Non Diabetic adults <5.7 Prediabetic (at risk) 5.7-6.4 Diabetes >6.4
--	-----	---	--

**Estimated average blood glucose (eag)** 103

Reference range (mg/dl):

90 - 120:Excellent control, 121 - 150:Good Control, 151 - 180:Average Control, 181 - 210:Action Suggested

>211:Panic value

<b>BLOOD GROUP (ABO)</b>	B
<b>Rh typing</b>	POSITIVE

#### NOTE :

- \* Apart from major A,B,H antigens which are used for ABO grouping and Rh typing, many minor blood group antigens exist. Agglutination may also vary according to titre of antigen and antibody.
- \* So before transfusion, reconfirmation of blood group as well as cross-matching is needed.
- \* Presence of maternal antibodies in newborns, may interfere with blood grouping.
- \* Auto agglutination (due to cold antibody, falciparum malaria, sepsis, internal malignancy etc.) may also cause erroneous result.

#### CBC

Haemoglobin	14.5	g/dl	13.0-17.0
Total Leucocyte Count	7200	/cumm	4000-10000
<b>Differential leucocyte count</b>			
Neutrophils	58.9	%	40-80
Lymphocyte	35.10	%	20-40
Monocytes	4.00	%	2-10
Eosinophils	1.5	%	1-6
Basophils	0.5	%	0-2
RBC Count	5.10	million/cumm	4.5 - 5.5

Checked By.

Dr. NITIN AGARWAL  
M.B.B.S., M.D. Path  
DMC/R/O  
DR. NITIN AGARWAL  
MBBS, MD(PATHOLOGIST)

47, Harsh Vihar, Pitampura, New Delhi-110034 | Ph.: 011-42480101, 9599913051

E-mail: [oneplusul@gmail.com](mailto:oneplusul@gmail.com) | Web.: [www.oneplusul.in](http://www.oneplusul.in)

Page 1 of 6



# OnePLUS Ultrasound Lab

— QUALITY FIRST... ALWAYS! —

**Dr. Nitin Agarwal**  
Pathologist & Director  
Ex. Sr. Res. MAMC  
& Lok Nayak Hospital  
Ex. Chief of Lab Dr. Lal Path Labs.

**Dr. Pooja (Garg) Agarwal**  
Radiologist & Director  
MAMC & Lok Nayak Hospital



NAME	:Mr. SUNIL KUMAR	Barcode No	:10141377
AGE/GENDER	:45 YRS/Male	SPECIMEN DATE	:01/Apr/2023 08:37AM
PATIENT ID	:111717	SPECIMEN RECEIVED	:01/Apr/2023 08:51AM
REFERRED BY	:Dr. MEDIWHEEL	REPORT DATE	:01/Apr/2023 04:08PM
CENTRE NAME	:ONEPLUS ULTRASOUND LAB	LAB NO.	:012304010003

Test Name	Result	Unit	Ref. Range
PCV(Hematocrit)	49.1	%	40-50
MCV	95.7	fL	83-101
MCH	28.3	Pg	27-32
MCHC	29.5	G/dL	32-35
Platelet count	355000	/cumm	150000-450000
RDW-CV	14	%	11.4-14.0
ESR(WESTEGRENs METHOD)	12	mm in 1st hr	0-20

### BIOCHEMISTRY

<u>Blood sugar fasting</u>	75	mg/dL	70-110
<u>Blood sugar pp</u>	128	mg/dL	70.0-140.0
<u>Bun (blood urea nitrogen )</u>	12.60	mg/dl	8.9-21.6
<u>Uric acid, serum</u>	4.6	mg/dl	3.5-7.2
<u>Creatinine, serum</u>	0.69	mg/dl	0.60-1.2

### LFT(LIVER FUNCTION TEST)

Bilirubin Total	0.54	mg/dl	0.1-1.2
Bilirubin Conjugated	0.24	mg/dl	0-0.4
Bilirubin Unconjugated	0.3	mg/dl	up to 0.7
SGOT (AST)	29	U/L	0-46
SGPT (ALT)	28	U/L	0-49
Alkaline phosphatase	95	U/L	40-129
Gamma glutamyl transpeptidase	26	U/L	10-45
Total Protein	6.9	gm/dl	6.60 - 8.70
Albumin serum	3.8	g/dL	3.0-5.2
Globulin	3.10	gm/dl	1.8-3.4
Albumin/Globulin Ratio	1.23		1.10 - 2.50

### LIPID PROFILE

Cholesterol	240	mg/dl	50-200
Triglycerides	207	mg/dL	25-150

Checked By.

DR. NITIN AGARWAL  
MBBS, MD  
DMC/R/01436

47, Harsh Vihar, Pitampura, New Delhi-110034 | Ph.: 011-42480101, 9599913051  
E-mail: onepusul@gmail.com | Web.: www.onepusul.in

Page 2 of 6



# OnePLUS Ultrasound Lab

— QUALITY FIRST... ALWAYS! —

**Dr. Nitin Agarwal**  
Pathologist & Director  
Ex. Sr. Res. MAMC  
& Lok Nayak Hospital  
Ex. Chief of Lab Dr. Lal Path Labs.

**Dr. Pooja (Garg) Agarwal**  
Radiologist & Director  
MAMC & Lok Nayak Hospital



NAME	:Mr. SUNIL KUMAR	Barcode No	:10141377
AGE/GENDER	:45 YRS/Male	SPECIMEN DATE	:01/Apr/2023 08:37AM
PATIENT ID	:111717	SPECIMEN RECEIVED	:01/Apr/2023 08:51AM
REFERRED BY	:Dr. MEDIWHEEL	REPORT DATE	:01/Apr/2023 04:08PM
CENTRE NAME	:ONEPLUS ULTRASOUND LAB	LAB NO.	:012304010003

Test Name	Result	Unit	Ref. Range
HDL Cholesterol	45	mg/dL	40 - 60
LDL cholesterol	154	mg/dL	<130
VLDL cholesterol	41.4	mg/dL	5-40
Cholesterol/HDL Ratio	5.3		Low Risk 3.3-4.97 Average Risk 4.4-7.1 Moderate Risk 7.1-11.0 High Risk >11.0
LDL/HDL Ratio	3.4		0 - 3.55

According to ATP III and NCEP guidelines

Parameter	Normal	Desirable	Borderline	High
Total cholesterol	<200		200-239	240
Triglycerides	<150	150-199	200-499	500
LDL	Optimal <100 Near Optimal 100-129	130-159	160-180	190
HDL	<40 : LOW 60 : HIGH			

### BUN/Creatinine ratio

Bun (blood urea nitrogen )	12.60	mg/dl	8.9-21.6
CREATININE	0.40	mg/dl	0.30-1.10
BUN/Creatinine ratio	31.50		10.0 - 20.0

### ENDOCRINOLOGY

#### PSA TOTAL

Prostatic specific antigen, Total 2.00 ng/ml <4.0

< 40 years	0.21 to 1.72 ng/ml
40 - 49	0.27 to 2.19 ng/ml
50, - 59	0.27 to 3.42 ng/ml

Checked By.

Dr. NITIN AGARWAL  
M.B.B.S., MD (Pathology)  
DMC/R/01438  
DR. NITIN AGARWAL  
MBBS, MD (PATHOLOGIST)

47, Harsh Vihar, Pitampura, New Delhi-110034 | Ph.: 011-42480101, 9599913051

E-mail: [oneplusul@gmail.com](mailto:oneplusul@gmail.com) | Web.: [www.oneplusul.in](http://www.oneplusul.in)

Page 3 of 6

Clinical correlation is essential for final diagnosis. • If test results are unsatisfactory please contact personally or on phone. • This report is for perusal of doctors only. • All disputes Subject to Delhi Jurisdiction only. • Not for medicolegal purposes. • All congenital anomalies in a foetus may not be diagnosed in routine obstetric ultrasound.





# OnePLUS Ultrasound Lab

QUALITY FIRST... ALWAYS!

**Dr. Nitin Agarwal**

Pathologist & Director  
Ex. Sr. Res. MAMC  
& Lok Nayak Hospital  
Ex. Chief of Lab Dr. Lal Path Labs.

**Dr. Pooja (Garg) Agarwal**

Radiologist & Director  
MAMC & Lok Nayak Hospital



NAME	:Mr. SUNIL KUMAR	Barcode No	:10141377
AGE/GENDER	:45 YRS/Male	SPECIMEN DATE	:01/Apr/2023 08:37AM
PATIENT ID	:111717	SPECIMEN RECEIVED	:01/Apr/2023 08:51AM
REFERRED BY	:Dr. MEDIWHEEL	REPORT DATE	:01/Apr/2023 04:08PM
CENTRE NAME	:ONEPLUS ULTRASOUND LAB	LAB NO.	:012304010003

Test Name	Result	Unit	Ref. Range
60 - 69	0.22 to 6.16 ng/ml		
> 69	0.21 to 6.77 ng/ml		

### Notes:

PSA is principally produced by the glandular epithelium of the prostate, and is secreted in the seminal fluid. PSA is also present in urine and blood. PSA acts on seminal fluid to fluidify and increase sperm mobility. PSA levels rise in prostatic pathologies such as benign prostatic hyperplasia (BPH) or prostate cancer.

### THYROID PROFILE(T3,T4,TSH)

Triiodothyronine total [t3]	0.84	ng/dl	0.52-1.9
Thyroxine total [t4]	7.60	µg/dl	4.4 - 10.8
TSH (Thyroid Stimulating Hormone)	5.90	µIU/ml	0.25-5.0

### AGE WISE VARIATION IN TSH

AGE	TSH(µIU/ml)	AGE	TSH(µIU/ml)
1-4 weeks	1.00 - 19.0	16-20 yrs	0.25 - 5.0
1-12 mths	1.70 - 9.1	21 - 80 yrs	0.25 - 5.0
1-5 yrs	0.80 - 8.2	I <sup>st</sup> trimester	0.25 - 5.0
6-10 yrs	0.25 - 5.0	II <sup>nd</sup> trimester	0.50 - 5.0
11-15 yrs	0.25 - 5.0	III <sup>rd</sup> trimester	0.4 - 6.0

### Reference ranges - Interpretation of Diagnostic tests - (Jacques Wallach)

1. Primary hypothyroidism is accompanied by depressed serum T3 and T4 values and elevated serum TSH level.
2. Primary hyperthyroidism is accompanied by elevated serum T3 and T4 levels along with depressed TSH values.
3. Slightly elevated T3 levels may be found in pregnancy and estrogen therapy, while depressed levels may be encountered in severe illness, renal failure and during therapy with drugs like propranolol and propyl thiouracil.
4. Although elevated TSH levels are nearly always indicative of primary hypothyroidism, and may be seen in secondary thyrotoxicosis

### CLINICAL PATHOLOGY

#### URINE ROUTINE

#### Physical examination

Checked By.

Dr. NITIN AGARWAL  
M B B S, MD  
DMC/R/01436  
DR. NITIN AGARWAL  
MBBS,MD(PATHOLOGIST)

47, Harsh Vihar, Pitampura, New Delhi-110034 | Ph.: 011-42480101, 9599913051

E-mail: oneplusul@gmail.com | Web.: www.oneplusul.in

Page 4 of 6



# OnePLUS Ultrasound Lab

— QUALITY FIRST... ALWAYS! —

**Dr. Nitin Agarwal**

Pathologist & Director  
Ex. Sr. Res. MAMC  
& Lok Nayak Hospital  
Ex. Chief of Lab Dr. Lal Path Labs.

**Dr. Pooja (Garg) Agarwal**

Radiologist & Director  
MAMC & Lok Nayak Hospital



NAME	:Mr. SUNIL KUMAR	Barcode No	:10141377
AGE/GENDER	:45 YRS/Male	SPECIMEN DATE	:01/Apr/2023 08:37AM
PATIENT ID	:111717	SPECIMEN RECEIVED	:01/Apr/2023 08:51AM
REFERRED BY	:Dr. MEDIWHEEL	REPORT DATE	:01/Apr/2023 04:08PM
CENTRE NAME	:ONEPLUS ULTRASOUND LAB	LAB NO.	:012304010003

Test Name	Result	Unit	Ref. Range
Quantity	20		ML
Colour	PALE YELLOW		
Transparency	CLEAR		CLEAR
Sp.gravity	1.015		1.010-1.030
pH	6.00		
Reaction	ACIDIC		ACIDIC
<b><u>Chemical examination</u></b>			
Urine protein	NIL		NIL
Urine sugar	NIL		NIL
Bilirubin, urine	NEGATIVE		NEGATIVE
Urobilinogen	NORMAL		NORMAL
Ketones	NEGATIVE		NEGATIVE
<b><u>Microscopic examination</u></b>			
<b>Pus cells.</b>	1-2	/HPF	0-2
Epithelial cells	1-2	/HPF	NIL
R.B.C.	NIL	/HPF	NIL
Casts	NIL	/HPF	NIL
Crystals	NIL	/HPF	NIL
Bacteria	NIL	/HPF	NIL
Others.	NIL	NIL	NIL
<b>STOOL ROUTINE</b>			
<b><u>Physical examination</u></b>			
Colour	BROWNISH		
Consistency	SEMI FORMED		Semi Formed
Blood	ABSENT		Absent
Mucus	ABSENT		Absent
<b><u>Chemical examination, stool</u></b>			
pH	6.00		
<b><u>Microscopic examination</u></b>			

Checked By.

DR. NITIN AGARWAL  
MBBS, MD (Path)  
DMC/R/01436

47, Harsh Vihar, Pitampura, New Delhi-110034 | Ph.: 011-42480101, 9599913051

E-mail: [oneplusul@gmail.com](mailto:oneplusul@gmail.com) | Web.: [www.oneplusul.in](http://www.oneplusul.in)

Page 5 of 6

Clinical correlation is essential for final diagnosis. • If test results are unsatisfactory please contact personally or on phone. • This report is for perusal of doctors only.  
• All disputes Subject to Delhi Jurisdiction only. • Not for medicolegal purposes. • All congenital anomalies in a foetus may not be diagnosed in routine obstetric ultrasound.



# OnePLUS Ultrasound Lab

— QUALITY FIRST... ALWAYS! —

**Dr. Nitin Agarwal**  
Pathologist & Director  
Ex. Sr. Res. MAMC  
& Lok Nayak Hospital  
Ex. Chief of Lab Dr. Lal Path Labs.

**Dr. Pooja (Garg) Agarwal**  
Radiologist & Director  
MAMC & Lok Nayak Hospital



NAME	:Mr. SUNIL KUMAR	Barcode No	:10141377
AGE/GENDER	:45 YRS/Male	SPECIMEN DATE	:01/Apr/2023 08:37AM
PATIENT ID	:111717	SPECIMEN RECEIVED	:01/Apr/2023 08:51AM
REFERRED BY	:Dr. MEDIWHEEL	REPORT DATE	:01/Apr/2023 04:08PM
CENTRE NAME	:ONEPLUS ULTRASOUND LAB	LAB NO.	:012304010003

Test Name	Result	Unit	Ref. Range
Pus cells	NIL	/HPF	
R.B.C.	NIL	/HPF	NIL
Ova	NIL		NIL
Cysts	NIL		NIL
Bacteria	PRESENT	/HPF	NIL
Others	NIL		

\*\*\* End Of Report \*\*\*

Checked By.

Dr. NITIN AGARWAL  
M B B S . MD (Pathology)  
DMC/R/01436  
DR. NITIN AGARWAL  
MBBS,MD(PATHOLOGIST)

47, Harsh Vihar, Pitampura, New Delhi-110034 | Ph.: 011-42480101, 9599913051  
E-mail: oneplusul@gmail.com | Web.: www.oneplusul.in

Page 6 of 6

Clinical correlation is essential for final diagnosis. • If test results are unsatisfactory please contact personally or on phone. • This report is for perusal of doctors only.  
• All disputes Subject to Delhi Jurisdiction only. • Not for medicolegal purposes. • All congenital anomalies in a foetus may not be diagnosed in routine obstetric ultrasound.



**OnePLUS**  
Ultrasound Lab  
— QUALITY FIRST... ALWAYS! —

**Dr. Nitin Agarwal**

Pathologist & Director  
Ex. Sr. Res. MAMC  
& Lok Nayak Hospital  
Ex. Chief of Lab Dr. Lal Path Labs.

**Dr. Pooja (Garg) Agarwal**

Radiologist & Director  
MAMC & Lok Nayak Hospital

Name	: Mr. SUNIL KUMAR	Age/Sex	: 45 YRS/Male
Ref. By	: Dr. MEDIWHEEL	Lab No	: 012304010003
Date	: 01-Apr-2023	Patient ID	: LSHHI111717

## X-ray-Chest PA view

Bony cage and soft tissues are normal.  
Cardiothoracic ratio is normal.  
Mediastinum is normal.  
Both hila are normal.  
Both costophrenic angles are clear.  
Both domes of diaphragm are normal.  
Lung fields are clear. No parenchymal lesion seen.

**IMPRESSION: Normal Study.**

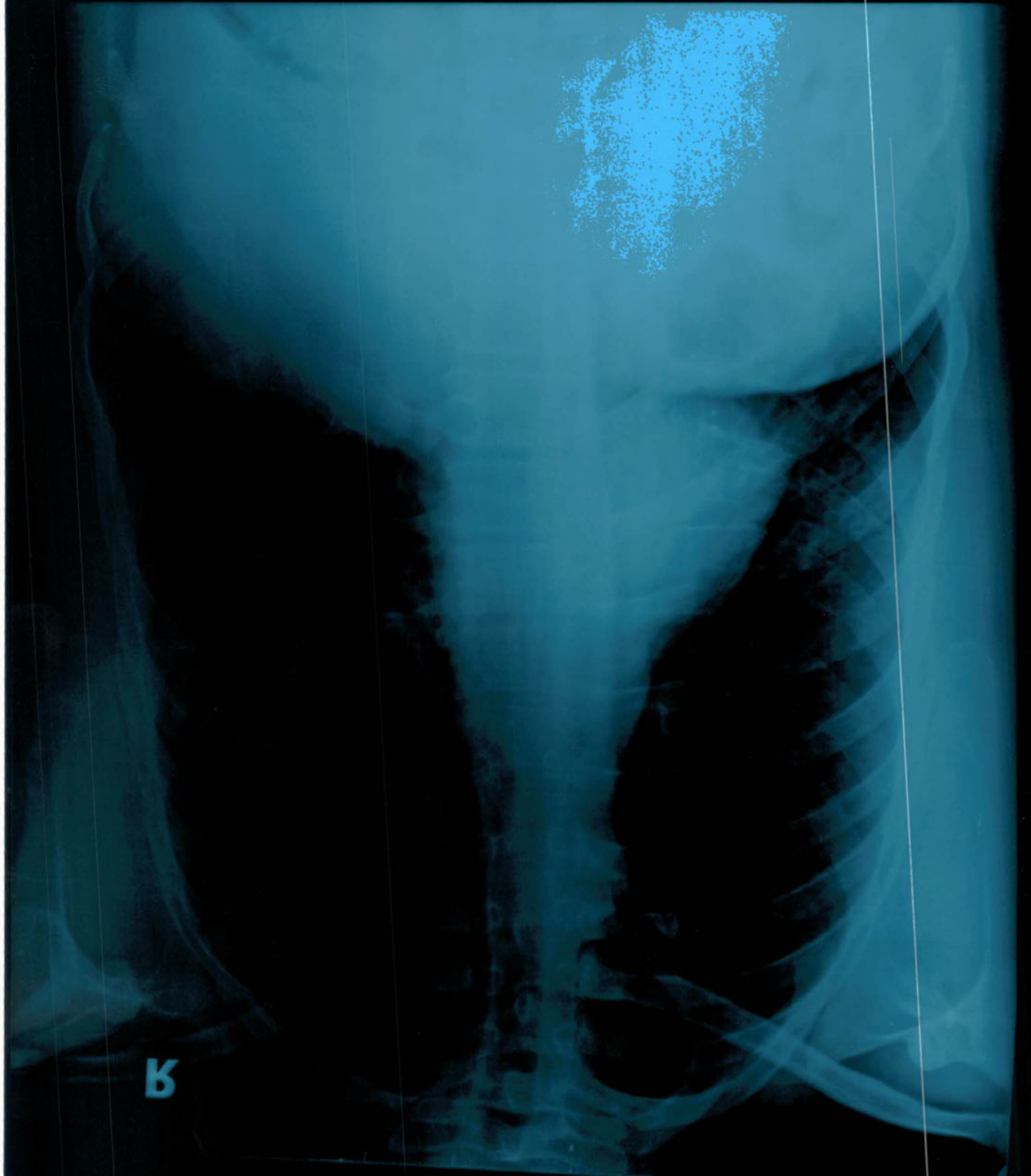
**DR. POOJA GARG**  
RADIOLOGIST  
REG NO- DMC/R/03398

Dr. POOJA GARG  
M.B.B.S., D.M.R.D  
Reg No. DMC/R/03398  
Radiologist

Type By : darshita

47, Harsh Vihar, Pitampura, New Delhi-110034 | Ph.: 011-42480101, 9599913051  
E-mail: oneplusul@gmail.com | Web.: www.oneplusul.in

ОИЕБГУС ПГТВАСОИИД ГАВ 47 НАР2Н АНАР 6ТАМЬУВА  
2011Г КУМАР 42УМ 110415053 М СЕШТА АНЕМ 4115053



**B**

R

SUNIL KUMAR 45Y/M 1/04/2023 M CHEST PA VIEW 4/1/2023  
ONEPLUS ULTRASOUND LAB, 47-HARSH VIHAR, PITAMPURA