

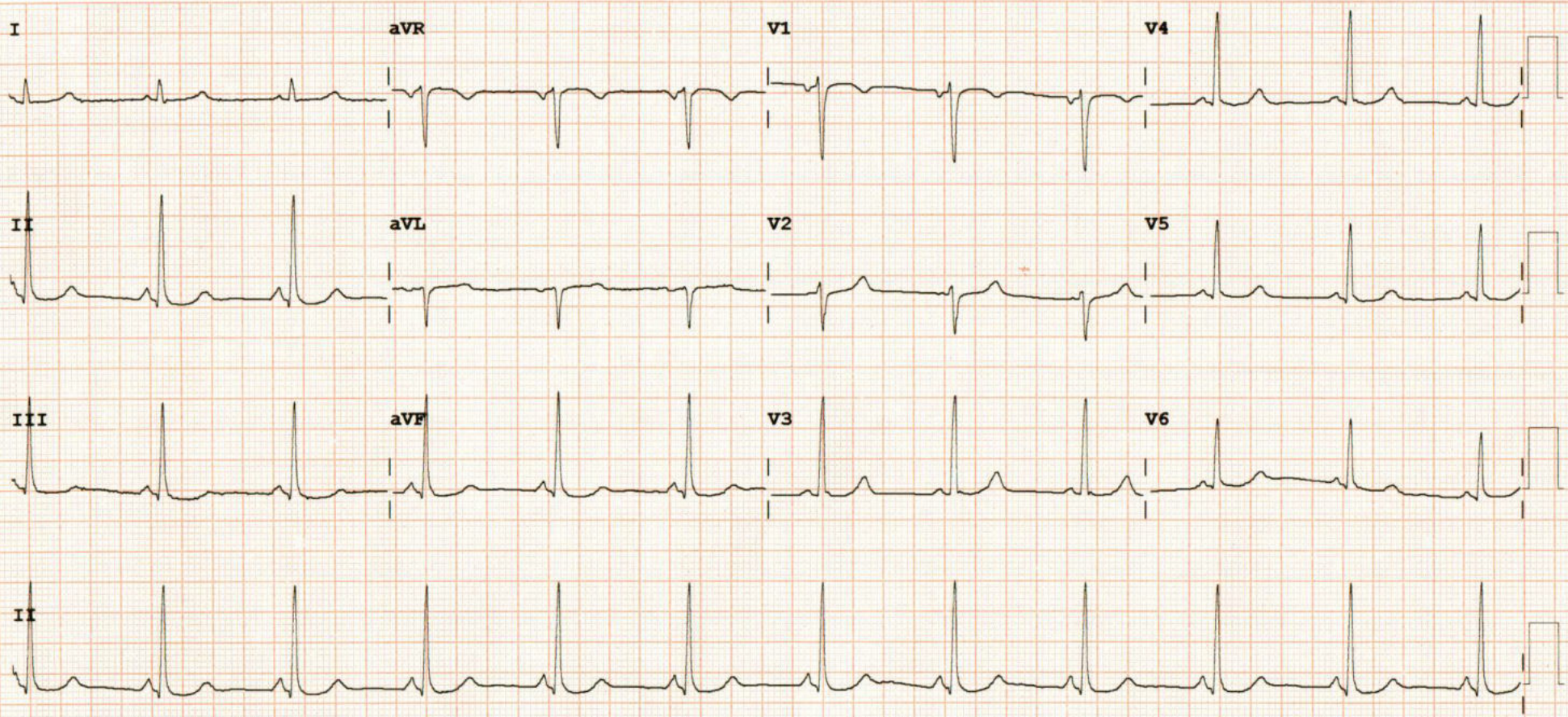
Female

Rate 69
 PR 108
 QRSD 91
 QT 396
 QTc 425

--AXIS--

P 70
 QRS 79
 T 29

12 Lead; Standard Placement



Device:

Speed: 25 mm/sec

Limb 10 mm/mV

Chest: 10.0 mm/mV

F 50~ 0.15-100 Hz

100B

CL

P?

Patient Name : Mrs. Nandini MN. **Age /Sex :** 87/F. **UHID No.:** 210809 **Date :** 28/8/23.

Chief Complaints :

Routine check up.
mild stickiness of eyes and tearing
No visual complaints.

Others : Cold, Fever, Nausea, Vomiting, Giddiness.

Past History : Eye Treatment (Y/N) Eye Operation (Y/N)

General Health : DM HTN Heart Disease Br. Asthma Allergies Any Others

VISION **Right Eye** **Left Eye**

PL :

Distant PH :

6/6

6/6

GL :

Near PL :

N6

N6

GL :

Colour vision:

(2)

AMSLER GRID :

AR Reading:

Dry	SPH	CYL	AXIS
RE			
LE			

Wet	SPH	CYL	AXIS
RE			
LE			

Acceptance :

RIGHT EYE				LEFT EYE			
SPH	CYL	AXIS	VA	SPH	CYL	AXIS	VA


IPD :

Ocular Examination : Extra Ocular Movements :-

RIGHT EYE

LEFT EYE

Anterior Segment



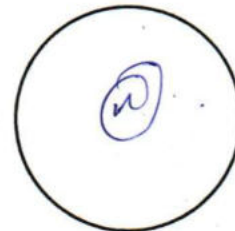

Posterior Segment

- Lens
- Media
- DISC
- Macula
- Blood Vessels
- BGF

Fundus:

Right Eye

Left Eye



IOP : $\begin{matrix} 16 \\ 18 \end{matrix}$ mm Hg

Provisional Diagnosis: Both eyes normal,

Medicine & Advice: Both eyes
 Refresh tears as & when reqd.

Annual eye check up

25/3/25

Date & Time

[Signature]

Dr. Name & Signature

UHID / IP NO	210809 (15198)	RISNo./Status :	58513/ WE CURE WITH CARE
Patient Name :	Mrs. NANDINI M N	Age/Gender :	37 Y/F (A Unit of Sree Vasavi Trust)
Referred By :	Dr. SRIDHAR SRINIVASAN G	Ward/Bed No :	OPD
Bill Date/No :	25/03/2023 8:33AM/ OPCR/23/7552	Scan Date :	
Report Date :	25/03/2023 12:08PM	Company Name:	Mediwheel (Arcofemi Healthcare Limited)

M- MODE MEASUREMENTS

AO	2.43	cm	RVIDD	1.20	cm
LA	2.60	cm	IVSD	0.83	cm
AO/LA RATIO	0.75	cm	LVIDD	3.89	cm
AV CUP	1.46	cm	LVPWD	1.07	cm
EPSS	0.9	cm	IVSS	1.18	cm
DE	1.83	cm	LVIDS	2.52	cm
EF SLOPE	0.7	cm	LVPWS	1.30	cm
SV	57.41		EDV	65.52	ml
CO			ESV	22.34	ml
HR			EF	65.73	%
LVMI			FS	35.90	%
OTHERS			LV MASS	185.32	grams

DESCRIPTIVE FINDINGS: Technically Adequate Study. Normal Sinus rhythm during Study.

LEFT VENTRICLE	Normal in size
LEFT ATRIUM	Normal in size
RIGHT VENTRICLE	Normal in size
RIGHT ATRIUM	Normal in size
WALL MOTION ANALYSIS	No RWMA
TRICUSPID VALVE	Mild TR With Mild PAH(PASP-38mmHg)
MITRAL VALVE	Normal
PULMONIC VALVE	Normal
AORTIC VALVE	Normal
IAS & IVS	Intact
AORTA & PA	Normal In Size
SYSTEMIC & PULMONARY VENIS	Normally Draining
PERICARDIUM	Normal
OTHERS	No Intra Cardiac Thrombus, Tumour or Vegetation

CARDIOLOGY

UHID / IP NO	210809 (15198)	RISNo./Status :	58513/
Patient Name :	Mrs. NANDINI M N	Age/Gender :	37 Y/F
Referred By :	Dr. SRIDHAR SRINIVASAN G	Ward/Bed No :	OPD
Bill Date/No :	25/03/2023 8:33AM/ OPCR/23/7552	Scan Date :	
Report Date :	25/03/2023 12:08PM	Company Name:	Mediwheel (Arcofemi Healthcare Limited).

DOPPLER STUDY

VALVES	VELOCITY	GRADIENT	REGURGITATION	OTHERS
P V	0.71m/s		NO PR	
MV	E: 1.14 m/s A: 0.86 m/s		NO MR	
AV	1.53 m/s		NO AR	
TV	E: 0.60m/s A: 0.40m/s	PASP-38mmHg	MILD TR	MILD PAH
OTHERS				

SUMMARY FINDINGS:

NORMAL CARDIAC CHAMBERS

NO REGIONAL WALL MOTION ABNORMALITY AT REST

NORMAL LV SYSTOLIC FUNCTION (EF-65 %)

MILD TR WITH MILD PAH (PASP-38mmHg)

NO CLOT / EFFUSION / VEGETATION

Dr. PRANEETHS
CONSULTANT
CARDIOLOGIST

Mr. Naveen Kumar M K



Vasavi Hospitals

LABORATORY

WE CURE WITH CARE

(A Unit of Sree Vasavi Trust)

Patient Name	Mrs. NANDINI M N	Lab No	58513
UHID	210809	Sample Date	25/03/2023 8:33AM
Age/Gender	37 Yrs/Female	Receiving Date	25/03/2023 9:32AM
Bed No/Ward	OPD	Report Date	25/03/2023 1:35PM
Referred By	Dr. SRIDHAR SRINIVASAN G	Report Status	Final
Bill No.	OPCR/23/7552	Manual No.	

HAEMATOLOGY

Test Name	Result	Unit	Biological Ref. Range	Method
BLOOD GROUP	"A"			
RH TYPE	POSITIVE			
			Sample: Blood	
HAEMOGLOBIN	13.5	gm/dl	12.00 - 16.00	
TOTAL COUNT	7240	cells/cumm	4500.00 - 11000.00	
DLC				
NEUTROPHILS	66	%	35.00 - 66.00	
LYMPHOCYTES	25	%	24.00 - 44.00	
MONOCYTES	06	%	4.00 - 10.00	
EOSINOPHILS	03	%	1.00 - 6.00	
BASOPHILS	00	%	0.00 - 1.00	
R.B.C COUNT	4.64	mill/cumm	4.00 - 5.20	
PACKED CELL VOLUME (PCV)	38.8	%	36.00 - 46.00	
PLATELET COUNT	2.24	lakh/cumm	1.50 - 4.50	
M.C.V	83.6	fL	80.00 - 100.00	
M.C.H	29.2	pg	26.00 - 34.00	
M.C.H.C	34.9	%	32.00 - 36.00	
ESR (ERYTHROCYTE SEDIMENTATION RATE)	11	mm/hr	0.00 - 12.00	

--End Of Report--



Badarini

Verified By

BADARINATH S
MD (PGI) KMC No 19014

#15, 70th Cross, 14th Main, 1st Stage, Kumaraswamy Layout (Opp. to 15 E Bus Stop), Bengaluru - 560 078

080 7150 0500 / 88844 66000 info@vasavihospitals.com www.vasavihospitals.com

Printed on 25/03/2023 15:06

Page: 4 Of 4



Vasavi Hospitals

LABORATORY

WE CURE WITH CARE

(A Unit of Sree Vasavi Trust)

Patient Name	Mrs. NANDINI M N	Lab No	58513
UHID	210809	Sample Date	25/03/2023 8:33AM
Age/Gender	37 Yrs/Female	Receiving Date	25/03/2023 9:32AM
Bed No/Ward	OPD	Report Date	25/03/2023 2:52PM
Referred By	Dr. SRIDHAR SRINIVASAN G	Report Status	Final
Bill No.	OPCR/23/7552	Manual No.	

BIOCHEMISTRY

Test Name	Result	Unit	Biological Ref. Range	Method
Sample: Serum				
BLOOD UREA NITROGEN	15.5	mg/dl	Upto 14 years : 5 - 18 mg/dl Male (above 14 years): 8 - 24 mg/dl Female (above 14 years): 6 - 21 mg/dl Pregnant women : 5 - 12 mg/dl	
SERUM CREATININE	0.66	mg/dl	0.60 - 1.40	
FASTING BLOOD SUGAR	93.3	mg/dl	74.00 - 100.00	
GLYCOSYLATED HAEMOGLOBIN (HbA1c)				
HbA1c (GLYCOSYLATED Hb)	4.4	%	4.00 - 6.00	Immunoturbidimetric
MEAN BLOOD GLUCOSE	79.58	mg/dl	70.00 - 140.00	
LIPID PROFILE				
TOTAL CHOLESTEROL	168	mg/dl	0.00 - 200.00	
TRIGLYCERIDES	51.3	mg/dl	0.00 - 200.00	
HDL CHOLESTEROL - DIRECT	43.6	mg/dl	35.00 - 55.00	
LDL CHOLESTEROL - DIRECT	85.6	mg/dl	0.00 - 130.00	
TC/HDL	3.85			
LDL/HDL	1.96			

Sample: Serum

LIVER FUNCTION TEST (LFT)

Verified By

Ravi Shankar K

#15, 70th Cross, 14th Main, 1st Stage, Kumaraswamy Layout (Opp. to 15 E Bus Stop), Bengaluru - 560 078

080 7150 0500 / 88844 66000 info@vasavihospitals.com www.vasavihospitals.com

Printed on 25/03/2023 15:06

Page: 1 Of 4



Vasavi Hospitals

LABORATORY

WE CURE WITH CARE

(A Unit of Sree Vasavi Trust)

Patient Name	Mrs. NANDINI M N	Lab No	58513
UHID	210809	Sample Date	25/03/2023 8:33AM
Age/Gender	37 Yrs/Female	Receiving Date	25/03/2023 9:32AM
Bed No/Ward	OPD	Report Date	25/03/2023 2:52PM
Referred By	Dr. SRIDHAR SRINIVASAN G	Report Status	Final
Bill No.	OPCR/23/7552	Manual No.	

TOTAL BILIRUBIN 0.27 mg/dl Adult - 0.2 - 1.3 mg/ dL

Special condition:

Premature - <2.0 mg/ dL
 Full term - <2.0 mg/ dL
 0-1 day - Premature- 1.0 - 8.0 mg/ dL
 0-1 day - Full term - 2.0 - 6.0 mg/ dL
 1 - 2 days Premature - 6.0 - 12.0 mg/ dL
 1 - 2 days Full term - 6.0 - 10.0 mg/ dL
 3 - 5 days Premature - 10.0 - 14.0 mg/ dL
 3 - 5 days Full term - 4.0 - 8.0 mg/ dL

DIRECT BILIRUBIN	0.15	mg/dl	0.00 - 0.30
INDIRECT BILIRUBIN.	0.12	mg/dl	
ASPARATE AMINOTRANSFERASE (SGOT/AST)	24.0	U/L	0.00 - 40.00
ALANINE AMINOTRANSFERASE (SGPT/ALT)	15.5	U/L	0.00 - 40.00
ALKALINE PHOSPHATASE (ALP)	78	IU/L	42.00 - 98.00
TOTAL PROTEIN	6.65	g/dl	6.00 - 8.50
SERUM ALBUMIN	4.19	g/dl	3.50 - 5.20
SERUM GLOBULIN	2.46	g/dl	2.30 - 3.50
A/G RATIO	1.70 H	%	1.00 - 1.50
POST PRANDIAL BLOOD GLUCOSE	78	mg/dl	70.00 - 140.00
URIC ACID	4.2	mg/dl	3.20 - 6.40

--End Of Report--

Ravi Shankar

Verified By

Ravi Shankar K

#15, 70th Cross, 14th Main, 1st Stage, Kumaraswamy Layout (Opp. to 15 E Bus Stop), Bengaluru - 560 078

080 7150 0500 / 88844 66000 info@vasavihospitals.com www.vasavihospitals.com

Printed on 25/03/2023 15:06

Page: 2 Of 4

Gastroenterology • Neurology • Orthopaedics • General Surgery • Obstetrics & Gynecology • Nephrology & Urology • ENT • Emergency & Critical Care



Vasavi Hospitals

LABORATORY

WE CURE WITH CARE

(A Unit of Sree Vasavi Trust)

Patient Name	Mrs. NANDINI M N	Lab No	58513
UHID	210809	Sample Date	25/03/2023 8:33AM
Age/Gender	37 Yrs/Female	Receiving Date	25/03/2023 12:40PM
Bed No/Ward	OPD	Report Date	25/03/2023 3:02PM
Referred By	Dr. SRIDHAR SRINIVASAN G	Report Status	Final
Bill No.	OPCR/23/7552	Manual No.	

CLINICAL PATHOLOGY

Test Name	Result	Unit	Biological Ref. Range	Method
UIRNE GLUCOSE FASTING				
URINE SUGAR	NIL		NEGATIVE	Sample: Urine
PHYSICAL CHARACTERS				
COLOUR	Pale Yellow			
APPEARANCE	Clear		Clear	
SPECIFIC GRAVITY	1.025			
PH	6.0			
CHEMICAL CONSTITUENTS				
ALBUMIN	Nil			
SUGAR	Nil			
BILE SALTS	Absent			
BILE PIGMENTS	Absent			
KETONE BODIES	NEGATIVE			
BLOOD	Absent			
MICROSCOPY				
PUS CELLS	1-2 /HPF			
R.B.C	Nil			
EPITHELIAL CELLS	2-3/HPF			
CASTS	Nil			
CRYSTALS	Nil			
BACTERIA	Absent			
URINE GLUCOSE-POST PRANDIAL				
URINE SUGAR	NIL		NEGATIVE	

--End Of Report--

Verified By

BADARINATH S
MD (PGI) KMC No 19014

#15, 70th Cross, 14th Main, 1st Stage, Kumaraswamy Layout (Opp. to 15 E Bus Stop), Bengaluru - 560 078

080 7150 0500 / 88844 66000 info@vasavihospitals.com www.vasavihospitals.com

Printed on 25/03/2023 15:06

Page: 3 Of 4



Patient Name	Mrs. NANDINI M N	RIS No	58513
UHID	210809	Order Date	25/03/2023 8:33AM
Age/Gender	37 Yrs/Female	Receiving Date	25/03/2023 11:47AM
Bed No/Ward	OPD	Report Date	25/03/2023 11:53AM
Referred By	Dr. SRIDHAR SRINIVASAN G	Report Status	Final
Bill No.	OPCR/23/7552	Manual No.	25602

LIVER: Liver is 11.0 cm in size, both lobes of liver are normal in size with homogeneous echotexture. No evidence of any focal lesion / intrahepatic biliary dilatation noted. CBD and Portal vein normal in size and echotexture.

GALL BLADDER: Well distended, gall bladder wall thickness is normal. **Multiple calculi are seen of size 3 to 6 mm.**

PANCREAS: Head and body appears normal. Uncinate process and tail could not be assessed due to bowel gas. MPD is normal.

SPLEEN: Normal in size measuring 8.3 cms with normal echotexture.

KIDNEYS: Both Kidneys are normal in size, shape, contour & position. Cortico medullary differentiation is well maintained. No evidence of any hydronephrosis / hydroureter. **Calculi measuring 4 mm is seen in the lower pole and 2.5 mm in the interpolar region of left kidney.**

Right Kidney measures : 9.5 x 3.2 cms. Parenchymal thickness 1.4 cms.

Left Kidney measures : 9.1 x 4.3 cms. Parenchymal thickness 1.6 cms.

URINARY BLADDER: Well distended with clear contents. Wall thickness is normal.

UTERUS: Normal in size and echotexture, measuring 8.2 x 3.6 x 5.4 cms. Myometrial echoes appear normal. Endometrium appears normal, measures 7.6 mm.

OVARIES: Both ovaries are normal in size and echotexture.

Right ovary: 2.7 x 1.8 cms. Left ovary: 2.6 x 1.6 cms.


No obvious free fluid in the peritoneal cavity.

IMPRESSION:

- **CHOLELITHIASIS.**

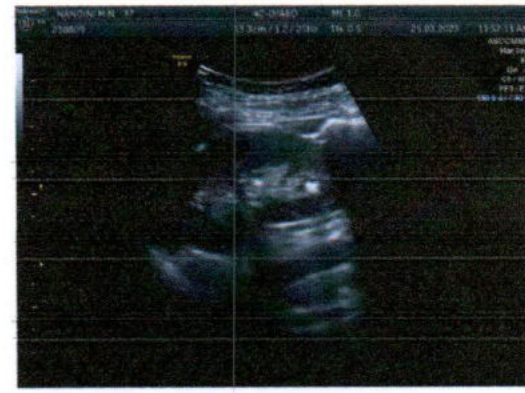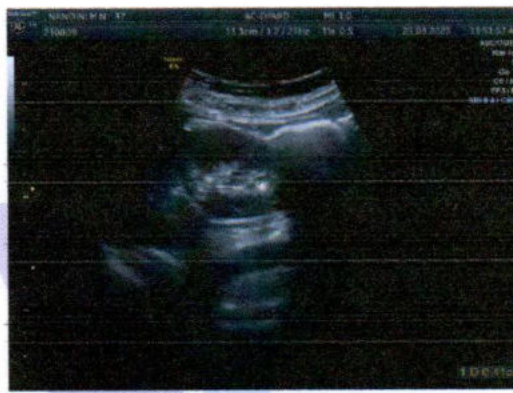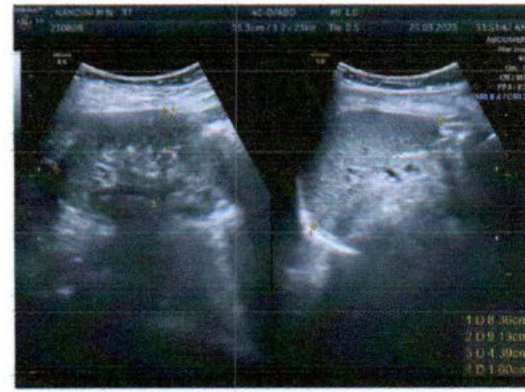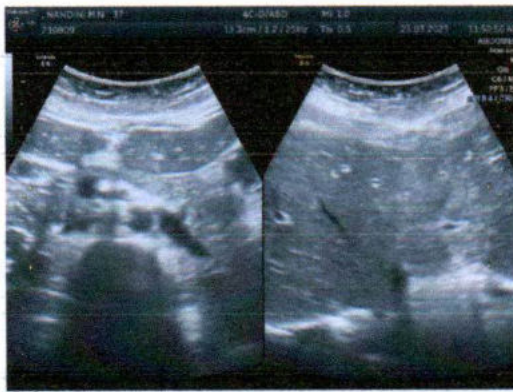
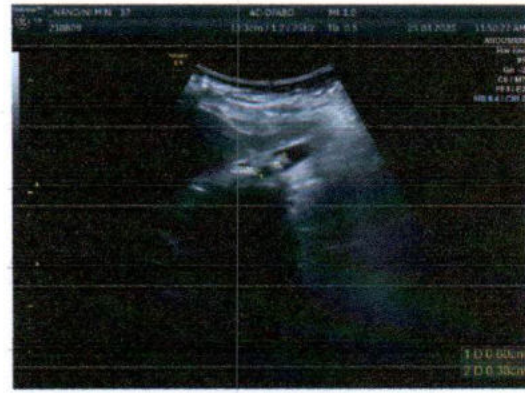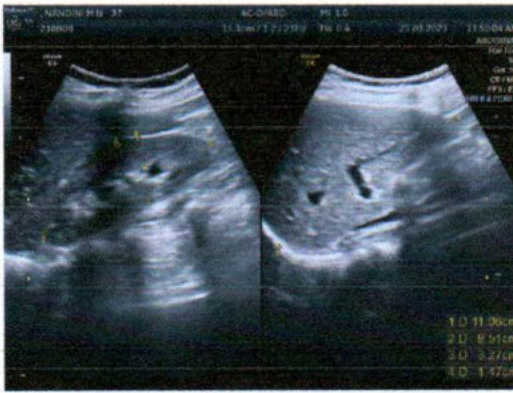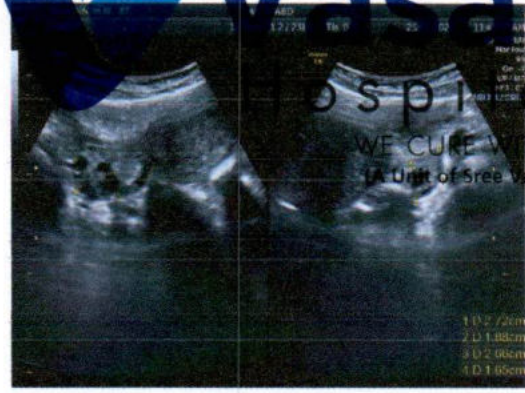
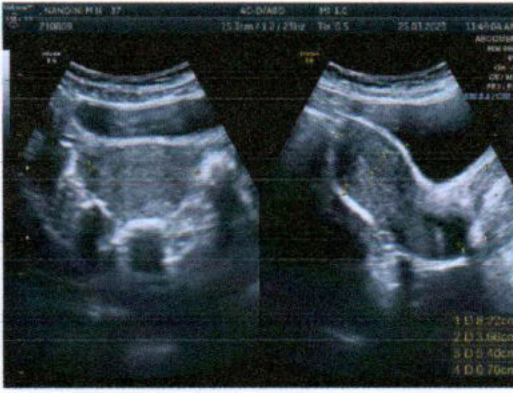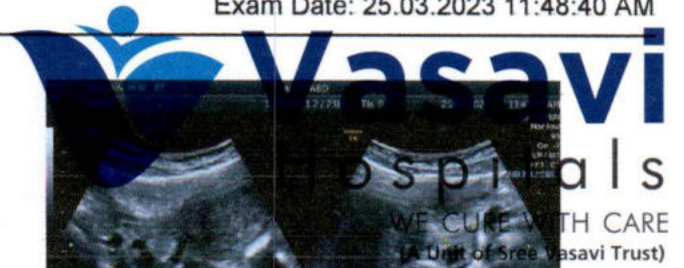
- **NON OBSTRUCTING LEFT RENAL CALCULI.**

**** Note: All abnormalities cannot be detected by Ultrasound scan due to technical limitation, obesity and other factors. Scan findings to be correlated with old reports or other investigations.**



Verified By
Ms Hemalatha K R

Dr. B SWAROOP
MBBS MD(Radiology)
CONSULTANT RADIOLOGIST



OPD Prescription



WE CURE WITH CARE
(A UNIT OF SREE VASAVI TRUST)

Reg. No 210809

Issue Date 25/3/23

Name Nandini

Age/Sex 37y/F

Doctor Dr. Sridhar S

Department

Patient Mob.

Category

BP: 100/60 Height: 162 Weight: 71.7 Pain: Pulse: 96/min Temperature: 37.2 SpO2: 98%

Allergies: [] YES [] NO Details: 1kg BMI: 19.7 COVID 19 Positive: [] YES [] NO

Previous Drug Reactions: [] YES [] NO Details:

History and complaints: Case Reviewed

Past History: of Case of Headache & B/L Numb

Examination: Adv Details: Drug orders:

Investigations: Tab Hepatind 300 1001 x 30 days then 1001 x 2 months

Provisional/Final Diagnosis: Review USG Abdomen after 3 months

Advice: (Lifestyle / Rehab / Diet) -> Surgeon opinion.

Nutritional Screening: [] Poor [] Moderate [] Well

Fall Risk: [] No Risk [] Low [] high

Follow up: Date: Time:

Name & Signature of the Consultant with Stamp: #15, 70th Cross, 14th Main, 1st Stage, Kumaraswamy Layout (Opp.to 15E Bus Stop), Bangalore-560078.

Appointment: 080 71 500 500 | Emergency: 080 71 500 555



Vasavi Hospitals

DEPARTMENT OF RADIOLOGY & IMAGING

Patient Name	Mrs. NANDINI M N	RIS No	58513
UHID	210809	Order Date	25/03/2023 8:33AM
Age/Gender	37 Yrs/Female	Receiving Date	25/03/2023 11:05AM
Bed No/Ward	OPD	Report Date	25/03/2023 11:48AM
Referred By	Dr. SRIDHAR SRINIVASAN G	Report Status	Final
Bill No.	OPCR/23/7552	Manual No.	46867

WE CURE WITH CARE
(A Unit of Sree Vasavi Trust)

X-RAY

CHEST PA VIEW (X RAY) 1

FINDINGS:

The lungs on the either side show equal translucency.
Cardiac size and ventricular configuration are normal.
Both hilar region appear normal.
Both C P angles appear clear.
Both domes of diaphragm appear normal.
Bony cage and soft tissue appear normal.

IMPRESSION: ESSENTIALLY NORMAL STUDY.

--End Of Report--



Verified By
Ms Hemalatha K R

Dr. B SWAROOP
MBBS MD(Radiology)
CONSULTANT RADIOLOGIST

Printed on 25/03/2023 11:47

Page: 1 Of 1

#15, 70th Cross, 14th Main, 1st Stage, Kumaraswamy Layout (Opp. to 15 E Bus Stop), Bengaluru - 560 078

☎ 080 7150 0500 / 88844 66000 ✉ info@vasavihospitals.com 🌐 www.vasavihospitals.com

Gastroenterology • Neurology • Orthopaedics • General Surgery • Obstetrics & Gynecology • Nephrology & Urology • ENT • Emergency & Critical Care

24/7 Radiology Services (Digital X-Ray, Ultrasound, Computed Tomography (CT))