


Government of India
விஜயா பி
Vijaya P
பிறந்த நாள் / DOB : 22/07/1972
பெண்பால் / Female



4208 2396 7897
எனது ஆதார், எனது அடையாளம்

விஜயா



MURUGAN HOSPITALS

HEALING HANDS



LAB REPORT

Patient Name : Mrs. VIJAYA.P
 Age / Gender : 49-Years / Female
 UHID ID : MH20210030178
 Doctor Name : Dr. ARUN PRAKASH

OP Report No. : INVA2101929
 Bill No. : INV2103061
 Sample Date : 14/08/2021 - 03:08 PM
 Report Date : 14/08/2021 - 03:36 PM

Test Name	Result	Units	Reference Interval
HAEMATOLOGY			
Complete Blood Cell Count(CBC)			
HAEMOGLOBIN	<u>11.0</u>	gms/dl	male :13.0 - 17.0 female :12.0 - 15.0
PACKED CELL VOLUME	<u>35.5</u>	%	male : 40 - 50 female : 36 - 46
RBC COUNT	<u>4.82</u>	millions cells/cu.mm	female: 3.8 - 4.8 male : 4.5 - 5.5
TOTAL WBC	5,300	Cells/Cumm	4,000 - 11,000
Differential Count			
NEUTROPHILS	55	%	40 - 65
LYMPHOCYTES	39	%	30-50
EOSINOPHILS	04	%	01-06
MONOCYTES	02	%	1-10
BASOPHILS	00	%	0-2
ESR 60 MTS	15	mm	5 - 20
PLATELET COUNT	3.37	Lakhs/cumm	1.5 - 4.5
MCV	<u>73.8</u>	fL	76 - 96
MCH	<u>22.8</u>	pg	27 - 32
MCHC	30.9	gms/dl	30 - 36

INTERPRETATION: Test done on automated three part cell counter, all abnormal results are reviewed and confirmed microscopically.

BLOOD GROUPING & RH TYPING " B " POSITIVE

Healing Hearts and Lives

264/125, Kilpauk Garden Road, Kilpauk, Chennai - 600 010.

Phone : +91 44 4644 8989 / 75500 53335 | Email : muruganhosp@gmail.com

Website : www.muruganhospitals.in



MURUGAN HOSPITALS

HEALING HANDS



LAB REPORT

Patient Name : Mrs. VIJAYA.P
 Age / Gender : 49-Years / Female
 UHID ID : MH20210030178
 Doctor Name : Dr. ARUN PRAKASH

OP Report No. : INVA2101929
 Bill No. : INV2103061
 Sample Date : 14/08/2021 - 03:08 PM
 Report Date : 14/08/2021 - 03:36 PM

Test Name	Result	Units	Reference Interval
BIO CHEMISTRY			
BLOOD SUGAR FASTING	140	mgs/dl	70-110
SERUM URIC ACID	<u>6.7</u>	mg/dl	male 3.1-7.0 , female 2.5-5.6
LIPID PROFILE			
TOTALCHOLESTEROL	201	mg/dl	< 200
TRIGLYCERIDE	199	mg/dl	< 150
HDL	42	mg/dl	35 - 80
VLDL	39	mg/dl	2 to 30
LDL	120	mg/dl	<130
CHOLESTEROL/ HDL RATIO	4.7	mg/dl	
LIVER FUNCTION TEST			
BILLIRUBIN(TOTAL)	0.4	mg/dl	0.0 -1.0
BILLIRUBIN(DIRECT)	0.1	mg/dl	0.1- 0.30
BILLIRUBIN(INDIRECT)	0.3	mg/dl	0.2-0.8
SGOT	61	IU/L	0-38
SGPT	51	IU/L	0.0-40
ALKALINE PHOSPHATASE	98	IU/L	40-140
TOTAL PROTEIN	7.4	gm/dl	6.6-8.7
ALBUMIN	4.3	gm/dl	3.5 - 5.5
GLOBULIN	3.1	gm/dl	2.0-3.5
A/G RATIO	1.3		

Healing Hearts and Lives

264/125, Kilpauk Garden Road, Kilpauk, Chennai - 600 010.

Phone : +91 44 4644 8989 / 75500 53335 | Email : muruganhosp@gmail.com

Website : www.muruganhospitals.in



MURUGAN HOSPITALS

HEALING HANDS



LAB REPORT

Patient Name : Mrs. VIJAYA.P
 Age / Gender : 49-Years / Female
 UHID ID : MH20210030178
 Doctor Name : Dr. ARUN PRAKASH

OP Report No. : INVA2101929
 Bill No. : INV2103061
 Sample Date : 14/08/2021 - 03:08 PM
 Report Date : 14/08/2021 - 03:36 PM

Test Name	Result	Units	Reference Interval
HBA1C	7.1	%	normal: <6.0 good control: 6.1-7.0 fair control: 7.1- 8.0 poor control:8.1 -10.0 unsatisfactory: >10.0

CLINICAL PATHOLOGY

URINE SUGAR (F) NIL

URINE ROUTINE

COLOUR PALE YELLOW

APPEARANCE CLOUDY

REACTION ACIDIC

SUGAR NIL

ALBUMIN NIL

DEPOSITES

PUS CELLS 1 - 2 / HPF

EPI CELLS 1 - 2 / HPF

RBC COUNT NIL / HPF

CAST NIL

CRYSTALS NIL

OTHERS NIL

SHENBAGAVALLI

Verified by

*** End of Report ***



Healing Hearts and Lives

264/125, Kilpauk Garden Road, Kilpauk, Chennai - 600 010.
 Phone : +91 44 4644 8989 / 75500 53335 | Email : muruganhosp@gmail.com
 Website : www.muruganhospitals.in



MURUGAN HOSPITALS

HEALING HANDS



LAB REPORT

Patient Name : Mrs. VIJAYA.P
 Age / Gender : 49-Years / Female
 UHID ID : MH20210030178
 Doctor Name : Dr. ARUN PRAKASH

OP Report No. : INVA2101939
 Bill No. : INV2103079
 Sample Date : 14/08/2021 - 04:25 PM
 Report Date : 14/08/2021 - 04:30 PM

Test Name	Result	Units	Reference Interval
BIO CHEMISTRY			
SERUM CREATININE	0.8	mg/dl	0.7-1.4
GAMMA G T	18	U/L	male<49 female<32
BUN	12	mg/dl	7-21

SHENBAGAVALLI

Verified by

*** End of Report ***



MH

Healing Hearts and Lives

264/125, Kilpauk Garden Road, Kilpauk, Chennai - 600 010.
 Phone : +91 44 4644 8989 / 75500 53335 | Email : muruganhosp@gmail.com
 Website : www.muruganhospitals.in



MURUGAN HOSPITALS

HEALING HANDS



LAB REPORT

Patient Name : Mrs. VIJAYA.P
 Age / Gender : 49-Years / Female
 UHID ID : MH20210030178
 Doctor Name : Dr. ARUN PRAKASH

OP Report No. : INVA2101929
 Bill No. : INV2103061
 Sample Date : 14/08/2021 - 03:08 PM
 Report Date : 15/08/2021 - 02:52 PM

Test Name	Result	Units	Reference Interval
ENDOCRINOLOGY			
T3	0.756	ng/ml	0.52-1.85
T4	7.036	ug/dl	5.0 -13.0 ug/dl
TSH	3.220	uIU/ml	0.39 - 6.16 uiu/ml

MALATHI
 Verified by

*** End of Report ***



DR. PAVITHRA, MD.
 Pathologist
 Reg. No. 78258

Healing Hearts and Lives

264/125, Kilpauk Garden Road, Kilpauk, Chennai - 600 010.
 Phone : +91 44 4644 8989 / 75500 53335 | Email : muruganhosp@gmail.com
 Website : www.muruganhospitals.in



MURUGAN HOSPITALS

HEALING HANDS

Date : 14/08/2021

NAME OF PATIENT : Mrs.P.VIJAYA

AGE : 47 / Y / FEMALE

Nil visual complaints

O/E

V/A

OD : 6/6 N6

OS : 6/6 N6

Within normal limits in both eyes.

IMPRESSION :

- Nil ophthalmic problem



Medical Officer



MURUGAN HOSPITALS

HEALING HANDS



SCAN REPORT

NAME : MRS. VIJAYA
AGE / SEX : 47Y / FEMALE
CONSULTANT: DR. ARUN PRAKASH

UHID NO : MH20210030178
OP : PATIENT
DATE : 14.08.2021

ULTRASOUND SCAN OF ABDOMEN

LIVER: Enlarged in size and measures- 182mm with mildly increased echotexture. No focal lesions are seen. No dilatation of intra-hepatic biliary radicals present. Hepatic veins and IVC appear normal. Portal vein is normal in caliber. Common bile duct is normal in caliber..

GALL BLADDER: partially distended.

PANCREAS: Normal in size and echotexture. No focal lesions are seen. No evidence of calculi or calcifications. No evidence of pancreatic duct dilation.

PARA AORTIC AREAS: Aorta and IVC appear normal. No evidence of para aortic lymphadenopathy.

SPLEEN: Normal in size and measures- 9.1cm. Normal in echotexture. No evidence of focal lesions.

RIGHT KIDNEY: Measures 9.6 x 4.3cm and is mildly increased echotexture with mild loss of .Cortico medullary differentiation There is no calculus hydronephrosis or mass.

LEFT KIDNEY: Measures 9.6 x 4.8 cm and is mildly increased echotexture with mild loss of . Cortico medullary differentiation . There is no calculus hydronephrosis or mass.

Healing Hearts and Lives

264/125, Kilpauk Garden Road, Kilpauk, Chennai - 600 010. Phone : +91 44 2644 8989 / 26440519
Email : admin@muruganhospitals.in | Website : www.muruganhospitals.in

URINARY BLADDER: Normal in size, contour and wall thickness. There is no evidence of calculus or mass. No vesical diverticulum present.

UTERUS AND OVARIES: Normal in size 5.1x 3.2 cm.

ENTOMOTRIUM: Thin

Both ovaries atropic

No ascites / pleural fluid at present.

IMPRESSION:

- **Hepatomegaly with fatty infiltration**
- **No other significant changes.**



DR. SAKTHI, MDRD.,
Consultant Radiologist.



MURUGAN HOSPITALS

HEALING HANDS



ECHO CARDIOGRAM REPORT

NAME : Mrs.P.VIJAYA

UHID NO : MH20210030178

AGE&SEX : 47Y /FEMALE

OP /PATIENT :OUTPATIENT

CONSULTANT: DR. ARUN PRAKESH

DATE : 14-08-2021

2D PLAX (mm)

RV - 24 mm
AO - 27 mm
LA - 37 mm

COLOR DOPPLER

Normal

M-Mode (mm)

IVS - 11 mm
PW - 09 mm
LVD - 41 mm
LVS - 27 mm
EF - 64 %
FS - 35 %

DOPPLER (m/sec)

MITRAL E - 0.6m/s
MITRAL A - 0.7 m/s
PULMONARY - 1.1 m/s
AORTIC - 1.4 m/s
TRICUSPID - 0.4m/s

IMPRESSION:

No RWMA
Normal LV Systolic function
Grade I left ventricular diastolic dysfunction
Normal RV function
No pulmonary hypertension
No pericardial effusion
No clot/ Vegetation.

DR. SIDHARTHAN, MD.,DM.,

Consultant Cardiologist

Reg. No: 62979

Dr. SIDHARTHAN, MD.,DM.,

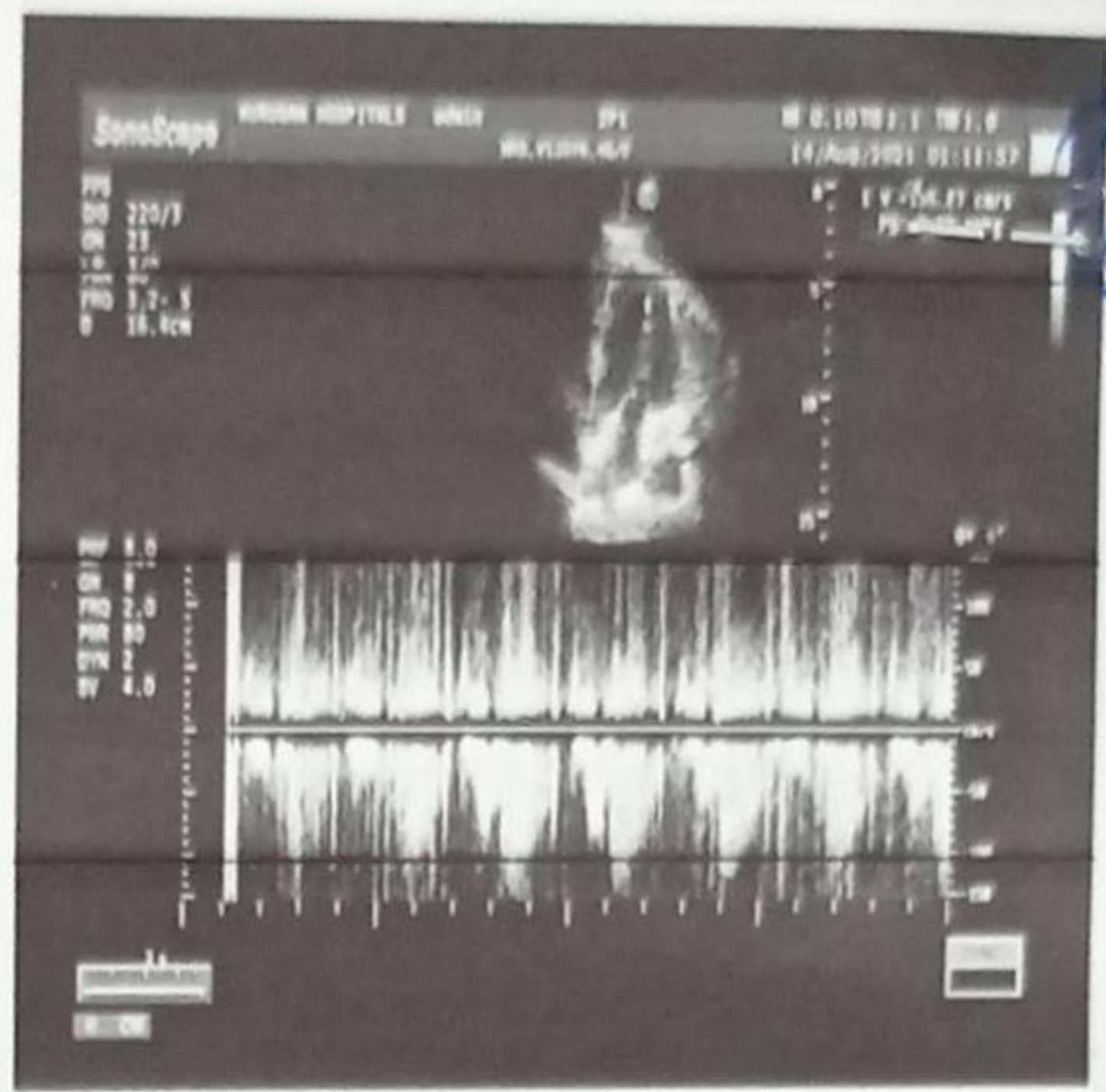
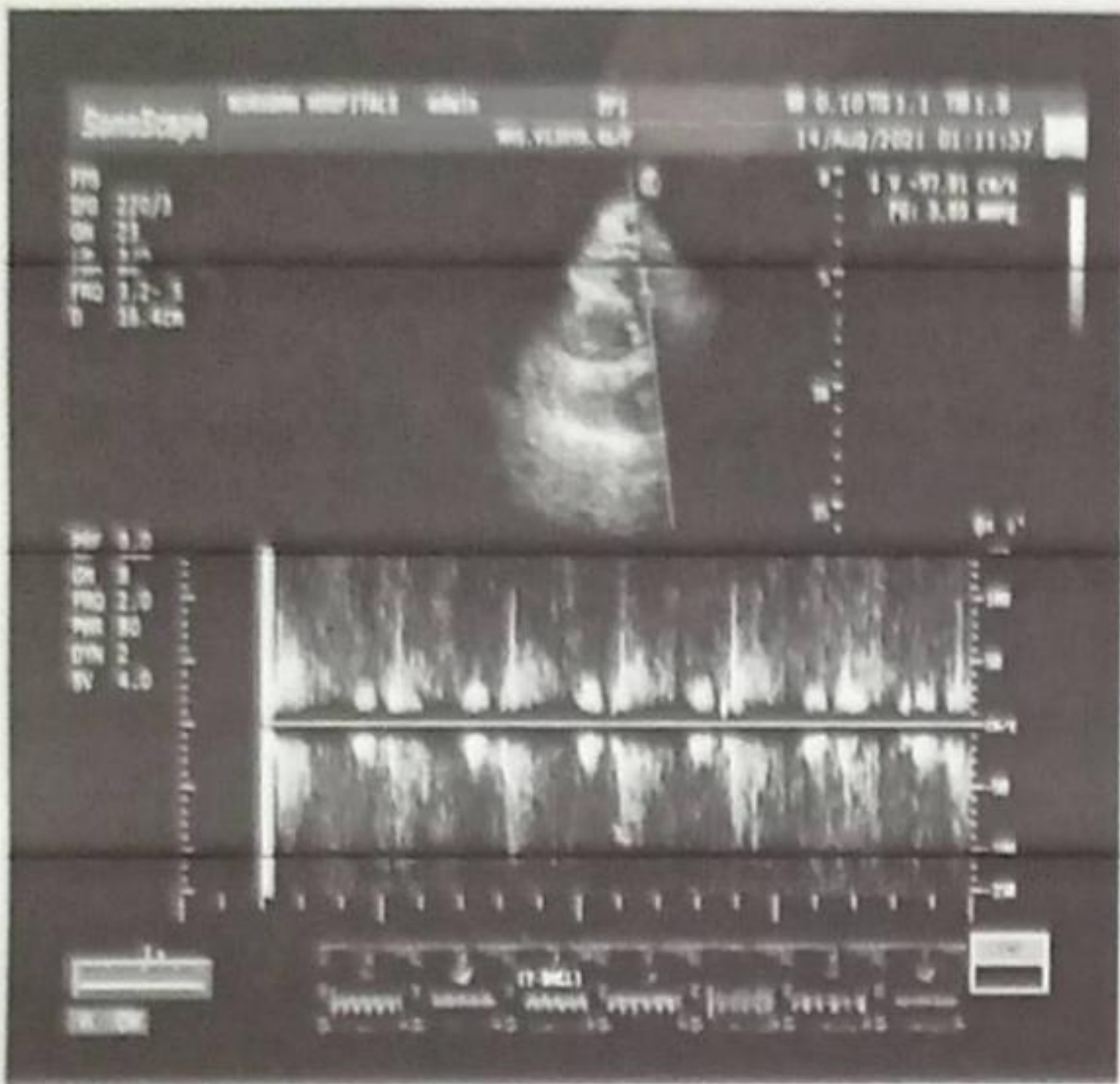
Consultant Cardiologist

Healing Hearts and Lives

264/125, Kilpauk Garden Road, Kilpauk, Chennai - 600 010.

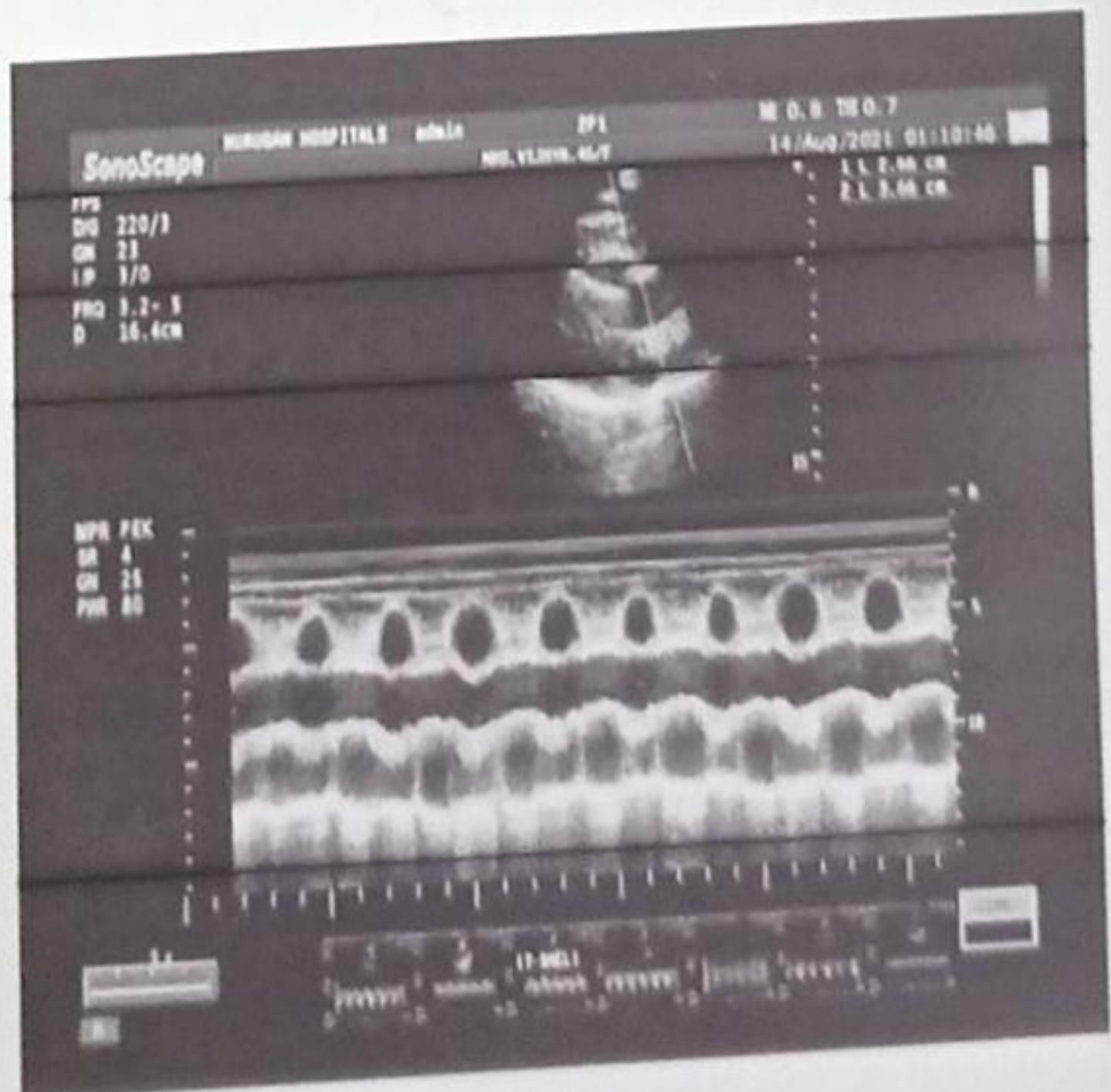
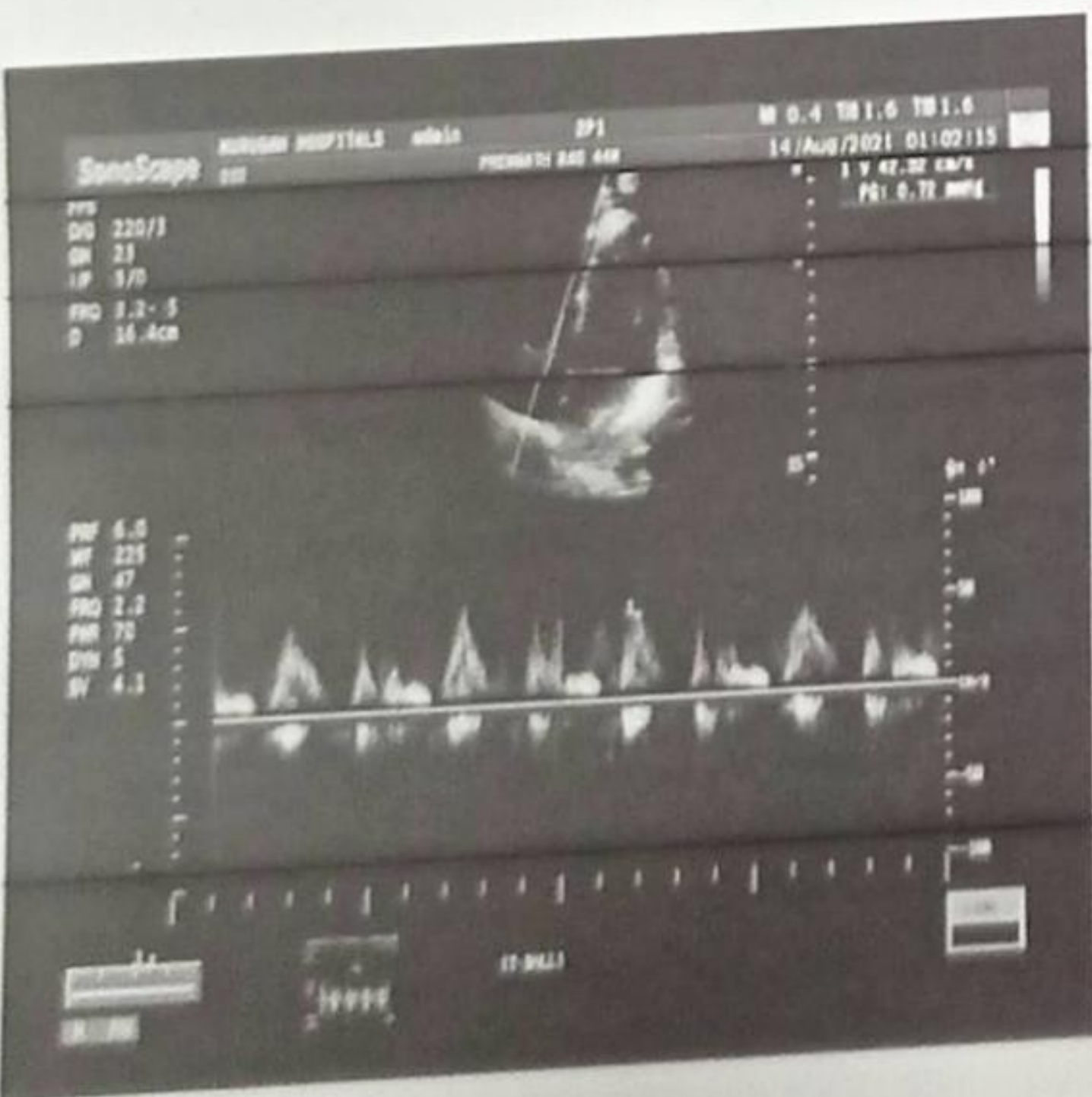
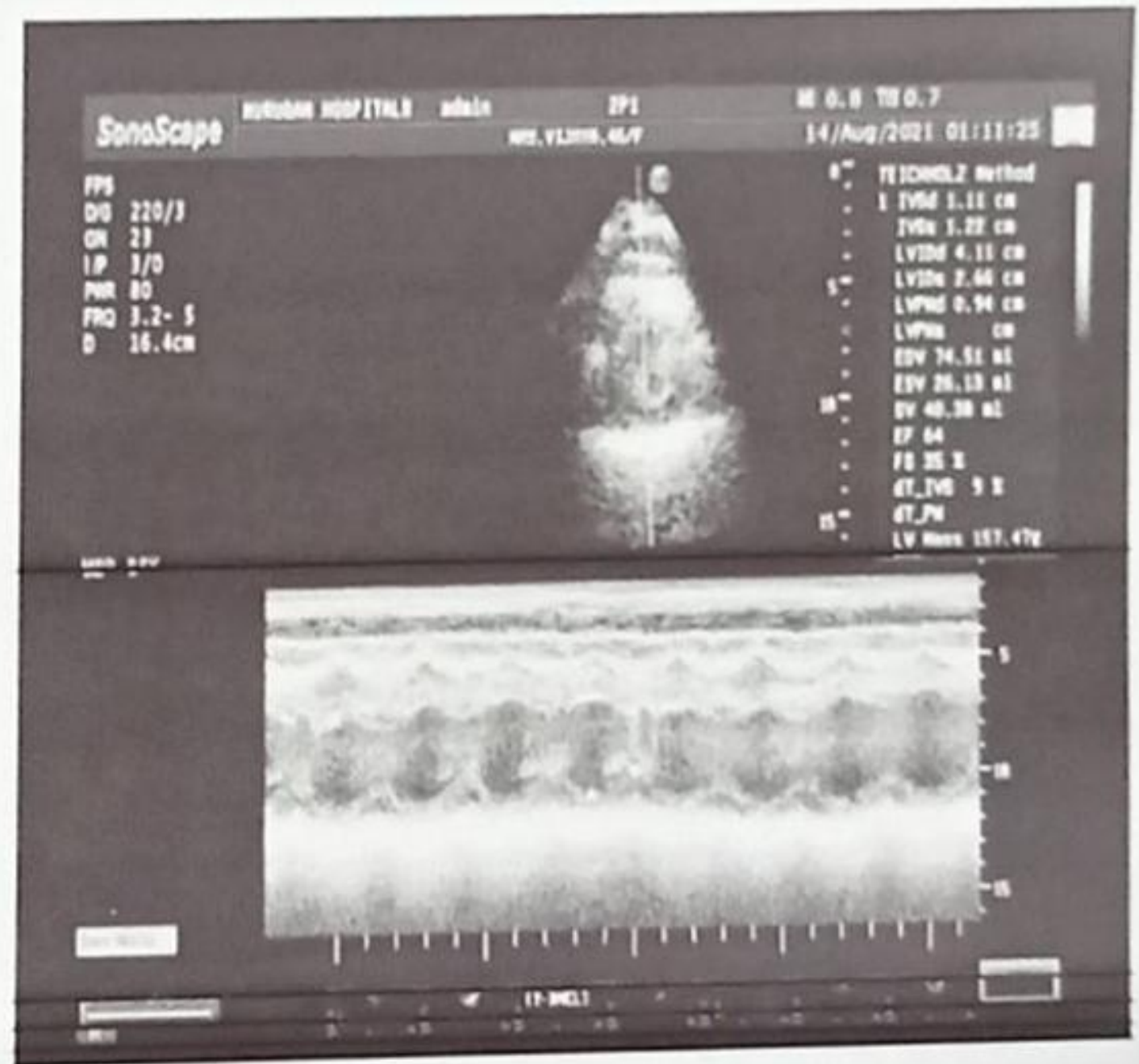
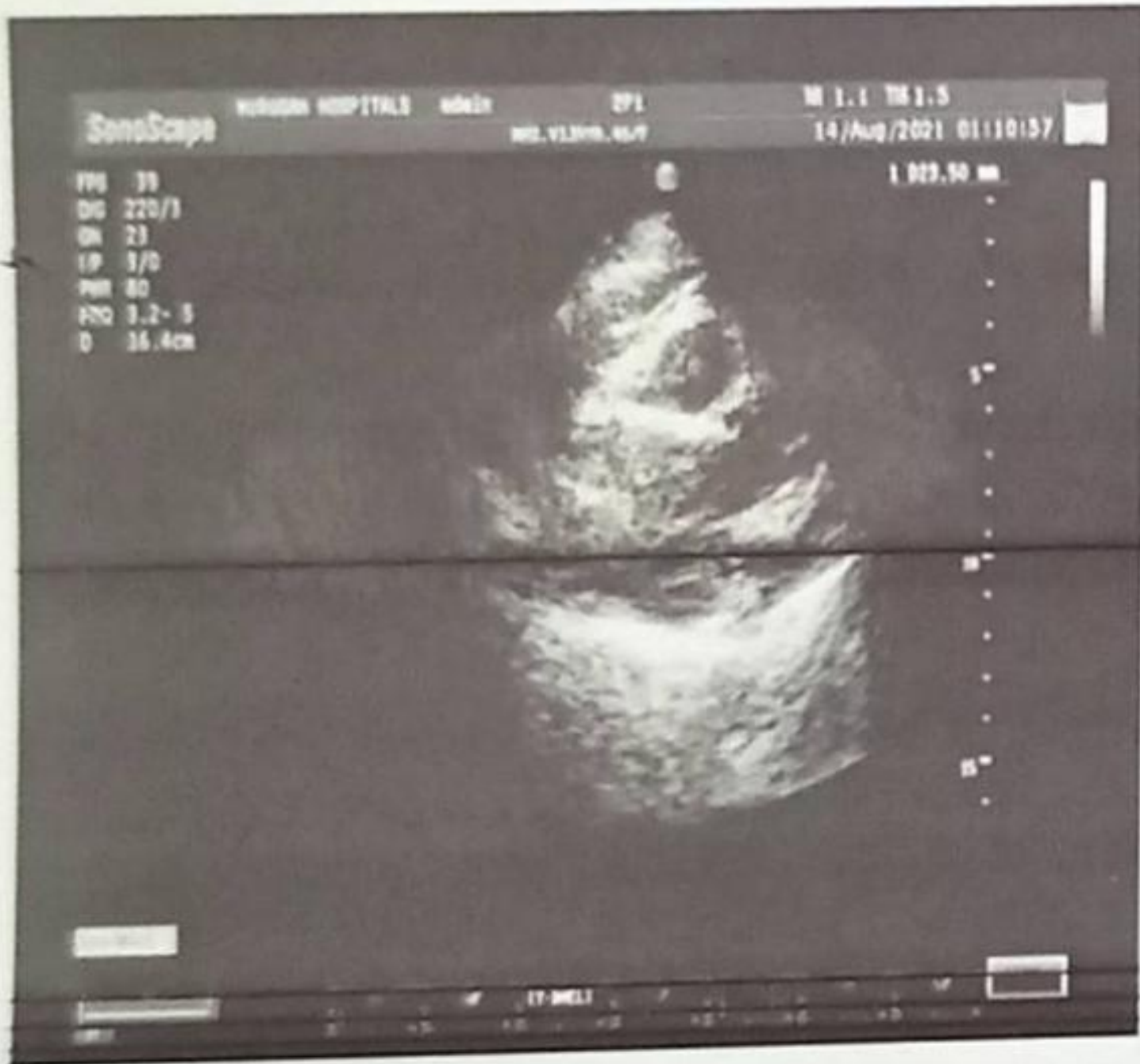Phone : +91 44 2644 8989 / 4644 8989 | Mob. : 7550053335 | Email : muruganhosp@gmail.com

Website : www.muruganhospitals.in



Mrs. Vijaya

47/P





MURUGAN HOSPITALS

HEALING HANDS

14/08/2021.

Mrs. VIJAYA

46/F

Nil Dental / ENT
Complaints



264/125, Kilpauk Garden Road, Kilpauk, Chennai - 600 010.

☎ : +91 44 4644 8989 / 75500 53335 email : muruganhosp@gmail.com

Website : www.muruganhospitals.in

ID : 2108140000
Name : MRS VIJAYA
Sex : Female
Divisions :

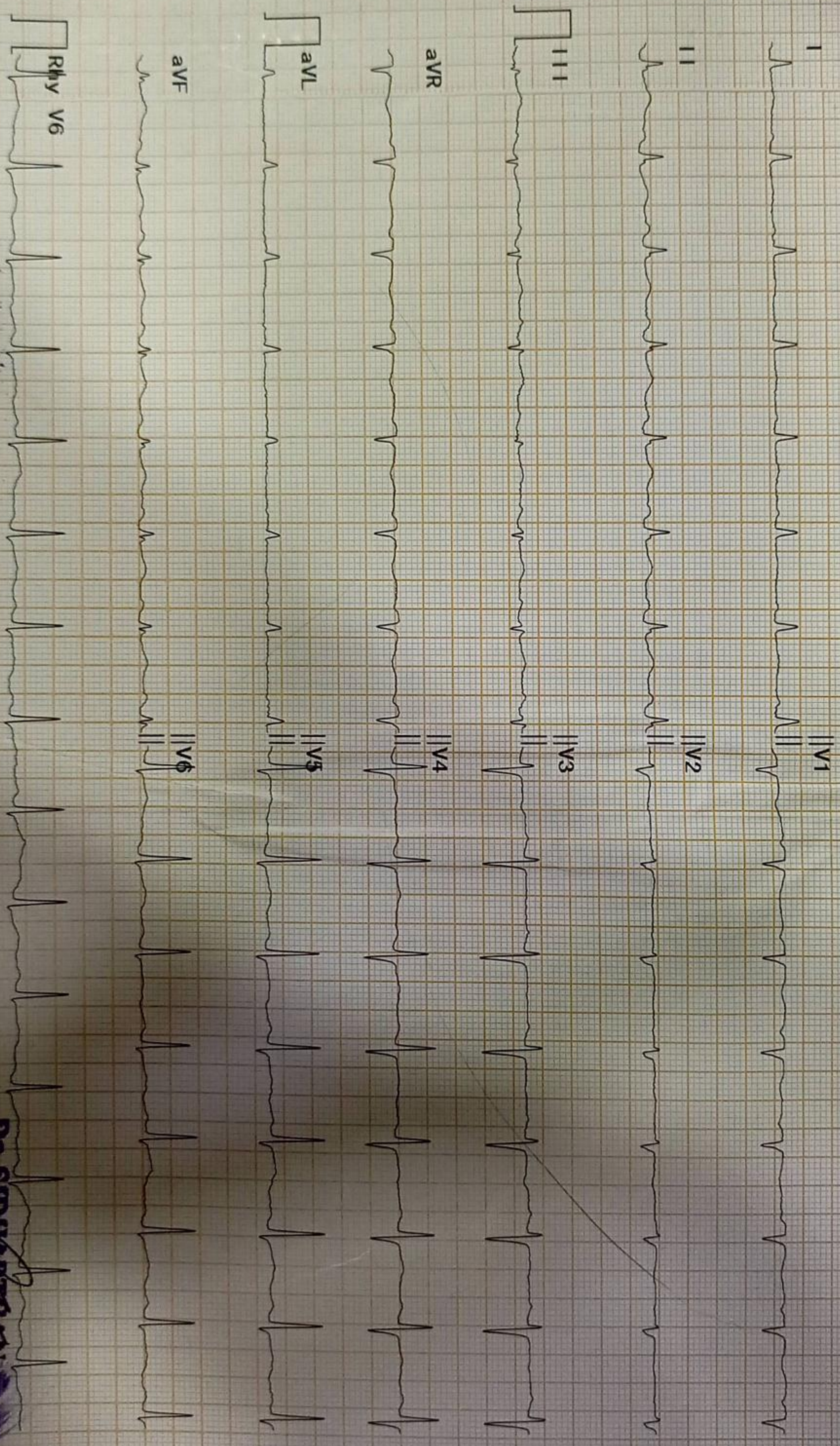
Date Time : 2021-08-14 09:24
Age : 47 yrs
BP : 130/80 mmHg
Bed No. :

Hospital : MURUGAN HOSPITALS
Height : 146 cm
Weight : 70 kg
Hospital No. :

HR : 92 bpm
P Dur/PR int : 99/147ms
QRS Dur : 103ms
QT/QTc int : 362/449 ms
P/QRS/T axis : 67/35/69°

RV5/SV1 amp : 0.996/0.412mV
RV5+SV1 amp : 1.408mV
RV6/SV2 amp : 0.948/0.222mV
Minnesota Code : 1-1-2 (V1)
9-1-1 (I, II, III)

Diagnosis Info
800 : Sinus Rhythm
131 : Low Voltage (Limb Leads)



Diagnosis for reference, ask your doctor to confirm
AUTO PRINT 6X2+1R 92bpm 10 mm/mV 0.50Hz-25Hz AC 50Hz 25 mm/sec

Confirmed By : **DR. SIDHARTHAN, MD, DM**
Consultant Cardiologist
Reg. No. 67579

67579



MURUGAN HOSPITALS

HEALING HANDS



SCAN REPORT

NAME: Mrs.P.VIJAYA
AGE / SEX : 46Y/FEMALE
CONSULTAN: DR. ARUN PRAKASH

UHID : MH20210030178
OP : OUTPATIANT
DATE : 14.08.2021

CHEST XRAY PA VIEW

- Increased bronchovascular markings
- Cardio – costophrenic angle normal

IMPRESSION :

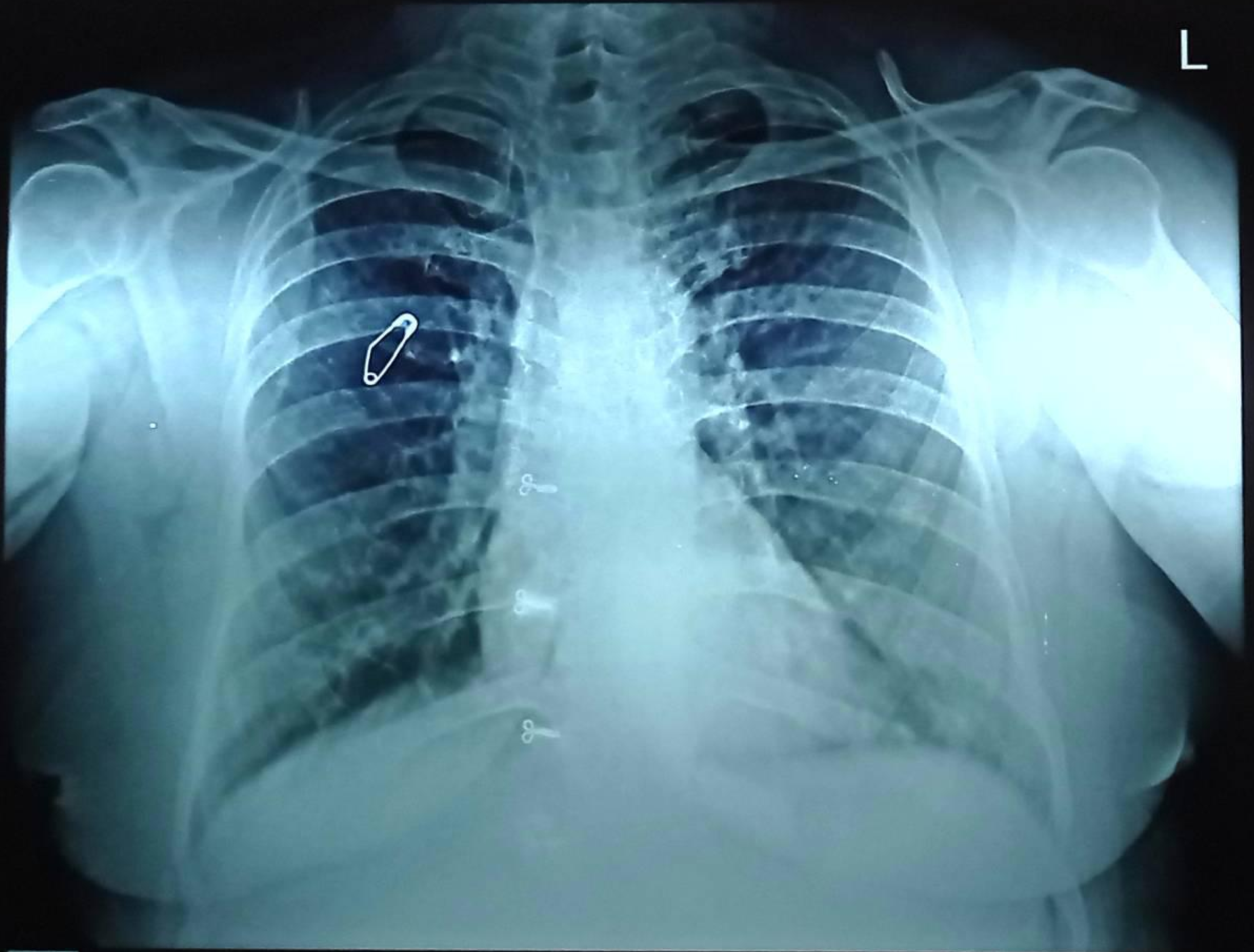
- Increased bronchovascular markings



CONSULTANT RADIOLOGIST

Healing Hearts and Lives

264/125, Kilpauk Garden Road, Kilpauk, Chennai - 600 010. Phone : +91 44 2644 8989 / 26440519
Email : admin@muruganhospitals.in | Website : www.muruganhospitals.in



MRS.VIJAYA 46YRS 30178 CHEST-PA 14-08-2021
MURUGAN HOSPITALS, KILPAUK,CHENNAI-10 PH NO:+91 44 2644 8989 / 2644 0519