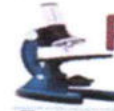

**Facilities:**

All clinical Biomedical & Hematology Investigations including Bone Marrow Examination  
VPT, Podiascan & Complete Foot Care (First Time in Purvanchal)  
All Hormonal Investigation by Chemiluminescent Method  
Visceral Fat by (AB-140) Ambulatory BP Monitoring  
CGMS & Insulin Pump Available  
PFT, 2D-ECHO (Color Doppler), Holter, TMT, Cardiac-3 available  
VIA, VILI, Colposcopy available  
Special Endocrinological Investigation Protocols.

ISO 9001:2008 Certified  
Mobile: 9389994334, 9554572190, 9453837595



# Panacea Pathology

## Clinical Reference Lab

Persistence, Preparedness and Precision  
EQAS (CMC Vellore Attached) & IQAS System  
पूर्वाचल की सर्वोत्तम गुणवत्ता वाली पैथोलॉजी

PATIENT NAME : PRATIMA

AGE/GENDER : 31 YRS/FEMALE

REFD BY DR. : ARCO FEMI HEALTHCARE LTD.

RECEIVED DATE : 28-01-2023(10:00AM)

SAMPLE : BLOOD & URINE

REPORT DATE : 28-01-2023(06:00PM)

## PATHOLOGY REPORT

### COMPLETE BLOOD COUNT (CBC)

TEST	LAB TEST VALUES	NORMAL RANGE
<b>HEMOGRAM</b>		
HEMOGLOBIN (FLOW CYTOMETRY)	12.3	13 – 16 gm/dl
TOTAL LEUCOCYTE COUNT (TLC)	4,600	4000 – 11000
RBC COUNT	4.38	3.5 – 5.5
PCV (HCT)	38.6	37 – 47
MCV	88.2	80 – 95
MCH	28.1	28 – 34
MCHC	31.8	30 – 36
PLATELET COUNT	1,53,000	1,50,000 – 4,00,000
E.S.R. (WINTROBE FIRST HOURS)	20.0	20 mm/1 <sup>st</sup> hr
<b>DIFFERENTIAL LEUCOCYTE</b>		
NEUTROPHILS	57	40 – 75%
LYMPHOCYTES	34	20 – 45%
EOSINOPHILS	04	1 – 6%
MONOCYTES	05	2 – 8%
BASOPHILS	00	< 2%

### RENAL & KIDNEY PROFILE, SERUM

TEST	LAB TEST VALUES	NORMAL RANGE
<b>RENAL FUNCTION TESTS</b>		
BLOOD UREA NITROGEN (BUN)	11.6	10 – 50 mg/dl
SERUM CREATININE	0.74	0.60 – 1.60 mg/dl
URIC ACID	4.10	3.60 – 7.70 mg/dl
ALKALINE PHOSPHATASE (ALP)	79.0	142 – 353 mg/dl
TOTAL PROTIENS	7.20	0 – 39 mg/dl
ALBUMIN	4.0	3.8 – 5.4 mg/dl
SERUM GLOBULIN	3.20	2.1 – 3.5 mg/dl
CALCIUM	9.0	8.80 – 10.20
PHOSPHORUS	3.04	2.50 – 5.00
SERUM SODIUM NA+	1.005	135.00 – 155.00 mEq/Ltr
SERUM POTASIUM K+	4.12	3.60 – 5.50 mEq/Ltr
ICALCIUM	1.22	1.10 – 1.35 mmol/L
SERUM CHLORIDE CL+	101.3	98.00 – 110.00 mEq/Ltr

PAGE 1

Lab Technician

PANACEA HOSPITAL

(A UNIT OF ARCO FEMI HEALTH CARE PVT. LT)

M.D., Pathology

B.36/44, B-4, KABIR NAGAR

DURGAKUND, VARANASI

Timing : 8.00 a.m. to 9.00 p.m. (Sunday 8.00 a.m. to 3.00 p.m.)

This Report is not valid for medico legal purpose

**Note:** These tests have technical limitations. Clinico-pathological interpretation is necessary. In case of any disparity test may be repeated immediately.

Address : 36/44 FK Kabir Nagar, Durgakund, Varanasi – 221005

Email: [dramishra@gmail.com](mailto:dramishra@gmail.com), [drpallaviojha@gmail.com](mailto:drpallaviojha@gmail.com) Website: [panaceahospital.org](http://panaceahospital.org)



**Facilities:**

All clinical Biomedical & Hematology Investigations including Bone Marrow Examination  
VPT, Podiascan & Complete Foot Care (First Time in Purvanchal)  
All Hormonal Investigation by Chemiluminescent Method  
Visceral Fat by (AB-140) Ambulatory BP Monitoring  
CGMS & Insulin Pump Available  
PFT, 2D-ECHO (Color Doppler), Holter, TMT, Cardiac-3 available  
VIA, VILI, Colposcopy available  
Special Endocrinological Investigation Protocols.

ISO 9001:2008 Certified  
Mobile: 9389994334, 9554572190, 9453837595



# Panacea Pathology

## Clinical Reference Lab

Persistence, Preparedness and Precision  
EQAS (CMC Vellore Attached) & IQAS System  
पूर्वाचल की सर्वोत्तम गुणवत्ता वाली पैथोलॉजी

PATIENT NAME : PRATIMA

AGE/GENDER : 31 YRS/FEMALE

REFD BY DR. : ARCO FEMI HEALTHCARE LTD.

RECEIVED DATE : 28-01-2023(10:00AM)

SAMPLE : BLOOD & URINE

REPORT DATE : 28-01-2023(06:00PM)

### PATHOLOGY REPORT

#### LIPID PROFILE, SERUM

TEST	LAB TEST VALUES	NORMAL RANGE
<b>BLOOD CHEMISTRY</b>		
TOTAL CHOLESTEROL (SERUM)	180.0	Desirable:- < 200 mg/dl Borderline:- 200 – 239 mg/dl High:- > 240 mg/dl
TRIGLYCERIDES (SERUM)	178.0	35 – 170 mg/dl
HDL CHOLESTEROL (SERUM)	46.0	35.30 – 79.50 mg/dl
LDL CHOLESTEROL (SERUM)	98.4	< 130 mg/dl
VLDL	35.6	< 40 mg/dl
CHOLESTROL/HDL RATIO	3.9	< 3.0 Low Risk Ratio 3.0 – 5.0 Avg Risk > 5.0 High Risk
LDL/HDL RATIO	0.46	< 3 Ratio

#### BLOOD GROUP

TEST	LAB TEST VALUES
<b>BLOOD GROUP ABO &amp; RH FACTOR</b>	
BLOOD GROUP	"A"
RH FACTOR	POSITIVE

#### GLYCOSYLATED HEMOGLOBIN (HBA1C)

TEST	LAB TEST VALUES	NORMAL RANGE
HBA1C	5.4	Normal : < 5.97 % Good Control : 5.97 – 6.81% Fair Control : 6.81 – 7.65% Poor Control : > 7.65%

#### THYROID PROFILE (T3, T4, TSH)

TEST	LAB TEST VALUES	NORMAL RANGE
<b>THYROID FUNCTION TEST</b>		
T3	1.16	0.60 – 1.81 ng/ml
T4	7.56	4.50 – 10.90 ug/dl
TSH	2.72	0.39 – 6.10 uIU/mL

PAGE 2

Lab Technician

Timing : 8.00 a.m. to 9.00 p.m. (Sunday 8.00 a.m. to 3.00 p.m.)

This Report is not valid for medico legal purpose

**Note:** These tests have technical limitations. Clinico-pathological interpretation is necessary. In case of any disparity test may be repeated immediately.

Address : 36/44 FK Kabir Nagar, Durgakund, Varanasi – 221005

Email: [dramishra@gmail.com](mailto:dramishra@gmail.com), [drpallaviojha@gmail.com](mailto:drpallaviojha@gmail.com) Website: [panaceahospital.org](http://panaceahospital.org)

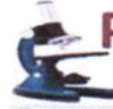**PANACEA HOSPITAL**  
(A UNIT OF ARCO FEMI HEALTH CARE PVT. LTD.)  
REG. NO. AL-1500  
M.D. Pathology  
B.36/44, B-4, KABIR NAGAR  
DURGAKUND, VARANASI



**Facilities:**

All clinical Biomedical & Hematology Investigations including Bone Marrow Examination  
 VPT, Podiascan & Complete Foot Care (First Time in Purvanchal)  
 All Hormonal Investigation by Chemiluminescent Method  
 Visceral Fat by (AB-140) Ambulatory BP Monitoring  
 CGMS & Insulin Pump Available  
 PFT, 2D-ECHO (Color Doppler), Holter, TMT, Cardiac-3 available  
 VIA, VILI, Colposcopy available  
 Special Endocrinological Investigation Protocols.

ISO 9001:2008 Certified  
 Mobile: 9389994334, 9554572190, 9453837595



# Panacea Pathology

## Clinical Reference Lab

Persistence, Preparedness and Precision  
 EQAS (CMC Vellore Attached) & IQAS System  
 पूर्वीचल की सर्वोत्तम गुणवत्ता वाली पैथोलॉजी

PATIENT NAME : PRATIMA

AGE/GENDER : 31 YRS/FEMALE

REFD BY DR. : ARCO FEMI HEALTHCARE LTD.

RECEIVED DATE : 28-01-2023(10:00AM)

SAMPLE : BLOOD & URINE

REPORT DATE : 28-01-2023(06:00PM)

### PATHOLOGY REPORT

#### LIVER PROFILE TEST, SERUM

TEST	LAB TEST VALUES	NORMAL RANGE
<b>BIO CHEMISTRY</b>		
TOTAL BILIRUBIN	0.72	0.0 – 1.1 mg/dl
DIRECT BILIRUBIN	0.28	0.0 – 0.2 mg/dl
INDIRECT BILIRUBIN	0.44	< 0.90 mg/dl
SGOT (AST)	22.6	0 – 52 mg/dl
SGPT (ALT)	25.0	0 – 39 mg/dl
GGT (GYT)	31.0	< 55 U/L

#### URINE ROUTINE EXAMINATION

TEST	LAB TEST VALUES	NORMAL RANGE
<b>PHYSICAL EXAMINATION</b>		
QUANTITY	29	ML
COLOUR	STRAW	PALE YELLOW
APPEARANCE	CLEAR	CLEAR
SPECIFIC GRAVITY	1.005	1.01 – 1.03
PH	6.5	4.7 – 7.5
<b>CHEMICAL EXAMINATION</b>		
GLUCOSE	Not Detected	Not Detected
PROTEIN	NIL	Not Detected
<b>MICROSCOPIC EXAMINATION</b>		
PUS CELLS	1-2	0-5
RBC	Not Detected	Not Detected
EPITHELIAL CELLS	2-3	0-5
CASTS	Not Detected	Not Detected
CRYSTALS	Not Detected	Not Detected
BACTERIA	Not Detected	Not Detected

#### RANDOM/FASTING BLOOD SUGAR

TEST	LAB TEST VALUES	NORMAL RANGE
<b>RBS/FBS</b>		
RANDOM BLOOD SUGAR	130.0	125-140 mg/dl
FASTING BLOOD SUGER	90.0	70-125 mg/dl

----- End of Report -----

Lab Technician

**PANACEA HOSPITAL**  
 UNIT OF ARCO FEMI HEALTH CARE PVT. LTD.  
 M.D. Pathology  
 B.36/44, B-4, KABIR NAGAR  
 DURGAKUND, VARANASI

Timing : 8.00 a.m. to 9.00 p.m. (Sunday 8.00 a.m. to 3.00 p.m.)

This Report is not valid for medico legal purpose

**Note:** These tests have technical limitations. Clinico-pathological interpretation is necessary. In case of any disparity test may be repeated immediately.

Address : 36/44 FK Kabir Nagar, Durgakund, Varanasi – 221005

Email: [dramishra@gmail.com](mailto:dramishra@gmail.com), [drpallaviojha@gmail.com](mailto:drpallaviojha@gmail.com) Website: [panaceahospital.org](http://panaceahospital.org)



# PANACEA HOSPITAL

B 36/44 F.K KABIR NAGAR, DURGAKUND  
TOLLFREE NO-18001233070.  
Whatsapp No - 8795832852  
www.piire.org



## OP Slip

Print Date : 28-Jan-2023 05:43PM



<b>UHID No</b> :- UD-22230003445	<b>OP No</b> :- OP-22230012794	<b>OP Date</b> :- 28 Jan 2023 5:42PM
<b>Patient Name</b> :- Mrs PRATIMA BOB	<b>Age/Sex</b> :- 31 Y/Female	<b>Mobile No</b> :- 9336699823
<b>Husband</b> :- JITENDRA CHAUHAN	<b>Department</b> :- OBST. & GYNAECOLOGY	
<b>Pay Type</b> :- Cash	<b>Consultant</b> :- Dr Tusharika Rai (MBBS,MS)	
<b>Token No</b> :- NOR. - 8	<b>Paid/Bal</b> :- 0.00 / 500.00	
<b>Patient Type</b> :- Normal		
<b>Address</b> :- PATRAW, Jaunpur		

BP 100/70 :-  
height :-  
Weight (kg) :- 73kg  
BMI :-  
SPO<sub>2</sub> - 96%  
LMP PR - 87b/m  
1/01/23

Rx

P<sub>2</sub>to (2A+H) c/o Irregular  
prev. 2LSCS. Pde X3-4  
month  
LD - 5yrs / 07 / 2LSCS / A+H.  
LMP - 1/01/2023.  
MH  $\frac{3-4d}{27-35day}$  [ F-Avg  
P ⊖ occ.  
C-occ

USG - Fatty liver

Adv - wt. loss  
- Diet

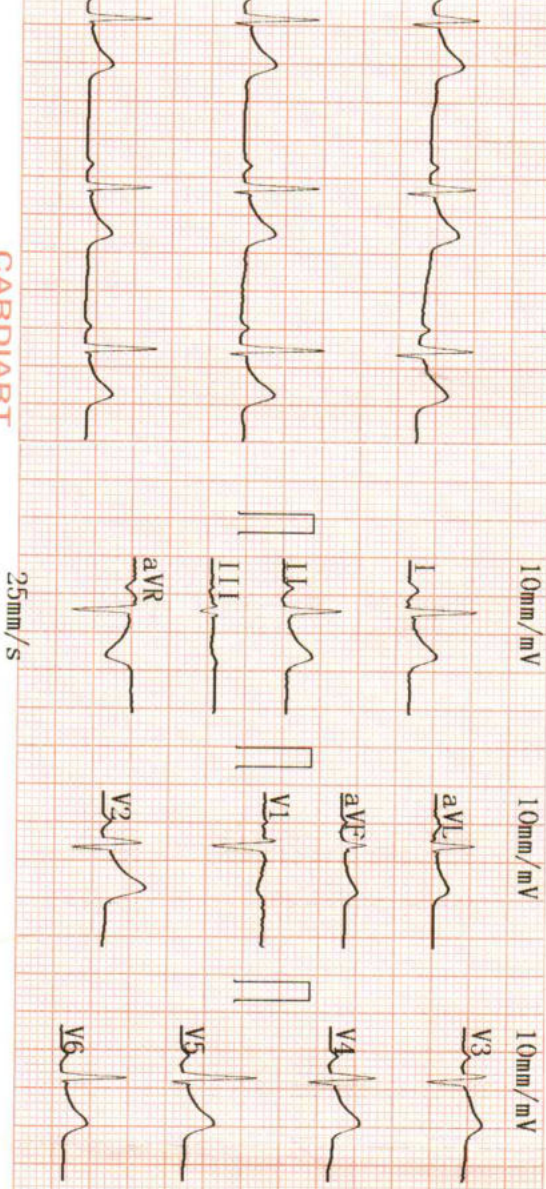
- Liquid Based  
cytology.

Printed By : Mr NITIN YADAV  
Created By : Mr NITIN YADAV

Syp Menohelp  
2ts F  
x 1 month.



CARDIART



10mm/mV

25mm/s

10mm/mV

10mm/mV

2023-01-28 12:58

BPL-02

ID :  
 Name : Poornima  
 Sex : F  
 Height :  
 SYS :  
 DIA :  
 HR : 68 bpm  
 PR Interval : 133 ms  
 P Duration : 91 ms  
 QRS Duration : 66 ms  
 T Duration : 226 ms  
 QT/QTc : 352/374 ms  
 P/QRS/T Axis : 13.3/25.6/32.6 deg  
 R(V5)/S(V1) : 0.99/0.68 mV  
 R(V5)+S(V1) : 1.66 mV

Age : 31Y  
 Weight : 31Y kg  
 \*\*Report need physician confirm\*\*

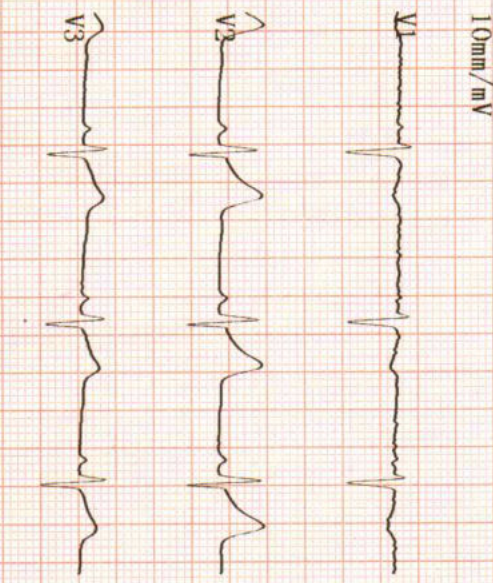
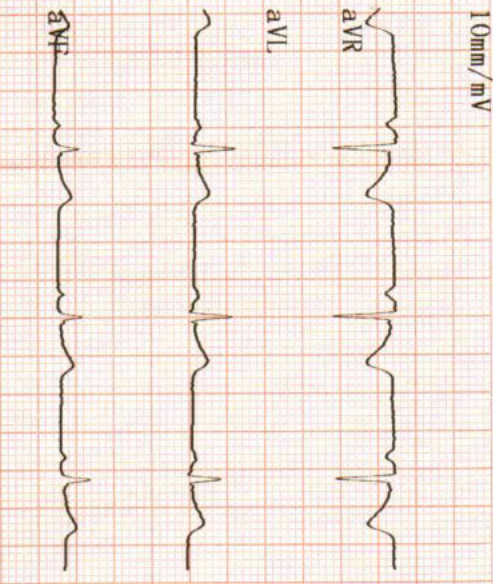
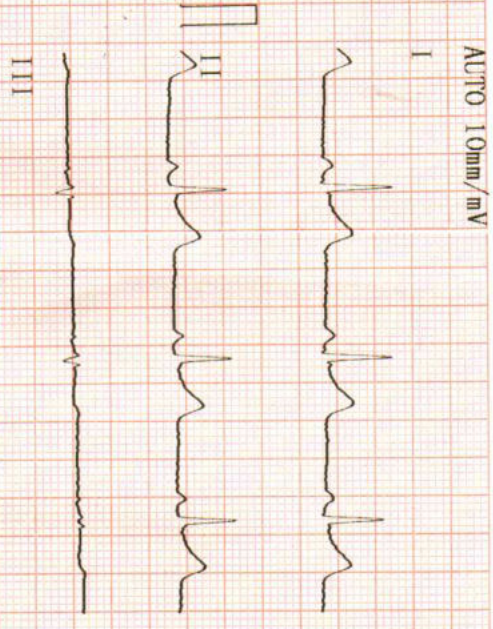
<< Conclusions >>

Normal Sinus Rhythm;  
 Longitudinal left axis deviation;

Physician

**DR. PALAVI MISHRA**  
 MIBBS, MD (GENERAL MEDICINE)  
 MCI Reg. No. 52033

AUTO 10mm/mV  
25mm/s AC50HZ+EMG35Hz  
CARDIART



AUTO 10mm/mV

10mm/mV

BPL-02  
10mm/mV

10mm/mV





# PANACEA HOSPITAL

*A shelter for many hearts A Home for many lives*

(An ISO 9001:2008 Certified Organisation)  
Lab Attached with CMC Vellore Under EQAS Scheme

Name	MRS.PRATIMA	Sex /Age	31/F	Date	28/01/2023
Ref. by	Dr.Pallavi Mishra(MD)	BSA - m <sup>2</sup>		Echo window	fair

## Echo - Cardiography

MITRAL VALVE Doppler	AML - normal morphology MV Flow - E - 0.8 A-0.5 E/A=1.58	PML - normal morphology MVA - 3.0 cm <sup>2</sup> Mitral Regurgitation - <b>No</b>
TRICUSPID VALVE Doppler	Normal TV Flow -No	Tricuspid Regurgitation - <b>No</b>
PULMONARY VALVE Doppler	Normal PV Flow -No	Pulmonary Regurgitation - No
AORTIC VALVE Doppler	Trileaflet-No AV Flow - no	Aortic Regurgitation - no
MEASUREMENT	Aorta - 24.0 (20-38) mm IVS ed - 9.7 (6 -12) mm LVID ed - 35.6 (35 - 55) mm LVPW ed - 10.9 (6 -12) mm OA - 7 (> 5) mm	LA - 26.8 (24-32) mm IVS es -12.6 (6 - 12) mm LVID es - 25.7 (24 - 40) mm LVPW es - 10.9 (6 -12) mm EPSS - 6 (< 9) mm

**CONCLUSION**

All cardiac chamber dimensions are WNL  
No valvular abnormalities  
Good LV systolic function present Modified Simpson's method (4C, 2C) (LVEF-54%)  
No diastolic dysfunction present (E/A = 1.58) by tissue Doppler (E/e'=6.2)  
No RWMA  
No pericardial effusion  
Intact IAS / IV  
No PAH  
No intra cardiac mass /thrombus /vegetation

## IMPRESSION

**Normal Echocardiogram**

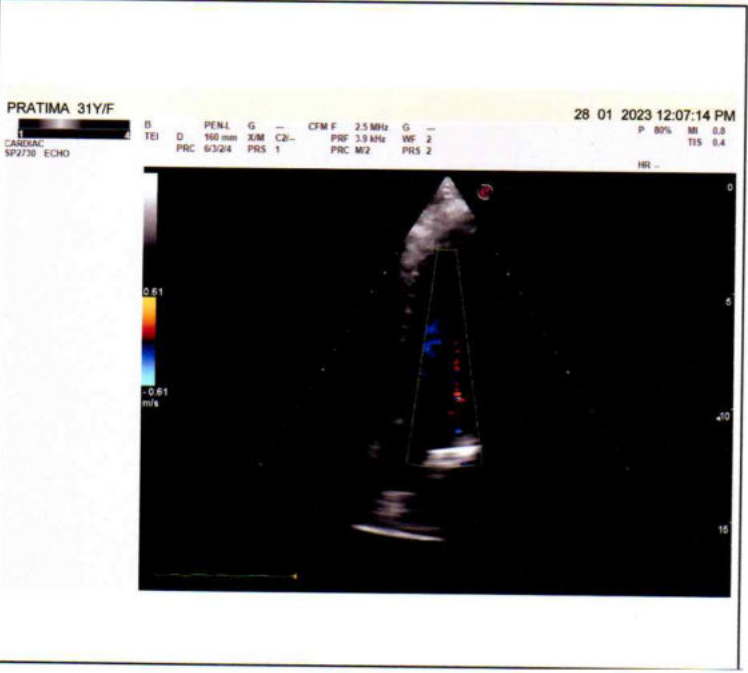
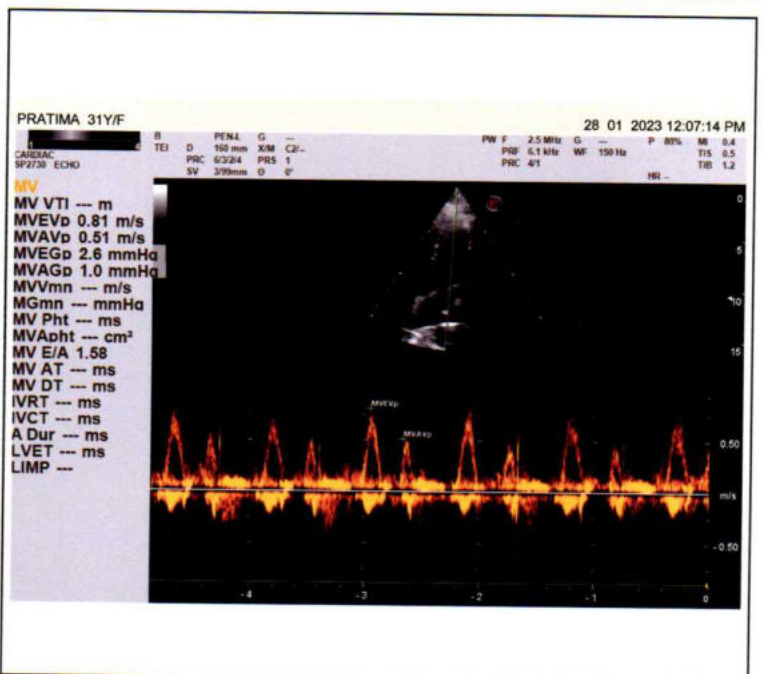
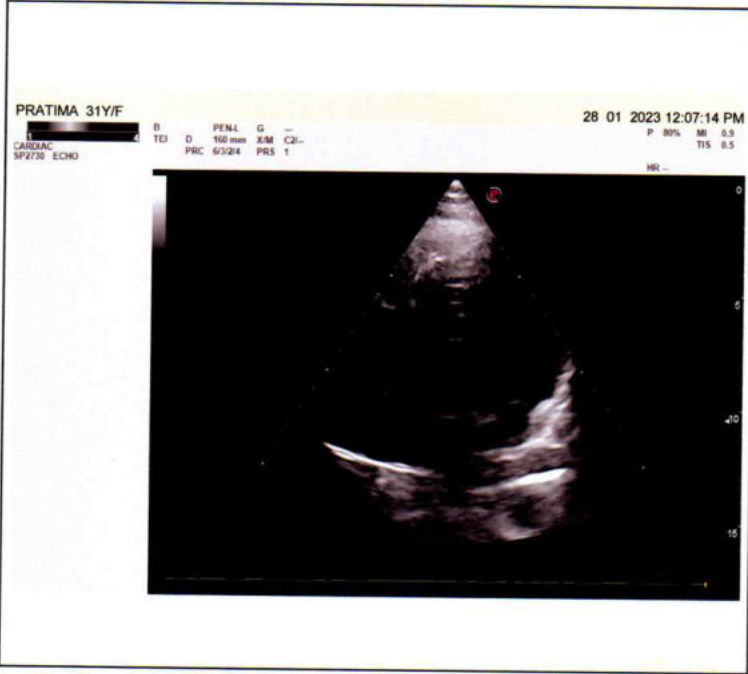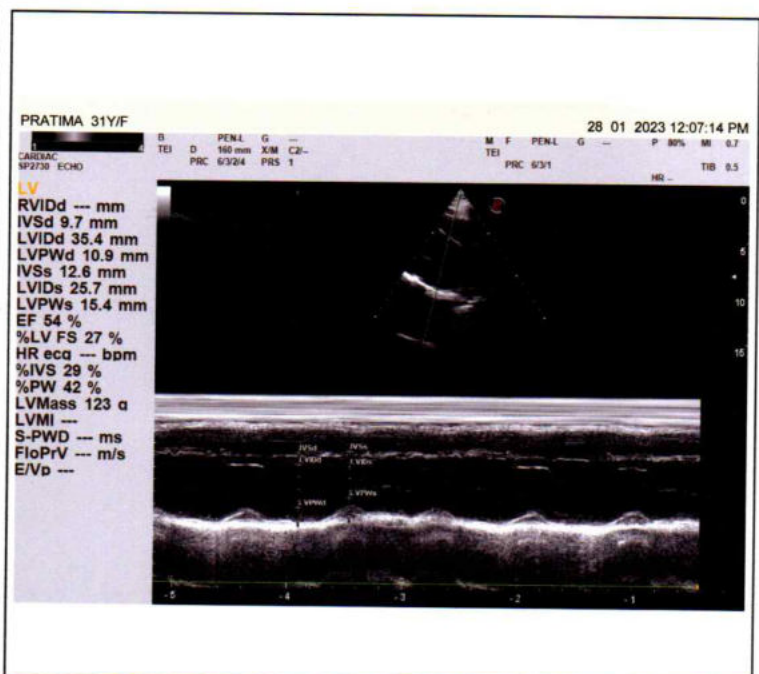
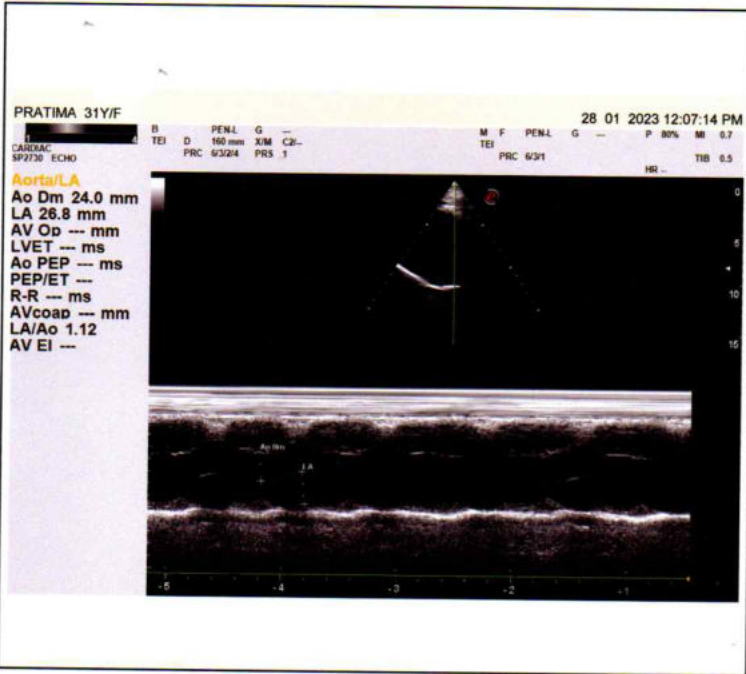
Niraj Mishra  
Physician Assistant  
(PIIRE)

*Pallavi*  
**DR. PALLAVI MISHRA**  
MBBS, MD (GENERAL MEDICINE)  
MBBS, MD (CARDIOLOGY)  
MCI Reg. No. 52033  
Non Invasive Cardiologist  
Women Cardiologist  
Diabetocardiologist

Address : Kabir Nagar (Near Sanjay Shiksha Niketan), Durgakund, Varanasi

Mobile : 9554572190 / 9453837595 / Recpn. 9389994334

E-mail : dramishra@gmail.com, drpallaviojha@gmail.com, Website: www.piire.org







# PANACEA HOSPITAL

*A shelter for many hearts A Home for many lives*

(An ISO 9001:2008 Certified Organisation)

Lab Attached with CMC Vellore Under EQAS Scheme

**NAME:** MRS. PRATIMA

**AGE/SEX:** 31 YRS / FEMALE

**REF BY:** DR. ASHUTOSH MISHRA (MD)

**DATE:** 28/01/2023

## ULTRA SOUND FOR ABDOMAN REPORT

**Liver:** Normal in shape and size (12.1 cm) and shows mildly increased echogenicity. Margins are smooth and regular. No focal lesion seen.

**Gall bladder** Partially distended with normal wall thickness and echo-free lumen.

**CBD** Visualized part normal in course & caliber.

**Pancreas:** Normal in size, shape & echogenicity. Margins are smooth & regular. No diffuse/ focal lesion seen. Pancreatic tail obscured.

**Spleen:** Normal in size(10.8 cm) shape & echogenicity. Margins are smooth & regular. No diffuse / focal lesion seen. Splenic vessels at hilum is normal.

**Kidney:** Right kidney: 9.6 X 4.4cm  
Left kidney: 9.5 X 4.3 cm  
Normal cortical echogenicity with well maintained Cortical-medullary differentiation. Pelvicalyceal system normal. No calculus/mass lesion seen. No hydronephrosis/ hydroureter seen.

**Address :** Kabir Nagar (Near Sanjay Shiksha Niketan), Durgakund, Varanasi

**Mobile :** 9554572190 / 9453837595 / Recpn. 9389994334

**E-mail :** dramishra@gmail.com, drpallaviojha@gmail.com, **Website:** www.piire.org



# PANACEA HOSPITAL

*A shelter for many hearts A Home for many lives*

(An ISO 9001:2008 Certified Organisation)

Lab Attached with CMC Vellore Under EQAS Scheme

- Urinary bladder:** Normally distended, wall thickness is normal.  
No echogenic foci lumen or diverticula seen.  
Both VUJ appears normal.  
No E.R. calculus / mass lesion seen.
- Uterus:** Uterus normal in size shape, & echogenicity.  
Margins are smooth & regular.  
Endometrial thickness within normal limits .
- Ovary:** Right ovary normal in size and shows normal morphology.  
Left ovary normal in size and shows normal morphology.
- Others:** No free fluid in peritoneal cavity.  
No free fluid in bilateral pleural cavity.

#### IMPRESSION:

- *Grade i fatty liver.*

Please correlate clinically and further investigations.

*Pallavi*  
**DR. PALLAVI MISHRA**  
MBBS, MD (GENERAL MEDICINE)  
MCI Reg. No. 52033  
**DR. PALLAVI MISHRA**  
MBBS MD(MED) Lucknow  
Echocardiography specialist, MIAE  
Non invasive cardiologist  
Women cardiologist

*[Signature]*  
Radiologist

**Dr. Tusharika Rai**  
MBBS MS

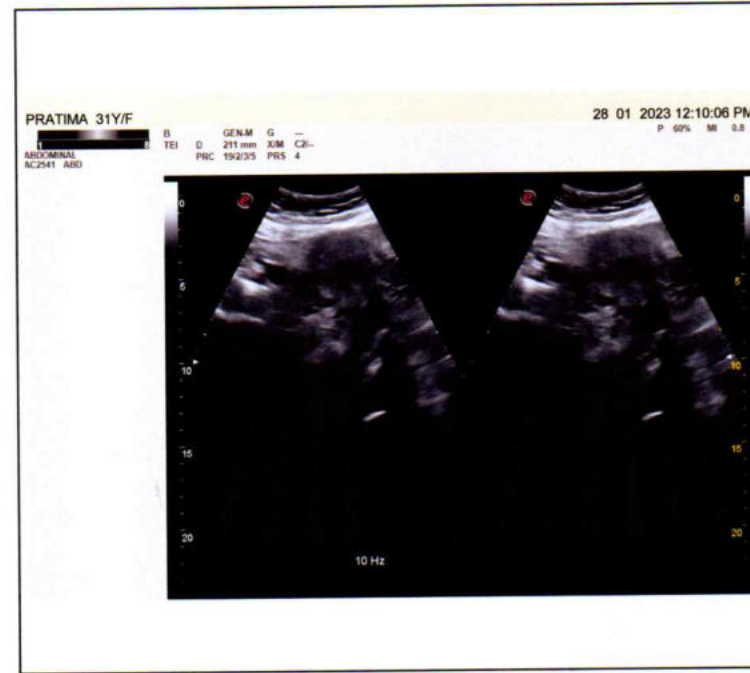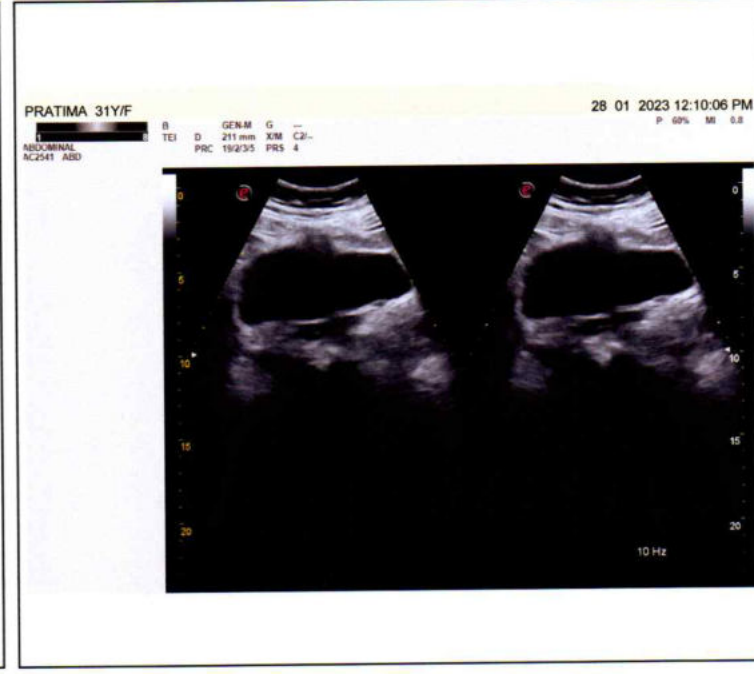
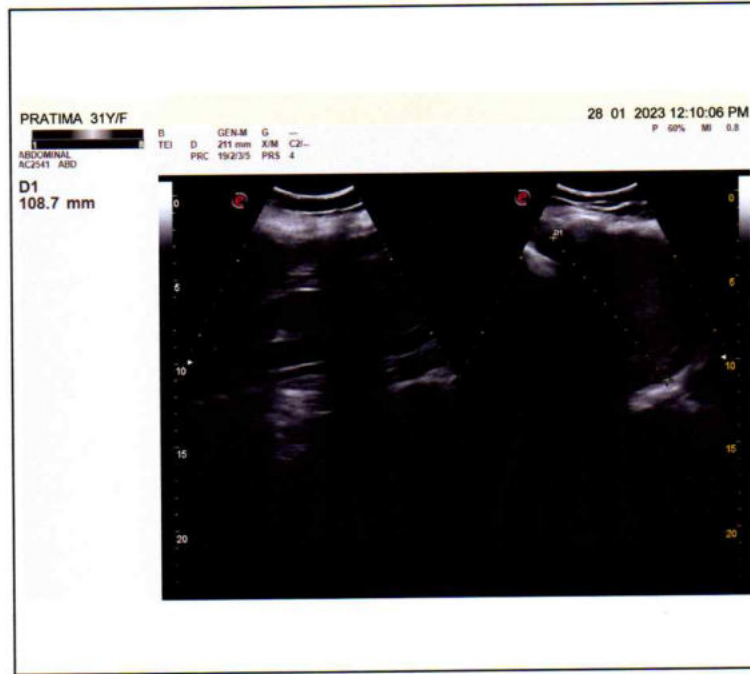
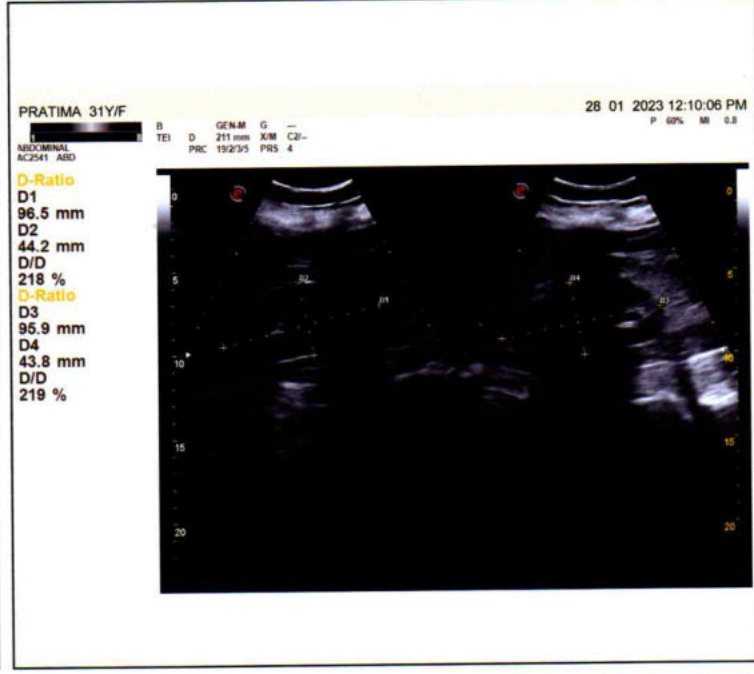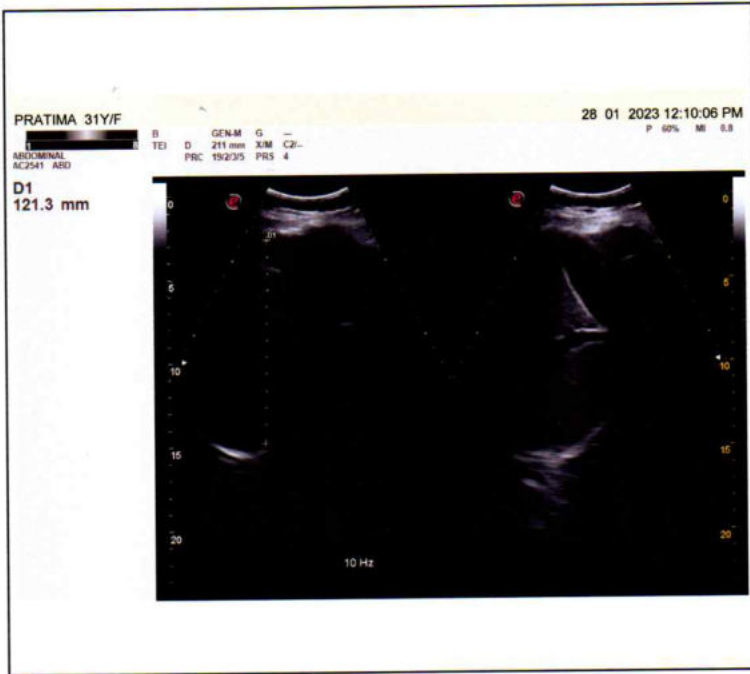
- Note: (1) This report is not valid for medico-legal purposes.  
(2) In case of any discrepancy due typing error, please get it Rectified immediately.

Address : Kabir Nagar (Near Sanjay Shiksha Niketan), Durgakund, Varanasi

Mobile : 9554572190 / 9453837595 / Recpn. 9389994334

E-mail : dramishra@gmail.com, drpallaviojha@gmail.com, Website: www.piire.org







# PANACEA HOSPITAL

*A shelter for many hearts A Home for many lives*

(An ISO 9001:2008 Certified Organisation)

Lab Attached with CMC Vellore Under EQAS Scheme

**NAME:** MRS.PRATIMA

**AGE/SEX:** 31 YRS / FEMALE

**REF BY:** DR. ASHUTOSH MISHRA (MD)

**DATE:** 28/01/2023

## X-RAY CHEST PA

### BOTH LUNG FIELDS AND PLEURAE:

Both lungs show normal bronchovascular pattern.

Right & left hila are normal

No focal mass or calcification is seen

There is no evidence of any fluid in the both the pleural cavities.

Both domes of diaphragms are normal in position.

### MEDIASTINUM:

Trachea is central in position.

Cardiac silhouette is of normal size and configuration.

No evidence of pericardial effusion.

No significant lymphadenopathy is seen.

Visualized skeleton is normal.

-----  
NO SIGNIFICANT RADIOGRAPHIC ABNORMALITY.

  
Radiologist

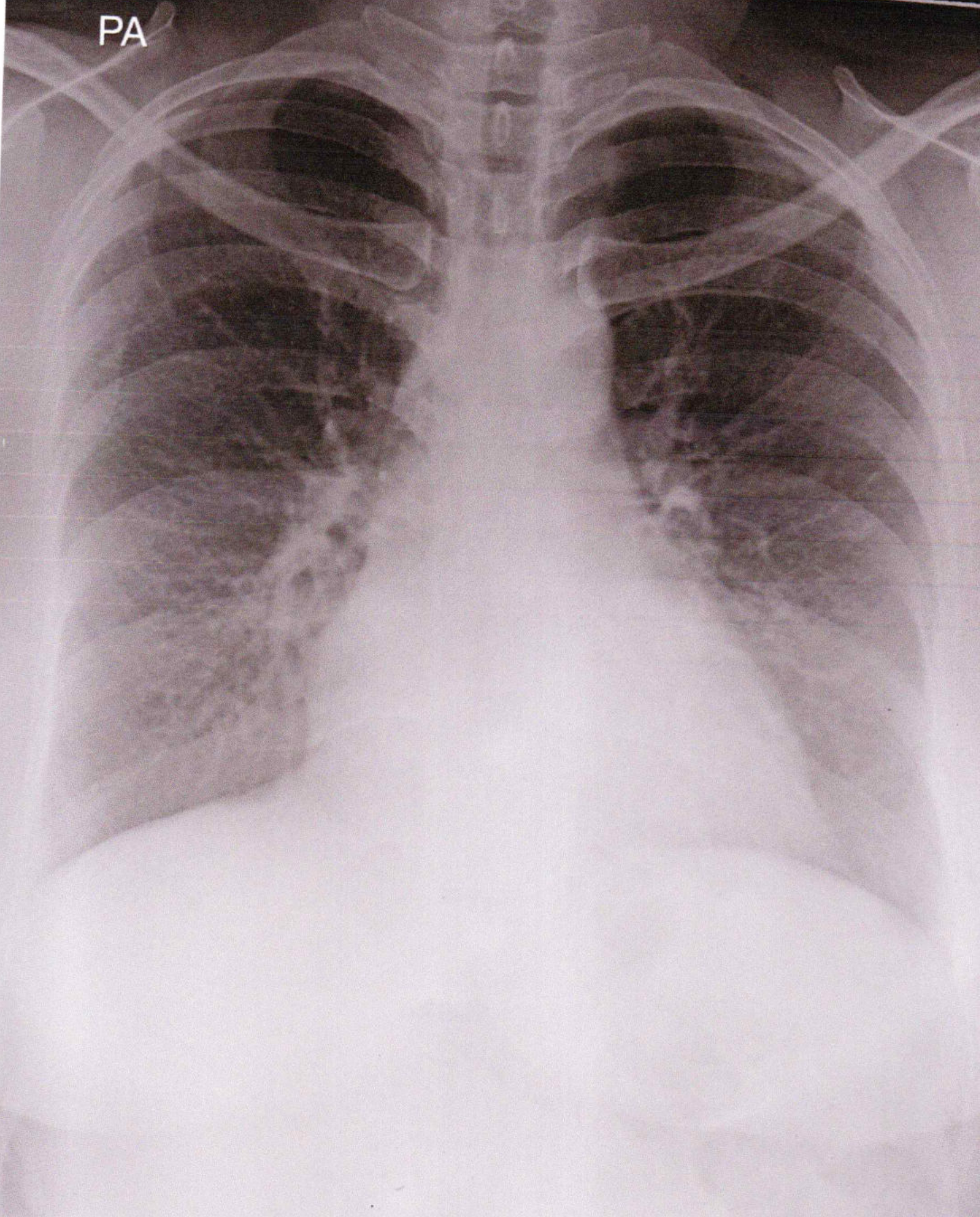
Address : Kabir Nagar (Near Sanjay Shiksha Niketan), Durgakund, Varanasi

Mobile : 9554572190 / 9453837595 / Recpn. 9389994334

E-mail : dramishra@gmail.com, drpallaviojha@gmail.com, Website: www.piire.org



R  
PA



PRATIMA 31Y/F 3445 O CHEST P.A. 28-Jan-23 11:51 AM

PANACEA HOSPITAL, KABIR NAGAR, DURGAKUND, VARANASI