

Facilities:

All clinical Biomedical & Hematology Investigations including Bone Marrow Examination VPT, Podiascan & Complete Foot Care (First Time in Purvanchal) All Hormonal Investigation by Chemiluminescent Method Visceral Fat by (AB-140) Ambulatory BP Monitoring CGMS & Insulin Pump Available PFT, 2D-ECHO (Color Doppler), Holter, TMT, Cardiac-3 available VIA, VILI, Colposcopy available Special Endocrinological Investigation Protocols.

ISO 9001:2008 Certified
Mobile: 9389994334, 9554572190, 9453837595



Panacea Pathology

Clinical Reference Lab

Persistence, Preparedness and Precision
EQAS (CMC Vellore Attached) & IQAS System
पूर्वाचल की सर्वोत्तम गुणवत्ता वाली पैथोलॉजी

PATIENT NAME : ANURADHA KUMARI

AGE/GENDER : 28 YRS/FEMALE

REFD BY DR. : ARCO FEMI HEALTHCARE LTD.

RECEIVED DATE : 26-01-2023(10:00AM)

SAMPLE : BLOOD & URINE

REPORT DATE : 26-01-2023(06:00PM)

PATHOLOGY REPORT

COMPLETE BLOOD COUNT (CBC)

TEST	LAB TEST VALUES	NORMAL RANGE
HEMOGRAM		
HEMOGLOBIN (FLOW CYTOMETRY)	12.8	13 – 16 gm/dl
TOTAL LEUCOCYTE COUNT (TLC)	4,800	4000 – 11000
RBC COUNT	4.17	3.5 – 5.5
PCV (HCT)	39.8	37 – 47
MCV	95.4	80 – 95
MCH	30.4	28 – 34
MCHC	32.2	30 – 36
PLATELET COUNT	2,23,000	1,50,000 – 4,00,000
E.S.R. (WINTROBE FIRST HOURS)	12.0	20 mm/1 st hr
DIFFERENTIAL LEUCOCYTE		
NEUTROPHILS	42	40 – 75%
LYMPHOCYTES	51	20 – 45%
EOSINOPHILS	04	1 – 6%
MONOCYTES	03	2 – 8%
BASOPHILS	00	< 2%

RENAL & KIDNEY PROFILE, SERUM

TEST	LAB TEST VALUES	NORMAL RANGE
RENAL FUNCTION TESTS		
BLOOD UREA NITROGEN (BUN)	9.2	10 – 50 mg/dl
SERUM CREATININE	0.68	0.60 – 1.60 mg/dl
URIC ACID	3.7	3.60 – 7.70 mg/dl
ALKALINE PHOSPHATASE (ALP)	69.0	142 – 353 mg/dl
TOTAL PROTIENS	7.41	0 – 39 mg/dl
ALBUMIN	4.21	3.8 – 5.4 mg/dl
SERUM GLOBULIN	3.20	2.1 – 3.5 mg/dl
CALCIUM	9.0	8.80 – 10.20
PHOSPHORUS	3.04	2.50 – 5.00
SERUM SODIUM NA+	1.005	135.00 – 155.00 mEq/Ltr
SERUM POTASIUM K+	4.12	3.60 – 5.50 mEq/Ltr
ICALCIUM	1.22	1.10 – 1.35 mmol/L
SERUM CHLORIDE CL+	101.3	98.00 – 110.00 mEq/Ltr

PAGE 1

Lab Technician

PANACEA HOSPITAL
(A UNIT OF ARCO FEMI HEALTH CARE PVT. LTD.)
REG. NO.: AL-1500
B.36/44 FK KABIR NAGAR
DURGAKUND, VARANASI

Timing : 8.00 a.m. to 9.00 p.m. (Sunday 8.00 a.m. to 3.00 p.m.)

This Report is not valid for medico legal purpose

Note: These tests have technical limitations. Clinico-pathological interpretation is necessary. In case of any disparity test may be repeated immediately.

Address : 36/44 FK Kabir Nagar, Durgakund, Varanasi – 221005

Email: dramishra@gmail.com, drpallaviojha@gmail.com Website: panaceahospital.org

Facilities:

All clinical Biomedical & Hematology Investigations
 including Bone Marrow Examination
 VPT, Podiascan & Complete Foot Care (First Time in Purvanchal)
 All Hormonal Investigation by Chemiluminescent Method
 Visceral Fat by (AB-140) Ambulatory BP Monitoring
 CGMS & Insulin Pump Available
 PFT, 2D-ECHO (Color Doppler), Holter, TMT, Cardiac-3 available
 VIA, VILI, Colposcopy available
 Special Endocrinological Investigation Protocols.

ISO 9001:2008 Certified
 Mobile: 9389994334, 9554572190, 9453837595



Panacea Pathology

Clinical Reference Lab

Persistence, Preparedness and Precision
 EQAS (CMC Vellore Attached) & IQAS System
 पूर्वांचल की सर्वोत्तम गुणवत्ता वाली पैथोलॉजी

PATIENT NAME : ANURADHA KUMARI	AGE/GENDER : 28 YRS/FEMALE
REFD BY DR. : ARCO FEMI HEALTHCARE LTD.	RECEIVED DATE : 26-01-2023(10:00AM)
SAMPLE : BLOOD & URINE	REPORT DATE : 26-01-2023(06:00PM)

PATHOLOGY REPORT

LIPID PROFILE, SERUM

TEST	LAB TEST VALUES	NORMAL RANGE
BLOOD CHEMISTRY		
TOTAL CHOLESTEROL (SERUM)	146.0	Desirable:- < 200 mg/dl Borderline:- 200 – 239 mg/dl High:- > 240 mg/dl
TRIGLYCERIDES (SERUM)	132.0	35 – 170 mg/dl
HDL CHOLESTEROL (SERUM)	36.0	35.30 – 79.50 mg/dl
LDL CHOLESTEROL (SERUM)	83.6	< 130 mg/dl
VLDL	26.4	< 40 mg/dl
CHOLESTROL/HDL RATIO	4.0	< 3.0 Low Risk Ratio 3.0 – 5.0 Avg Risk > 5.0 High Risk
LDL/HDL RATIO	0.43	< 3 Ratio

BLOOD GROUP

TEST	LAB TEST VALUES
BLOOD GROUP ABO & RH FACTOR	"O"
BLOOD GROUP	POSITIVE
RH FACTOR	

GLYCOSYLATED HEMOGLOBIN (HBA1C)

TEST	LAB TEST VALUES	NORMAL RANGE
HBA1C	4.8	Normal : <5.97 % Good Control : 5.97 – 6.81% Fair Control : 6.81 – 7.65% Poor Control : >7.65%

THYROID PROFILE (T3, T4, TSH)

TEST	LAB TEST VALUES	NORMAL RANGE
THYROID FUNCTION TEST		
T3	1.11	0.60 – 1.81 ng/ml
T4	7.46	4.50 – 10.90 ug/dl
TSH	9.0	0.39 – 6.10 uIU/mL

PAGE 2

Lab Technician

PANACEA HOSPITAL
 (A UNIT OF ARCO FEMI HEALTH CARE PVT. LTD.)
 REG. NO. AL/1500
 M.D. Pathology
 B.36/44, B-4, KABIR NAGAR
 DURGAKUND, VARANASI

Timing : 8.00 a.m. to 9.00 p.m. (Sunday 8.00 a.m. to 3.00 p.m.)

This Report is not valid for medico legal purpose

Note: These tests have technical limitations. Clinico-pathological interpretation is necessary. In case of any disparity test may be repeated immediately.

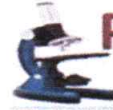Address : 36/44 FK Kabir Nagar, Durgakund, Varanasi – 221005

Email: dramishra@gmail.com, drpallaviojha@gmail.com Website: panaceahospital.org

Facilities:

All clinical Biomedical & Hematology Investigations including Bone Marrow Examination
VPT, Podiascan & Complete Foot Care (First Time in Purvanchal)
All Hormonal Investigation by Chemiluminescent Method
Visceral Fat by (AB-140) Ambulatory BP Monitoring
CGMS & Insulin Pump Available
PFT, 2D-ECHO (Color Doppler), Holter, TMT, Cardiac-3 available
VIA, VILI, Colposcopy available
Special Endocrinological Investigation Protocols.

ISO 9001:2008 Certified
Mobile: 9389994334, 9554572190, 9453837595



Panacea Pathology

Clinical Reference Lab

Persistence, Preparedness and Precision
EQAS (CMC Vellore Attached) & IQAS System
पूर्वचल की सर्वोत्तम गुणवत्ता वाली पैथोलॉजी

PATIENT NAME : ANURADHA KUMARI

AGE/GENDER : 28 YRS/FEMALE

REFD BY DR. : ARCO FEMI HEALTHCARE LTD.

RECEIVED DATE : 26-01-2023(10:00AM)

SAMPLE : BLOOD & URINE

REPORT DATE : 26-01-2023(06:00PM)

PATHOLOGY REPORT

LIVER PROFILE TEST, SERUM

TEST	LAB TEST VALUES	NORMAL RANGE
BIO CHEMISTRY		
TOTAL BILIRUBIN	0.66	0.0 – 1.1 mg/dl
DIRECT BILIRUBIN	0.24	0.0 – 0.2 mg/dl
INDIRECT BILIRUBIN	0.42	< 0.90 mg/dl
SGOT (AST)	21.6	0 – 52 mg/dl
SGPT (ALT)	23.2	0 – 39 mg/dl
GGT (GYT)	18.6	< 55 U/L

URINE ROUTINE EXAMINATION

TEST	LAB TEST VALUES	NORMAL RANGE
PHYSICAL EXAMINATION		
QUANTITY	29	ML
COLOUR	STRAW	PALE YELLOW
APPEARANCE	CLEAR	CLEAR
SPECIFIC GRAVITY	1.005	1.01 – 1.03
PH	5.0	4.7 – 7.5
CHEMICAL EXAMINATION		
GLUCOSE	Not Detected	Not Detected
PROTEIN	NIL	Not Detected
MICROSCOPIC EXAMINATION		
PUS CELLS	1-2	0-5
RBC	Not Detected	Not Detected
EPITHELIAL CELLS	2-3	0-5
CASTS	Not Detected	Not Detected
CRYSTALS	Not Detected	Not Detected
BACTERIA	Not Detected	Not Detected

RANDOM/FASTING BLOOD SUGAR

TEST	LAB TEST VALUES	NORMAL RANGE
RBS/FBS		
RANDOM BLOOD SUGAR	110.0	125-140 mg/dl
FASTING BLOOD SUGAR	107	110-125 mg/dl

----- End of Report -----

Lab Technician

PANACEA HOSPITAL
(A UNIT OF ARCO FEMI HEALTH CARE PVT. LTD.)
REG. NO. 123456
B-36/44, B-4, KABIR NAGAR
DURGAKUND, VARANASI

Timing : 8.00 a.m. to 9.00 p.m. (Sunday 8.00 a.m. to 3.00 p.m.)

This Report is not valid for medico-legal purpose

Note: These tests have technical limitations. Clinico-pathological interpretation is necessary. In case of any disparity test may be repeated immediately.

Address : 36/44 FK Kabir Nagar, Durgakund, Varanasi – 221005

Email: dramishra@gmail.com, drpallaviojha@gmail.com Website: panaceahospital.org



PANACEA HOSPITAL

A shelter for many hearts A Home for many lives

(An ISO 9001:2008 Certified Organisation)

Lab Attached with CMC Vellore Under EQAS Scheme

ime	MRS.ANURADHA KUMARI	Sex /Age	28/F	Date	26/01/2023
f. by	Dr.Pallavi Mishra(MD)	BSA - m ²		Echo window	fair

Echo - Cardiography

MITRAL VALVE Doppler	AML - normal morphology MV Flow - E - 1.1 A-0.8 E/A=1.38	PML - normal morphology MVA - 3.0 cm ² Mitral Regurgitation - No
TRICUSPID VALVE Doppler	Normal TV Flow -No	Tricuspid Regurgitation - No
PULMONARY VALVE Doppler	Normal PV Flow -No	Pulmonary Regurgitation - No
AORTIC VALVE Doppler	Trileaflet-No AV Flow - no	Aortic Regurgitation - no
MEASUREMENT	Aorta - 21.0 (20-38) mm IVS ed - 8.9 (6 -12) mm LVID ed - 22.9 (35 - 55) mm LVPW ed - 12.6 (6 -12) mm OA - 7 (> 5) mm	LA - 22.0 (24-32) mm IVS es -12.0 (6 - 12) mm LVID es - 15.4 (24 - 40) mm LVPW es - 11.2 (6 -12) mm EPSS - 6 (< 9) mm


Note:-Tachycardia present

CONCLUSION All cardiac chamber dimensions are WNL
No valvular abnormalities
Good LV systolic function present Modified Simpson's method (4C, 2C) (LVEF-64%)
No diastolic dysfunction present (E/A = 1.38) by tissue Doppler (E/e'=6.2)
No RWMA
No pericardial effusion
Intact IAS / IV
No PAH
No intra cardiac mass /thrombus /vegetation

IMPRESSION

Normal Echocardiogram

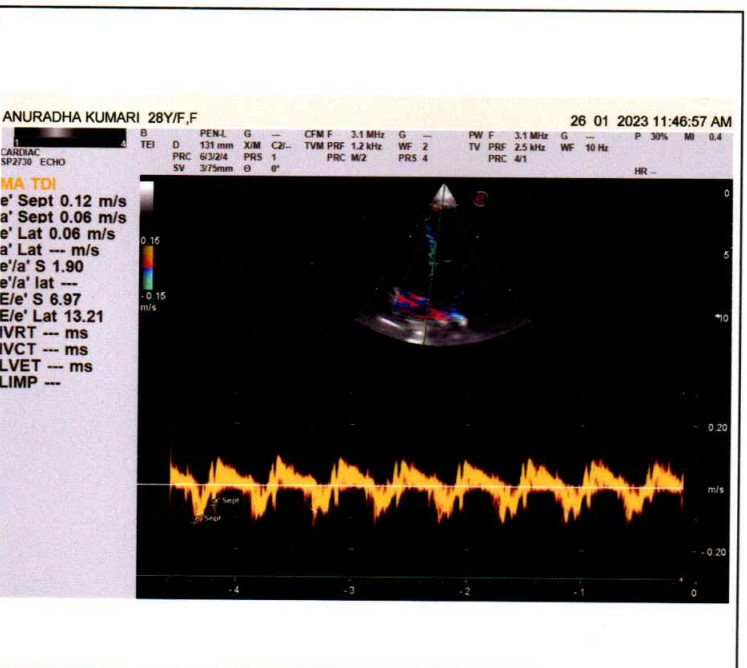
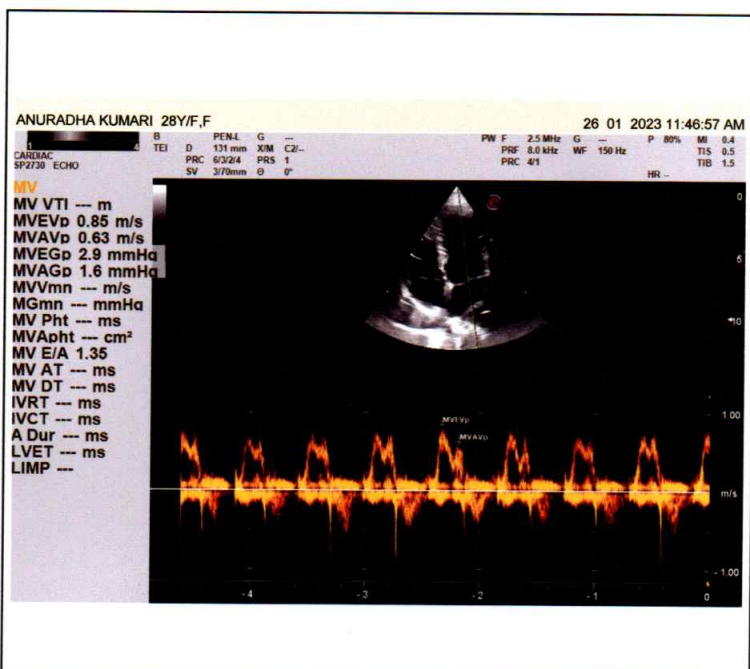
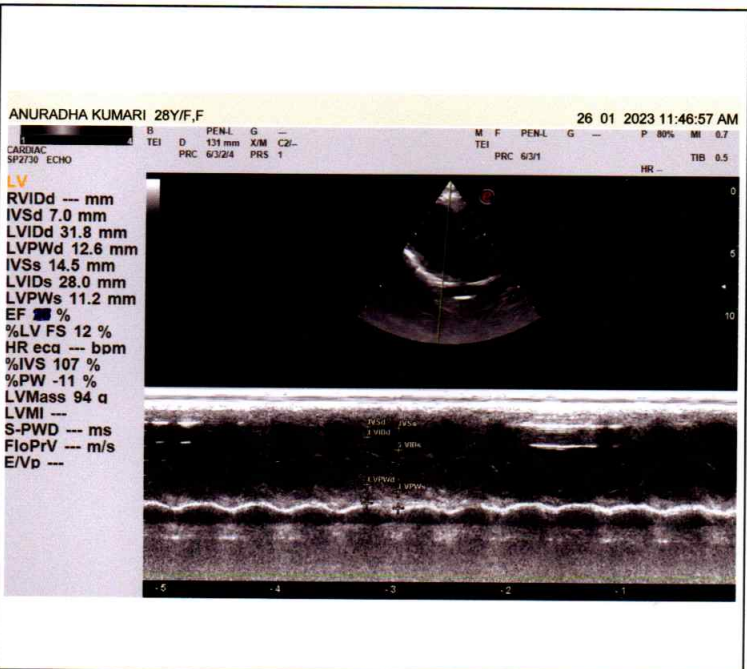
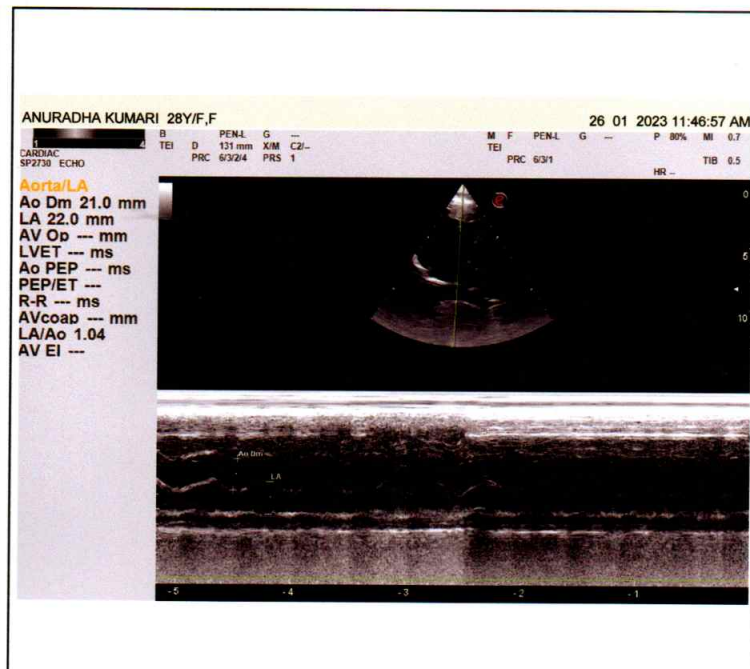
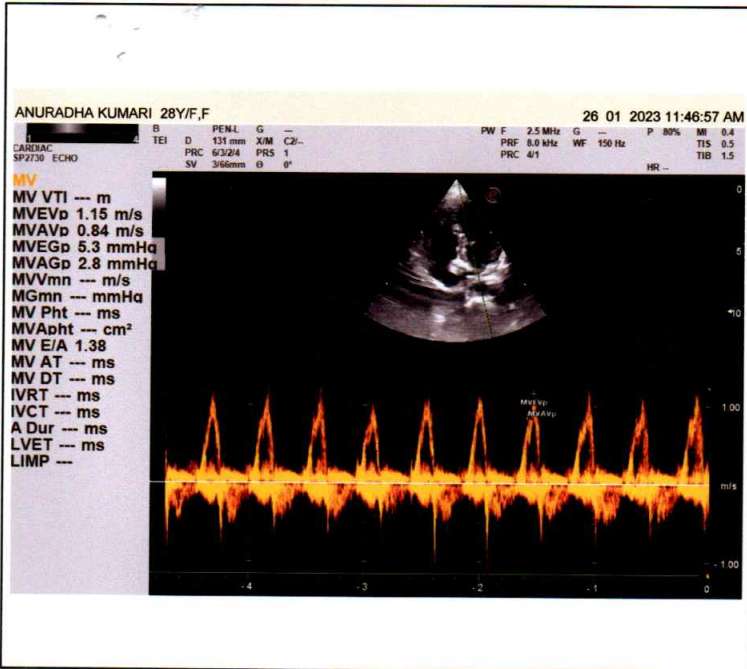

Niraj Mishra
Physician Assistant
(PHIRE)

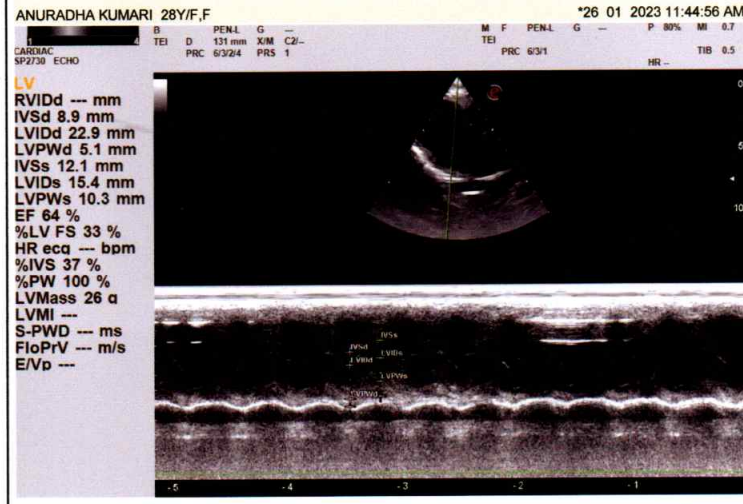
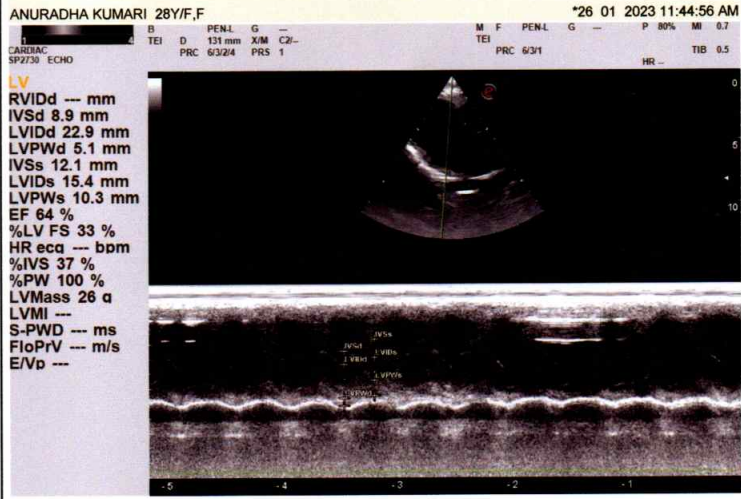

DR. PALLAVI MISHRA
MBBS,MD (GENERAL MEDICINE)
MCI Reg.No. 52033
Dr. Pallavi Mishra
MBBS, MD (MED) Lucknow
Echocardiography Specialist, MIAE
Non-invasive cardiologist
Women Cardiologist
Diabetocardiologist

Address : Kabir Nagar (Near Sanjay Shiksha Niketan), Durgakund, Varanasi

Mobile : 9554572190 / 9453837595 / Recpn. 9389994334

E-mail : dramishra@gmail.com, drpallaviojha@gmail.com, Website: www.piire.org







PANACEA HOSPITAL

B 36/44 F.K KABIR NAGAR, DURGAKUND
TOLLFREE NO-18001233070.
Whatsapp No - 8795832852
www.piire.org



OP Slip

Print Date : 26-Jan-2023 04:33PM



UHID No :- UD-22230003419	OP No :- OP-22230012692	OP Date :- 26 Jan 2023 4:33PM
Patient Name :- Ms. ANURADHA KUMARI BOB	Age/Sex :- 28 Y/Female	Mobile No :- 8521671958
Father :- INDU SHEKHAR SINGH	Department :- DIABETES, ENDOCRINOLOGY & METABOLIC PHYSICIAN	
Pay Type :- Cash	Consultant :- Dr ASHUTOSH MISHRA (MD(MEDICINE), IMS, BHU)	
Token No :- NOR. - 16	Paid/Bal :- 0.00 /470.00	
Patient Type :- Normal		
Address :- NAGWA, varanasi		

BP :-
height :-
Weight (kg) :-
BMI :-

Rx

Emphysema.

ADW
• Amb TPO...

Rx.
Tab. Montelukast AB (200/10) OD
• Dichebe dret- 1 Booklet (d)
• es. Amylase (100) OD (1/2 tab)
• es. Column M2 OD

• Avul (60) ADx(10)

↓
SUNITW.

RIA 2 month

019 Influenza IMSh

Printed By : Mr NITIN YADAV

Created By : Mr NITIN YADAV



PANACEA HOSPITAL

B 36/44 F.K KABIR NAGAR, DURGAKUND
TOLLFREE NO-18001233070.
Whatsapp No - 8795832852
www.piire.org



OP Slip

Print Date : 26-Jan-2023 11:31AM



UHID No :- UD-22230003419	OP No :- OP-22230012675	OP Date :- 26 Jan 2023 11:31AM
Patient Name :- Ms. ANURADHA KUMARI BOB	Age/Sex :- 28 Y/Female	Mobile No :- 8521671958
Father :- INDU SHEKHAR SINGH	Department :- OPHTHALMOLOGY	
Pay Type :- Cash	Consultant :- Dr ANKIT SONI (MBBS,MS)	
Token No :- NOR. - 1	Paid :- 0.00	
Patient Type :- Normal		
Address :- NAGWA, varanasi		

BP :-
height :-
Weight (kg) :-
BMI :-

Rx

with glass

VA $\left\{ \begin{array}{l} 6/9 \\ 6/9 \end{array} \right.$

PH

VA $\left\{ \begin{array}{l} \text{NO IMP} \\ \text{NO IMP} \end{array} \right.$

AR $\left\{ \begin{array}{l} -3.25 \text{ DSpH} / -0.25 \text{ cyl} \times 103^\circ \\ -3.00 \text{ DSpH} / -1.25 \text{ cyl} \times 127^\circ \end{array} \right.$

[ST $\left\{ \begin{array}{l} -3.25 \text{ DSpH} \\ -3.00 \text{ DSpH} / -0.75 \text{ cyl} \times 140^\circ \end{array} \right.$

E/d - s.c.m 0000.

Printed By : Mr NITIN YADAV

Created By : Mr NITIN YADAV



PANACEA HOSPITAL

B 36/44 F.K KABIR NAGAR, DURGAKUND
TOLLFREE NO-18001233070.
Whatsapp No - 8795832852
www.piire.org



OP Slip

Print Date : 26-Jan-2023 11:17AM



UHID No	:- UD-22230003419	OP No	:- OP-22230012673	OP Date	:- 26 Jan 2023 11:17AM
Patient Name	:- Ms. ANURADHA KUMARI BOB	Age/Sex	:- 28 Y/Female	Mobile No	:- 8521671958
Father	:- INDU SHEKHAR SINGH	Department	:- GYNAECOLOGY		
Pay Type	:- Cash	Consultant	:- Dr VANDANA SINGH (MBBS,MS)		
Token No	:- NOR. - 2	Paid/Bal	:- 0.00 /30.00		
Patient Type	:- Normal				
Address	:- NAGWA, varanasi				

BP :- 110/90
 height :- 147
 Weight (kg) :- 29.9
 BMI :- 13.8
 SpO₂ - 97
 PR - 122

Rx LMP - 7/1/23 - Regular / 3-5d / 2-3p /
 unmarried.
 No gynae. complaints.

S-TSH - 9.0
 CxR - 40 - COPD

→ Tab ^{adv} thyrox 25~~0~~ ug x OD x BD
 → Tab zincovit w 1 x BD x 7d

Refer. to Dr. Ashutosh Sin

Printed By : Mr NITIN YADAV
 Created By : Mr NITIN YADAV

AUTO 10mm/mV

10mm/mV

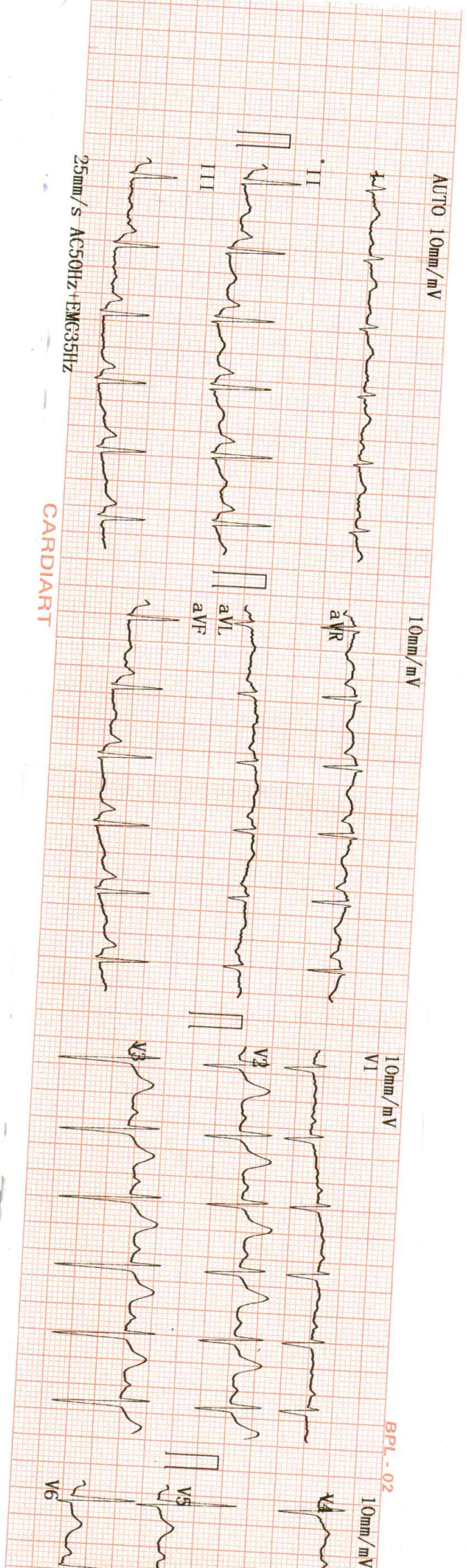
10mm/mV

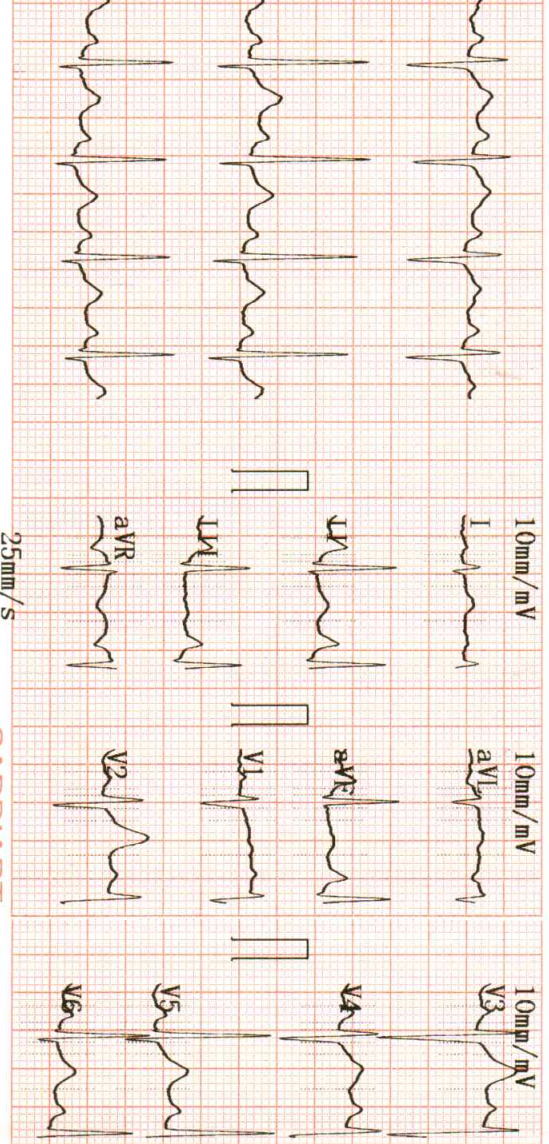
10mm/mV

25mm/s AC50Hz+EMG35Hz

CARDIART

BPL-02





25mm/s

CARDIART

2023-01-26 12:36

<< Conclusions >>

BPL - 02

ID :
 Name : Anurodha Kumaru
 Sex : F
 Height :
 Weight : 29 kg
 Age : 28
 SYS :
 DIA :
 HR : 114 bpm
 PR Interval : 132 ms
 P Duration : 94 ms
 QRS Duration : 69 ms
 T Duration : 185 ms
 QT/QTc : 321/443 ms
 P/QRS/T Axis : 83.1/80.7/-3.0 deg
 R(V5)/S(V1) : 1.53/0.51 mV
 R(V5)+S(V1) : 2.05 mV

Sinus mode Tachycardia;
 Cardiac electric axis normal;

Report need physician confirm

DR. PALLAVI MISHRA
 MBBS, MD (GENERAL MEDICINE)
 Reg. No. 52032

Physician _____



PANACEA HOSPITAL

A shelter for many hearts A Home for many lives

(An ISO 9001:2008 Certified Organisation)

Lab Attached with CMC Vellore Under EQAS Scheme

NAME: MRS. ANURADHA KUMARI

AGE/SEX: 28 YRS / FEMALE

REF BY: DR. ASHUTOSH MISHRA (MD)

DATE: 26/01/2023

ULTRA SOUND FOR ABDOMAN REPORT

- Liver:** Normal in shape and size(8.5 cm) and shows smooth and regular margin.
No diffuse/focal lesion seen.
- Gall bladder** Partially distended with normal wall thickness and echo-free lumen.
- CBD** Visualized part normal in course & caliber.
- Pancreas:** Normal in size, shape & echogenicity.
Margins are smooth & regular.
No diffuse/ focal lesion seen. Pancreatic tail obscured.
- Spleen:** Normal in size(8.1 cm) shape & echogenicity.
Margins are smooth & regular. No diffuse / focal lesion seen.
Splenic vessels at hilum is normal.
- Kidney:** Right kidney: 8.8 X 3.4cm
Left kidney: 9.3 X 4.8 cm
Normal cortical echogenicity with well maintained Cortical-medullary differentiation.
Pelvicalyceal system normal.
No calculus/mass lesion seen.
No hydronephrosis/ hydroureter seen.

Address : Kabir Nagar (Near Sanjay Shiksha Niketan), Durgakund, Varanasi

Mobile : 9554572190 / 9453837595 / Recpn. 9389994334

E-mail : dramishra@gmail.com, drpallaviojha@gmail.com, Website: www.paire.org



PANACEA HOSPITAL

A shelter for many hearts A Home for many lives

(An ISO 9001:2008 Certified Organisation)

Lab Attached with CMC Vellore Under EQAS Scheme

Urinary bladder: Minimally distended, wall thickness is normal.
No echogenic foci lumen or diverticula seen.

Uterus: Uterus normal in size shape, & echogenicity.
Margins are smooth & regular.
Endometrial thickness within normal limits.

Ovary: Right ovary normal in size and shows normal morphology.
Left ovary normal in size and shows normal morphology.

Others: No free fluid in peritoneal cavity.
No free fluid in bilateral pleural cavity.

IMPRESSION:

- NO SIGNIFICANT SONOLOGICAL ABNORMALITY DETECTED.

Please correlate clinically and further investigations.

DR. PALLAVI MISHRA
MBBS, MD (GENERAL MEDICINE)
MCI Reg.No. 52033

DR. PALLAVI MISHRA

MBBS MD(MED) Lucknow

Echocardiography specialist, MIAE

Non invasive cardiologist

Women cardiologist

Radiologist

Dr.Tusharika Rai

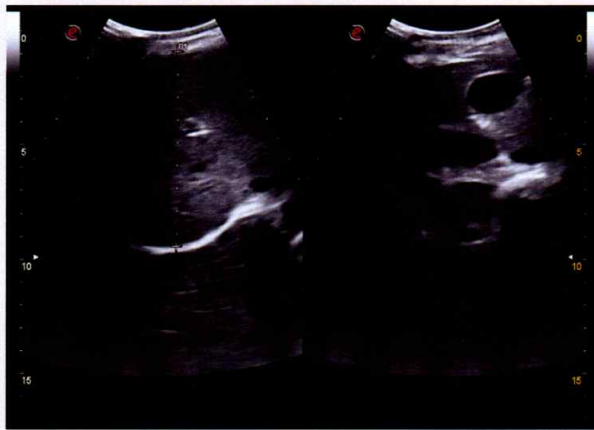MBBS MS

Note: (1) This report is not valid for medico-legal purposes.

(2) In case of any discrepancy due typing error, please get it Rectified immediately.

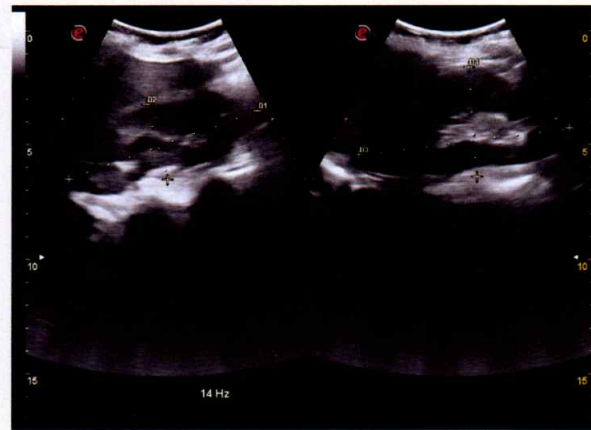
ANURADHA KUMARI 28Y/F,F
26 01 2023 11:54:19 AM
P 60% MI 0.8

D1
85.3 mm



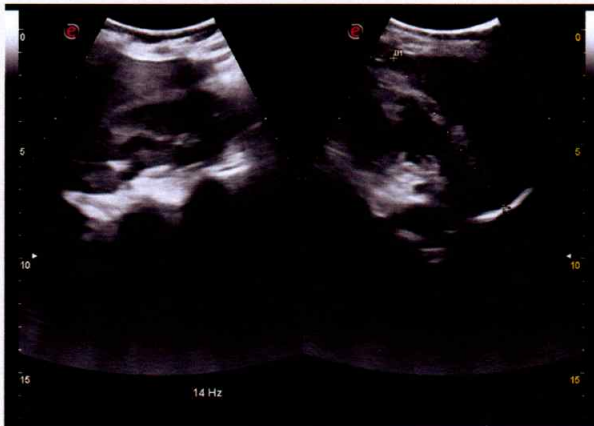ANURADHA KUMARI 28Y/F,F
26 01 2023 11:54:19 AM
P 60% MI 0.8

D-Ratio
D1
88.1 mm
D2
34.2 mm
D/D
258 %
D-Ratio
D3
93.0 mm
D4
48.2 mm
D/D
193 %

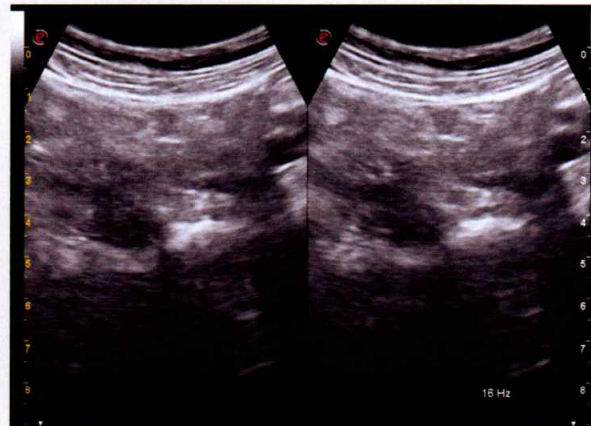


ANURADHA KUMARI 28Y/F,F
26 01 2023 11:54:19 AM
P 60% MI 0.8

D1
81.5 mm



ANURADHA KUMARI 28Y/F,F
26 01 2023 11:54:19 AM
P 60% MI 0.8



Call Now - 1800-123-3070



PANACEA HOSPITAL

A shelter for many hearts A Home for many lives

(An ISO 9001:2008 Certified Organisation)

Lab Attached with CMC Vellore Under EQAS Scheme

NAME: MRS. ANURADHA KUMARI

AGE/SEX: 28 YRS / FEMALE

REF BY: DR. ASHUTOSH MISHRA (MD)

DATE: 26/01/2023

X-RAY CHEST PA

BOTH LUNG FIELDS AND PLEURAE:

Coarse bronchovascular markings with hyperinflation of lungs suggestive of - COPD.

Right & left hila are normal

There is no evidence of any fluid in the both the pleural cavities.

Both domes of diaphragms are normal in position.

MEDIASTINUM:


Trachea is central in position.

Cardiac silhouette is of normal size and configuration.

No evidence of pericardial effusion.

No significant lymphadenopathy is seen.

Visualized skeleton is normal.

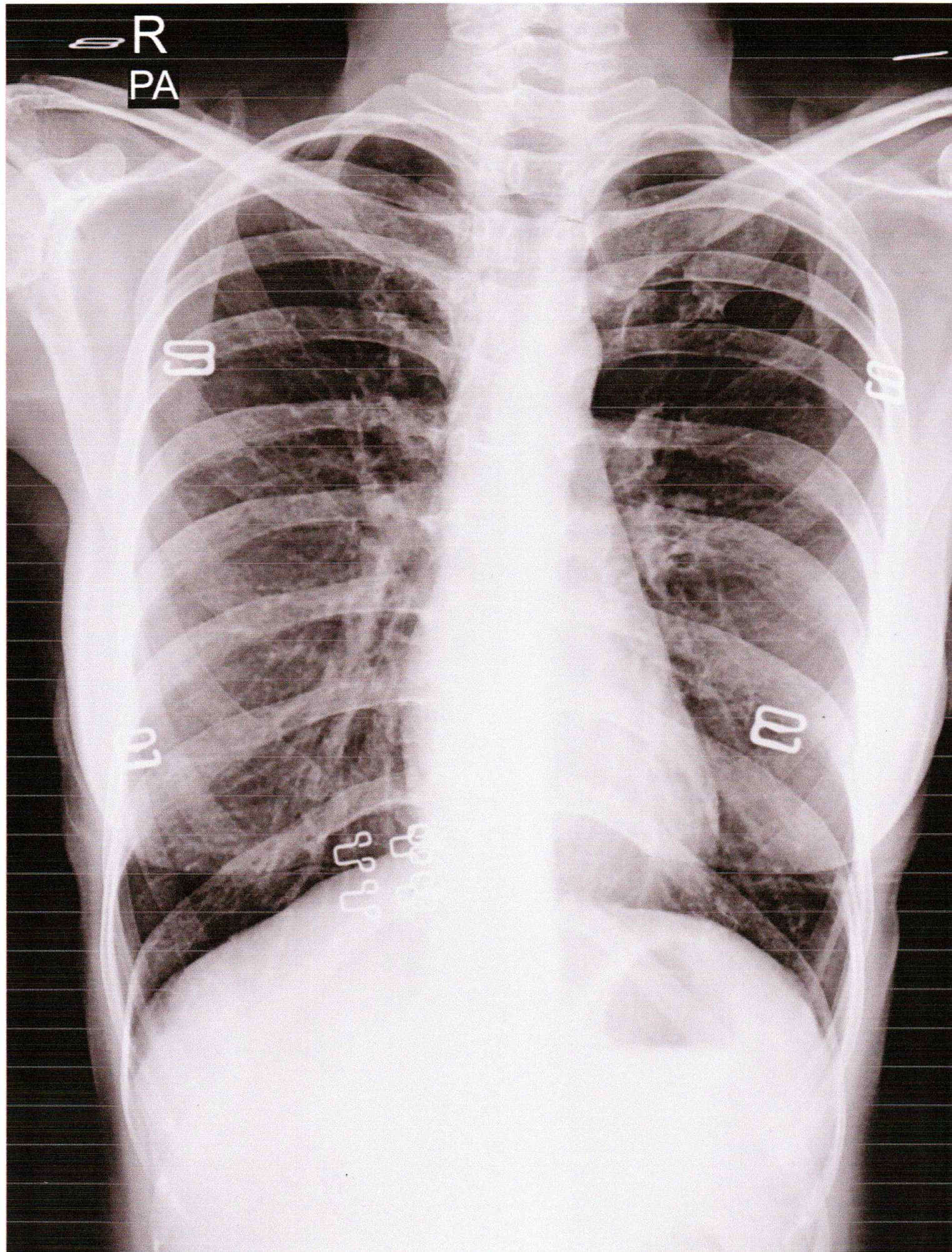

Radiologist

Address : Kabir Nagar (Near Sanjay Shiksha Niketan), Durgakund, Varanasi

Mobile : 9554572190 / 9453837595 / Recpn. 9389994334

E-mail : dramishra@gmail.com, drpallaviojha@gmail.com, **Website:** www.piire.org

R
PA



ANURADHA KUMARI 28YF 3419 O CHEST P.A. 26-Jan-23 11:27 AM

PANACEA HOSPITAL, KABIR NAGAR, DURGAKUND, VARANASI