



PARKLINE DIAGNOSTICS PVT. LTD.

L.G. 3, 4 & 5, Bhuvana Towers, S.D. Road, Secunderabad - 500 003.

Tel : +91 40-2784 5852, 6649 1787, 7995421787, 7093445852, Fax : +91 40 2784 7864

Email parklinediagnostics@gmail.com www.parklinediagnostics.com



NABL Accredited
Certificate No.MC-2566

MEDICAL EXAMINATION REPORT

Name	Mr. Sharma Chandar shekhar		Date :	12/01/2022		
Company	Clo: Mediwheel		Reg. No. :	1668703		
Contact No.	9701518401		Sex	<input checked="" type="checkbox"/> M <input type="checkbox"/> F	Age :	<input type="checkbox"/> 50
Type	Pre-Emp		Emp. No.:	96311		
	Overseas		Height	170 cm		
	Annual	<input checked="" type="checkbox"/>	Weight	86 kgs		
Remarks	<p><u>X-ray chest</u> : Pleural effusion ^{thickening} + lamellae effusion of (R) lung.</p> <p>- Raised ESR. Advised for RTPCR.</p> <p>- Pre-diabetic state. Advised for life style modification & diet restrictions.</p> <p style="text-align: right;">DR. PRIYANKA SANNIDHI M.B.B.S Regn. No: 11351</p>					
Fitness Status	Medically Fit / Unfit		Physician's Signature			

COMPREHENSIVE MEDICAL EXAMINATION REPORT

NAME Mr. Shaama Chandar Shekhar

AGE 50yrs / male

MARITAL STATUS married CHILDREN : M 1 F 1

IDENTIFICATION (IF ANY) A mole on the (R) hand (palm).

PAST HISTORY

Any family H/o : High Blood Pressure, Heart Disease, Tuberculosis, Diabetes, Asthma, Cancer

Late Father CVA

Any personal H/o Major illness like : Typhoid.....NIL.....Jaundice.....1994.....Etc.

Any H/o STD.....NIL.....Skin infection.....NIL

H/o Blood Transfusion.....NIL.....Recent Vaccination.....COVISHIELD 2 doses ✓

H/o Epilepsy.....NIL.....Giddiness.....NIL

H/o Surgery.....Small sub pleura Fracture in the past.....NIL

Any Personal H/O. infra scapular region 2017.

High Blood Pressure, Heart Disease Tuberculosis, Diabetes, Asthma, Cancer

Drug Abuse, Drug Allergy, Micturition, Bowels, Alcohol, Smoking, Sleep, MC, Wt. Loss/Wt. Gain

Present illness / Medication - Nil particular -

GENERAL EXAMINATION

Conjunctiva :
Skin :
Ears :
Nose :
Throat & Oral Cavity :

NBD

Bone, Joints : N
Nutritional Status : well Nourished.
Lymph Nodes : NPD
Edema Feet : NIL
Varicose Veins : NIL

Distant Vision : Near Vision :

Right Eye: 6/6

With glasses / Without glasses

left Eye: 6/6

with glasses / without glasses

Colour Vision: Normal

Right Ear

Hearing :

(N)

Rinee's Test ;

Weber Test :

Discharge :

NIL

Right Eye: R10 +2.00 sph N6

With glasses / Without glasses

left Eye: R10 +2.00 sph N6

with glasses / without glasses

Ophthalmologist's Signature

DR. KATTA
(M.D.O., F.R.F.
REGD. O.P.H.THALM.
(AMC)

Left Ear

(N)

NIL

SYSTEMIC EXAMINATION

Pulse : 80 bpm

B.P. : 130/90 mmHg

Lungs : A. Shape of Chest B/C symmetrical
B. Breath Sounds etc-clear (+)
C. Adventitious Sounds No

Heart : A. Sounds S1, S2 (+)
B. Murmurs No murmurs

Nervous System

Abdomen : A. Liver NP
B. Spleen NP
C. Piles No
D. Any Lump No

A. Higher Function :
B. Cranial Nerves :
C. Sensory System :
D. Motor System :
E. Jerks :

NAD

General : A. Hernia
B. Hydrocele
C. Varicocele

NAD

Breast : Rt _____ Lt. _____

CANDIDATE'S DECLARATION

I hereby solemnly declare that I am not suffering from Asthma, Hypertension, Diabetes, Occult Psychological disorders or any other ailment which can be suppressed without my voluntary declaration.

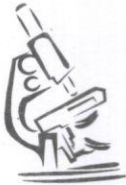Date : 12 Jan 2022

Place : Secunderabad

Signature

C. J. Anthon

Note : General Physical Examination and Investigation included in the health check-up Have certain limitations and may not be able to detect all latent and asymptomatic diseases. Any new symptoms developing after the health check-up or persisting thereafter should be brought to the attention of the treating physician.



PARKLINE DIAGNOSTICS PVT. LTD.

L.G. 3, 4 & 5, Bhuvana Towers, S.D. Road, Secunderabad - 500 003. Tel : +91 40-2784 5852, 6649 1787, 7995421787, 7093445852, Fax : +91 40 2784 7864 Email parklinediagnostics@gmail.com www.parklinediagnostics.com



NABL Accredited Certificate No.MC-2566

ENT CONSULTATION

S.No. 1668703

Emp.No.

Date 12/01/2021

Name Mr. Sharma Chandar Age 50 Yrs
Shekhar

Sex M/F

EARS : Right Left

EAC : patent, no Cerumen. Intact, pearly white. - do - do -

TM : Cone of light (+)

TFT : Rinne's +ve Weber's - central

NOSE : Septum Devs to (L). Bil. T's & meatus (N). Proc - @ non dev

THROAT : Oropharynx (N) - Bil. v. csg (N) moving bil. Alveolarly

NECK : (N)

IMPRESSION: Euvl to Devs to (L).

Dr. D. Hari Krishna Reddy
MS (ENT)
Head & Neck Surgeon
Reg. No: 88379

Name : Sharma chandra Sex : M Age : 50


Date : 12/1/22

OPD No : 381

U/L scaling done
Staine ++
Cal ++

1) *Rexidine Mouth Wash. [once daily].*

2) *Stolin Gum paint.*
[Before sleep].


MULTI SPECIALITY DENTAL CLINIC
Smile Confidently... Not Confidentially...
B.D.S, IMPLANTOLOGIST (USA)
1-3-1, Rajamudalliar Street, Kalasiguda,
Secunderabad, Cell : 8977910590.



PARKLINE DIAGNOSTICS PVT. LTD.

L.G. 3, 4 & 5, Bhuvana Towers, Sarojini Devi Road, Secunderabad - 500 003 Tel. +91 40-2784 5852
6649 1787 Fax : +91 40 2784 7864 Email : parklinediagnostics@gmail.com www.parklinediagnostics.com



NABL Accredited
Certificate No. MC-2566

TEST REPORT

Name : Mr . SHARMA CHANDAR SHEKHAR [96311]
Age / Gender : 50 Years / Male
Ref.By : Medi Wheel
Req. No : BIL1668703

TID : UMR0661206
Registered on : 12-Jan-2022 09:14 AM
Reported On : 12-Jan-2022 10:15 AM

DEPARTMENT OF ULTRASOUND Ultrasound Whole Abdomen

LIVER : Normal in size and increased echotexture. No focal lesions.
No IHBD /CBD dilatation. Portal vein is normal.

SPLEEN : Normal in size and echotexture. No focal lesion seen.

GALL BLADDER : Well distended. No sludge / gall stones / sol.
Gall bladder - Wall thickness is normal.
No pericholecystic oedema.

PANCREAS : Normal in size and echotexture.No calcification / sol.
Pancreatic duct is normal. No peripancreatic fluid collection.

RIGHT KIDNEY : 10.0 x 4.7 cms.
Normal in size and echotexture.
Cortical thickness is normal.
No evidence of calculi / sol.
Pelvi calyceal system is normal.

LEFT KIDNEY : 9.9 x 4.8 cms.
Normal in size and echotexture.
Cortical thickness is normal.
No evidence of calculi / sol.
Pelvi calyceal system is normal.

URINARY BLADDER : Well distended.Normal in contour.
Wall thickness is normal. No calculus / sol.

PROSTATE : Measuring 2.9 x 2.3 x 2.8 cms (Vol: 10.3 cc). Normal in size and echotexture.
No calcification / sol.
No pre or para aortic adenopathy / ascites noted.

IMPRESSION : Grade I fatty liver.

Clinical correlation

Dr. D.J. MOHAN
MD DMRD
(Reg No. 8995)
Consultant Radiologist

The Test marked with*are not accredited by NABL

Lab Timings (Weekdays) : 7.00 am to 8.30 pm
Sundays & Holidays : 7.00 am to 1.00 pm

Radiologists Timings (Weekdays) : 7.30 am to 1.30 pm
& 5.30 pm to 7.45 pm
Sundays & Holidays : 7.30 am to 9.30 am




PARKLINE DIAGNOSTICS PVT. LTD.

L.G. 3, 4 & 5, Bhuvana Towers, Sarojini Devi Road, Secunderabad - 500 003 Tel. +91 40-2784 5852
6649 1787 Fax :+91 40 2784 7864 Email : parklinediagnostics@gmail.com www.parklinediagnostics.com



NABL Accredited
Certificate No. MC-2566

TEST REPORT

Name : MR.SHARMA CHANDAR SHEKHAR [96311] TID/SID : UMR0661206/
Age / Gender : 50 Years / Male Registered on : 12-Jan-2022 / 09:14 AM
Ref.By : - Collected on : 12-Jan-2022 / 09:14 AM
Req.No :  Reported on : 12-Jan-2022 / 09:47 AM
BIL1668703 Reference : Medi Wheel


DEPARTMENT OF CARDIOLOGY

2D Echo/Doppler Study

Mitral Valve	Normal
Aortic valve	Normal
Tricuspid valve	Normal
Pulmonary valve	Normal
Aorta	2.5 cm
Left Atrium	3.9 cm
Left Ventricle	LVdD: 4.6 cm IVSd : 1.1 cm EF: 67 % LVDs: 2.9 cm LVPwd: 1.3 cm FS: 37 %
RWMA	Nil
Right Atrium	Normal
Right Ventricle	Normal
Pulmonary Artery	Normal
IAS	Intact
IVS	Intact
Pericardium	Normal
Svc / Ivc	Normal
Intracardiac Masses	Nil
Doppler Study	Mitral flow: E > A Aortic flow : 1.0 m/sec Pulmonary flow : 1.0 m/sec
Colour Doppler	No MR / AR / TR / PR
Conclusion	No RWMA. Normal valves/ Normal chambers. No MR/ AR/ TR / PR Good LV/ RV function. No PE/ clot/ vegetation.

* Sample processed at Parkline

--- End Of Report ---


Dr. NAVEEN KUMAR .C
M.D., D.M.
Consultant Cardiologist
Reg. No. 52291

The Test marked with*are not accredited by NABL

Lab Timings (Weekdays) : 7.00 am to 8.30 pm
Sundays & Holidays : 7.00 am to 1.00 pm

Radiologists Timings (Weekdays) : 7.30 am to 1.30 pm
& 5.30 pm to 7.45 pm
Sundays & Holidays : 7.30 am to 9.30 am

Free Home Visit for Sample Collection.

Call : 7995421787, 7093445852, 8121147282, 9885202212



PARKLINE DIAGNOSTICS PVT. LTD.

L.G. 3, 4 & 5, Bhuvana Towers, Sarojini Devi Road, Secunderabad - 500 003 Tel. +91 40-2784 5852
6649 1787 Fax :+91 40 2784 7864 Email : parklinediagnostics@gmail.com www.parklinediagnostics.com



NABL Accredited
Certificate No. MC-2566

TEST REPORT

Name : Mr . SHARMA CHANDAR SHEKHAR [96311]
Age / Gender : 50 Years / Male
Ref.By : Medi Wheel
Req. No : BIL1668703

TID : UMR0661206
Registered on : 12-Jan-2022 09:14 AM
Reported On : 12-Jan-2022 10:34 AM

DEPARTMENT OF X-RAY X-Ray Chest PA View

Lung fields are clear.

Linear opacity lateral aspect of left chest with blunt CP angle.

Cardiac thoracic ratio is normal.

Hila are normal.

Bony cage is normal.

IMPRESSION : Pleura thickening / Lamellar effusion on left.

Clinical correlation.

Dr. D.J. MOHAN
MD DMRD
(Reg No. 8995)
Consultant Radiologist

The Test marked with*are not accredited by NABL

Lab Timings (Weekdays) : 7.00 am to 8.30 pm
Sundays & Holidays : 7.00 am to 1.00 pm

Radiologists Timings (Weekdays) : 7.30 am to 1.30 pm
& 5.30 pm to 7.45 pm
Sundays & Holidays : 7.30 am to 9.30 am

ID: 1668703 12-01-2022 09:35:01 AM
MR.SHARMA CHANDAR SHEKHAR
Female 50Years

CARDIART

HR : 86 bpm
P : 112 ms
PR : 168 ms
QRS : 70 ms
QT/QTc : 335/403 ms
P/QRS/T : 35/31/18 °
RV5/SV1 : 1.224/0.728 mV

NSR
WNL
CS

Dr. NAVEEN KUMAR .C
M.D., D.M.
Consultant Cardiologist
Reg. No. 52291

Diagnosis Information:
Sinus Rhythm
Normal ECG

Report Confirmed by: