

Standard 0.5-320  
 I II III  
 STNC

aVR aVL aVF  
 STNC

V1 V2 V3  
 STNC

V4 V5 V6  
 STNC

391 M  
 30/13/23

391 M

HR : 75 bpm  
 R-R : 792 ms  
 P-R : 154 ms  
 QRS : 90 ms  
 QT/QTc : 345/387 ms  
 P/QRS/T : 69/60/36  
 RV5/SV1 : 1.51/0.759 mV  
 RV5-SV1 : 2.260 mV

Sex :  
 ID : 0226  
 Name :  
 Unconfirmed report Verified by:

Dr. Krish P. Varadachari  
 MD, PGCC  
 Associate Consultant-Cardiology  
 Reg.No.G-50510  
 Heart and Disease  
 Vadodra

# Heart & General Clinic

Icure Heart & Diet Clinic, 402, Epsilon tower, opp Pasha bhai park, Race course, Vadodara

## :: PERSONAL HEALTH REPORT ::

Vivek Acharya		*DATE 30/3/23
		SR. NO. SEX. male AGE 39 <sup>yes</sup> HEIGHT 165 cm WEIGHT 77 kg

### HISTORY

Present History : NO  
 Past Illness History : NO Diabetes/Hypertension/Tuberculosis/Asthma/Epilepsy  
 Past Occupational History : NO  
 Family History : Father - Diabetic, mother HT  
 Personal History : NO  
 Addiction : NO Tobacco/Gutkha/Smoking/Alcohol

### GENERAL EXAMINATION

T.P.R. : 75/min B.P. : 122/80 mm Hg :  
 Pallor/Icterus/Cyanosis/Varicosity/Lymph Nodes/Thyroid/Oedema/NVE/Other :

### SYSTEMIC EXAMINATION

R.S. : MAD  
 C.V.S. : MAD  
 C.N.S. : MAD  
 A.S. : MAD  
 Musculo-skelet System : MAD



E.N.T. Ex. MAD	ACUITY OF VISION			
	Without Glass	DISTANT	RT EYE 2 6/	LT EYE 2 6/
Dental Ex. MAD		Near	6/	6/
Skin Ex. MAD	With Glass	DISTANT	6/ 6	6/ 6
		Near	6/ 6	6/ 6
Psychic Ex. MAD	COLOUR BLINDNESS MAD			

### REMARK

### ADVICE

The Worker is FIT/UNFIT for the assigned job.

Dr. Krish P. Vaidya  
 MD, PGDCC  
 Associate Consultant - Cardiology  
 Reg. No. G-50510  
 DR. KRISH VAIDYA

MD G-50510, CIH



ભારતીય વિશિષ્ટ ઓળખાણ પ્રાધિકરણ

ભારત સરકાર  
Unique Identification Authority of India  
Government of India

નોંધણીની ઓળખ / Enrollment No.: 1104/60605/49541

To  
આચાર્ય વિવેક  
Acharya Vivek  
S/O: Acharya Ashok  
E/15 kabir complex  
opp don bosco school makarpura road  
Vadodara  
Ongc Col  
Vadodara Vadodara  
Gujarat 390009  
9638507522

31/03/2013

7319655



MN073196555FT



તમારો આધાર નંબર / Your Aadhaar No. :

**9432 7949 7340**

આધાર - સામાન્ય માણસનો અધિકાર



ભારત સરકાર

Government of India



આચાર્ય વિવેક  
Acharya Vivek  
જન્મનું વર્ષ / Year of Birth : 1983  
પુરુષ / Male




**9432 7949 7340**

આધાર - સામાન્ય માણસનો અધિકાર




4/19  
18/2


 **બંક ઓફ બરોડા**  
**Bank of Baroda**

**જનમ સમીક્ષા**  
**Janam Samiksha**

સંખ્યા  
સંબંધિત શાખા નં.  
સ.ક. કો.  
સંબંધિત સંસ્થા  
Issuing Authority

84841

  
સહાયક મેનેજર  
Assistant Manager





# BARODA DIAGNOSTIC LABORATORY



Patient's name : Vivek Acharya  
Age/Sex : 39 Years/Male  
Referred by : C/o. I Cure Heart & Diet Clinic  
Sample From : Received from I cure Heart & Diet Clinic  
UHID :

Reg. ID : icure-953-19  
Accession : 28588  
Reg. Date : 30/03/2023  
Collection Time : 30/03/2023 13:56

## COMPLETE BLOOD COUNT

Sample Type: EDTA

Test Name	Result	Units	Biological Reference Interval
<b>Blood Counts</b>			
Haemoglobin :	13.5	Gms%	13.5 - 18.0
Total R.B.C. :	<b>4.41</b>	mill/c.mm	4.7 - 6.0
Total W. B. C. :	7200	/cu mm	4000 - 10500
Platelet Count :	295000	/cu.mm	1,50,000 - 4,50,000
<b>Differential Count</b>			
Neutrophils :	65	%	40 - 70
Lymphocytes :	32	%	20 - 40
Eosinophils :	01	%	1 - 4
Monocytes :	02	%	2 - 6
Basophils :	00	%	0 - 01
<b>Blood Indices</b>			
P. C. V :	<b>37.1</b>	%	42 - 52
M. C. V. :	84.1	fl	78 - 100
M.C.H :	30.6	pg	27 - 31
M. C. H. C :	<b>36.4</b>	%	32 - 36
R.D.W :	11.9	%	11.5 - 14.0

### E.S.R.( Westergren Method )

After one hour : 06 mm 1 - 7



*Dr Harsh Pandya*  
(MD)  
Consultant Pathologist  
Reg. No.: G-32582

*Dr. Priya Kriplani*  
(MD)  
Consultant Pathologist  
Reg. No.: G-46004





# BARODA DIAGNOSTIC LABORATORY



\* 2 8 5 8 8 \*

Patient's name : Vivek Acharya  
Age/Sex : 39 Years/Male  
Referred by : C/o. I Cure Heart & Diet Clinic  
Sample From : Received from Icure Heart & Diet Clinic  
UHID :  
Reg. ID : icure-953-19  
Accession : 28588  
Reg. Date : 30/03/2023  
Collection Time : 30/03/2023 13:56

## HbA1C REPORT

Sample Type: EDTA

Test Name	Result	Units	Biological Reference Interval
HbA1C :	5.31	%	Excellent control: 4.2-6.2 Good Control : 6.3-7.2 Fair Control : 7.3-8.2 Poor Control : >8.3
Mean Blood Glucose levels : of last 03months	106.0	mg/dl	

### NOTE

\*As per the new 2009 update of American Diabetes Association regarding HbA1C & Mean Blood Glucose relationship.

This test is used to monitor diabetic patients compliance with the therapeutic regimen and long term blood glucose control. It's level is proportional to both the average blood glucose concentration and the life span of the red blood cells (RBC) in circulation. HbA1c values are free of day to day glucose fluctuations and are unaffected by exercise or recent food intake.

Received from Icure Heart & Diet Clinic  
LAB USE ONLY (Entered by : OP1 Enter Date/Time:30/03/2023 3:18:00 PM) (Verify by : OP1 Verify Date/Time:30/03/2023 3:18:00 PM)

BARODA DIAGNOSTIC LABORATORY



**Dr Harsh Pandya**  
(MD)  
Consultant Pathologist  
Reg. No.: G-32582

**Dr. Priya Kriplani**  
(MD)  
Consultant Pathologist  
Reg. No.: G-46004

302, Trivia Complex, Natubhai Circle, Race Course, Vadodara. ☎: +91 88660 09950 / 74050 09950 ✉: bdl95950@gmail.com

Laboratory results serve as an aid to diagnosis & should be interpreted in relation to clinical findings. Please refer back to laboratory in case of any discrepancy.



Scanned with OKEN Scanner



# BARODA DIAGNOSTIC LABORATORY



Patient's name : Vivek Acharya  
Age/Sex : 39 Years/Male  
Referred by : C/o. I Cure Heart & Diet Clinic  
Sample From : Received from I cure Heart & Diet Clinic  
UHID :  
Reg. ID : icure-953-19  
Accession : 28588  
Reg. Date : 30/03/2023  
Collection Time : 30/03/2023 13:56

## THYROID FUNCTION

Sample Type: Serum

Test Name	Result	Units	Biological Reference Interval
TOTAL T3 :	1.99	ng/ml	0.84 - 2.0
TOTAL T4 :	9.01	ug/dl	5.1 - 14.0
TSH :	2.91	mIU/L	0.25 - 5.0

Method : CLIA

## RENAL FUNCTION TEST

Test Name	Result	Units	Biological Reference Interval
Urea :	25	mg/dl	10 - 50
Bun (Calculated) :	11.7	mg/dl	0 - 18
Creatinine :	0.99	mg/dl	0.4 - 1.5
Uricacid :	4.35	mg/dl	3.4 - 7.0
BUN CREAT RATIO :			10:1 - 20:1

Done on Fully automated biochemistry analyser - COBAS C 111

Received from I cure Heart & Diet Clinic  
LAB USE ONLY (Entered by :OP1 Enter Date/Time:30/03/2023 3:10:00 PM)



Dr. Harsh Pandya

(MD)  
Consultant Pathologist  
Reg. No.: G-32582

Dr. Priya Kriplani

(MD)  
Consultant Pathologist  
Reg. No.: G-46004

302, Trivia Complex, Natubhai Circle, Race Course, Vadodara. ☎: +91 88660 09950 / 74050 09950 ✉: bdl95950@gmail.com

Laboratory results serve as an aid to diagnosis & should be interpreted in relation to clinical findings. Please refer back to laboratory in case of any discrepancy.



Scanned with OKEN Scanner



# BARODA DIAGNOSTIC LABORATORY



\* 2 8 5 8 8 \*

Patient's name : Vivek Acharya  
Age/Sex : 39 Years/Male  
Referred by : C/o. I Cure Heart & Diet Clinic  
Sample From : Received from I cure Heart & Diet Clinic  
UHID :

Reg. ID : icure-953-19  
Accession : 28588  
Reg. Date : 30/03/2023  
Collection Time : 30/03/2023 13:56

## LIVER FUNCTION TEST

Sample Type: Serum

Test Name	Result	Units	Biological Reference Interval
S.G.P.T (ALT) :	11	U/L	0 - 40
S.G.O.T (AST) :	18	U/L	0 - 37
ALK.PHOSPHATASE :	52	U/L	40 - 130
G.G.T :	12.8	U/L	8 - 78
<b><u>Bilirubin</u></b>			
Total :	0.38	mg/dl	0.2 - 1.0
Direct :	0.18	mg/dl	0 - 0.6
Indirect :	0.20	mg/dl	0 - 0.5
<b><u>Serum Proteins</u></b>			
Total Protein :	6.99	gms/dl	6.4 - 8.3
Albumin :	4.01	gms/dl	3.8 - 4.4
Globulins :	2.98	gms/dl	2.3 - 3.5
A/G Ratio :	1.35		0.9 - 2.9

Done on Fully automated biochemistry analyser - COBAS C 111

Received from I cure Heart & Diet Clinic

LAB USE ONLY (Entered by :OP1 Enter Date/Time:30/03/2023 3:18:00 PM) (Verify by :OP1 Verify Date/Time:30/03/2023 3:37:00 PM)



**Dr Harsh Pandya**  
(MD)  
Consultant Pathologist  
Reg. No.: G-32582

**Dr. Priya Kriplani**  
(MD)  
Consultant Pathologist  
Reg. No.: G-46004

*Dr. Priya Kriplani*

302, Trivia Complex, Natubhai Circle, Race Course, Vadodara. ☎ : +91 88660 09950 / 74050 09950 ✉ : bdl95950@gmail.com

Laboratory results serve as an aid to diagnosis & should be interpreted in relation to clinical findings. Please refer back to laboratory in case of any discrepancy.



Scanned with OKEN Scanner





# BARODA DIAGNOSTIC LABORATORY



\* 2 8 5 8 7 \*

Patient's name : Vivek Acharya  
Age/Sex : 39 Years/Male  
Referred by : C/o. I Cure Heart & Diet Clinic  
Sample From : Received from I cure Heart & Diet Clinic  
UHID :  
Reg. ID : icure-952-19  
Accession : 28587  
Reg. Date : 30/03/2023  
Collection Time : 30/03/2023 13:54

## LIPID PROFILE

Sample Type: Serum

Test Name	Result	Units	Biological Reference Interval
Cholesterol :	<u>218</u>	mg/dl	0 - 200
Triglyceride :	<u>232</u>	mg/dL	0 - 150
HDL - Cholesterol :	44	mg/dL	35 - 65
LDL - Cholesterol :	123	mg/dL	0 - 130
VLDL - Cholesterol :	<u>46.4</u>	mg/dL	0 - 30
Total Cholesterol/HDL Ratio :	4.95		1 - 6
LDL / HDL Cholesterol Ratio :	2.80		0 - 3.5

Done on Fully automated biochemistry analyser - COBAS C 111

*Dr. Priya Kriplani*

Received from I cure Heart & Diet Clinic

LAB USE ONLY (Entered by : OP1 Enter Date/Time:30/03/2023 3:16:00 PM) (Verify by : OP1 Verify Date/Time:30/03/2023 3:16:00 PM)

BARODA DIAGNOSTIC LABORATORY



**Dr Harsh Pandya**  
(MD)  
Consultant Pathologist  
Reg. No.: G-32582

**Dr. Priya Kriplani**  
(MD)  
Consultant Pathologist  
Reg. No.: G-46004

302, Trivia Complex, Natubhai Circle, Race Course, Vadodara. ☎: +91 88660 09950 / 74050 09950 ✉: bdl95950@gmail.com

Laboratory results serve as an aid to diagnosis & should be interpreted in relation to clinical findings. Please refer back to laboratory in case of any discrepancy.



Scanned with OKEN Scanner

  
**Heart & General Clinic**

**iCure Heart& Diet Clinic, 402, Epsil on tower, opp Pasha bhai park, Race course, Vadodara**

**Name** : VIVEK ACHARYA  
**Ref By** : ICURE HEART & DIET CLINIC

**Age/Sex** : 39 Yrs./M  
**Date** : 30/03/2023  
**Report ID.** : 1

**HAEMOGRAM PROFILE**

<u>TEST</u>	<u>RESULT</u>
Blood Group	: * O *
Rh Factor (Anti D.)	: * POSITIVE *

**BIOCHEMISTRY**

**FASTING (FBS)**

Blood Glucose : 98.0 mg/dL 70 - 110 mg/dL

**POST-PRANDIAL**

Blood Glucose : 138.0 mg/dL 80 - 140 mg/dL

*Done By Fully Auto Analyzer MIURA, A-1004*



END OF REPORT



  
**Heart & General Clinic**


iCure Heart& Diet Clinic, 402, Epsil on tower, opp Pasha bhai park, Race course, Vadodara

**Name** : VIVEK ACHARYA  
**Ref By** : ICURE HEART & DIET CLINIC

**Age/Sex** : 39 Yrs./M  
**Date** : 30/03/2023  
**Report ID.** : 1

**EXAMINATION OF URINE**

<u>TEST</u>	<u>RESULT</u>	<u>UNIT</u>
Sample	: FASTING	
<b><u>PHYSICAL EXAMINATION</u></b>		
Quantity	: 10	mL
Colour	: PALE YELLOW	
Transperancy	: CLEAR	
Specific Gravity	: 1.030	
Reaction	: ACIDIC	
Deposits	: ABSENT	
<b><u>CHEMICAL EXAMINATION</u></b>		
Albumin	: NIL	
Sugar	: NIL	
Acetone	: ABSENT	
Bile Salts	: ABSENT	
Bile Pigments	: ABSENT	
Urobilinogen	: NORMAL : ~ < 1.0 mg/dL	
Occult Blood	: ABSENT	
Nitrate	: ABSENT	
<b><u>MICROSCOPIC EXAMINATION</u></b>		
Pus Cells	: 0-1 / hpf	
RBC	: NIL	
Epithelial Cells	: NIL	
Crystals	: NIL	
Amorphous Phosphate	: NIL	
Cast	: NIL	



END OF REPORT

  
**Heart & General Clinic**

**2D Echocardiography & Color Doppler Report**

iCure Hear care, 402, Epsilon tower, opp Pasha bhai park, Race course, Vadodara

**Patient Name: Mr Vivek Acharya**

**Dates: 30 / 03 / 2023**

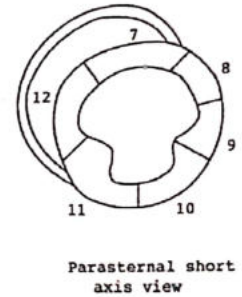
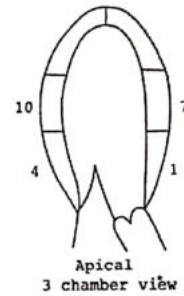
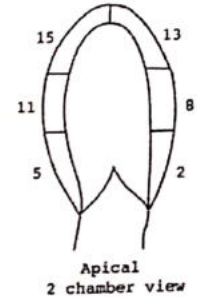
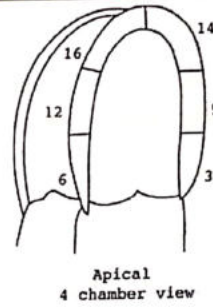
**Age Gender: male - 39 Years**

**M. Mode Study:**

<b>LA</b>	<b>36</b>	<b>IVS</b>	<b>10</b>	<b>PWD</b>	<b>10</b>
<b>AO</b>	<b>25</b>	<b>LVDs</b>	<b>26</b>	<b>LVDd</b>	<b>48</b>

**Doppler Study:**

<b>Mitral Valve</b>	<b>E: 0.85 A: 0.62</b>
<b>Aortic Valve</b>	<b>Normal</b>
<b>Tricuspid Valve</b>	<b>Normal</b>
<b>Pulmonary Valve</b>	<b>Normal</b>



**Conclusion:**

- **Normal LV Systolic function**
- **LVEF: 60 % ,No RWMA**
- **Cardiac Chambers: Normal**
- **Diastolic function: Normal**
- **TR: No PAH: No RVSP: 15mmhg**
- **No Ms , No MR**
- **No AR , No AS**
- **ASD/VSD/PDA/Co-A : No**
- **No Clots or vegetations found**
- **IVC: 09mm size with Normally collapsive**



**Dr. Krish P. Vaidya**  
 MD, PCC  
 Associate Consultant-Cardiology  
 Reg.No.G-50510

**Dr. Krish P Vaidya**  
 Consultant Cardiologist, Diabetologist  
 & General Physician

**Note:**

Normal 2D echo report does not rule out cardiac diseases  
 this report shall not be used for Medico legal purposes,  
 Clinical Correlation advisable.

  
**Heart & General Clinic**

NAME : Mr Vivek Acharya	AGE : 39Y/M	DATE : 30/03/2023
-------------------------	-------------	-------------------

**ULTRASONOGRAPHY OF WHOLE ABDOMEN**  
(Screening Only)

**Liver** is normal in size and echotexture and shows normal parenchymal reflectivity. No focal lesion is seen. Hepatic veins appear normal. There is no evidence of any dilated intra hepatic biliary radicals.

**Portal Vein** appears normal in diameter.

**Common Bile Duct** is of normal diameter.

**Gallbladder** is physiologically distended with normal wall thickness. There is no evidence of gallstones. No evidence of peri-cholecystic fluid or probe tenderness.

**Pancreas** is normal in size and shows homogenous reflectivity. There is no evidence of any calcification or ductal dilatation.

**Spleen** is normal size and shows a homogenous echotexture. There is no evidence of any focal lesion.

**Both Kidneys** are normal in position and size. They show normal cortical reflectivity and cortico-medullary distinction. Right kidney measures 92x35mm. Left kidney measures 98x42mm. There is no evidence of calculi, hydronephrosis or mass seen.

**Bladder** is well distended and shows normal wall thickness. No evidence of intra-luminal mass or calculi.

**Prostate gland** is normal in size . it has smooth outlines and normal reflectivity

There is no evidence of ascites.

No evidence of any gross bowel mass seen.

No evidence of any aorto-caval or mesenteric root lymphadenopathy.

No mass or collection in right iliac fossa.

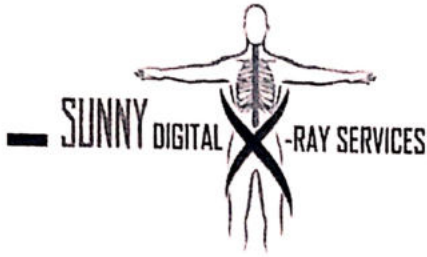Conclusion : No Sonographic abnormality seen.



*Mehul Prajapati*  
**DR. MEHUL PRAJAPATI**  
CONSULTANT RADIOLOGIST

 **icure™**  
**Heart & General Clinic**

iCure Heart& Diet Clinic, 402, Epsil on tower, opp Pasha bhai park, Race course, Vadodara



Sunny K. Machhi  
+91 87585 30074  
+91 83205 61551  
sunnydigitalxray@yahoo.com

<b>NAME</b>	VIVEK ACHARYA	<b>AGE/SEX</b>	39/MALE
<b>REF BY</b>	ICURE HEART & DIET CLINIC	<b>DATE</b>	30-03-2023

**X-RAY CHEST PA VIEW**

BOTH LUNG FIELDS ARE NORMAL.

BOTH COSTOPHRENIC RECESS ARE CLEAR.

CARDIAC CONFIGURATION IS NORMAL.

MEDIASTINUM AND BONY THORACIC CAGE REVEAL NO ABNORMALITY.

**IMPRESSION : NORMAL LUNGS HEART AND MEDIASTINUM**

**DR.HIMANI VIRAPARA**  
**Regn. No: G.28771**  
**M.D. [Radiodiagnosis]**  
**(CONSULTANT RADIOLOGIST)**

