

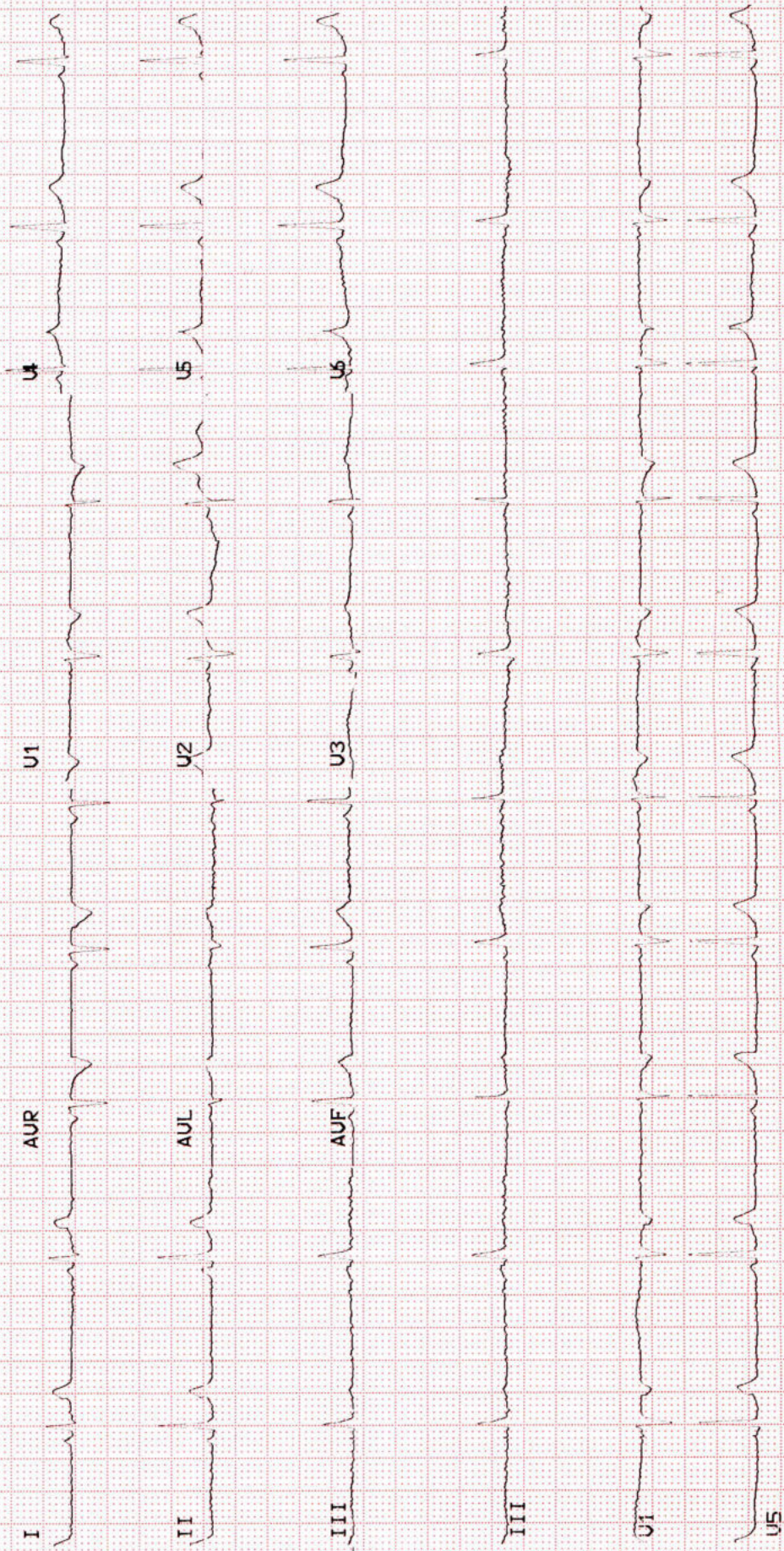
Dr. Vishal K Singh
 25/3/23
 60 bpm



Interpretation:
 short PR interval
 probably normal ECG

QRS	84 ms	< P
QT/QTcB	374 / 381 ms	< T
PR	104 ms	< QRS
P	78 ms	aVL
RR/PP	976 / 980 ms	0 I
P/QRS/T	55 / 65 / 40 degrees	III +90 II
QTD/QTcBD	40 / 40 ms	aVF
Sokolow	1.4 mV	
NK	8	

Inconformed report





Metro Hospital & Heart Institute

(A unit of Sunhill Hospital Private Limited)

OPD CONSULTATION

Patient Name Ms. Vishakha Singh Age/Sex 25/F Reg. No. _____

Doctor's Name Dr. Sushil

Date 25/08/23 Time _____

OPHTHALMIC EXAMINATION

VISION

DISTANCE VISION-

Rt 6/6
Lt 6/6

NEAR VISION-

Rt N/6
Lt N/6

COLOUR VISION

Normal

EYE EXAMINATION

Cornea


Ant Chamber

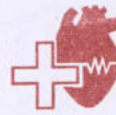Pupil

Fundus Examination

W.N.C

ADVICE-





METRO

HOSPITAL & HEART INSTITUTE

(A unit of Sunhill Hospitals Private Limited)

(NABH & ISO 9001: 2008 Certified)

Radiology Investigation Report

Name	: Ms. Vishakha Singh	Age/Sex	: 25 Y/F
Ref. By	: Dr. ANIL SINGH	UHID NO	: 2023005105
IP/OP	: OP/202230520	Request No	: 70223694
Date	: 25/03/2023		

USG WHOLE ABDOMEN

The diaphragm is normal in contour & respiratory excursion. There is no ascitis or lymph node mass.

Liver is normal in shape, outline & echotexture. No focal lesion of abnormal ecogenecity is seen. Intrahepat biliary radicles are not dilated. Portal vein & portal venous radicles are normal.

Gall bladder is well distended, its outlines are smooth & its wall are not thick. No calculus /mass lesion is seen in its lumen. Common bile duct is normal in course & caliber. No calculus is seen in its lumen.

Spleen & pancreas appears normal in shape, size, outline & echotexture.

Both the kidneys are normal in shape, size, outline & echotexture. Renal parenchymal thickness is normal. Corticomedullary junction is defined & is normal. There is no hydronephrosis. **There is left renal concretion.**

Urinary bladder is normal in contour & capacity. Bladder wall is not thick. No pathological filling defect / vesical calculus is seen in bladder. Ureterovesical junctions appear normal.

Uterus is normal in size shape, outline & echotexture. Myometrial & endometrial echoes are normal. No uterin mass is seen. Both the ovaries appear normal. There is no free fluid seen in cul de sac.

IMPRESSION : Left renal concretion.



DR. PRAKASH CHANDRA PANDEY
MBBS, DMRD
CONSULTANT RADIOLOGIST

Note:

- (1) Not Valid for medical-legal purposes.
- (2) This is a professional opinion based on imaging finding and not the diagnosis.
- (3) In case of any discrepancy due to machine error or typing error, please get it rectified immediately.

Plot No. F-1, Sector-6A, SIDCUL, Haridwar - 249 403

Emergency : +91 8191902600, Phone : 01334 - 239040 / 42 / 43, Fax : 01334 - 239043

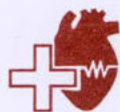E-mail : metroharidwar@metrohospitals.com, Website: www.metrohospitals.com

Regd. Office : 21, Community Center, Preet Vihar, New Delhi-110092

CIN No.: U33201DL2006PTC156918

MHHI/CL/0115/Rev. No. 01

25-Mar-23 10:51 AM

**METRO****HOSPITAL & HEART INSTITUTE**

(A unit of Sunhill Hospitals Private Limited)

(NABH & ISO 9001: 2008 Certified)

Radiology Investigation Report

Name : Ms. Vishakha Singh
Ref. By : Dr. ANIL SINGH
IP/OP : OP/202230520
Date : 25/03/2023

Age/Sex : 25 Y/F
UHID NO : 2023005105
Request No : 70223694

X-RAY CHEST PA View

Trachea is central.

Bilateral hila are normal in size & density.

Cardiac silhouette is normal.


Bilateral lung fields are clear.

Bilateral Costophrenic angles are normal.

Bilateral domes of diaphragm are normal in position & contour.

Bones and soft tissues are normal.

IMPRESSION : Normal skiagram


DR. PRAKASH CHANDRA PANDEY
M.B.B.S, D.M.R.D
CONSULTANT RADIOLOGIST

Note:

- (1) Not Valid for medical-legal purposes.
- (2) This is a professional opinion based on imaging finding and not the diagnosis.
- (3) In case of any discrepancy due to machine error or typing error, please get it rectified immediately.

Plot No. F-1, Sector-6A, SIDCUL, Haridwar - 249 403

Emergency : +91 8191902600, Phone : 01334 - 239040 / 42 / 43, Fax : 01334 - 239043

E-mail : metroharidwar@metrohospitals.com, Website: www.metrohospitals.com

Regd. Office : 21, Community Center, Preet Vihar, New Delhi-110092

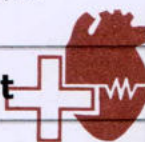
CIN No.: U33201DL2006PTC156918

MHHI/CL/0115/Rev. No. 01

27-Mar-23 11:10 AM

12

Pathology Report



METRO PATH LABS

Name : Ms. Vishakha Singh
 Ref. By : Dr. ANIL SINGH
 IP/OP : OP/202230520
 Sample Date : 25/03/2023
 Reporting Date: 25/03/2023

Age/Sex : 25 Y/F
 UHID : 2022005103
 Request No. : 10344624
 Sample Time : 09:00
 Reporting Time : 20:58

(A unit of Sunhill Hospitals Private Limited)
 (ISO & NABH Certified)
 CIN No.: U33201DL2006PTC156918

Test	Result	Unit	Bio. Ref. Inter.	Test Method
------	--------	------	------------------	-------------

Hematology

BLOOD GROUP

ABO	A	-	-	-
Rh	POSITIVE	-	-	-
ESR	19	mm/hr	20	-

Serology & Immunology

THYROID PROFILE

T3	2.40	nmol/L	1.70-3.10	-
T4	10.0	µg/dl	5.95-15.4	-
TSH	1.43	µIU/L	0.46-4.68	-

*** End of Reports ***

Dr. Vishal Arora
 MBBS, DCP
 (Consultant Pathologist)



Note:

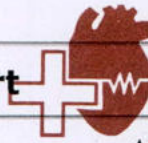
1. These reports are mere estimation of values at that particular time and are liable to vary/change in different conditions in different laboratories.
2. The values are to be collaborated with clinical findings by qualified doctor and any alarming and unexpected results should be reported to Lab urgently for recheck and manual typing errors.
3. These reports are not valid for medicolegal purposes and all doctor unsigned reports should be considered provisional only.
4. All card based tests are screening test therefore need confirmation by other alternative test like (PCR, ELISA).

Plot No. F-1, Sector-6A, SIDCUL, Haridwar - 249 403

Emergency : +91 8191902600, Phone : 01334-289040 / 43 / 43, Fax : 01334-289043

E-mail : metroharidwar@metrohospitals.com, Website: www.metrohospitals.com

Pathology Report



METRO PATH LABS

Name : Ms. Vishakha Singh
 Ref. By : Dr. ANIL SINGH
 IP/OP : OP/202230520
 Sample Date : 25/03/2023
 Reporting Date: 25/03/2023

Age/Sex : 25 Y/F
 (A unit of Sunhill Hospitals Private Limited)
 UHID : 202305103
 Request No. : 10344624
 Sample Time : 09:00
 Reporting Time : 20:58
 (ISO & NABH Certified)
 CIN No.: 0332010L2006PTC156918

Test	Result	Unit	Bio. Ref. Inter.	Test Method
Biochemistry				
HB1AC	5.9	%	4.5-6.3	
BLOOD SUGAR -FASTING	90.0	mg/dl	70.0-110.0	
BLOOD SUGAR -PP	105.0	mg/dl	70.0-140.0	
LIPID PROFILE				
TOTAL CHOLESTEROL	173.0	mg/dl	00-250.0	
HDL-CHOLESTEROL	49.0	mg/dl	00-50.0	
LDL	99.0	mg/dl	00-150.0	
TRIGLYCERIDES	123.0	md/dl	30-150	
VLDL	25.0	mg/dl	0-50	
CHOL/HDL Ratio	3.5		<4.5	
LFT (LIVER FUNCTION TEST)				
BILIRUBIN INDIRECT	0.30	mg/dl	0.2-0.8	
SGOT	28.0	U/L	10-42	
SGPT	32.0	U/L	10-42	
BIILIRUBIN TOTAL	0.60	mg/dl	0.2-1.0	
ALKALINE PHOSPHATASE	74.0	IU/L	28-111	
BILIRUBIN DIRECT	0.30	mg/dl	0.1-0.4	
TOTAL PROTEIN	6.7	gm/dl	6.4-8.2	
ALBUMIN	3.7	g/dl	3.5-5.0	
GLOBULIN	3.0	gm/dl	2.0-4.0	
AG RATIO	1.1		-	
KFT (KIDNEY FUNCTION TEST)				
UREA	18.0	mg/dl	15-45	
SODIUM	141.0	mmol/L	135-155	
CREATININE	0.64	mg/dl	0.6-1.3	
URIC ACID	5.1	mg/dl	3.0-7.6	
BUN	8.5	mg/dl	05-20	
POTTASSIUM	4.4	mmol/L	3.5-5.5	
CALCIUM	9.4	mg/dl	8.5-10.5	

*** End of Reports ***

Dr. Vishal Arora
 MBBS, DCP
 (Consultant Pathologist)



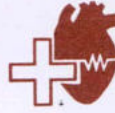Checked By

Note:

1. These reports are mere estimation of values at that particular time and are liable to vary/change in different conditions in different laboratories.
2. The values are to be collaborated with clinical findings by qualified doctor and any alarming and unexpected results should be reported to Lab urgently for recheck and manual typing errors.
3. These reports are not valid for medicolegal purposes and all doctor unsigned reports should be considered provisional only.
4. All card based tests are screening test therefore need confirmation by other alternative test like(PCR,ELISA).

Plot No. F-1, Sector-6A, SIDCUL, Haridwar - 249 403

Emergency : +91 8191902600, Phone : 01334 - 239040 / 43 / 43, Fax : 01334 - 239043
 192.168.7.100/hismetroharidwarmetrohospital/lab/print_path_lab_result.php?sid=32657&dec=0603&tab=074&en=local_user=ck_1... 1/1
 E-mail : metroharidwar@metrohospitals.com, Website: www.metrohospitals.com



METRO

HOSPITAL & HEART INSTITUTE

(A unit of Sunhill Hospitals Private Limited)

(NABH & ISO 9001: 2008 Certified)

2D ECHOCARDIOGRAPHY

Name:	Mrs. Vishakha Singh	UHID No:	2023005105
Age/Sex:	25Y/F	Ward:	OPD
Referred by:	Dr. Anil Singh	Date:	25.03.2023

ACOUSTIC WINDOW: Normal

MEASUREMENTS AND CALCULATIONS

Measurements	Observed Value	Reference Value
IVS (ED)	0.8	(0.6 – 1.1 cm)
LVPW (ED)	1.0	(0.6 – 1.1 cm)
LVID (ED)	3.7	Male (3.7 – 5.5 cm) Female (3.7 – 5.2 cm)
Aortic root diameter	2.1	(2.0 – 3.7 cm)
LA dimension	2.9	Male (1.9 – 4.0 cm) Female (1.7 – 3.8 cm)
LV EF	60%	(55 – 75%)

MORPHOLOGICAL DATA

Mitral valve	Normal	Right Atrium	Normal
Aortic valve	Normal	Right Ventricle	Normal
Tricuspid valve	Normal	PA	Normal
Pulmonary valve	Normal	IVS	Intact
		IAS	Intact

DOPPLER STUDY

Valve	Regurges	Velocities (cm/s)	Gradients (mmHg)
Mitral	Trace	E – 93, A – 60, E/A > 1	
Aortic	Nil	Vel – 120	
Tricuspid	Mild	Vel – 250	PASP – 30
Pulmonary	Nil	Vel – 85	

Plot No. F-1, Sector-6A, SIDCUL, Haridwar - 249 403

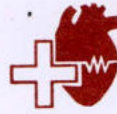Emergency : +91 8191902600, Phone : 01334 - 239040 / 42 / 43, Fax : 01334 - 239043

E-mail : metroharidwar@metrohospitals.com, Website: www.metrohospitals.com

Regd. Office : 21, Community Center, Preet Vihar, New Delhi-110092

CIN No.: U33201DL2006PTC156918

MHHI/CL/0115/Rev. No. 01



METRO

HOSPITAL & HEART INSTITUTE

(A unit of Sunhill Hospitals Private Limited)

(NABH & ISO 9001: 2008 Certified)

FINAL IMPRESSION

- Normal Acoustic Window
- Normal Chambers Dimensions
- No RWMA
- LVEF~60%
- No LVDD
- Trace MR, Trace TR, PASP 30 mmHg
- No pericardial effusion
- No Intracardiac clot



Dr. Krishna CK

MD, DNB (Medicine), DNB (Cardiology)
Consultant Interventional Cardiology
UKMC Reg. No: 12883

Dr. Ajit Kumar

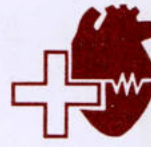MBBS, PGDCC
Associate Consultant, Cardiology
UKMC Reg. No: 7569

(Note: This document is not for medico-legal purpose)

Plot No. F-1, Sector-6A, SIDCUL, Haridwar - 249 403
Emergency : +91 8191902600, Phone : 01334 - 239040 / 42 / 43, Fax : 01334 - 239043
E-mail : metroharidwar@metrohospitals.com, Website: www.metrohospitals.com

Regd. Office : 21, Community Center, Preet Vihar, New Delhi-110092
CIN No.: U33201DL2006PTC156918

MHHI/CL/0115/Rev. No. 01



METRO PATH LABS

(A unit of Sunhill Hospitals Private Limited)

(ISO & NABH Certified)

CIN No.: U33201DL2006PTC156918

Patient Name : **Ms. VISHAKHA SINGH**
DOB/Age/Gender : 25 Year's /Female
Patient ID : --- 12
Referred By : **Dr.**

Sample Collected Date : Mar,25/2023
Report Date : Mar,25/2023
Report Time : 07:12 PM

Test Description	Value(S)	Unit(S)	Reference Range
Complete Blood Count & {C.B.C.} HAEMATOLOGY			
Hemoglobin:-	11.4	mg/dl	11.5---16.0
T L C:-	5.820	Cells/cumm	4.000—11.000
D L C:-			
Neutrophils:-	73.0	%	45 - 75
Lymphocytes:-	18.3	%	25 - 45
Eosinophils:-	6.5	%	1 - 6
Monocytes:-	2.20	%	2 - 8
Basophils:-	0.00	%	---<2
RED BLOOD CELLS Count:R.B.C.	4.11	Million/cu/mm	3.5 - 5.5
PACKED CELL VOLUME {HCT} P.C.V	43.1	%	36 - 52
MEAN CELLS VOLUME:(M.C.V):	96.1	f1	80 - 100
MEAN CELLS HEMOGLOBIN:M.C.H	25.5	pg	27 - 32
MEAN CELLS HEMGRAM CONCENTRATION:-M.C.H.C:	29.6	gm/dl	31 - 37
PLATELETS COUNT:-	2.13	Lakh/cu mm	1.50 - 4.50
RDW:-	15.4	%	11.5 - 15.0

End Of Report



Plot No. F-1, Sector-6A, SIDCUL, Haridwar - 249 403

Emergency : +91 8191902600, Phone : 01334 - 239040 / 42 / 43, Fax : 01334 - 239043

E-mail : metroharidwar@metrohospitals.com, Website: www.metrohospitals.com

Pathology Report



METRO PATH LABS

Name : Ms. Vishakha Singh
 Ref. By : Dr. ANIL SINGH
 IP/OP : OP/202230520
 Sample Date : 25/03/2023
 Reporting Date: 25/03/2023

Age/Sex : 25 Y/F
 (A Unit of Sunhill Hospitals Private Limited)
 UHID : 2023005105
 Request No. CIN No. 10374102406PTC156918
 Sample Time : 09:00
 Reporting Time: 20:58

Test	Result	Unit	Bio. Ref. Inter.	Test Method
------	--------	------	------------------	-------------

Urine Examination

URINE SUGAR NIL

URINE ROUTINE ANALYSIS

PHYSICAL EXAMINATION

COLOUR PALE YELLOW -

TRANSPARENCY CLEAR -

S. GRAVITY 1.025 -

CHEMICAL EXAMINATION

ALBUMIN NIL -

SUGAR NIL -

pH 6.0 -

BLOOD NIL -

KETONE NIL -

MICROSCOPIC EXAMINATION

PUS CELLS 2-3 -

EPITHELIAL CELLS 1-2 -

RBC NIL -

CRYSTALS NIL -

CAST NIL -

BACTERIA NIL -

AMORPHOUS PHOSPHATE NIL -

AMORPHOUS URATES NIL -

*** End of Reports ***

Dr. Vishal Arora
 MBBS, DCP
 (Consultant Pathologist)

Checked By



Note:

1. These reports are mere estimation of values at that particular time and are liable to vary/change in different conditions in different laboratories.
2. The values are to be collaborated with clinical findings by qualified doctor and any alarming and unexpected results should be reported to Lab urgently for recheck and manual typing errors.
3. These reports are not valid for medicolegal purposes and all doctor unsigned reports should be considered provisional only.
4. All card based tests are screening test therefore need confirmation by other alternative test like (PCR, ELISA).

Plot No. F-1, Sector-6A, SIDCUL, Haridwar - 249 403

Emergency : +91 8191902600, Phone : 01334 - 239040 / 42 / 43, Fax : 01334 - 239043

E-mail : metroharidwar@metrohospitals.com, Website: www.metrohospitals.com