



# PARKLINE DIAGNOSTICS PVT. LTD.

L.G. 3, 4 & 5, Bhuvana Towers, S.D. Road, Secunderabad - 500 003.

Tel : +91 40-2784 5852, 6649 1787, 7995421787, 7093445852, Fax : +91 40 2784 7864

Email parklinediagnostics@gmail.com www.parklinediagnostics.com




NABL Accredited  
Certificate No.MC-256

## MEDICAL EXAMINATION REPORT

Name	Mrs. N. Anuradha		Date :	11/01/2022		
Company	Clo: Mediwheel		Reg. No. :	1663926		
Contact No.	9001877654		Sex	<input type="checkbox"/> M <input checked="" type="checkbox"/> F	Age :	<input type="checkbox"/> 40 <input checked="" type="checkbox"/> 49
Type	Pre-Emp		Emp. No.:	Spouse		
	Overseas		Height	152 cm		
	Annual	<input checked="" type="checkbox"/>	Weight	85 kgs		
Remarks						
	<p>ECG - T-wave depression in leads I, aVL, V<sub>1</sub>-V<sub>6</sub>. — ? Post MI status.</p> <p>- Cardiologist consultation for further treatment.</p> <p>- Prediabetic state - Advised life style modification</p> <p>- Hypercholesterolemia - Advice follow up.</p> <p>V&amp;V - Fibroids in Uterus. Advice gynaecologist consultation for further follow up.</p> <p>DR. PRIYANKA SANNIDHI MBBS Regn. No : 11351</p>					
Fitness Status	Medically Fit / Unfit		Physician's Signature			

# COMPREHENSIVE MEDICAL EXAMINATION REPORT



NAME Ms. M. Anuradha

AGE 49 yrs

MARITAL STATUS Married CHILDREN: M  F

IDENTIFICATION (IF ANY) A mole on (L) Hand.

## PAST HISTORY

Any family H/o : High Blood Pressure, Heart Disease, Tuberculosis, Diabetes, Asthma, Cancer

Mother

Any personal H/o Major illness like : Typhoid.....NIL.....Jaundice.....NIL.....Etc.

Any H/o STD.....Skin infection.....NIL

H/o Blood Transfusion.....Recent Vaccination.....COVID 19 2 Doses ✓

H/o Epilepsy.....NIL.....Giddiness.....NIL

H/o Surgery.....Fracture in the past.....NIL

### Any Personal H/O.

High Blood Pressure, Heart Disease Tuberculosis, Diabetes, Asthma, Cancer

Drug Abuse, Drug Allergy, Micturition, Bowels, Alcohol, Smoking, Sleep, MC, Wt. Loss/Wt. Gain

post-menopausal state.

Present illness / Medication NIL particular.

## GENERAL EXAMINATION

Conjunctiva :  
 Skin :  
 Ears :  
 Nose :  
 Throat & Oral Cavity :

NBD

Bone, Joints :  
 Nutritional Status :  
 Lymph Nodes :  
 Edema Feet :  
 Varicose Veins :

RA?  
 ⊕ Sciatica, Disc prolap.  
 well nourished.  
 NPD  
 NIL  
 NIL

**Distant Vision : Near Vision :**

Right Eye: 6/6

With glasses / Without glasses

left Eye : 6/6

with glasses / without glasses

Colour Vision : Normal

Right Eye: N10 + 2.00 sph N6

With glasses / Without glasses

left Eye : N10 + 2.00 sph N6

with glasses / without glasses

Ophthalmologist's Signature

DR. KATTA  
M.S., D.O., F.R.F.  
Regd. (AMC)

**Right Ear**

Hearing :

(N)

Rinee's Test ;

Weber Test :

Discharge :

NIL

**Left Ear**

(N)

NIL

**SYSTEMIC EXAMINATION**

Pulse : 85 bpm

B.P. : 160/100 mmHg

Lungs : A. Shape of Chest B/L symmetrical  
B. Breath Sounds B/L - clear ⊕  
C. Adventitious Sounds No

Heart : A. Sounds S<sub>1</sub> S<sub>2</sub> ⊕  
B. Murmurs No murmurs

Abdomen : A. Liver NP  
B. Spleen NP  
C. Piles NIL  
D. Any Lump NIL

**Nervous System**

A. Higher Function :  
B. Cranial Nerves :  
C. Sensory System :  
D. Motor System :  
E. Jerks :  
(N)

General : A. Hernia  
B. Hydrocele  
C. Varicocele  
] NAD

Breast : Rt \_\_\_\_\_ Lt. \_\_\_\_\_

## CANDIDATE'S DECLARATION

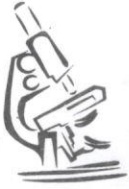I hereby solemnly declare that I am not suffering from Asthma, Hypertension, Diabetes, Occult Psychological disorders or any other ailment which can be suppressed without my voluntary declaration.

Date :

  
\_\_\_\_\_  
Signature

Place :

Note : General Physical Examination and Investigation included in the health check-up Have certain limitations and may not be able to detect all latent and asymptomatic diseases. Any new symptoms developing after the health check-up or persisting thereafter should be brought to the attention of the treating physician.



# PARKLINE DIAGNOSTICS PVT. LTD.

L.G. 3, 4 & 5, Bhuvana Towers, S.D. Road, Secunderabad - 500 003. Tel : +91 40-2784 5852, 6649 1787, 7995421787,  
7093445852, Fax : +91 40 2784 7864 Email parklinediagnostics@gmail.com www.parklinediagnostics.com



NABL Accredited  
Certificate No.MC-2566

## ENT CONSULTATION

S.No.	1663926	Emp.No.		Date	
Name	Anuradha	Age	Yrs	Sex	M/F

EARS :	Right	Left
EAC	: patent, no Cerumen	-do-
TM	: Intact, pearly white	-do-
TFT	: Cone of light (+) Rinne's +ve	Rinne's +ve

NOSE : <sup>Debee's - centralised</sup> Septum (N). Bil. Turbinate (N). Pnis (N) mounted.

THROAT : Oropharynx (N). Bil. v-c's (N) moving

NECK : (N) <sup>Asymmetry</sup> N=1.

IMPRESSION: ENT Clinically NAD.

**Dr. D. Hari Krishna Reddy**  
 MS (ENT)  
 Head & Neck Surgeon  
 Reg. No: 88379

Name : Anusadha ..... Sex : F ..... Age : 49 .....

Date : 11/1/22 .....

OPD No : 376 .....

Staine + Cal +




# PARKLINE DIAGNOSTICS PVT. LTD.

L.G. 3, 4 & 5, Bhuvana Towers, Sarojini Devi Road, Secunderabad - 500 003 Tel. +91 40-2784 5852  
6649 1787 Fax : +91 40 2784 7864 Email : parklinediagnostics@gmail.com www.parklinediagnostics.com



NABL Accredited  
Certificate No. MC-2566

## TEST REPORT

Name : Ms . M ANURADHA [SPOUSE]  
Age / Gender : 49 Years / Female  
Ref.By : Medi Wheel  
Req. No : BIL1663926

TID : UMR0659223  
Registered on : 11-Jan-2022 08:41 AM  
Reported On : 11-Jan-2022 09:58 AM

### DEPARTMENT OF ULTRASOUND Ultrasound Whole Abdomen

**LIVER** : Normal in size and echotexture. No focal lesions.

No IHBD /CBD dilatation. Portal vein is normal.

**SPLEEN** : Normal in size and echotexture. No focal lesion seen.

**GALL BLADDER** : Well distended. No sludge / gall stones / sol.  
Gall bladder - Wall thickness is normal.  
No pericholecystic oedema.

**PANCREAS** : Normal in size and echotexture.No calcification / sol.  
Pancreatic duct is normal. No peripancreatic fluid collection.

**RIGHT KIDNEY** : 9.6 x 4.8 cms  
Normal in size and echotexture.  
Cortical thickness is normal.  
No evidence of calculi / sol.  
Pelvi calyceal system is normal.

**LEFT KIDNEY** : 9.7 x 4.8 cms  
Normal in size and echotexture.  
Cortical thickness is normal.  
No evidence of calculi / sol.  
Pelvi calyceal system is normal.

**URINARY BLADDER** : Well distended.Normal in contour.  
Wall thickness is normal. No calculus / sol.

**UTERUS** : Anteverted measuring 9.1 x 4.3 x 4.4 cms - Normal in size and echotexture.  
Iso and hypochoic areas in fundus of uterus anteriorly and posteriorly measuring 1.54 cms and 1.19 cms.  
Cervix is normal in size and echopattern.

**ENDOMETRIUM** : Normal.

The Test marked with\*are not accredited by NABL

Lab Timings (Weekdays) : 7.00 am to 8.30 pm

Sundays & Holidays : 7.00 am to 1.00 pm

Radiologists Timings (Weekdays) : 9.30 am to 1.30 pm

Sundays & Holidays

& 5.30 pm to 7.45 pm

: 7.30 am to 9.30 am



# PARKLINE DIAGNOSTICS PVT. LTD.

L.G. 3, 4 & 5, Bhuvana Towers, Sarojini Devi Road, Secunderabad - 500 003 Tel. +91 40-2784 5852  
6649 1787 Fax :+91 40 2784 7864 Email : parklinediagnostics@gmail.com www.parklinediagnostics.com



NABL Accredited  
Certificate No. MC-2566

## TEST REPORT

Name : Ms . M ANURADHA [SPOUSE]  
Age / Gender : 49 Years / Female  
Ref.By : Medi Wheel  
Req. No : BIL1663926

TID : UMR0659223  
Registered on : 11-Jan-2022 08:41 AM  
Reported On : 11-Jan-2022 09:58 AM

**OVARIES** : Right ovary : 2.2 x 1.0 cms Left ovary : Not visible.  
No adnexal mass seen.  
No fluid in POD.

**IMPRESSION** : ? Fibroid uterus.

Clinical correlation.



12

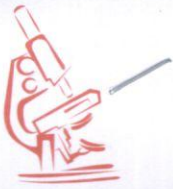Dr. D.J. MOHAN  
MD DMRD  
(Reg No. 8995)  
Consultant Radiologist

The Test marked with\*are not accredited by NABL

**Lab Timings** (Weekdays) : 7.00 am to 8.30 pm  
Sundays & Holidays : 7.00 am to 1.00 pm

**Radiologists Timings** (Weekdays) : 9.30 am to 1.30 pm  
& 5.30 pm to 7.45 pm  
Sundays & Holidays : 7.30 am to 9.30 am





# PARKLINE DIAGNOSTICS PVT. LTD.

L.G. 3, 4 & 5, Bhuvana Towers, Sarojini Devi Road, Secunderabad - 500 003 Tel. +91 40-2784 5852  
6649 1787 Fax :+91 40 2784 7864 Email : parklinediagnostics@gmail.com www.parklinediagnostics.com



NABL Accredited  
Certificate No. MC-2566

## TEST REPORT

Name : Ms . M ANURADHA [SPOUSE]  
Age / Gender : 49 Years / Female  
Ref.By : Medi Wheel  
Req. No : BIL1663926

TID : UMR0659223  
Registered on : 11-Jan-2022 08:41 AM  
Reported On : 11-Jan-2022 01:53 PM

Bilateral CC and MLO views done.

Both breasts show normal fibro-glandular parenchyma.

No dominant mass /pleomorphic micro calcifications /skin thickening /  
Nipple retraction on either side.

No architectural distortion.

No evidence of duct dilatation.

No axillary lymphadenopathy.


**Ultrasound screening** did not reveal any abnormality.

No axillary lymphnodes seen.

**IMPRESSION : No breast abnormality noted - BIRADS- I**

**Advised clinical correlation.**

**Note: Please bring previous reports on next visit.**

  
Dr. PRAJAKTA SUKHADEVE  
DNB RADIOLOGY  
Reg. No. 68493

The Test marked with\*are not accredited by NABL

**Lab Timings** (Weekdays) : 7.00 am to 8.30 pm

Sundays & Holidays : 7.00 am to 1.00 pm

**Radiologists Timings** (Weekdays) : 7.30 am to 1.30 pm

& 5.30 pm to 7.45 pm

Sundays & Holidays

: 7.30 am to 9.30 am

# PARKLINE DIAGNOSTICS PVT. LTD.

L.G. 3, 4 & 5, Bhuvana Towers, Sarojini Devi Road, Secunderabad - 500 003 Tel. +91 40-2784 5852  
6649 1787 Fax :+91 40 2784 7864 Email : parklinediagnostics@gmail.com www.parklinediagnostics.com



NABL Accredited  
Certificate No. MC-2566

## TEST REPORT

Name : Ms . M ANURADHA [SPOUSE]  
Age / Gender : 49 Years / Female  
Ref.By : Medi Wheel  
Req. No : BIL1663926

TID : UMR0659223  
Registered on : 11-Jan-2022 08:41 AM  
Reported On : 11-Jan-2022 01:53 PM

### BIRADS ASSESSMENT CATEGORIES

- 0 - Needs additional imaging.
- 1 - Negative - There is nothing the comment on.
- 2 - Benign finding.
- 3 - Probably benign finding - followup after 3 months suggested.
- 4 - Suspicious abnormality. Biopsy should be considered  
[ 4A - Low suspicion ,4B - Intermediate suspicion, 4C- Moderate concern]
- 5 - Highly suggestive of malignancy.
- 6 - Known biopsy proven malignancy.

The Test marked with\*are not accredited by NABL

Lab Timings (Weekdays) : 7.00 am to 8.30 pm  
Sundays & Holidays : 7.00 am to 1.00 pm

Radiologists Timings (Weekdays) : 9.00 am to 1.30 pm  
& 5.30 pm to 7.45 pm  
Sundays & Holidays : 7.30 am to 9.30 am



# PARKLINE DIAGNOSTICS PVT. LTD.

L.G. 3, 4 & 5, Bhuvana Towers, Sarojini Devi Road, Secunderabad - 500 003 Tel. +91 40-2784 5852  
6649 1787 Fax :+91 40 2784 7864 Email : parklinediagnostics@gmail.com www.parklinediagnostics.com



NABL Accredited  
Certificate No. MC-2566

## TEST REPORT

Name : Ms . M ANURADHA [SPOUSE]  
Age / Gender : 49 Years / Female  
Ref.By : Medi Wheel  
Req. No : BIL1663926

TID : UMR0659223  
Registered on : 11-Jan-2022 08:41 AM  
Reported On : 11-Jan-2022 09:11 AM

### DEPARTMENT OF X-RAY X-Ray Chest PA View

Lung fields are clear.

Cardia is normal.

Hila are normal.

C P angles are free.

Bony cage is normal.

Soft tissues are normal.

**IMPRESSION : NORMAL CHEST XRAY.**

12

Dr. D.J. MOHAN  
MD DMRD  
(Reg No. 8995)  
Consultant Radiologist

The Test marked with\*are not accredited by NABL

Lab Timings (Weekdays) : 7.00 am to 8.30 pm  
Sundays & Holidays : 7.00 am to 1.00 pm

Radiologists Timings (Weekdays) : 7.30 am to 1.30 pm  
& 5.30 pm to 7.45 pm  
Sundays & Holidays : 7.30 am to 9.30 pm

PATIENT SUMMARY REPORT

VE DIAGNOSTICS PVT.LTD

: 1663926  
: MS.M.ANURADHA  
EX : 49 / FEMALE

HEIGHT (cm) : 152  
WEIGHT (kg) : 75  
PROTOCOL : BRUCE

REF. BY : MEDIWHEEL  
DONE BY : DR.NAVEEN KUMAR C  
TECHNICIAN : G.M.SURESH

11-01-2022, 10:06:  
AC

STORY :

REASON FOR REFERENCE :

TYPE OF TEST : Routine Check Up.

INDICATIONS : None.

ACTIVITY : Very Active.

TEST INVESTIGATION : E C G

REASON FOR TERMINATION : Dyspnoea.

EXERCISE TOLERANCE : Moderate ( < 10 METS ).

EXERCISE INDUCED ARRHYTHMIAS : No.


EXERCISE RESPONSE : Normal.

POST EXERCISE RESPONSE : Normal.

IMPRESSION :

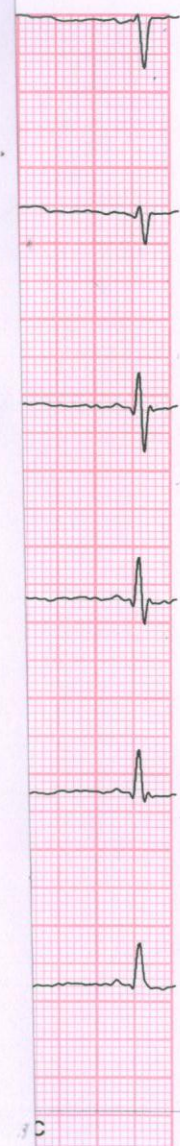
REMARKS :

negative for inducible ischemia

  
**Dr. NAVEEN KUMAR .C**  
M.D., D.M.  
Consultant Cardiologist  
Reg. No. 52291

Confirmed By

Signature



ID: 1663926  
MS.M ANURADHA  
Female 49Years

11-01-2022 09:00:17 AM

CARDIART

TD E<sub>c</sub> aVL V<sub>1</sub>-V<sub>6</sub>  
Correlate clinically



HR : 68 bpm  
P : 107 ms  
PR : 135 ms  
QRS : 79 ms  
QT/QTc : 387/413 ms  
P/QRS/T : -11/22/113 °  
RV5/SV1 : 1.133/0.868 mV

**Dr. NAVEEN KUMAR .C**  
M.D., D.M.  
Consultant Cardiologist  
Reg. No. 52291

Diagnosis Information:  
Sinus Rhythm  
Flattened T Wave(V6)

Report Confirmed by: