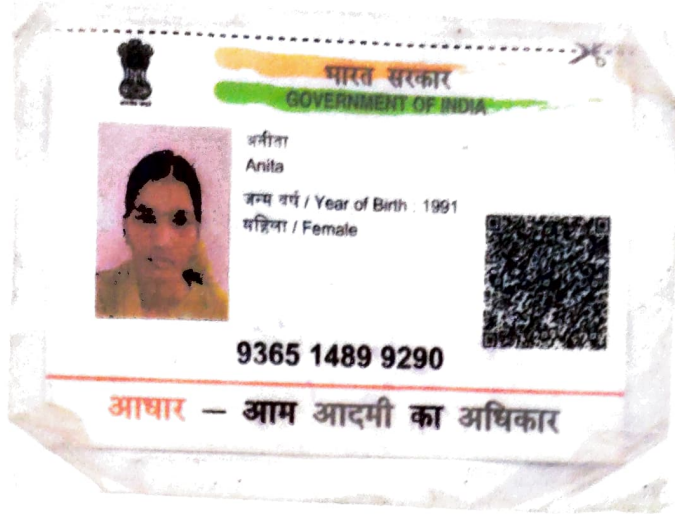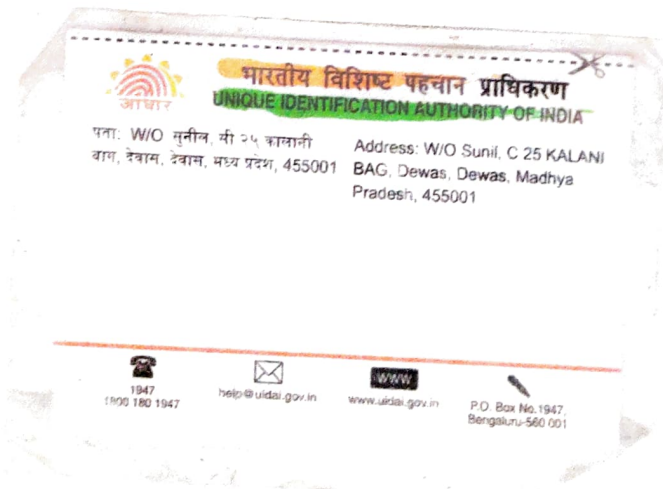




अनीता वर्मा





# प्राइम पैथालॉजी

(प्राइम हॉस्पिटल)

105-ए, सिविल लाईन मेन रोड, देवास (म.प्र.) मो. : 8770552644, 9827435781, amitshree96@gmail.com

## PATHOLOGY

Fully Computerize Pathology Lab

Patient's Name: **MRS. ANITA VARMA**  
Age & Sex : 31 Yrs., Female  
Referred by : DR. PAWAN CHILLORIA M.B.B.S.M.D.  
Consultant Dr. : DR. PAWAN CHILLORIA M.B.B.S.M.D.

Ref.No. : 2122-0004599  
Date : 13/02/2022

### Haematology Examination



Test Name	Result	Normal Range
Heamoglobin	12.3 gm/dl	M: 13.5 - 18.0 F: 11-16
Total WBC Count	5,600 /cumm	4,000 - 11,000
Neutrophils	78 %	40 - 75
Lymphocytes	17 %	20 - 50
Monocytes	03 %	0 - 10
Eosinophils	02 %	1 - 6
Basophils	00 %	0 - 1
E.S.R. (Wintrob's Method)	14 mm	M: 1- 13 F: 1-20
P.C.V.	42.0 %	M: 40-52 F: 35-45
R.B.C. Count	4.56 mili/cumm	M: 4.5 -6.5 F: 3.5-5.5
M.C.V.	92.11 fl.	74 -96
M.C.H.	26.97 pg.	27 - 32
M.C.H.C	29.29 g/dl	30 - 35
Platelet Count	2.36 lacs/cumm	1.5 - 4.5
Blood Group	"A"	
Rh (D)	Positive	



All Investigations have technical and biological limitations. Please correlate clinically as well as with other investigative findings.  
A Review should be requested in case of any disparity. This Report is not valid for medicolegal purpose.



# प्राईम पैथालॉजी

(प्राईम हॉस्पिटल)

105-ए, सिविल लाईन मेन रोड, देवास (म.प्र.) मो. : 8770552644, 9827435781, amitshree96@gmail.com

## PATHOLOGY

Fully Computerize Pathology Lab

Patient's Name: **MRS. ANITA VARMA**  
Age & Sex : 31 Yrs. Female  
Referred by : DR. PAWAN CHILLORIA M.B.B.S.M.D.  
Consultant Dr. : DR. PAWAN CHILLORIA M.B.B.S.M.D.

Ref.No. : **2122-0004599**  
Date : **13/02/2022**



Test Name	Result	Normal Range
<b><u>Biochemical Examination</u></b>		
GLUCOSE FASTING	96.0 mg/dl	70-100
GLUCOSE PP	121.0 mg/dl	upto 140
S. CREATININE	1.1 mg/dl	0.5- 1.5
BLOOD UREA NITROGEN	12.6 mg/dl	5-21
S. URIC ACID	4.63 mg/dl	M: 2.5-7 F: 1.5 - 6
GAMMA -GT	26.0 IU/L	M 8-61 F 5-36
<b><u>Lipid Profile</u></b>		
TOTAL LIPIDS	519.38	400-700
S. CHOLESTEROL	194.0 mg/dl	150-240
HDL CHOLESTEROL	44.3 mg/dl	30 - 70
S. TRIGLYCERIDES	127.0 mg/dl	< 150 Normal 150-200 Border line high > high
L.D.L. CHOLESTEROL	124.30 mg/dl	Low Risk < 100 , Normal Risk 139-160 >160
V.L.D.L.	25.40 mg/dl	upto 40
RISK RATIO	4.38	Up to 4.97
<b><u>Thyroid Test</u></b>		
Total Triiodothyronine (T3)	0.93 ng/ml	0.60- 1.81
Total Thyroxine (T4)	5.39 ug/dl	4.5 - 12.6
Thyroid Stimulating Hormone (TSH)	2.46 uIU/ml	0.34 - 5.5



All Investigations have technical and biological limitations. Please correlate clinically as well as with other investigative findings.  
A Review should be requested in case of any disparity. This Report is not valid for medicolegal purpose.



# प्राईम पैथालॉजी

(प्राईम हॉस्पिटल)

105-ए, सिविल लाईन मेन रोड, देवास (म.प्र.) मो. : 8770552644, 9827435781, amitshree96@gmail.com

## PATHOLOGY

Fully Computerize Pathology Lab

Patient's Name: **MRS. ANITA VARMA**  
Age & Sex : 31 Yrs., Female  
Referred by : DR. PAWAN CHILLORIA M.B.B.S.M.D.  
Consultant Dr. : DR. PAWAN CHILLORIA M.B.B.S.M.D.

Ref.No. : **2122-0004599**

Date : **13/02/2022**

### Liver Profile



Test Name	Result	Normal Range
TOTAL BILIRUBIN	0.64 mg/dl	0.0 - 1.00
DIRECT BILIRUBIN	0.17 mg/dl	0.0 - 0.25
INDIRECT BILIRUBIN	0.47 mg/dl	0.0 - 0.75
S.G.O.T.	21.0 IU/L	upto 49
S.G.P.T.	29.0 IU/L	upto 40
ALKALINE PHOSPHATASE	182.0 IU/L	Ad. 100-250 Ch. 250-770
TOTAL PROTEINS	7.13 g/dl	6.2 - 8.3
ALBUMIN	4.24 g/dl	3.5 - 5.0
GLOBULIN	2.89 g/dl	2.3 - 3.5
A/G RATION	1.47:1	1.2-1.8 : 1



All Investigations have technical and biological limitations. Please correlate clinically as well as with other investigative findings.  
A Review should be requested in case of any disparity. This Report is not valid for medicolegal purpose.



# प्राईम पैथालॉजी

(प्राईम हॉस्पिटल)

105-ए, सिविल लाईन मेन रोड, देवास (म.प्र.) मो. : 8770552644, 9827435781, amitshree96@gmail.com

## PATHOLOGY

Fully Computerize Pathology Lab

Patient's Name : MRS. ANITA VARMA

Age & Sex : 31 Yrs. Female

Referred by : DR. PAWAN CHILLORIA M.B.B.S.M.D.

Consultant : DR. PAWAN CHILLORIA M.B.B.S.M.D.

Ref.No. : 2122-0004599

Report Date: 13-Feb-2022



## HAEMATOLOGY

Glyc. Hb ( HbA1c ) : 4.86 %

Noramal : 4.2 - 6.5

Good control : 6.5 - 8.0

Fair control : 8.0 - 10.0

Poor control : > 10.0





# प्राईम पैथालॉजी

(प्राईम हॉस्पिटल)

105-ए, सिविल लाईन मेन रोड, देवास (म.प्र.) मो. : 8770552644, 9827435781, amitshree96@gmail.com

## PATHOLOGY

Fully Computerize Pathology Lab

Patient's Name: **MRS. ANITA VARMA**

Age & Sex : 31 Yrs., Female

Referred by : DR. PAWAN CHILLORIA M.B.B.S.M.D.

Consultant Dr. : DR. PAWAN CHILLORIA M.B.B.S.M.D.

Ref.No. : **2122-0004599**

Date : **13/02/2022**

### EXAMINATION OF STOOL



#### Physical Examination

Colour	<b>Brown yellow</b>
Consistency	<b>Semi Solid</b>
Mucus	<b>Absent</b>
Blood	<b>Absent</b>

#### Chemical Examination

Reaction pH	<b>Acidic</b>
Reducing Sugar	<b>Negative</b>
Occult Blood	<b>Absent</b>

#### Microscopic Examination

Pus Cells	<b>2-3 /hpf</b>	Bacteria	<b>Absent</b>
Starch	<b>Absent</b>	Parasite	<b>Nil</b>
Vegetables	<b>Absent</b>	Red Blood Cells	<b>Absent</b>
Macrophages	<b>Absent</b>	Fat Globules	<b>Absent</b>
Undigested Food Particals	<b>Present</b>	Epithelial Cells	<b>Absent</b>
Cyst	<b>Nil</b>	Ova	<b>Nil</b>



All Investigations have technical and biological limitations. Please correlate clinically as well as with other investigative findings.  
A Review should be requested in case of any disparity. This Report is not valid for medicolegal purpose.



# प्राइम पैथालॉजी

(प्राइम हॉस्पिटल)

105-ए, सिविल लाईन मेन रोड, देवास (म.प्र.) मो. : 8770552644, 9827435781, amitshree96@gmail.com

## PATHOLOGY

Fully Computerize Pathology Lab

Patient's Name: **MRS. ANITA VARMA**

Age & Sex : 31 Yrs., Female

Referred by : DR. PAWAN CHILLORIA M.B.B.S.M.D.

Consultant Dr. : DR. PAWAN CHILLORIA M.B.B.S.M.D.

Ref.No. : **2122-0004599**

Date : **13/02/2022**

### EXAMINATION OF URINE



#### Physical Examination

Collection From : **Hospital**  
Sample Collection : **Random**  
Quantity : **40 ml**  
Colour : **Pale Yellow**  
Appearance : **Clear**  
Specific Gravity : **1.015**

#### Chemical Examination


Reaction : **Acidic**  
Albumin : **Nil**  
Sugar : **Nil**  
Ketone Bodie : **Absent**  
Bile Salts : **Absent**  
Bile Pigment : **Absent**  
Occult Blood : **Nil**

#### Microscopic Examination

(After Centrifugation at 2000 rpm. for 5 minuts)

Leucocytes(Pus Cells) : **2-3 /hpf**  
Epithelial Cells : **4-5 /hpf**  
Red Blood Cells : **NIL /hpf**  
Crystals : **Absent**  
Spermatozoa : **Absent**  
Parasites : **Absent**  
Cast : **Absent**  
Yeast Cells : **Absent**  
Bacteria : **Nil**

**Trichomonas Vaginalls: Absent**



All Investigations have technical and biological limitations. Please correlate clinically as well as with other investigative findings.  
A Review should be requested in case of any disparity. This Report is not valid for medicolegal purpose.

# DEWAS DIAGNOSTICS

## CT SCAN & MRI CENTRE

• 1.5 Tesla MRI • Multi Slice CT Scan • 3D, 4D Sonography • Digital X-ray • Digital Mammography  
• Echo- Cardiography • Digital OPG • Pathology • TMT  
106, Civil Lines, Dewas, Phone: 07272-404287, 254637

45

Patient's Name:	Mrs. Anita Verma	Age/Sex:	31 Y/F
Ref_ by: Dr.	P.K. Chilloriya MBBS, MD	Date:	12/02/2022

### U.S.G. WHOLE ABDOMEN

**Liver** is normal in size. It measures (13.7 cm) in mid clavicular line. Its shape is normal and has smooth margins.

**Gall bladder** is normal in size, has thin walls and lumen is echo free. The CBD is normal.

**Pancreas** is normal in size, out line and echo texture.

**Spleen** is normal in size and has normal homogenous parenchyma.

**Right kidney** is normal in size, shape, outline & position. Renal paranchymal echogenicity is normal and Pelvicalyceal system not dilated. Cortico-medulary ratio is maintained.

**Left kidney** is normal in size, shape, outline & position. Renal paranchymal echogenicity is normal and Pelvicalyceal system not dilated. Cortico-medulary ratio is maintained.

IVC and aorta are normal in caliber.

No para aortic or mesenteric lymphadenopathy is seen. No ascites or free fluid is seen.


**Urinary bladder** is normal in shape and its lumen echo free.

**Uterus** is anteverted and normal in size, shape & echotexture (L-7.5cm, T-4.8 cm, AP-6.6cm.). Myometrium is homogenous. Cervix is normal in size.

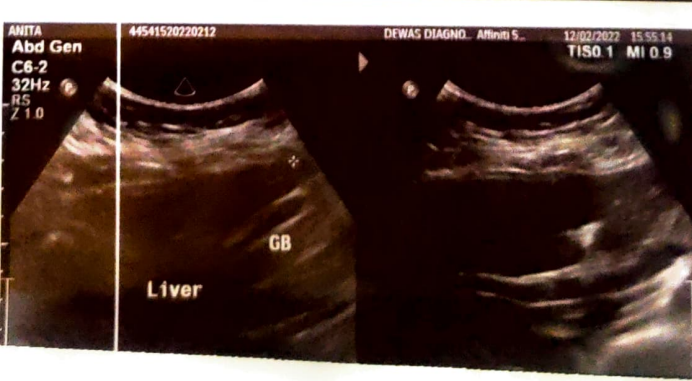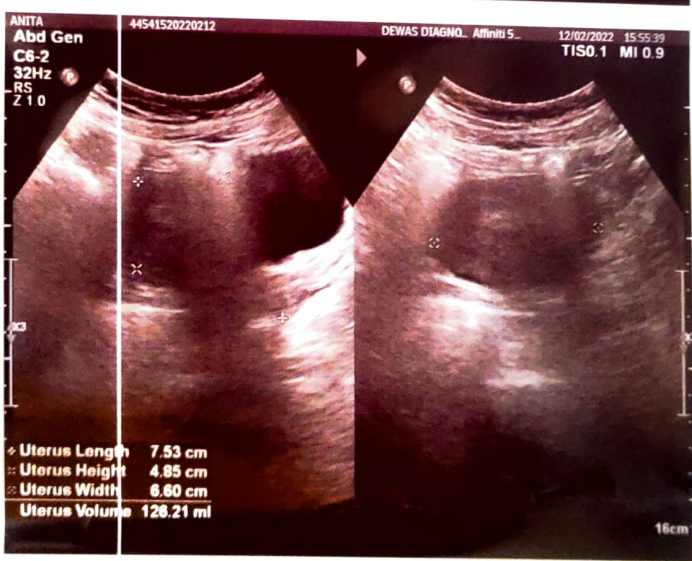
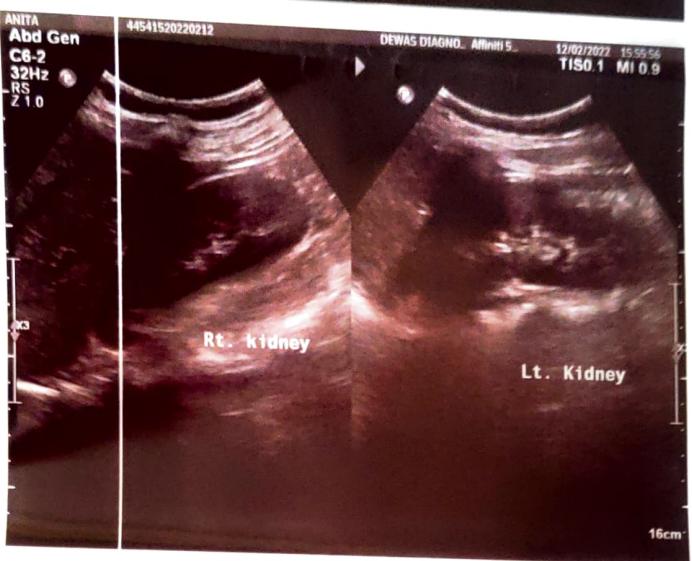
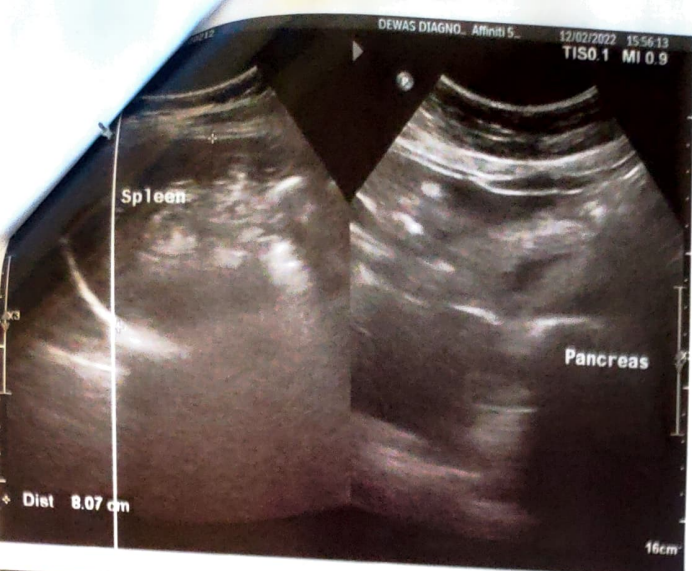
**Endometrium** is 6 mm thickness.

**Both ovaries** are normal in size.

**IMPRESSION** - No significant abnormality seen.

  
Dr. ANUJ SHARMA  
MBBS DMRD







देवास का नं. 1 स्वच्छ हॉस्पिटल *Better Diagnosis, Better Care*

# प्राइम हॉस्पिटल एण्ड रिसर्च सेन्टर

105-ए, सिविल लाईन, मेन रोड, देवास फोन : 07272 -400060, मो. 98272 65457

Date .....

Patient's Name :- Mrs. Anita Verma  
Date :- 02/12/2022  
Age & Sex :- 31 Year / Female  
Consultant Doctor :- DR. PAWAN KUMAR CHILLORIA

## Radiologist's Report

### X-RAY CHEST PA VIEW

- CHEST X-RAY PA VIEW TAKEN IN FULL INSPIRATION
- TRACHEA IN A CENTRAL POSITION
- CARDIOPHERENIC AND COSTOPHERENIC ANGLES ARE FREE
- CARDIAC SHADOW APPEARS NORMAL
- NO BONY ABNORMALITIES DETECTED
- PROMINENT BRONCHO VASCULAR MARKING

IMPRESSION - Normal

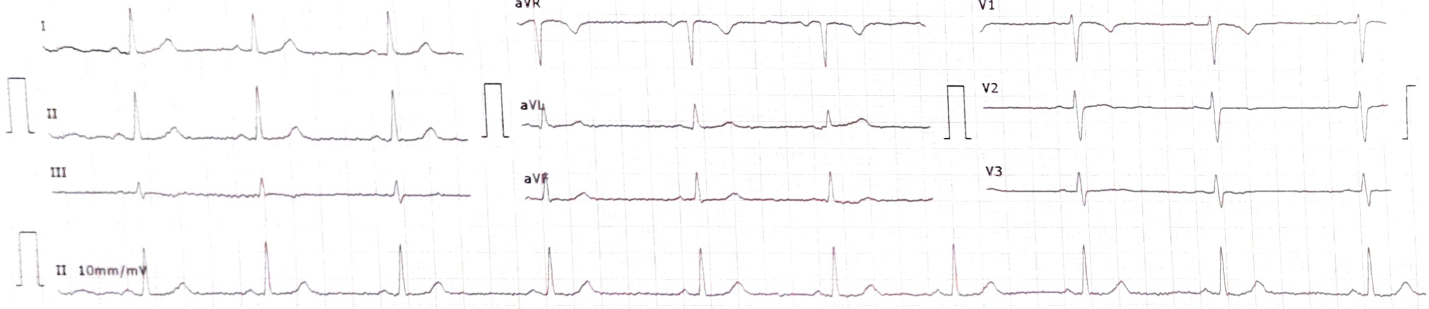

Dr. Rahul Adaval  
D.M.R.D.D.N.B  
[RADIOLOGIST]

10mm/mV AUTO

10mm/mV

10mm/mV



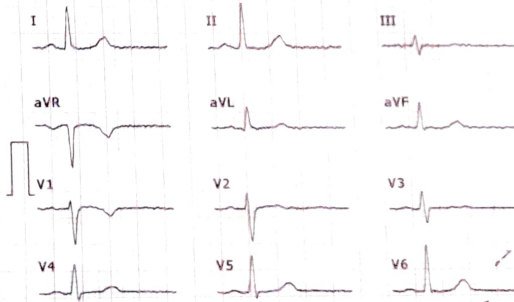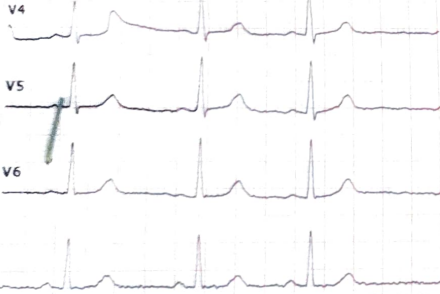25mm/s AC:ON 0.05-25Hz PRIME HOSPITAL AND RESEARCH CENTER DEWAS ICU 9827265457

AW CE

10mm/mV

2022-2-12 23:56:47

ID:0000878



25mm/s

AW CE

ID Card:

Name: MRS ANITA

Age: 32

Weight(Kg):

Gender: Female

Height(cm):

BP(mmHg): /

<< Conclusion >>

801 Sinus Rhythm

\*\* NORMAL ECG \*\*

HR .....bpm 61  
 P-R .....ms 103  
 Q-R-S .....ms 83  
 QT/QTc .....ms 376/376  
 P/QRS/T AXES .....deg 46/34/46  
 RV5/SV1 .....mV 0.78/0.66  
 RV5+SV1 .....mV 1.44

\*The result must be confirmed by doctor!

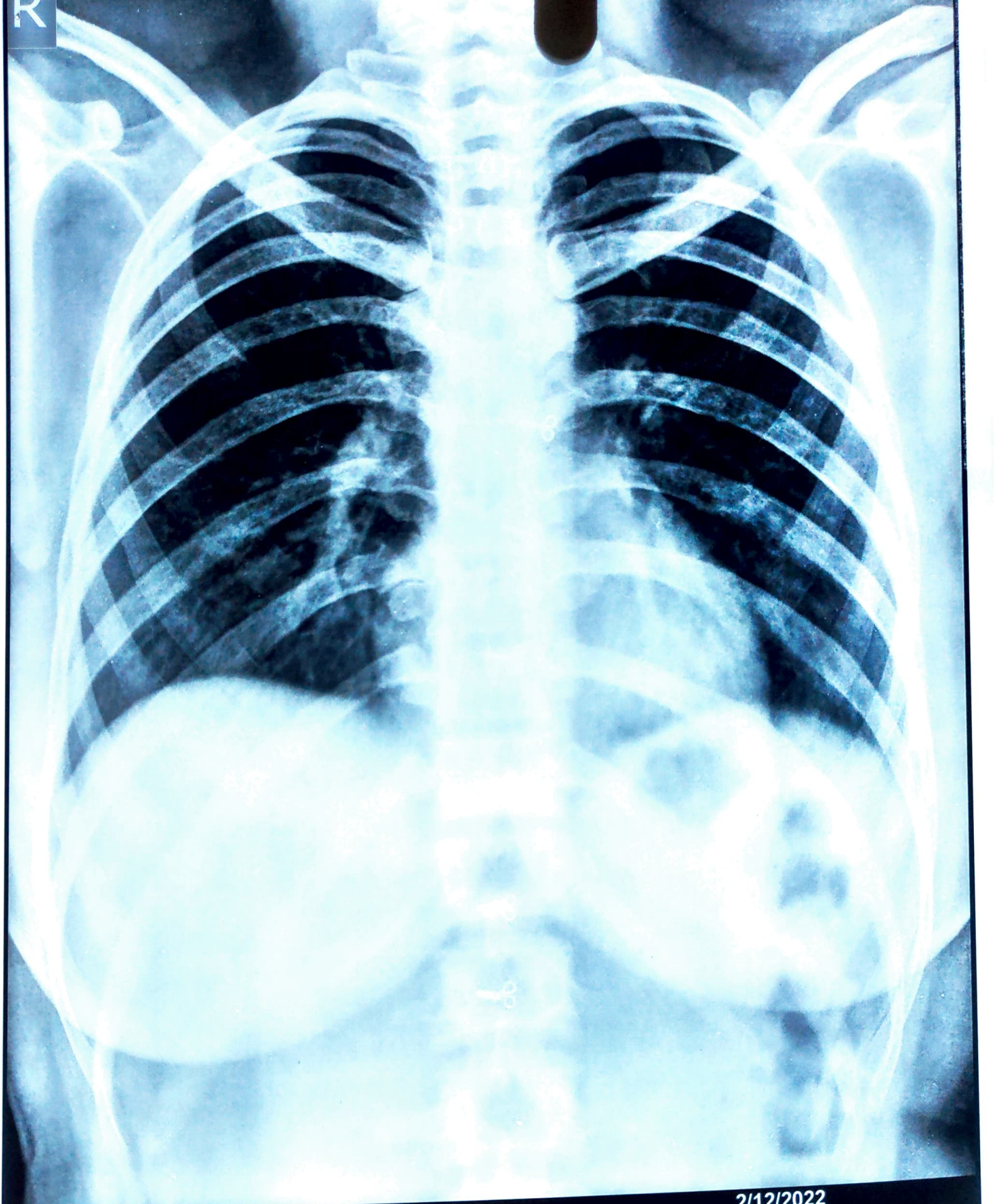
Report Confirmed by: DR PAWAN CHILLORIA

Report - wnl

Pawan  
आन्ताली चव्हा



R

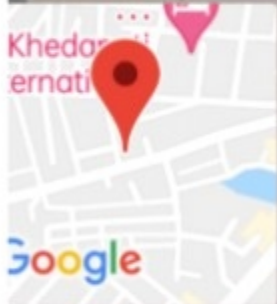


MRS.ANITA BAI 31 year(s) Female  
DR.P.K. CHILLORIA (MBBS MD)

Chest  
Chest PA

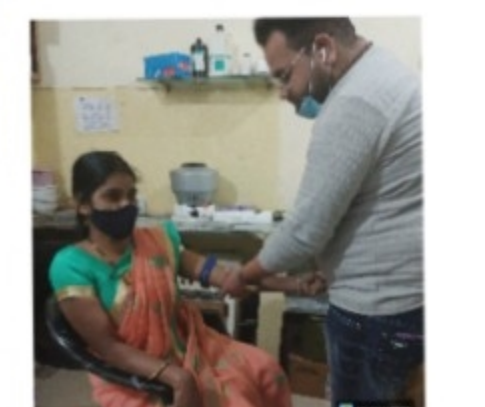2/12/2022  
12:32:45 PM

PRIME HOSPITAL & RESEARCH CENTRE , DEWAS (M.P.)



**देवास, मध्य प्रदेश, भारत**  
 106, मेंडकी रोड़, पाचुनकर कॉलोनी, इटावा, देवास, मध्य  
 प्रदेश 455001, भारत  
 Lat 22.964881°  
 Long 76.045049°  
 12/02/22 12:05 PM

**देवास, मध्य प्रदेश, भारत**  
 106, मेंडकी रोड़, पाचुनकर कॉलोनी,  
 प्रदेश 455001, भारत  
 Lat 22.964884°  
 Long 76.045041°  
 12/02/22 12:06 PM



**देवास, मध्य प्रदेश, भारत**  
 106, मेंडकी रोड़, पाचुनकर कॉलोनी, इटावा, देवास, मध्य  
 प्रदेश 455001, भारत

**Dewas, Madhya Pradesh, भारत**  
 106, मेंडकी रोड़, पाचुनकर कॉलोनी, इटावा, देवास, मध्य  
 प्रदेश 455001, भारत

**देवास, मध्य प्रदेश, भारत**  
 106, मेंडकी रोड़, पाचुनकर कॉलोनी, इटावा, देवास, मध्य  
 प्रदेश 455001, भारत