



PANACEA HOSPITAL

B 36/44 F.K KABIR NAGAR, DURGAKUND
TOLLFREE NO-18001233070. Whatsapp No - 8795832852
www.piire.org
panaceaquery@gmail.com|panaceahospitalit@gmail.com



OP Slip

Print Date : 24-Feb-2024 11:11AM



UHID No :- UD-23240006389 **OP No** :- OP-23240019568 **OP Date** :- 24 Feb 2024 11:06AM
Patient Name :- Mr HARIOM PRAJAPTI **Age/Sex** :- 36 Y/Male **Mobile No** :- 9616165393
Father :- SONCHAND PRAJAPATI **Department** :- GENERAL MEDICINE
Pay Type :- Cr **Consultant** :- Dr Pallavi Mishra (MBBS,MD,MBBS)
Token No :- NOR. - 15 **Paid/Bal** :- 0.00 /1030.00
Patient Type :- Normal
Address :- D 37/88 A GODOWALIA BARADEO,221001,varanasi

BP :- 110/70
 height :- 165
 Weight (kg) :- 68
 BMI :-
 PR - 80
 SPO2 - 98
 CH - 88
 NC - 36
 WC - 96
 PEAR - 500

Rx

Δ Prediabetes
Dyslipidemia
HASN

Rx f05 sgs Co.

Tab. Diabetes 10mg OD
 Ts. Remy 20mg BID
 Paster. Anti-biotic (500mg)

DR. Pallavi Mishra
 MBBS, MD(GENERAL MEDICINE)
 MCI Reg. No.52033

Printed By : Mr Siddhant Dwivedi
 Created By : Mr Siddhant Dwivedi



PANACEA HOSPITAL

B 36/44 F.K KABIR NAGAR, DURGAKUND
TOLLFREE NO-18001233070. Whatsapp No - 8795832852
www.piire.org
panaceaquery@gmail.com|panceahospitalit@gmail.com



OP Slip

Print Date : 24-Feb-2024 11:13AM



UHID No :- UD-23240006389	OP No :- OP-23240019574	OP Date :- 24 Feb 2024 11:12AM
Patient Name :- Mr HARIOM PRAJAPTI	Age/Sex :- 36 Y/Male	Mobile No :- 9616165393
Father :- SONCHAND PRAJAPATI	Department :- DERMATOLOGY	
Pay Type :- Cr	Consultant :- Dr RAVI BHUSHAN (MBBS,MD)	
Token No :- NOR. - 7	Paid/Bal :- 0.00 /1000.00	
Patient Type :- Normal		
Address :- D 37/88 A GODOWALIA BARADEO,221001,varanasi		

BP :-
height :-
Weight (kg) :-
BMI :-

Rx

SI B1 Reg LSKW

want

Rx

→ KE-T procedure
1800 - 300 discount PB

→ ~~Fucidic acid cream~~
(1-1) PB

→ Bacheal lotion
(2-2) Rx x today

→ Ketogem. Z Shampoo
twice (w)

→ Mupisom oint x 5
(1-1) Day

Printed By : Mr Nitin Kumar Yadav
Created By : Mr Nitin Kumar Yadav





PANACEA HOSPITAL

B 36/44 F.K KABIR NAGAR, DURGAKUND
TOLLFREE NO-18001233070. Whatsapp No - 8795832852
www.piire.org
panaceaquery@gmail.com|panceahospitalit@gmail.com



OP Slip

Print Date : 24-Feb-2024 11:12AM



UHID No :- UD-23240006389 OP No :- OP-23240019570 OP Date :- 24 Feb 2024 11:11AM
Patient Name :- Mr HARIOM PRAJAPTI Age/Sex :- 36 Y/Male Mobile No :- 9616165393
Father :- SONCHAND PRAJAPATI Department :- DENTAL
Pay Type :- Cr Consultant :- Dr SHRUTI MISHRA (AA)
Token No :- NOR. - 9 Paid :- 0.00
Patient Type :- Normal
Address :- D 37/88 A GODOWALIA BARADEO, 221001, varanasi

BP :-
height :-
Weight (kg) :-
BMI :-

Rx c/c => patient came for routine dental check up.

O/E => Stain/calculus - ++/++

P/D => chronic gen gingivitis

T/A => Scaling & polishing

Rs fee - 1000

Dr. SHRUTI MISHRA
BDS, (DENTIST)
MCI Reg. No. (A-09784)

Printed By : Mr Nitin Kumar Yadav
Created By : Mr Nitin Kumar Yadav



PANACEA HOSPITAL

B 36/44 F.K KABIR NAGAR, DURGAKUND
TOLLFREE NO-18001233070. Whatsapp No - 8795832852
www.piire.org
panaceaquery@gmail.com|panceahospitalit@gmail.com



OP Slip

Print Date : 24-Feb-2024 11:12AM



UHID No :- UD-23240006389	OP No :- OP-23240019571	OP Date :- 24 Feb 2024 11:12AM
Patient Name :- Mr HARIOM PRAJAPTI	Age/Sex :- 36 Y/Male	Mobile No :- 9616165393
Father :- SONCHAND PRAJAPATI	Department :- OPHTHALMOLOGY	
Pay Type :- Cr	Consultant :- Dr SANTOSH VERMA (MBBS,MS)	
Token No :- NOR. - 5	Paid :- 0.00	
Patient Type :- Normal		
Address :- D 37/88 A GODOWALIA BARADEO,221001,varanasi		

BP :-
height :-
Weight (kg) :-
BMI :-

Rx
VA $\left\{ \begin{array}{l} 6/9 - M \\ 6/6 - \end{array} \right.$ ~~4~~ ~~4~~

BE Ref Error

Adm
Ref
- OCT (ms) BE
- Fundus BE

2. B/E
1. G. CUBSTONE ULTRA TDS
Cap 2 FORTE PWS 1050 10day

Adm. Com-exams
2 RD 10day 7 ey

Printed By : Mr Nitin Kumar Yadav
Created By : Mr Nitin Kumar Yadav

Dr. SANTOSH VERMA.
MBBS, MS (Ophthalmologist)
MCI Reg. No. 09-34327

Facilities:

All clinical Biomedical & Hematology Investigations including Bone Marrow Examination
VPT, Podiascan & Complete Foot Care (First Time in Purvanchal)
All Hormonal Investigation by Chemiluminescent Method
Visceral Fat by (AB-140) Ambulatory BP Monitoring
CGMS & Insulin Pump Available
PFT, 2D-ECHO (Color Doppler), Holter, TMT, Cardiac-3 available
VIA, VILI, Colposcopy available
Special Endocrinological Investigation Protocols.

ISO 9001:2008 Certified
Mobile: 9389994334, 9554572190, 9453837595



Panacea Pathology

Clinical Reference Lab

Persistence, Preparedness and Precision
EQAS (CMC Vellore Attached) & IQAS System
पूर्वांचल की सर्वोत्तम गुणवत्ता वाली पैथोलॉजी

UHID No :- UD-23240006389
Patient Name :- Mr HARIOM PRAJAPTI
Father :- SONCHAND PRAJAPATI
Address :- D 37/88 A GODOWALIA
BARADEO,221001 , varanasi
Consultant :- Dr Pallavi Mishra (MBBS,MD)

Booking No/Date :- 133 / 24-Feb-2024 04:12 PM
Age/Sex :- 36 Y/M
OP No :- OP-23240019568
Mobile No :- 9616165393

Investigations	Observations	Biological Ref. Interval	Unit
----------------	--------------	--------------------------	------

HAEMATOLOGY

CBC

HAEMOGLOBIN

DefaultMethod / test Machine

14.7

13.00 - 16.00

gm/dl

TLC

Methology / Carm

6,600

4000.00 - 11000.00

Cells/cumm.

DLC DIFFERENTIAL LEUCOCYTE
COUNT

NEUTROPHILS

65

40.00 - 75.00

%

LYMPHOCYTES

27

20.00 - 45.00

%

EOSINOPHILS

03

1.00 - 6.00

%

MONOCYTES

05

2.00 - 10.00

%

BASOPHILS

00

<1-2

%

PLATELET COUNT

1.02

1.50 - 4.10

lacs /cumm

PCV

45.6

33.00 - 42.00

%

RBC

Methology / Carm

4.94

4.50 - 5.50

million/cumm

MCV(MEAN CELL VOLUME)

92.3

83.00 - 101.00

fl

MCH(MEAN CELL HAEMOGLOBIN)

29.8

27.00 - 32.00

pg

MCHC

32.3

31.50 - 35.00

gm%

RDW-CV

13.1

11.00 - 16.00

%

RDW-SD

49.2

37.00 - 57.00

fl

Lab Technician

Timing : 24/7 hrs

This Report is not valid for medico legal purpose


Consulting Pathologist

DR. UMESH KUMAR
MBBS, D.PATHOLOGY
MCI Reg. No. 41413

Note: These tests have technical limitations. Clinico-pathological interpretation is necessary. In case of any disparity test may be repeated immediately.

Address : 36/44 FK Kabir Nagar, Durgakund, Varanasi – 221005

Email: dramishra@gmail.com, drpallaviojha@gmail.com Website: panaceahospital.org

Facilities:

All clinical Biomedical & Hematology Investigations including Bone Marrow Examination VPT, Podiascan & Complete Foot Care (First Time in Purvanchal) All Hormonal Investigation by Chemiluminescent Method Visceral Fat by (AB-140) Ambulatory BP Monitoring CGMS & Insulin Pump Available PFT, 2D-ECHO (Color Doppler), Holter, TMT, Cardiac-3 available VIA, VILI, Colposcopy available Special Endocrinological Investigation Protocols.

ISO 9001:2008 Certified
Mobile: 9389994334, 9554572190, 9453837595



Panacea Pathology

Clinical Reference Lab

Persistence, Preparedness and Precision
EQAS (CMC Vellore Attached) & IQAS System
पूर्वांचल की सर्वोत्तम गुणवत्ता वाली पैथोलॉजी

UHID No	:- UD-23240006389	Booking No/Date	:- 133 / 24-Feb-2024 04:12 PM
Patient Name	:- Mr HARIOM PRAJAPTI	Age/Sex	:- 36 Y/M
Father	:- SONCHAND PRAJAPATI	OP No	:- OP-23240019568
Address	:- D 37/88 A GODOWALIA BARADEO,221001 , varanasi	Mobile No	:- 9616165393
Consultant	:- Dr Pallavi Mishra (MBBS,MD)		

Investigations	Observations	Biological Ref. Interval	Unit
----------------	--------------	--------------------------	------

URINE EXAMINATION

URINE ROUTINE EXAMINATION

PHYSICAL EXAMINATION

QUANTITY 25 ml

COLOR STRAW CLEAR YELLOW
Methology

APPEARANCE CLEAR CLEAR
DefaultMethod

CHEMICAL EXAMINATION

SPECIFIC GRAVITY 1.015 1.01 - 1.03

PH 6.0 4.60 - 8.00

GLUCOSE NIL 60.00 - 100.00 mg/dl

PROTEIN- NIL

MICROSCOPIC EXAMINATION

PUS CELLS NIL 2.00 - 3.00 /HPF

RBCS (RED BLOOD CELLS) NIL 4.50 - 5.50 /HPF

EPITHELIAL CELLS 01-02 /HPF

CASTS ABSENT ABSENT

CRYSTALS ABSENT ABSENT

Lab Technician

Timing : 24/7 hrs

This Report is not valid for medico legal purpose

Consulting Pathologist

Dr. Umesh Kumar
M.D. Pathology
MBBS,MD (PATHOLOGIST)

MCI Reg. No. 41413

Note: These tests have technical limitations. Clinico-pathological interpretation is necessary. In case of any disparity test may be repeated immediately.

Address : 36/44 FK Kabir Nagar, Durgakund, Varanasi – 221005

Email: dramishra@gmail.com, drpallaviojha@gmail.com Website: panaceahospital.org

Facilities:

All clinical Biomedical & Hematology Investigations including Bone Marrow Examination
VPT, Podiascan & Complete Foot Care (First Time in Purvanchal)
All Hormonal Investigation by Chemiluminescent Method
Visceral Fat by (AB-140) Ambulatory BP Monitoring
CGMS & Insulin Pump Available
PFT, 2D-ECHO (Color Doppler), Holter, TMT, Cardiac-3 available
VIA, VILI, Colposcopy available
Special Endocrinological Investigation Protocols.

ISO 9001:2008 Certified
Mobile: 9389994334, 9554572190, 9453837595



Panacea Pathology

Clinical Reference Lab

Persistence, Preparedness and Precision
EQAS (CMC Vellore Attached) & IQAS System
पूर्वाचल की सर्वोत्तम गुणवत्ता वाली पैथोलॉजी

UHID No :- UD-23240006389
Patient Name :- Mr HARIOM PRAJAPTI
Father :- SONCHAND PRAJAPATI
Address :- D 37/88 A GODOWALIA
BARADEO,221001, varanasi
Consultant :- Dr Pallavi Mishra (MBBS,MD)

Booking No/Date :- 133 / 24-Feb-2024 04:12 PM
Age/Sex :- 36 Y/M
OP No :- OP-23240019568
Mobile No :- 9616165393

Investigations	Observations	Biological Ref. Interval	Unit
HAEMATOLOGY			
ESR	12.0	0.00 - 15.00	mm at 1 hr
BLOOD GROUP ABO & RH FACTOR			
BLOOD GROUP	"B"		
RH FACTOR	POSITIVE		
HBA1C -(BY GOLD STANDARD METHOD :HPLC)	5.8	Normal: 4.0 - 5.4 Prediabetic : 5.5 -6.3 Diabetes mellitus := 6.4	%
BIOCHEMISTRY			
BLOOD SUGAR FASTING			
GLUCOSE	102.0	60.00 - 100.00	mg/dl
PRE-DIABETICS(IMPAIRED FASTING TOLER)	-	100.00 - 125.00	mg/dl
DIABETICS	-	upto 126	mg/dl
TARGET IN DM	-	80.00 - 130.00	mg/dl
BIOCHEMISTRY			
LIPID PROFILE			
TOTAL CHOLESTROL	144.0	Desirable : - < 200 mg/dL Borderline: - 200 - 239 mg/dL High : - > 240mg/dL	mg/dl
TRIGLYCERIDES	163.0	35.00 - 160.00	mg/dl
HDL CHOLESTROL	38.0	35.30 - 79.50	mg/dl

Lab Technician

Consulting Pathologist

Dr. Umesh Kumar
DR. UMESH KUMAR
M.D. Pathology
MBBS,MD (PATHOLOGIST)
MCI Reg. No. 41413

Timing : 24/7 hrs

This Report is not valid for medico legal purpose

Note: These tests have technical limitations. Clinico-pathological interpretation is necessary. In case of any disparity test may be repeated immediately.

Address : 36/44 FK Kabir Nagar, Durgakund, Varanasi - 221005

Email: dramishra@gmail.com, drpallaviojha@gmail.com Website: panaceahospital.org

Facilities:

All clinical Biomedical & Hematology Investigations including Bone Marrow Examination
VPT, Podiascan & Complete Foot Care (First Time in Purvanchal)
All Hormonal Investigation by Chemiluminescent Method
Visceral Fat by (AB-140) Ambulatory BP Monitoring
CGMS & Insulin Pump Available
PFT, 2D-ECHO (Color Doppler), Holter, TMT, Cardiac-3 available
VIA, VILI, Colposcopy available
Special Endocrinological Investigation Protocols.

ISO 9001:2008 Certified
Mobile: 9389994334, 9554572190, 9453837595



Panacea Pathology

Clinical Reference Lab

Persistence, Preparedness and Precision
EQAS (CMC Vellore Attached) & IQAS System
पूर्वाचल की सर्वोत्तम गुणवत्ता वाली पैथोलॉजी

UHID No :- UD-23240006389
Patient Name :- Mr HARIOM PRAJAPTI
Father :- SONCHAND PRAJAPATI
Address :- D 37/88 A GODOWALIA
BARADEO,221001 , varanasi
Consultant :- Dr Pallavi Mishra (MBBS,MD)

Booking No/Date :- 133 / 24-Feb-2024 04:12 PM
Age/Sex :- 36 Y/M
OP No :- OP-23240019568
Mobile No :- 9616165393

Investigations	Observations	Biological Ref. Interval	Unit
LDL CHOLESTROL	73.4	<130	mg/dl
VLDL	32.60	<40	mg/dl
CHOLESTROL/ HDL RATIO	3.79	<3.0 LOW RISK, 3.0-5.0 AVG RISK, >5.0 HIGH RISK	ratio
LDL/HDL RATIO	1.93	<3	ratio
LFT (LIVER FUNCTION TESTS)			
TOTAL BILIRUBIN	0.63	0.00 - 1.20	mg/dl
DIRECT BILIRUBIN	0.23	0.00 - 0.30	
INDIRECT BILIRUBIN	0.40	0.20 - 0.70	mg/dl
SGOT	29.0	2.00 - 31.00	U/L
SGPT	38.0	10.00 - 45.00	U/L
ALKALINE PHOSPHATASE	98.0	25.00 - 140.00	U/L
TOTAL PROTIENS	7.3	6.60 - 8.70	g/dl
ALBUMIN	4.2	3.50 - 5.20	gm%
GLOBULIN	3.1	1.50 - 3.60	gms/dl
A/G RATIO	1.35	2:1	RATIO

RFT (RENAL FUNCTION TESTS)

Lab Technician

Timing : 24/7 hrs

This Report is not valid for medico legal purpose


Consulting Pathologist

Dr. Umesh Kumar
MBBS,MD (PATHOLOGIST)
M.D., Pathology
MCI Reg. No. 41413

Note: These tests have technical limitations. Clinico-pathological interpretation is necessary. In case of any disparity test may be repeated immediately.

Address : 36/44 FK Kabir Nagar, Durgakund, Varanasi – 221005

Email: dramishra@gmail.com, drpallaviojha@gmail.com Website: panaceahospital.org

Facilities:

All clinical Biomedical & Hematology Investigations including Bone Marrow Examination
 VPT, Podiascan & Complete Foot,Care (First Time in Purvanchal)
 All Hormonal Investigation by Chemiluminescent Method
 Visceral Fat by (AB-140) Ambulatory BP Monitoring
 CGMS & Insulin Pump Available
 PFT, 2D-ECHO (Color Doppler), Holter, TMT, Cardiac-3 available
 VIA, VILI, Colposcopy available
 Special Endocrinological Investigation Protocols.

ISO 9001:2008 Certified
 Mobile: 9389994334, 9554572190, 9453837595



Panacea Pathology

Clinical Reference Lab

Persistence, Preparedness and Precision
 EQAS (CMC Vellore Attached) & IQAS System
 पूर्वांचल की सर्वोत्तम गुणवत्ता वाली पैथोलॉजी

UHID No :- UD-23240006389
Patient Name :- Mr HARIOM PRAJAPTI
Father :- SONCHAND PRAJAPATI
Address :- D 37/88 A GODOWALIA
 BARADEO,221001 , varanasi
Consultant :- Dr Pallavi Mishra (MBBS,MD)

Booking No/Date :- 133 / 24-Feb-2024 04:12 PM
Age/Sex :- 36 Y/M
OP No :- OP-23240019568
Mobile No :- 9616165393

Investigations	Observations	Biological Ref. Interval	Unit
SERUM CREATININE	0.87	0.60 - 1.60	mg/dl
URIC ACID	3.98	3.60 - 7.70	mg/dl
YGGT	21.0	10.00 - 50.00	U/L
<u>IMMUNOLOGY</u>			
THYROID PROFILE (T3,T4,TSH)			
T3	1.23	0.60 - 1.81	ng/ml
T4	7.4	4.50 - 10.90	ug/dl
TSH	2.15	0.39 - 6.10	uIU/mL
<u>PARASITOLOGY</u>			
STOOL ROUTINE			
<u>GROSS EXAMINATON</u>			
COLOR <i>Methodology</i>	YELLOW	CLEAR YELLOW	
CONSISTANCY	NORMAL		
BLOOD	ABSENT		
MUCUS	ABSENT		
<u>MICROSCOPIC EXAMINATON</u>			
OVA OR EGGS OF HELMINTHS	ABSENT		
CYST OF PROTOZOA	ABSENT		

Consulting Pathologist

Dr. Umesh Kumar
 MBBS, MD (Pathology) (GIST)
 MCI Reg. No. 41413

Lab Technician

Timing : 24/7 hrs

This Report is not valid for medico legal purpose

Note: These tests have technical limitations. Clinico-pathological interpretation is necessary. In case of any disparity test may be repeated immediately.

Address : 36/44 FK Kabir Nagar, Durgakund, Varanasi – 221005

Email: dramishra@gmail.com, drpallaviojha@gmail.com Website: panaceahospital.org

Facilities:

- All clinical Biomedical & Hematology Investigations including Bone Marrow Examination
- VPT, Podiascan & Complete Foot Care (First Time in Purvanchal)
- All Hormonal Investigation by Chemiluminescent Method
- Visceral Fat by (AB-140) Ambulatory BP Monitoring
- CGMS & Insulin Pump Available
- PFT, 2D-ECHO (Color Doppler), Holter, TMT, Cardiac-3 available
- VIA, VILI, Colposcopy available
- Special Endocrinological Investigation Protocols.

ISO 9001:2008 Certified
Mobile: 9389994334, 9554572190, 9453837595



Panacea Pathology

Clinical Reference Lab

Persistence, Preparedness and Precision
EQAS (CMC Vellore Attached) & IQAS System
पूर्वांचल की सर्वोत्तम गुणवत्ता वाली पैथोलॉजी

UHID No :- UD-23240006389
Patient Name :- Mr HARIOM PRAJAPTI
Father :- SONCHAND PRAJAPATI
Address :- D 37/88 A GODOWALIA
BARADEO,221001 , varanasi
Consultant :- Dr Pallavi Mishra (MBBS,MD)

Booking No/Date :- 133 / 24-Feb-2024 04:12 PM
Age/Sex :- 36 Y/M
OP No :- OP-23240019568
Mobile No :- 9616165393

Investigations	Observations	Biological Ref. Interval	Unit
PUS CELLS	03-05	2.00 - 3.00	/HPF
RBC <i>Methology / Carm</i>	NIL	4.50 - 5.50	million/cumm

* END OF REPORT *

Lab Technician

Timing : 24/7 hrs

This Report is not valid for medico legal purpose

Consulting Pathologist

Dr. Umesh Kumar
MBBS, MD (PATHOLOGIST)
MCI Reg. No. 41413

Note: These tests have technical limitations. Clinico-pathological interpretation is necessary. In case of any disparity test may be repeated immediately.

Address : 36/44 FK Kabir Nagar, Durgakund, Varanasi – 221005

Email: dramishra@gmail.com, drpallaviojha@gmail.com Website: panaceahospital.org

Facilities:

All clinical Biomedical & Hematology Investigations including Bone Marrow Examination
 VPT, Podiascan & Complete, Foot Care (First Time in Purvanchal)
 All Hormonal Investigation by Chemiluminescent Method
 Visceral Fat by (AB-140) Ambulatory BP Monitoring
 CGMS & Insulin Pump Available
 PFT, 2D-ECHO (Color Doppler), Holter, TMT, Cardiac-3 available
 VIA, VILI, Colposcopy available
 Special Endocrinological Investigation Protocols.

ISO 9001:2008 Certified
 Mobile: 9389994334, 9554572190, 9453837595



Panacea Pathology

Clinical Reference Lab

Persistence, Preparedness and Precision
 EQAS (CMC Vellore Attached) & IQAS System
 पूर्वांचल की सर्वोत्तम गुणवत्ता वाली पैथोलॉजी

UHID No :- UD-23240006389
Patient Name :- Mr HARIOM PRAJAPTI
Father :- SONCHAND PRAJAPATI
Address :- D 37/88 A GODOWALIA
 BARADEO, 221001, varanasi
Consultant :- Dr Pallavi Mishra (MBBS, MD)

Booking No/Date :- 133 / 25-Feb-2024 03:20 PM
Age/Sex :- 36 Y/M
OP No :- OP-23240019568
Mobile No :- 9616165393

Investigations	Observations	Biological Ref. Interval	Unit
----------------	--------------	--------------------------	------

BIOCHEMISTRY

PPBS(POST PRANDIAL BLOOD SUGAR)

POST PRANDIAL BLOOD GLUCOSE(2 HR AFTER MEAL)	120.0	110.00 - 150.00	mg/dl
IGT(2 HR 75GM GLUCOSE)	---	140.00 - 199.00	mg/dl
DIABETES	----	upto200	mg/dl
TARGET IN DM	----	80.00 - 130.00	mg/dl

* END OF REPORT *

Consulting Pathologist

DR. UMESH KUMAR
 MBBS, MD (PATHOLOGIST)
 MCI Reg. No. 41413

Lab Technician

Timing : 24/7 hrs

This Report is not valid for medico legal purpose

Note: These tests have technical limitations. Clinico-pathological interpretation is necessary. In case of any disparity test may be repeated immediately.

Address : 36/44 FK Kabir Nagar, Durgakund, Varanasi – 221005

Email: dramishra@gmail.com, drpallaviojha@gmail.com Website: panaceahospital.org

Facilities:

All clinical Biomedical & Hematology Investigations including Bone Marrow Examination
 VPT, Podiascan & Complete Foot Care (First Time in Purvanchal)
 All Hormonal Investigation by Chemiluminescent Method
 Visceral Fat by (AB-140) Ambulatory BP Monitoring
 CGMS & Insulin Pump Available
 PFT, 2D-ECHO (Color Doppler), Holter, TMT, Cardiac-3 available
 VIA, VILI, Colposcopy available
 Special Endocrinological Investigation Protocols.

ISO 9001:2008 Certified
 Mobile: 9389994334, 9554572190, 9453837595



Panacea Pathology

Clinical Reference Lab

Persistence, Preparedness and Precision
 EQAS (CMC Vellore Attached) & IQAS System
 पूर्वांचल की सर्वोत्तम गुणवत्ता वाली पैथोलॉजी

UHID No :- UD-23240006389
Patient Name :- Mr HARIOM PRAJAPTI
Father :- SONCHAND PRAJAPATI
Address :- D 37/88 A GODOWALIA
 BARADEO,221001 , varanasi
Consultant :- Dr Pallavi Mishra (MBBS,MD)

Booking No/Date :- 132 / 24-Feb-2024 04:12 PM
Age/Sex :- 36 Y/M
OP No :- OP-23240019568
Mobile No :- 9616165393

Investigations	Observations	Biological Ref. Interval	Unit
----------------	--------------	--------------------------	------

BIOCHEMISTRY

BUN	13.0	7.00 - 21.00	mg/dl
------------	------	--------------	-------

* END OF REPORT *

Consulting Pathologist

DR. Umesh Kumar
 MBBS, MD (PATHOLOGIST)
 MCI Reg. No. 41413

Lab Technician

Timing : 24/7 hrs

This Report is not valid for medico legal purpose

Note: These tests have technical limitations. Clinico-pathological interpretation is necessary. In case of any disparity test may be repeated immediately.

Address : 36/44 FK Kabir Nagar, Durgakund, Varanasi – 221005

Email: dramishra@gmail.com, drpallaviojha@gmail.com Website: panaceahospital.org



Call Now - 1800-123-3070

PANACEA HOSPITAL



A shelter for many hearts A Home for many lives

(An ISO 9001:2008 Certified Organisation)
Lab Attached with CMC Under EQAS Scheme

Dept. of Radiodiagnosis - 32 Slice CT Scan, 3D/4D USG, 2D ECHO, Colour Doppler, Intervention Procedures, Digital X-Ray

PATIENT'S NAME : HARIOM PRAJAPATI

AGE/SEX: 36Y/M

REF. BY : Dr. ASHUTOSH MISHRA(MD)

DATE 24-02-2024

X-RAY CHEST (AP VIEW)

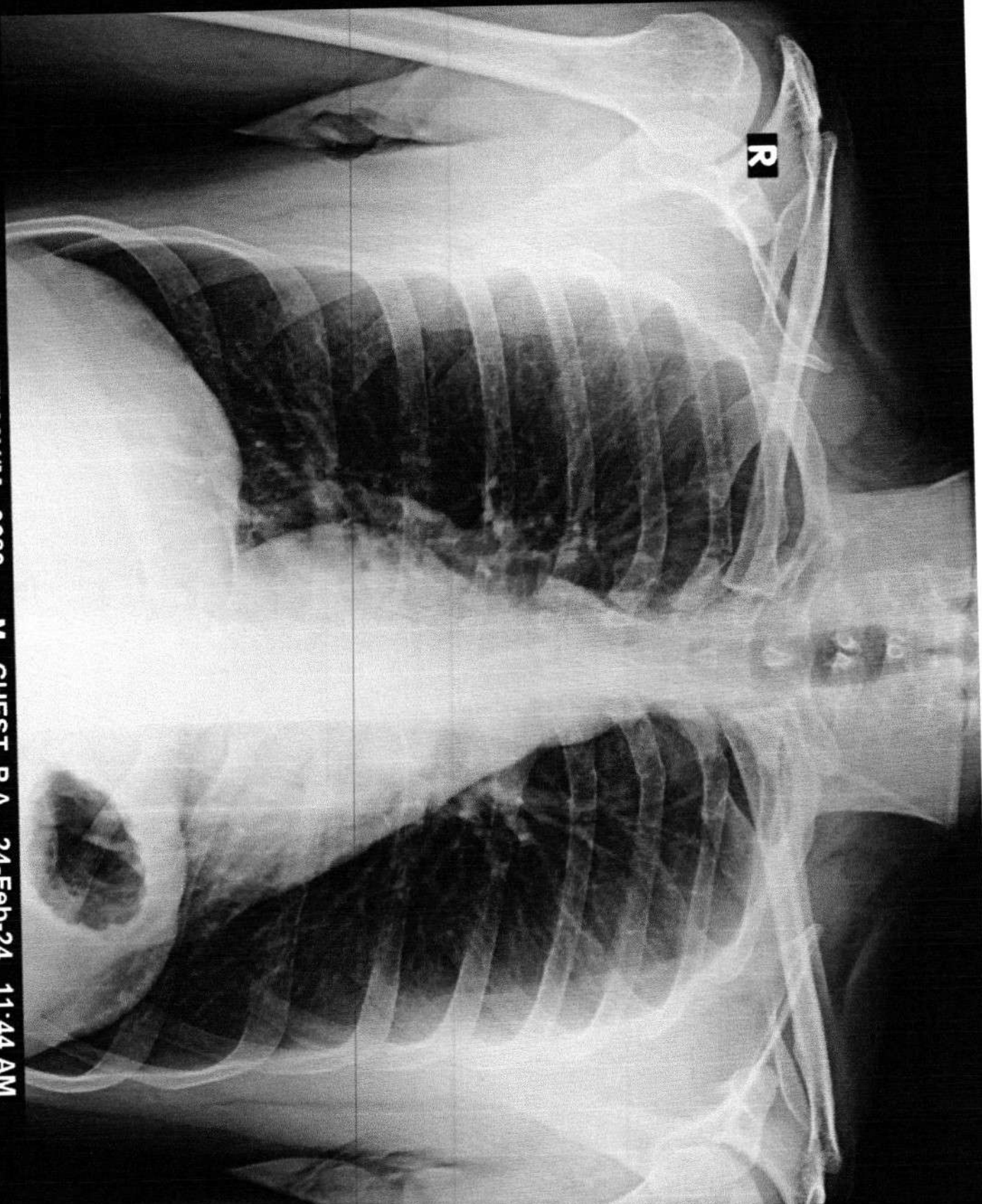
- Lung fields show hazy opacities in both parahilar, basal zone with mild prominent brochopulmonary markings findings suggestive of MILD BRONCHITIS.
- Rest visualized lung fields appear normal.
- Trachea appear normal in position and course.
- Both CP angles appear clear.
- Bony rib cage and soft tissue shadows appear normal.

Thanks for reference.


Dr. Anurag Kumar Tiwari
MBBS, MD (Radio Diagonosis)
Reg. No. 57557

Disclaimer: This report is not valid for Madicolegal or Judicial Purpose. Radiological diagnosis is solely interpretation of images produced by tissue & may not be always conclusive.

Address : B36/44 B4 Kabir Nagar (Near Sanjay Shiksha Niketan), Durgakund, Varanasi
Mobile : 9554572190 / 9453837595 / Recpn, 9389994334
Email : dramishra@gmail.com, drpallaviojha@gmail.com, Website : www.piire.org



R

HARIOM PRAJAPATI 36Y/M 3689 M CHEST P.A. 24-Feb-24 11:44 AM

PANACEA HOSPITAL, KABIR NAGAR, DURGAKUND, VARANASI



Call Now - 1800-123-3070

PANACEA HOSPITAL



A shelter for many hearts A Home for many lives

(An ISO 9001:2008 Certified Organisation)
Lab Attached with CMC Under EQAS Scheme

Dept. of Radiodiagnosis - 32 Slice CT Scan, 3D/4D USG, 2D ECHO, Colour Doppler, Intervention Procedures, Digital X-Ray

PATIENT'S NAME : HARIOM PRAJAPATI	AGE/SEX: 38 Y/M
REF. BY : Dr. ASHUTOSH MISHRA (MD)	Saturday, February 24, 2024

Echo - Cardiography


MITRAL VALVE Doppler	AML - normal morphology MV Flow - E - 0.5 A-0.4 E/A=1.08	PML - normal morphology MVA - 3.0 cm ² Mitral Regurgitation - No
TRICUSPID VALVE Doppler	Normal TV Flow -No	Tricuspid Regurgitation -No
PULMONARY VALVE Doppler	Normal PV Flow -No	Pulmonary Regurgitation - No
AORTIC VALVE Doppler	Trileaflet-No AV Flow - no	Aortic Regurgitation - no
MEASUREMENT	Aorta - 28.0 (20-38) mm IVS ed - 9.1 (6 -12) mm LVID ed -41.1 (35 - 55) mm LVPW ed - 12.0 (6 -12) mm OA - 7 (> 5) mm	LA - 24.6 (24-32) mm IVS es -16.0 (6 - 12) mm LVID es - 29.4 (24 - 40) mm LVPW es -10.9 (6 -12) mm EPSS - 4 (< 9) mm

CONCLUSION

All cardiac chamber dimensions are WNL
 No valvular abnormalities
 Good LV systolic function present Modified Simpson's method (4C, 2C) (LVEF=54%)
 No diastolic dysfunction present (E/A = 1.08)
 No RWMA
 No pericardial effusion
 Intact IAS / IV
 No PAH
 No intra cardiac mass /thrombus /vegetation

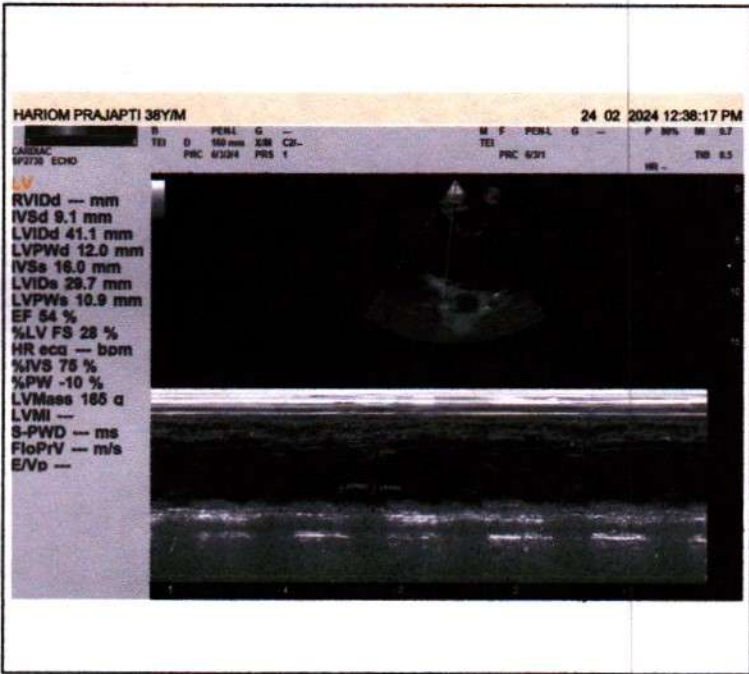
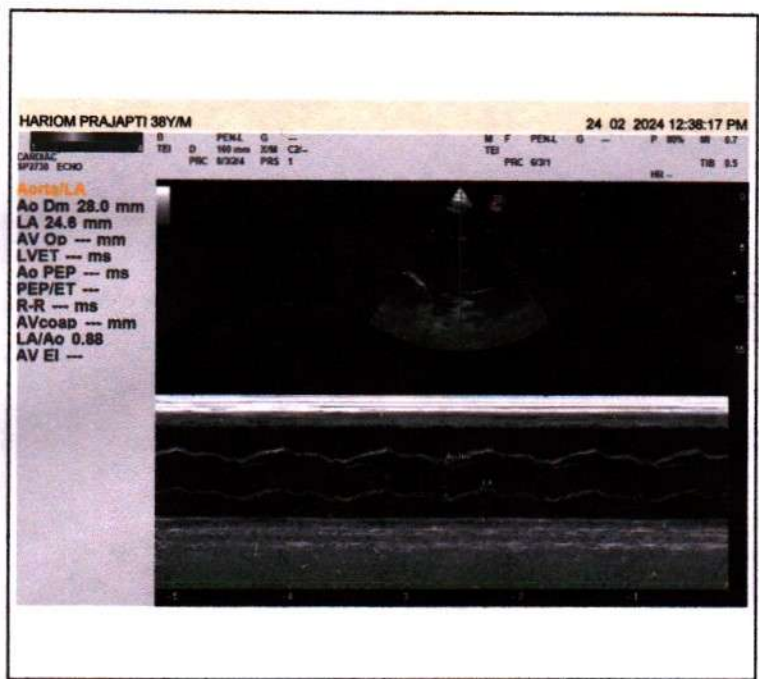
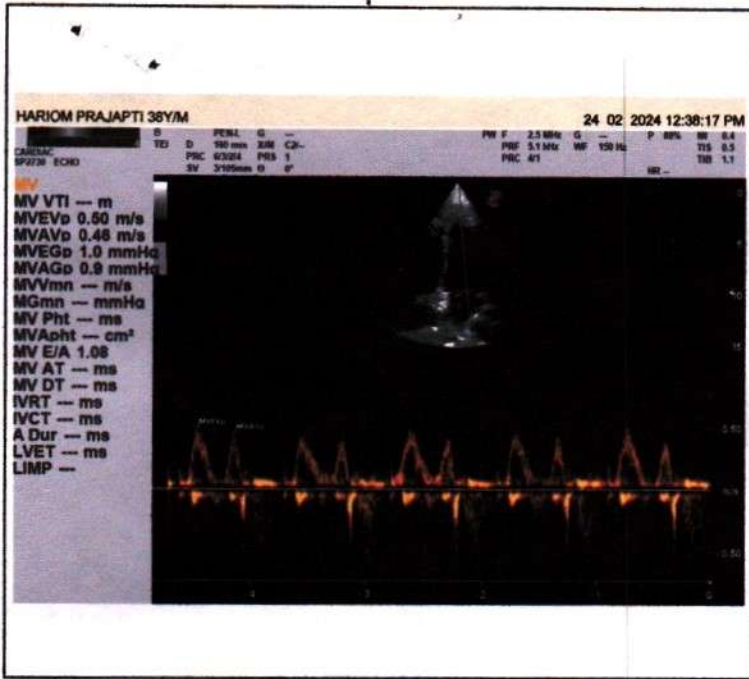
IMPRESSION **Normal Echocardiogram**


Niraj Mishra
Physician Assistant
(PIIRE)


DR. Pallavi Misra
MBBS, MD (GENERAL MEDICINE)
MCI Reg. No. 52033
Echocardiography Specialist, MIAE
Non-invasive cardiologist
Women Cardiologist
Diabetocardiologist

Disclaimer: This report is not valid for Madicolegal or Judicial Purpose. Radiological diagnosis is solely interpretation of images produced by tissue & may not be always conclusive.

Address : B36/44 B4 Kabir Nagar (Near Sanjay Shiksha Niketan), Durgakund, Varanasi
 Mobile : 9554572190 / 9453837595 / Recpn, 9389994334
 Email : dramishra@gmail.com, drpallaviojha@gmail.com, Website : www.piire.org





Call Now - 1800-123-3070

PANACEA HOSPITAL



A shelter for many hearts A Home for many lives

(An ISO 9001:2008 Certified Organisation)
Lab Attached with CMC Under EQAS Scheme

Dept. of Radiodiagnosis - 32 Slice CT Scan, 3D/4D USG, 2D ECHO, Colour Doppler, Intervention Procedures, Digital X-Ray

PATIENT'S NAME : HARIOM PRAJAPATI **AGE/SEX:** 38 Y/M
REF. BY : Dr. ASHUTOSH MISHRA (MD) **DATE:** 24/02/2024

U/S. WHOLE ABDOMEN

- LIVER** : Liver is normal in size, **Diffuse increased echogenicity of liver parenchyma - Grade I fatty liver.** Intra hepatic biliary radicals are normal. Portal venous channels are normal.
- G. B.** : Gall bladder is normal in size, lumen is clear. Wall thickness normal.
- C.B.D.** : C.B.D. is normal in caliber.
- PANCREAS** : Pancreas is normal in size, shape and echotexture. No evidence of any inflammatory disease or mass.
- SPLEEN** : Spleen is normal in size, shape and echotexture.
- Rt. KIDNEY** : Normal in size, shape and echotexture. Renal sinus is normal
Cortico medullary differentiation is normal. P. C. system is normal.
Right renal cortical largest cyst of size 25x21mm at upper pole.
- Lt. KIDNEY** : Normal in size, shape and echotexture. Renal sinus is normal
Cortico medullary differentiation is normal. P. C. system is normal.
- URI. BLADDER** : Urinary bladder is normal in size, position. Wall thickness normal.
- PROSTATE** : **Prostate is enlarged measuring approx 32X48X37mm vol-30.4cc.**
No ascites & retro peritoneal lymphadenopathy seen.

IMPRESSION :

GRADE I FATTY LIVER.

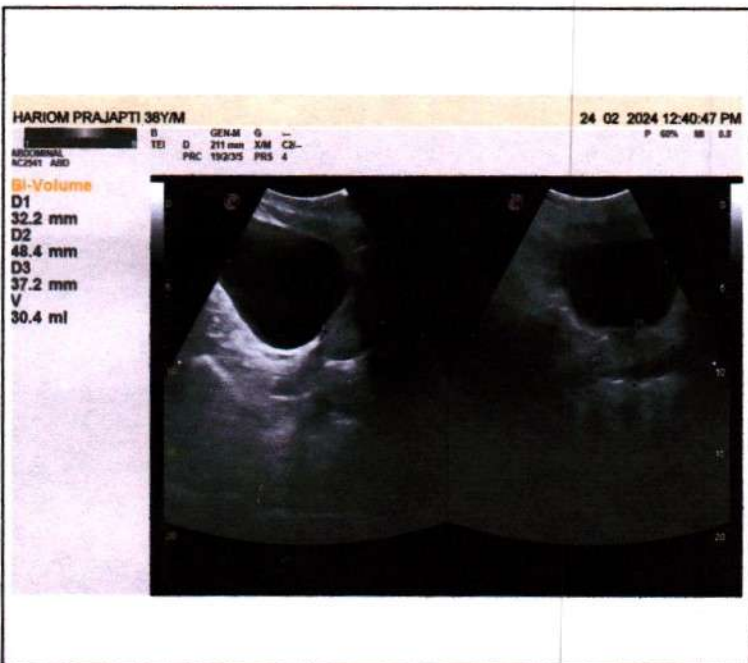
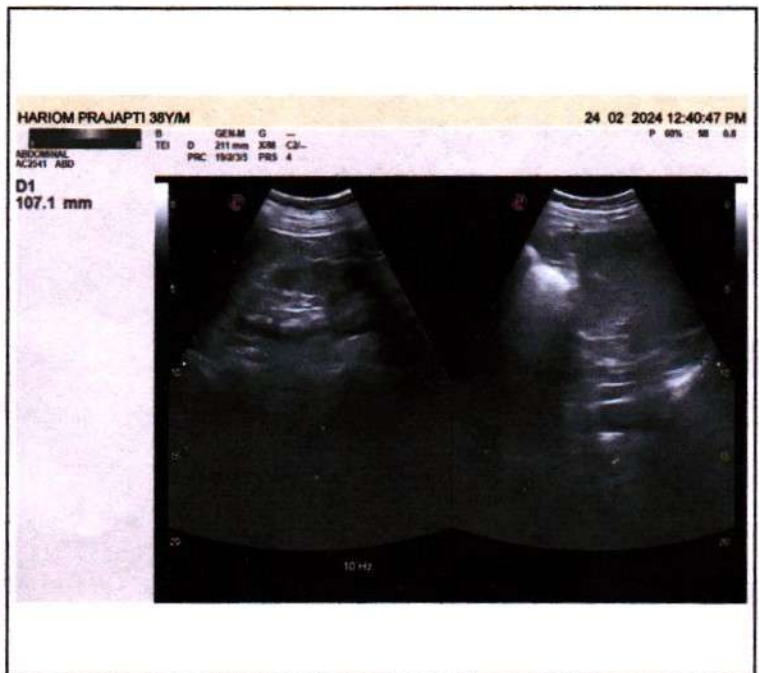
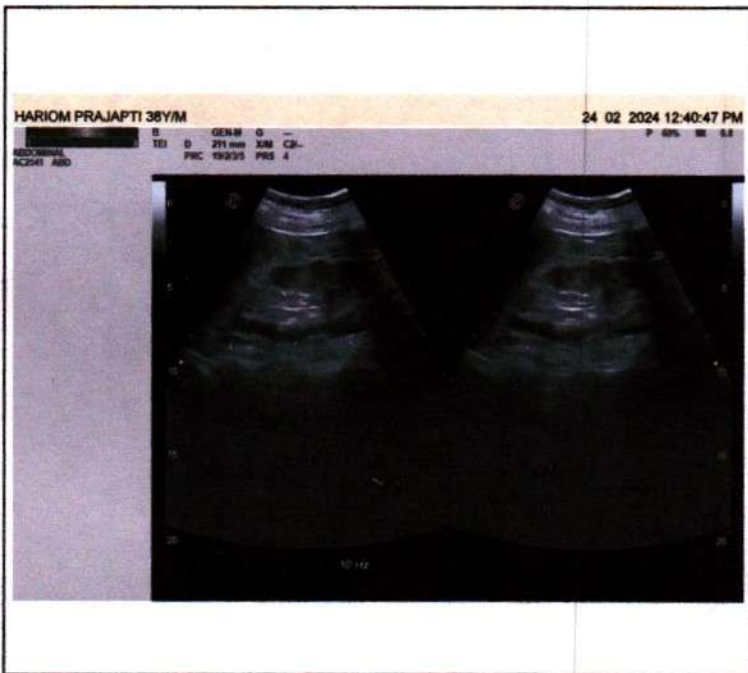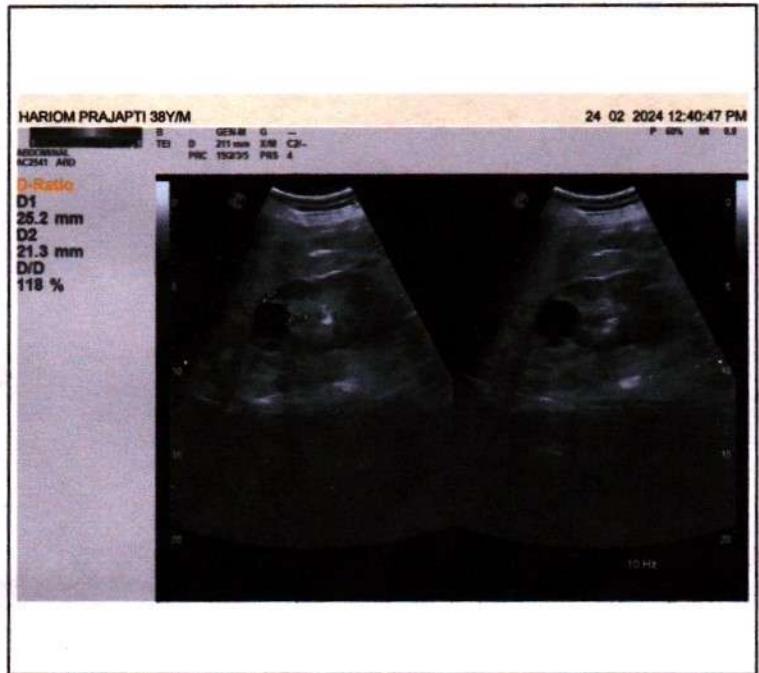
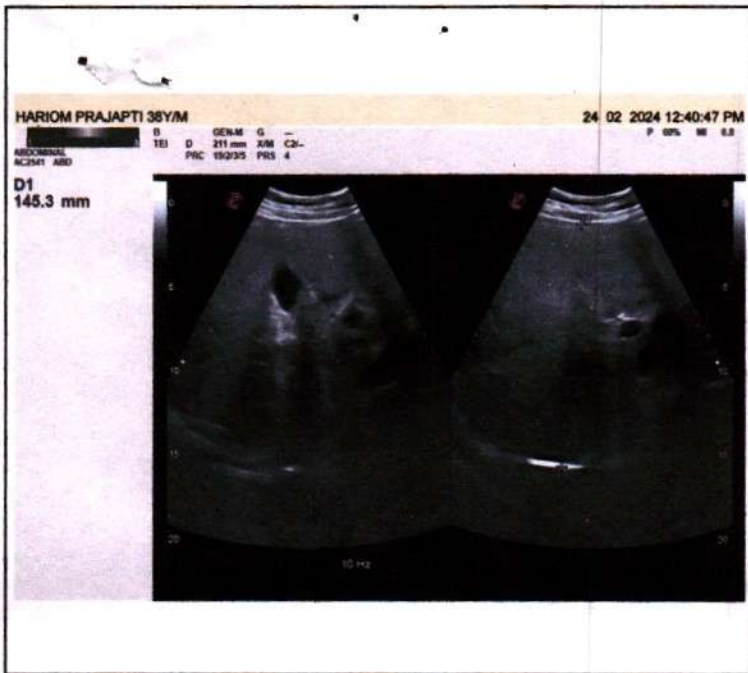
RIGHT RENAL SIMPLE CYST (BOSNIAK I)

Thanks for reference.

Sanologist
Dr. Rahul Kumar Tiwan
MBBS, MD (Radio Diagonosi-
Reg. No. 57557

Disclaimer: This report is not valid for Madicolegal or Judicial Purpose. Radiological diagnosis is solely interpretation of images produced by tissue & may not be always conclusive.

Address : B36/44 B4 Kabir Nagar (Near Sanjay Shiksha Niketan), Durgakund, Varanasi
Mobile : 9554572190 / 9453837595 / Recpn, 9389994334
Email : dramishra@gmail.com, drpallaviojha@gmail.com, Website : www.paire.org



BPL-12

AUTO 10mm/mV

10mm/mV

aVR

aVL

aVF

10mm/mV

V1

V2

V3

10mm/mV

V4

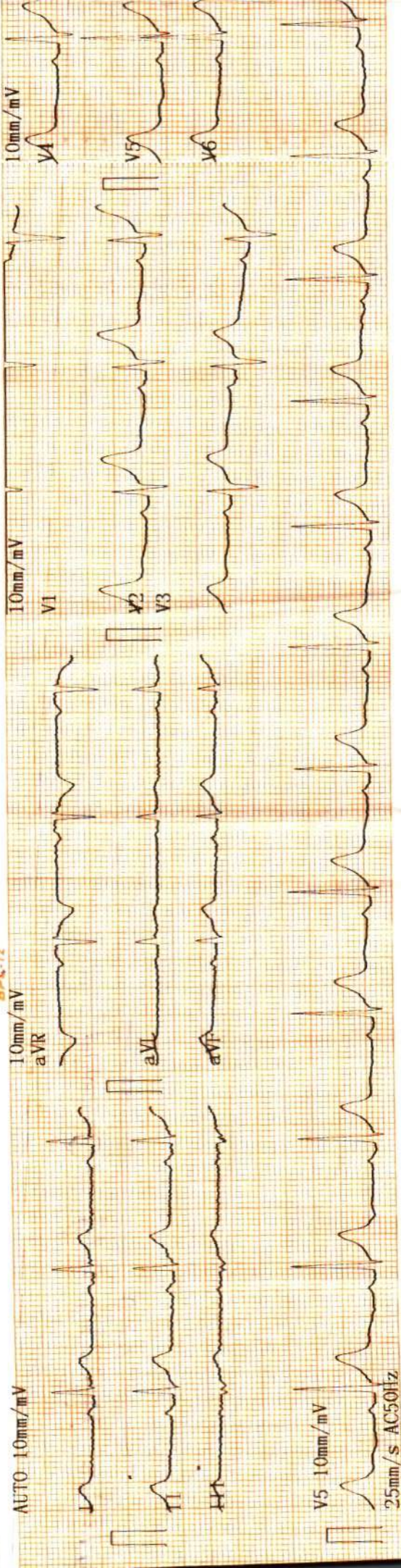
V5

V6

V5 10mm/mV

25mm/s AC50Hz

ARDIART



2024-02-24 13:18

<< Conclusions >>

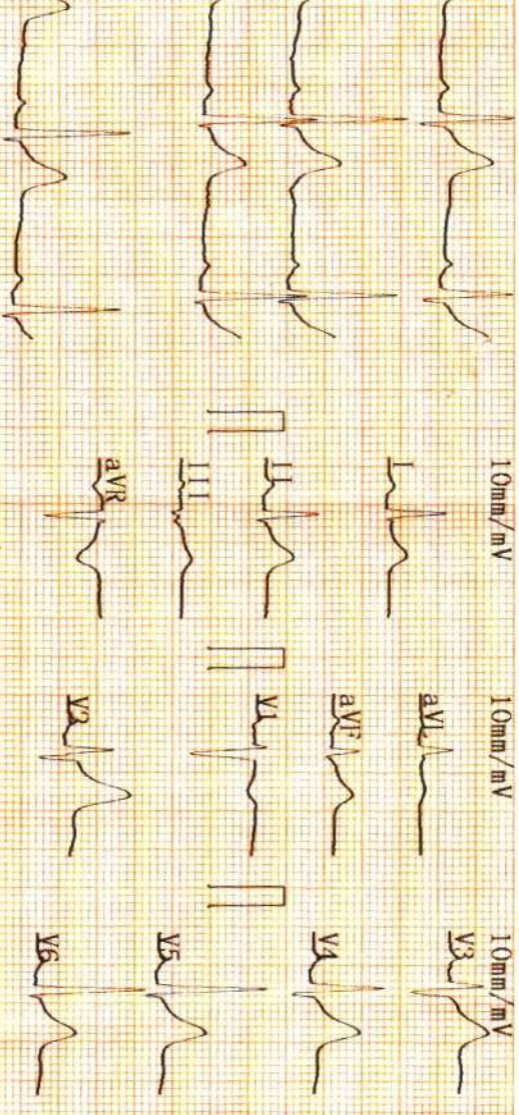Normal Sinus Rhythm;

Longitudinal Left axis deviation.

Age : 36 Weight: 68 kg **Report need physical confirm**

ID :
 Name : Hareem
 Sex : M.
 Height : 165
 SYS :
 DIA :

HR	bpm	: 66
PR Interval	ms	: 179
P Duration	ms	: 109
QRS Duration	ms	: 75
T Duration	ms	: 184
QT/QTc	ms	: 342/358
P/QRS/T Axis	deg	: 35.5/18.5/49.4
R(V5)/S(V1)	mV	: 1.46/0.84
R(V5)+S(V1)	mV	: 2.30



CARDIART

25mm/s

Dr. Pallavi Misa
 DR. Pallavi Misa
 MD (GENERAL MEDICINE)
 MBBS Physist Reg. No. 5203