



# PANACEA HOSPITAL

B 36/44 F.K KABIR NAGAR, DURGAKUND  
TOLLFREE NO-18001233070. Whatsapp No - 8795832852  
www.piire.org  
panaceaquery@gmail.com|panaceahospital@gmail.com



## OP Slip

Print Date : 15-Nov-2024 11:36AM



<b>UHID No</b>	:- UD-24250004382	<b>OP No</b>	:- OP-24250013048	<b>OP Date</b>	:- 15 Nov 2024 11:36AM
<b>Patient Name</b>	:- Mr SHASHI KANT KUMAR	<b>Age/Sex</b>	:- 37 Y/Male	<b>Mobile No</b>	:- 8210539694
<b>Father</b>	:- BHANU CHAUDHARY	<b>Department</b>	:- OPHTHALMOLOGY		
<b>Pay Type</b>	:- Cr	<b>Consultant</b>	:- Dr SANTOSH VERMA (MBBS,MS)		
<b>Token No</b>	:- NOR - 3	<b>Paid</b>	:- 0.00		
<b>Patient Type</b>	:- Normal				
<b>Address</b>	:- SANJHAULI ROHTAS -802220,BIHAR				

BP :- 110/70  
 height :- 166  
 Weight (kg) :- 67.2  
 BMI :- 24.38

Rx

VA  $\left\{ \begin{array}{l} 6/6 \\ 6/6 \end{array} \right.$

Near  $\left\{ \begin{array}{l} NG \\ NG \end{array} \right.$

PR - 87  
 SpO2 - 98  
 NE - 34  
 WC - 96  
 PEFr - 400  
 PR - 87

BE - fundus c/wvl

Locally OE.

I.G. Clear Eye - TOS.  
OVD

Printed By : Ms. Anjali Prajapati  
Created By : Ms. Anjali Prajapati

Dr. SANTOSH VERMA  
 MBBS, MS (Ophthalmologist)  
 MCI Reg. No. 09-34327



# PANACEA HOSPITAL

B 36/44 F.K KABIR NAGAR, DURGAKUND  
TOLLFREE NO-18001233070. Whatsapp No - 8795832852  
www.pilre.org  
panaceaquery@gmail.com|panaceahospital@gmail.com



## OP Slip

Print Date : 15-Nov-2024 11:35AM



<b>UHID No</b>	:- UD-24250004382	<b>OP No</b>	:- OP-24250013045	<b>OP Date</b>	:- 15 Nov 2024 11:34AM
<b>Patient Name</b>	:- Mr SHASHI KANT KUMAR	<b>Age/Sex</b>	:- 37 Y/Male	<b>Mobile No</b>	:- 8210539694
<b>Father</b>	:- BHANU CHAUDHARY	<b>Department</b>	:- GENERAL MEDICINE		
<b>Pay Type</b>	:- Cr	<b>Consultant</b>	:- Dr Pallavi Mishra (MBBS,MD,MBBS)		
<b>Token No</b>	:- NOR - 4	<b>Paid/Bal</b>	:- 0.00 /1030.00		
<b>Patient Type</b>	:- Normal				
<b>Address</b>	:- SANJHAULI ROHTAS -802220,BIHAR				

BP :- 110/70  
height :- 166  
Weight (kg) :- 67.2  
BMI :- 24.38

Rx

SPO2 - 98  
NC - 34  
WE - 96  
PEFR - 400  
PR - 87

Rx  
tab Anti inferno 20  
tab Rabonic - L 02  
tab Nutripure B12 20

R/A 2 month

*Pallavi Mishra*  
**Dr. Pallavi Mishra**  
MBBS, MD (General Medicine)  
MCI Reg. No. 52033

Printed By : Ms. Anjali Prajapati  
Created By : Ms. Anjali Prajapati



# PANACEA HOSPITAL

B 36/44 F.K KABIR NAGAR, DURGAKUND  
TOLLFREE NO-18001233070. Whatsapp No - 8795832852  
www.piire.org  
panaceaquery@gmail.com|panaceahospitalit@gmail.com



## OP Slip

Print Date : 15-Nov-2024 11:35AM



UHID No :- UD-24250004382	OP No :- OP-24250013046	OP Date :- 15 Nov 2024 11:35AM
Patient Name :- Mr SHASHI KANT KUMAR	Age/Sex :- 37 Y/Male	Mobile No :- 8210539694
Father :- BHANU CHAUDHARY	Department :- DENTAL	
Pay Type :- Cr	Consultant :- Dr SHRUTI MISHRA (AA)	
Token No :- NOR - 5	Paid :- 0.00	
Patient Type :- Normal		
Address :- SANJHAULI ROHTAS -802220,BIHAR		

BP :- 110/70  
height :- 166  
Weight (kg) :- 67.2  
BMI :- 24.38

Rx (c => patient came for routine dental check up

O/E => stains/calculus - ++/++

I/O => Chronic gen gingivitis

SpO2 - 98  
NC - 34  
Wc - 26  
PEFR - 400  
PR - 87

*Shruti*  
**Dr. SHRUTI MISHRA**  
BDS, (DENTIST)  
MCI Reg. No. (A-09784)

Printed By : Ms. Anjali Prajapati  
Created By : Ms. Anjali Prajapati



# PANACEA HOSPITAL

B 36/44 F.K KABIR NAGAR, DURGAKUND  
TOLLFREE NO-18001233070. Whatsapp No - 8795832852  
www.piire.org  
panaceaquery@gmail.com|panaceahospitalit@gmail.com



## OP Slip

Print Date : 15-Nov-2024 11:36AM



UHID No :-	UD-24250004382	OP No :-	OP-24250013047	OP Date :-	15 Nov 2024 11:35AM
Patient Name :-	Mr SHASHI KANT KUMAR	Age/Sex :-	37 Y/Male	Mobile No :-	8210539694
Father :-	BHANU CHAUDHARY	Department :-	DERMATOLOGY		
Pay Type :-	Cr	Consultant :-	Dr DR. ASHUTOSH MISHRA (MBBS,MD)		
Token No :-	NOR - 5	Paid :-	0.00		
Patient Type :-	Normal				
Address :-	SANJHAULI ROHTAS -802220,BIHAR				

BP :- 110/70  
height :- 166  
Weight (kg) :- 67.2  
BMI :- 24.38  
SpO2-98  
NC-34  
WC-36  
PEFR-400  
PR-87

Rx

Rx (Hyperhydrosis lotion)  
H:ft lotion →

QID  
x 2 days

As  
Q. Total 2 days

2 days



Printed By : Ms. Anjali Prajapati  
Created By : Ms. Anjali Prajapati

**Facilities:**

All clinical Biomedical & Hematology Investigations including Bone Marrow Examination  
 VPT, Podiascan & Complete Foot Care (First Time in Purvanchal)  
 All Hormonal Investigation by Chemiluminescent Method  
 Visceral Fat by (AB-140) Ambulatory BP Monitoring  
 CGMS & Insulin Pump Available  
 PFT, 2D-ECHO (Color Doppler), Holter, TMT, Cardiac-3 available  
 VIA, VILI, Colposcopy available  
 Special Endocrinological Investigation Protocols.

ISO 9001:2008 Certified

Mobile: 9389994334, 9554572190, 9453837595

**Panacea Pathology****Clinical Reference Lab**

Persistence, Preparedness and Precision  
 EQAS (CMC Vellore Attached) & IQAS System  
 पूर्वांचल की सर्वोत्तम गुणवत्ता वाली पैथोलॉजी

**UHID No** :- UD-24250004382 **Booking No/Date** :- 66 / 15-Nov-2024 01:18 PM  
**Patient Name** :- Mr SHASHI KANT KUMAR **Age/Sex** :- 37 YM  
**Father** :- BHANU CHAUDHARY **Reg No** :- 24250004382  
**Address** :- SANJHAULI ROHTAS -802220, BIHAR **Mobile No** :- 8210539694  
**Consultant** :- Dr ASHUTOSH MISHRA (MD)(MEDICINE),IMS,BHU)

Investigations	Observations	Biological Ref. Interval	Unit
----------------	--------------	--------------------------	------

**HAEMATOLOGY****CBC****HAEMOGLOBIN**

DefaultMethod / test Machine

15.3

13.00 - 16.00

gm/dl

**TLC**

Methodology / Carry

6400

4000.00 - 11000.00

Cells/cumm.

**DLC DIFFERENTIAL LEUCOCYTE COUNT**

NEUTROPHILS

**38**

40.00 - 75.00

%

LYMPHOCYTES

**51**

20.00 - 45.00

%

EOSINOPHILS

06

1.00 - 6.00

%

MONOCYTES

05

2.00 - 10.00

%

BASOPHILS

00

&lt;1-2

%

**PLATELET COUNT**

1.78

1.50 - 4.10

lacs /cumm

**PCV****46.9**

33.00 - 42.00

%

**RBC**

Methodology / Carry

4.96

4.50 - 5.50

million/cumm

**MCV(MEAN CELL VOLUME)**

94.4

83.00 - 101.00

fl

**MCH(MEAN CELL HAEMOGLOBIN)**

30.9

27.00 - 32.00

pg

**MCHC**

32.7

31.50 - 35.00

gm%

**RDW-CV**

13.7

11.00 - 16.00

%

**RDW-SD**

52.6

37.00 - 57.00

fl

Consulting Pathologist  
**Dr. UMESH KUMAR**

Diplomist (Pathologist)

MCI Reg. Pathology 413

**Lab Technician**

Timing : 24/7 hrs

This Report is not valid for medico legal purpose

Note: These tests have technical limitations. Clinico-pathological interpretation is necessary. In case of any disparity test may be repeated immediately.

Address : 36/44 FK Kabir Nagar, Durgakund, Varanasi - 221005

Email: [dramishra@gmail.com](mailto:dramishra@gmail.com), [drpallaviojha@gmail.com](mailto:drpallaviojha@gmail.com) Website: [panaceahospital.org](http://panaceahospital.org)

**Facilities:**

All clinical Biomedical & Hematology Investigations including Bone Marrow Examination  
 VPT, Podiascan & Complete Foot Care (First Time in Purvanchal)  
 All Hormonal Investigation by Chemiluminescent Method  
 Visceral Fat by (AB-140) Ambulatory BP Monitoring  
 CGMS & Insulin Pump Available  
 PFT, 2D-ECHO (Color Doppler), Holter, TMT, Cardiac-3 available  
 VIA, VILI, Colposcopy available  
 Special Endocrinological Investigation Protocols.

ISO 9001:2008 Certified

Mobile: 9389994334, 9554572190, 9453837595

**Panacea Pathology****Clinical Reference Lab**

Persistence, Preparedness and Precision  
 EQAS (CMC Vellore Attached) & IQAS System  
 पूर्वांचल की सर्वोत्तम गुणवत्ता वाली पैथोलॉजी

**UHID No** :- UD-24250004382 **Booking No/Date** :- 66 / 15-Nov-2024 01:18 PM  
**Patient Name** :- Mr SHASHI KANT KUMAR **Age/Sex** :- 37 YM  
**Father** :- BHANU CHAUDHARY **Reg No** :- 24250004382  
**Address** :- SANJHAULI ROHTAS -802220, BIHAR **Mobile No** :- 8210539694  
**Consultant** :- Dr ASHUTOSH MISHRA (MD(MEDICINE),IMS,BHU)

Investigations	Observations	Biological Ref. Interval	Unit
----------------	--------------	--------------------------	------

**URINE EXAMINATION****URINE ROUTINE EXAMINATION****PHYSICAL EXAMINATION**

QUANTITY 25 ml

COLOR STRAW CLEAR YELLOW  
Methodology

APPEARANCE CLEAR CLEAR  
DefaultMethod

**CHEMICAL EXAMINATION**

SPECIFIC GRAVITY 1.010 1.01 - 1.03

PH 5.0 4.60 - 8.00

GLUCOSE NIL 60.00 - 100.00 mg/dl

PROTEIN- NIL

**MICROSCOPIC EXAMINATION**

PUS CELLS NIL 2.00 - 3.00 /HPF

RBCS ( RED BLOOD CELLS) NIL 4.50 - 5.50 /HPF

EPITHELIAL CELLS 01-02 /HPF

CASTS ABSENT ABSENT

CRYSTALS ABSENT ABSENT

Consulting Pathologist\*  
**Dr. UMESH KUMAR**  
 Dr. Umesh Kumar  
 MBBS, MD (Pathologist)  
 M.D. Pathology  
 MCI REG. NO. 41413

Lab Technician

Timing : 24/7 hrs

This Report is not valid for medico legal purpose

Note: These tests have technical limitations. Clinico-pathological interpretation is necessary. In case of any disparity test may be repeated immediately.

Address : 36/44 FK Kabir Nagar, Durgakund, Varanasi – 221005

Email: [dramishra@gmail.com](mailto:dramishra@gmail.com), [drpallaviojha@gmail.com](mailto:drpallaviojha@gmail.com) Website: [panaceahospital.org](http://panaceahospital.org)

**Facilities:**

All clinical Biomedical & Hematology Investigations including Bone Marrow Examination  
 VPT, Podiascan & Complete Foot Care (First Time in Purvanchal)  
 All Hormonal Investigation by Chemiluminescent Method  
 Visceral Fat by (AB-140) Ambulatory BP Monitoring  
 CGMS & Insulin Pump Available  
 PFT, 2D-ECHO (Color Doppler), Holter, TMT, Cardiac-3 available  
 VIA, VILI, Colposcopy available  
 Special Endocrinological Investigation Protocols.

ISO 9001:2008 Certified  
 Mobile: 9389994334, 9554572190, 9453837595



# Panacea Pathology

## Clinical Reference Lab

Persistence, Preparedness and Precision  
 EQAS (CMC Vellore Attached) & IQAS System  
 पूर्वांचल की सर्वोत्तम गुणवत्ता वाली पैथोलॉजी

**UHID No** :- UD-24250004382 **Booking No/Date** :- 66 / 15-Nov-2024 01:18 PM  
**Patient Name** :- Mr SHASHI KANT KUMAR **Age/Sex** :- 37 Y/M  
**Father** :- BHANU CHAUDHARY **Reg No** :- 24250004382  
**Address** :- SANJHAULI ROHTAS -802220, BIHAR **Mobile No** :- 8210539894  
**Consultant** :- Dr ASHUTOSH MISHRA (MD(MEDICINE),IMS,BHU)

Investigations	Observations	Biological Ref. Interval	Unit
----------------	--------------	--------------------------	------

### HAEMATOLOGY

HBA1C -(BY GOLD STANDARD METHOD :HPLC)	5.1	Normal: 4.0 - 5.4 Prediabetic : 5.5 -6.3 Diabetes mellitus := 6.4	%
ESR	12.0	0.00 - 15.00	mm at 1 hr

### IMMUNOLOGY

#### THYROID PROFILE (T3,T4,TSH)

T3	1.02	0.60 - 1.81	ng/ml
T4	8.2	4.50 - 10.90	ug/dl
TSH	2.67	0.39 - 6.10	uIU/mL

### BIOCHEMISTRY

#### LFT (LIVER FUNCTION TESTS)

TOTAL BILIRUBIN	0.72	0.00 - 1.20	mg/dl
DIRECT BILIRUBIN	0.22	0.00 - 0.30	
INDIRECT BILIRUBIN	0.50	0.20 - 0.70	mg/dl
SGOT	21.0	2.00 - 31.00	U/L
SGPT	29.0	10.00 - 45.00	U/L
ALKALINE PHOSPHATASE	68.0	25.00 - 140.00	U/L
TOTAL PROTIENS	7.21	6.60 - 8.70	g/dl

Lab Technician

Timing : 24/7 hrs

This Report is not valid for medico legal purpose

Note: These tests have technical limitations. Clinico-pathological interpretation is necessary. In case of any disparity test may be repeated immediately.

Address : 36/44 FK Kabir Nagar, Durgakund, Varanasi – 221005

Email: [dramishra@gmail.com](mailto:dramishra@gmail.com), [drpallaviojha@gmail.com](mailto:drpallaviojha@gmail.com) Website: [panaceahospital.org](http://panaceahospital.org)

Consulting Pathologist  
**Dr. UMESH KUMAR**  
 Dr. Umesh Kumar  
 MBBS, MD (Pathologist)  
 M.D. Pathology  
 Reg. No. 41413

**Facilities:**

All clinical Biomedical & Hematology Investigations including Bone Marrow Examination  
 VPT, Podiascan & Complete Foot Care (First Time in Purvanchal)  
 All Hormonal Investigation by Chemiluminescent Method  
 Visceral Fat by (AB-140) Ambulatory BP Monitoring  
 CGMS & Insulin Pump Available  
 PFT, 2D-ECHO (Color Doppler), Holter, TMT, Cardiac-3 available  
 VIA, VILI, Colposcopy available  
 Special Endocrinological Investigation Protocols.

ISO 9001:2008 Certified

Mobile: 9389994334, 9554572190, 9453837595



# Panacea Pathology

## Clinical Reference Lab

Persistence, Preparedness and Precision  
 EQAS (CMC Vellore Attached) & IQAS System  
 पूर्वांचल की सर्वोत्तम गुणवत्ता वाली पैथोलॉजी

**UHID No** :- UD-24250004382 **Booking No/Date** :- 66 / 15-Nov-2024 01:18 PM  
**Patient Name** :- Mr SHASHI KANT KUMAR **Age/Sex** :- 37 YM  
**Father** :- BHANU CHAUDHARY **Reg No** :- 24250004382  
**Address** :- SANJHAULI ROHTAS -802220, BIHAR **Mobile No** :- 8210539894  
**Consultant** :- Dr ASHUTOSH MISHRA (MD(MEDICINE),IMS,BHU)

Investigations	Observations	Biological Ref. Interval	Unit
ALBUMIN	4.10	3.50 - 5.20	gm%
GLOBULIN	3.11	1.50 - 3.60	gms/dl
A/G RATIO	1.31	2:1	RATIO
<b>RFT (RENAL FUNCTION TESTS)</b>			
SERUM CREATININE	0.79	0.60 - 1.60	mg/dl
URIC ACID	3.92	3.60 - 7.70	mg/dl
<b>LIPID PROFILE</b>			
TOTAL CHOLESTROL	164.0	Desirable : - &lt; 200 mg/dL Borderline: - 200 - 239 mg/dL High : - &gt; 240mg/dL	mg/dl
TRIGLYCERIDES	148.0	35.00 - 160.00	mg/dl
HDL CHOLESTROL	41.0	35.30 - 79.50	mg/dl
LDL CHOLESTROL	93.4	&lt;130	mg/dl
VLDL	29.60	&lt;40	mg/dl
CHOLESTROL/ HDL RATIO	4.00	&lt;3.0 LOW RISK, 3.0-5.0 AVG RISK, &gt;5.0 HIGH RISK	ratio
LDL/HDL RATIO	2.28	&lt;3	ratio

**BIOCHEMISTRY****BLOOD SUGAR FASTING**

Lab Technician

Consulting Pathologist  
**Dr. UMESH KUMAR**  
 Dr. Umesh Kumar  
 MBBS, MD (Pathologist)  
 M.D. Pathology  
 MCI Reg. No. 41493

Timing : 24/7 hrs

This Report is not valid for medico legal purpose

Note: These tests have technical limitations. Clinico-pathological interpretation is necessary. In case of any disparity test may be repeated immediately.

Address : 36/44 FK Kabir Nagar, Durgakund, Varanasi - 221005

Email: [dramishra@gmail.com](mailto:dramishra@gmail.com), [drpallaviojha@gmail.com](mailto:drpallaviojha@gmail.com) Website: [panaceahospital.org](http://panaceahospital.org)



**Facilities:**

All clinical Biomedical & Hematology Investigations including Bone Marrow Examination  
 VPT, Podiascan & Complete Foot Care (First Time in Purvanchal)  
 All Hormonal Investigation by Chemiluminescent Method  
 Visceral Fat by (AB-140) Ambulatory BP Monitoring  
 CGMS & Insulin Pump Available  
 PFT, 2D-ECHO (Color Doppler), Holter, TMT, Cardiac-3 available  
 VIA, VILI, Colposcopy available  
 Special Endocrinological Investigation Protocols.

ISO 9001:2008 Certified

Mobile: 9389994334, 9554572190, 9453837595

**Panacea Pathology****Clinical Reference Lab**

Persistence, Preparedness and Precision  
 EQAS (CMC Vellore Attached) & IQAS System  
 पूर्वांचल की सर्वोत्तम गुणवत्ता वाली पैथोलॉजी

**UHID No** :- UD-24250004382 **Booking No/Date** :- 66 / 15-Nov-2024 01:18 PM  
**Patient Name** :- Mr SHASHI KANT KUMAR **Age/Sex** :- 37 Y/M  
**Father** :- BHANU CHAUDHARY **Reg No** :- 24250004382  
**Address** :- SANJHAULI ROHTAS -802220 , BIHAR **Mobile No** :- 8210539694  
**Consultant** :- Dr ASHUTOSH MISHRA (MD(MEDICINE),IMS,BHU)

Investigations	Observations	Biological Ref. Interval	Unit
GLUCOSE	90.0	60.00 - 100.00	mg/dl
PRE-DIABETICS(IMPAIRED FASTING TOLER)	-	100.00 - 125.00	mg/dl
DIABETICS	-	upto 126	mg/dl
TARGET IN DM	-	80.00 - 130.00	mg/dl

**BIOCHEMISTRY****PPBS(POST PRANDIAL BLOOD SUGAR)**

POST PRANDIAL BLOOD GLUCOSE(2 HR AFTER MEAL)	<b>107.0</b>	110.00 - 150.00	mg/dl
IGT(2 HR 75GM GLUCOSE)	-	140.00 - 199.00	mg/dl
DIABETES	-	upto200	mg/dl
TARGET IN DM	-	80.00 - 130.00	mg/dl

\* END OF REPORT \*

Consulting Pathologist

Dr. UMESH KUMAR  
 M.D., Pathologist  
 MCI Reg. No. 41413

Lab Technician

Timing : 24/7 hrs

This Report is not valid for medico legal purpose

Note: These tests have technical limitations. Clinico-pathological interpretation is necessary. In case of any disparity test may be repeated immediately.

Address : 36/44 FK Kabir Nagar, Durgakund, Varanasi – 221005

Email: [dramishra@gmail.com](mailto:dramishra@gmail.com), [drpallaviojha@gmail.com](mailto:drpallaviojha@gmail.com) Website: [panaceahospital.org](http://panaceahospital.org)



# PANACEA HOSPITAL



*A shelter for many hearts A Home for many lives*

(An ISO 9001:2008 Certified Organisation)  
Lab Attached with CMC Under EQAS Scheme

Dept. of Radiodiagnosis - 32 Slice CT Scan, 3D/4D USG, 2D ECHO, Colour Doppler, Intervention Procedures, Digital X-Ray

**NAME: SHASHI KANT KUMAR**  
**REF.DR.ASHUTOSH MISHRA(MD)**

**AGE/SEX: 37 YRS/MALE**  
**DATE: 15/11/2024**

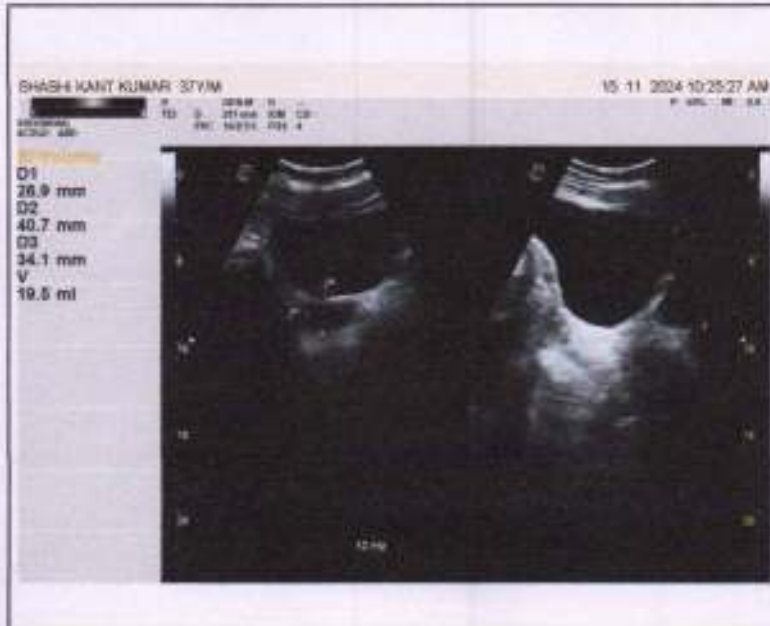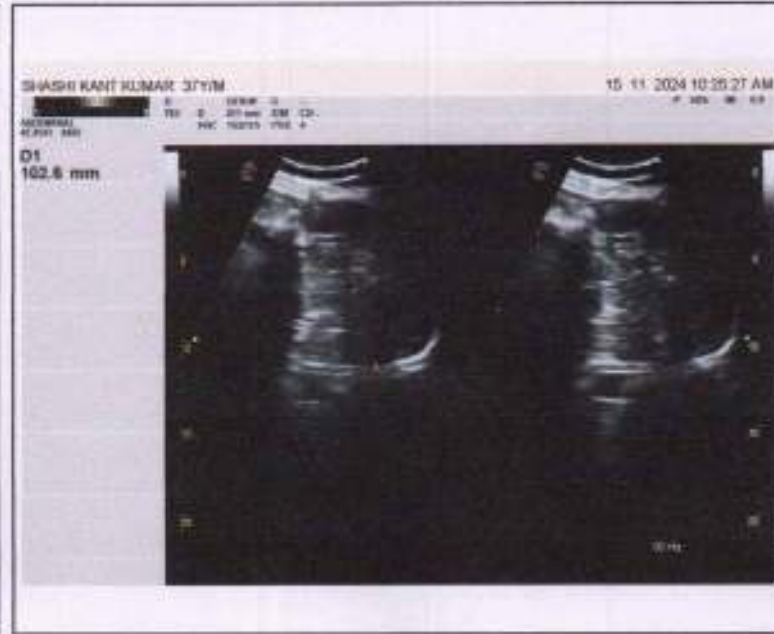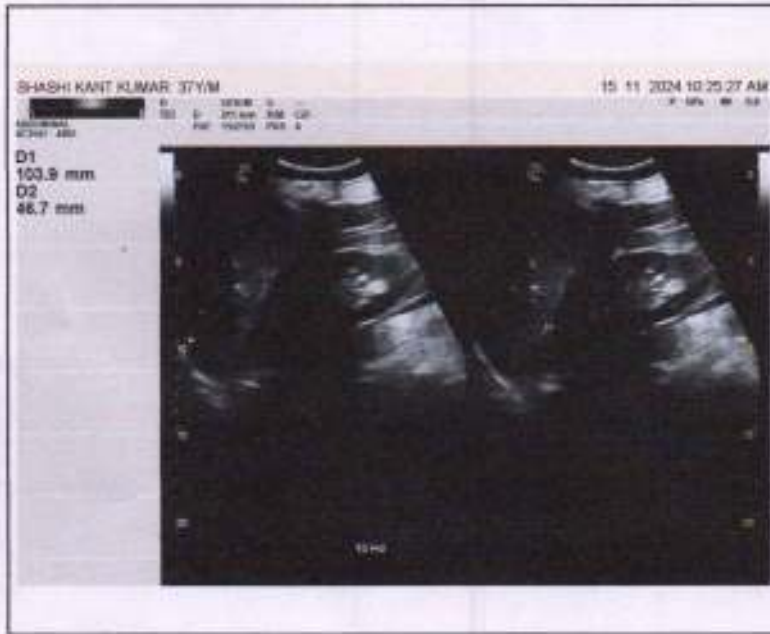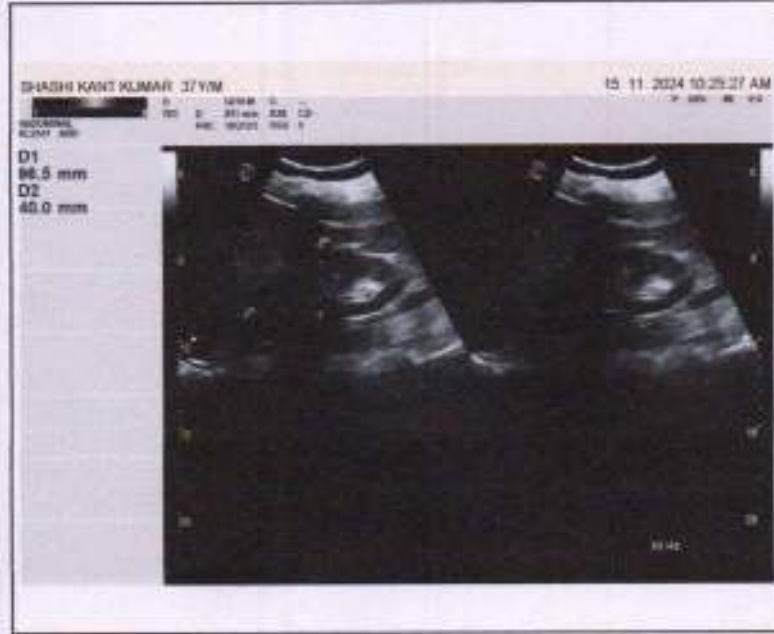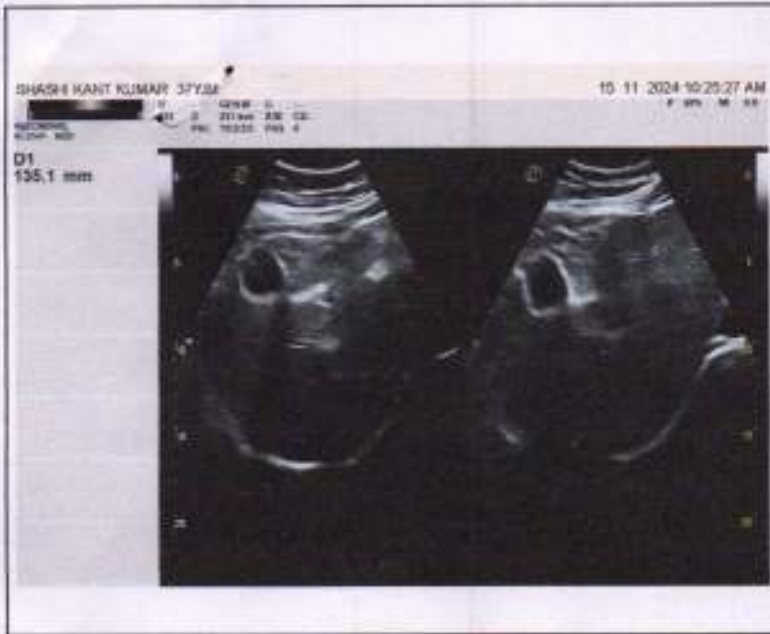## ULTRASOUND WHOLE ABDOMEN REPORT

<b><u>Liver:</u></b>	Normal in size(135mm), shape, & echogenicity. Intra & extra hepatic biliary radicals & vascular structures are normal. Margins are smooth and regular.
<b><u>Gall bladder:</u></b>	Normally distended with echo free lumen.
<b><u>Portal vein:</u></b>	Normal in course and caliber.
<b><u>CBD diameter:</u></b>	Visualized part normal in course & caliber.
<b><u>Pancreas:</u></b>	Normal in size, shape & echogenicity. Margins are smooth & regular. No diffuse/ focal lesion seen. Pancreatic duct not visualized.
<b><u>Spleen:</u></b>	Normal in size, shape & echogenicity. Margins are smooth & regular. No diffuse / focal lesion seen.
<b><u>Kidney:</u></b>	Both normal in size, shape echogenicity & position. Cortical-medullary differentiation is maintained. Pelvicalyceal system normal. No evidence of any calculus/mass lesion seen. No hydronephrosis/ hydroureter seen. No suprarenal mass lesion.
<b><u>Urinary bladder:</u></b>	Normally distended with normal wall thickness. No echogenic foci lumen or diverticula seen. Both VUJ appears normal. No evidence of calculus / mass lesion seen.
<b><u>Prostate:</u></b>	Normal in size(26X40X34mmVol19.5ml), shape & echogenicity.
<b><u>Others:</u></b>	No free fluid in peritoneal cavity. No free fluid in bilateral pleural cavity. No evidence of significantly enlarged retroperitoneal/ mesenteric lymph nodes noted.
<b><u>IMPRESSION: -</u></b>	<b>NO OBVIOUS SONOLOGICAL ABNORMALITY SEEN.</b>

Please correlate clinically and further investigations.

*Sonologist*  
**Dr. Rahul Kumar Tiwari**  
MBBS, MD (Radio Diagnosis)  
MCI Reg. No. 57557

Note: (1) This report is not valid for medico-legal purposes.  
(2) In case of any discrepancy due typing error, please get it Rectified immediately.





# PANACEA HOSPITAL



*A shelter for many hearts A Home for many lives*  
 (An ISO 9001:2008 Certified Organisation)  
 Lab Attached with CMC Under EQAS Scheme

Dept. of Radiodiagnosis - 32 Slice CT Scan, 3D/4D USG, 2D ECHO, Colour Doppler, Intervention Procedures, Digital X-Ray

NAME: SHASHI KANT KUMAR

AGE/SEX: 37YRS/MALE

REF. DR. DR. ASHUTOSH MISHRA (MD)


DATE: 15/11/2024


## Echo - Cardiography

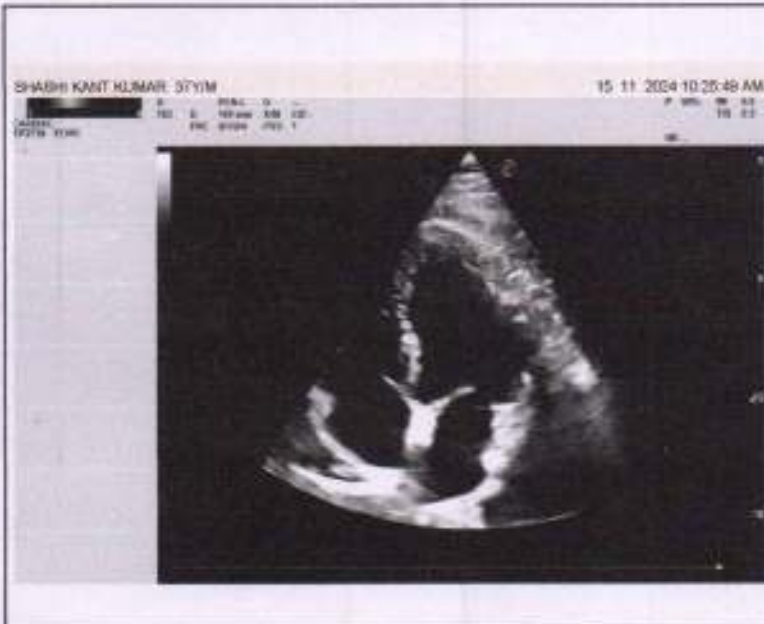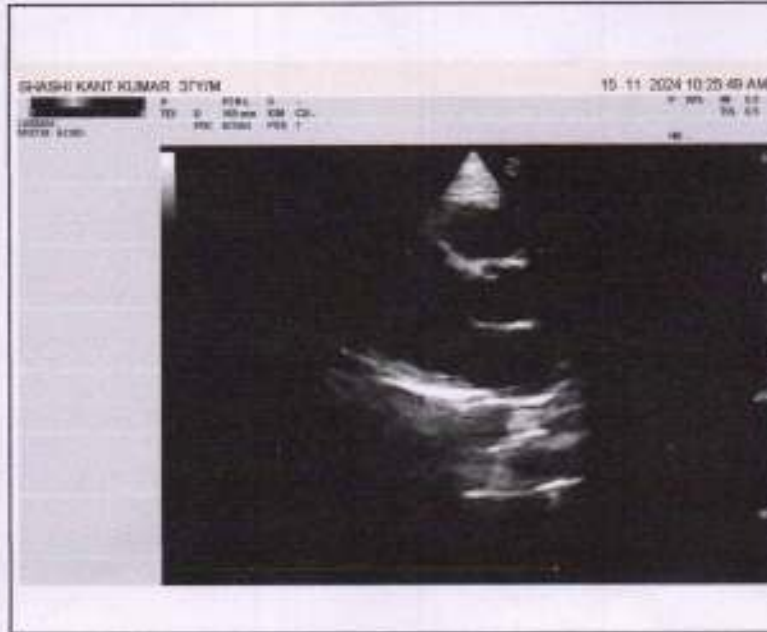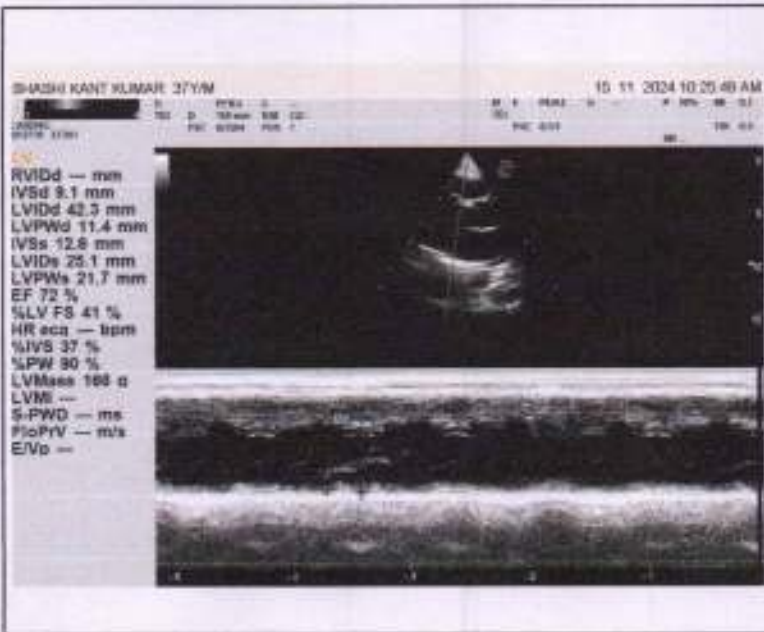
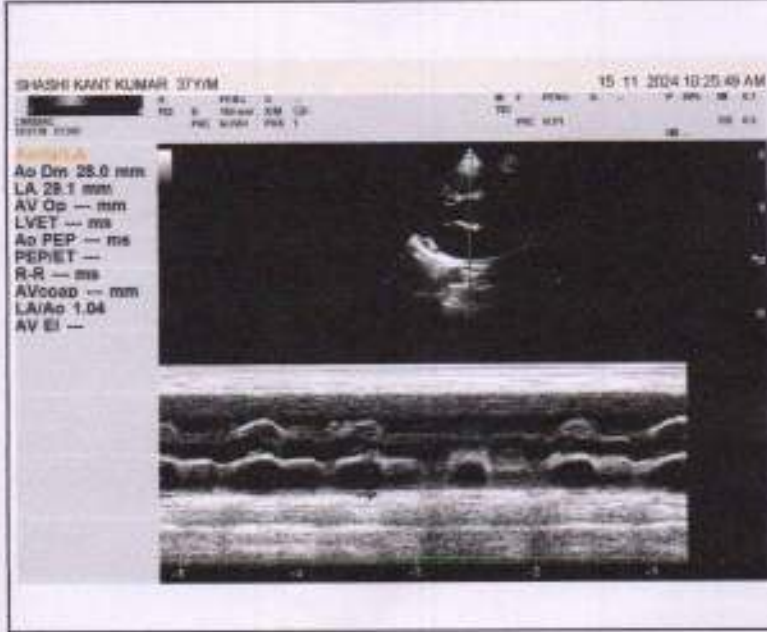
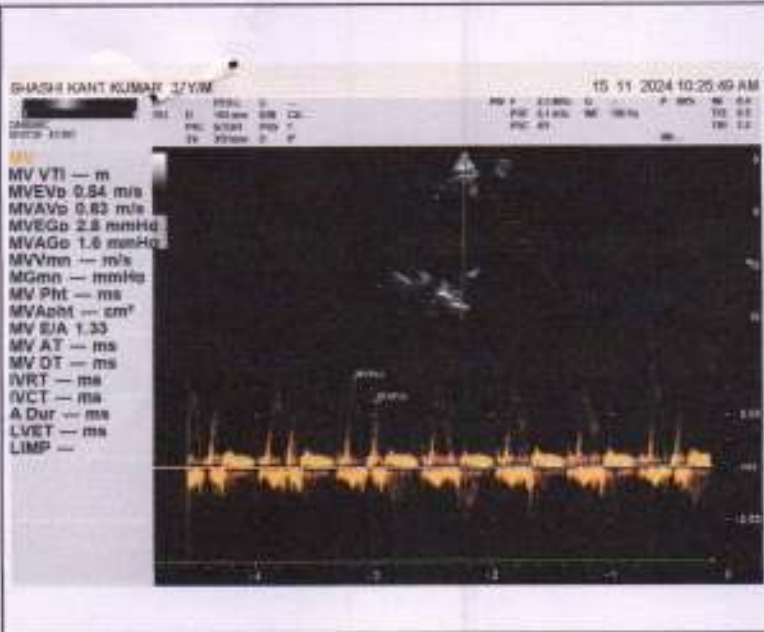
MITRAL VALVE Doppler	AML - normal morphology MV Flow - E - 0.8 A-0.8 E/A=1.33	PML - normal morphology MVA - 3.0 cm <sup>2</sup> Mitral Regurgitation - No
TRICUSPID VALVE Doppler	Normal TV Flow - No	Tricuspid Regurgitation - No
PULMONARY VALVE Doppler	Normal PV Flow - No	Pulmonary Regurgitation - No
AORTIC VALVE Doppler	Trileaflet - No AV Flow - no	Aortic Regurgitation - No
MEASUREMENT	Aorta - 28.0 (20-38) mm IVS ed - 9.1 (6-12) mm LVID ed - 42.3 (35-55) mm LVPW ed - 11.6 (6-12) mm OA - 7 (> 5) mm	LA - 29.1 (24-32) mm IVS es - 12.6 (6-12) mm LVID es - 25.1 (24-40) mm LVPW es - 21.7 (6-12) mm EPSS - 4 (< 9) mm

**CONCLUSION** All cardiac chamber dimensions are WNL  
 No valvular abnormalities  
 Good LV systolic function present Modified Simpson's method (4C, 2C) (LVEF-72%)  
 No diastolic dysfunction present (E/A = 1.33)  
 No pericardial effusion  
 No RWMA  
 Intact IAS / IV  
 No PAH  
 No intra cardiac mass / thrombus / vegetation

**IMPRESSION** Normal Echocardiogram

  
 Niraj Mishra  
 Physician Assistant  
 (PMBE)

  
 Dr. Pankaj Mishra  
 Echocardiography Specialist, MBE  
 MBBS, MD (General Medicine)  
 MCI Reg. No. 52033  
 Durgakund, Varanasi





# PANACEA HOSPITAL



*A shelter for many hearts A Home for many lives*  
(An ISO 9001:2008 Certified Organisation)  
Lab Attached with CMC Under EQAS Scheme

Dept. of Radiodiagnosis - 32 Slice CT Scan, 3D/4D USG, 2D ECHO, Colour Doppler, Intervention Procedures, Digital X-Ray

PATIENT NAME	SHASHI KANT KUMAR	AGE/SEX	37YRS/M
REF. BY DR.	DR. ASHUTSOH MISHRA	DATE	15/11/2024

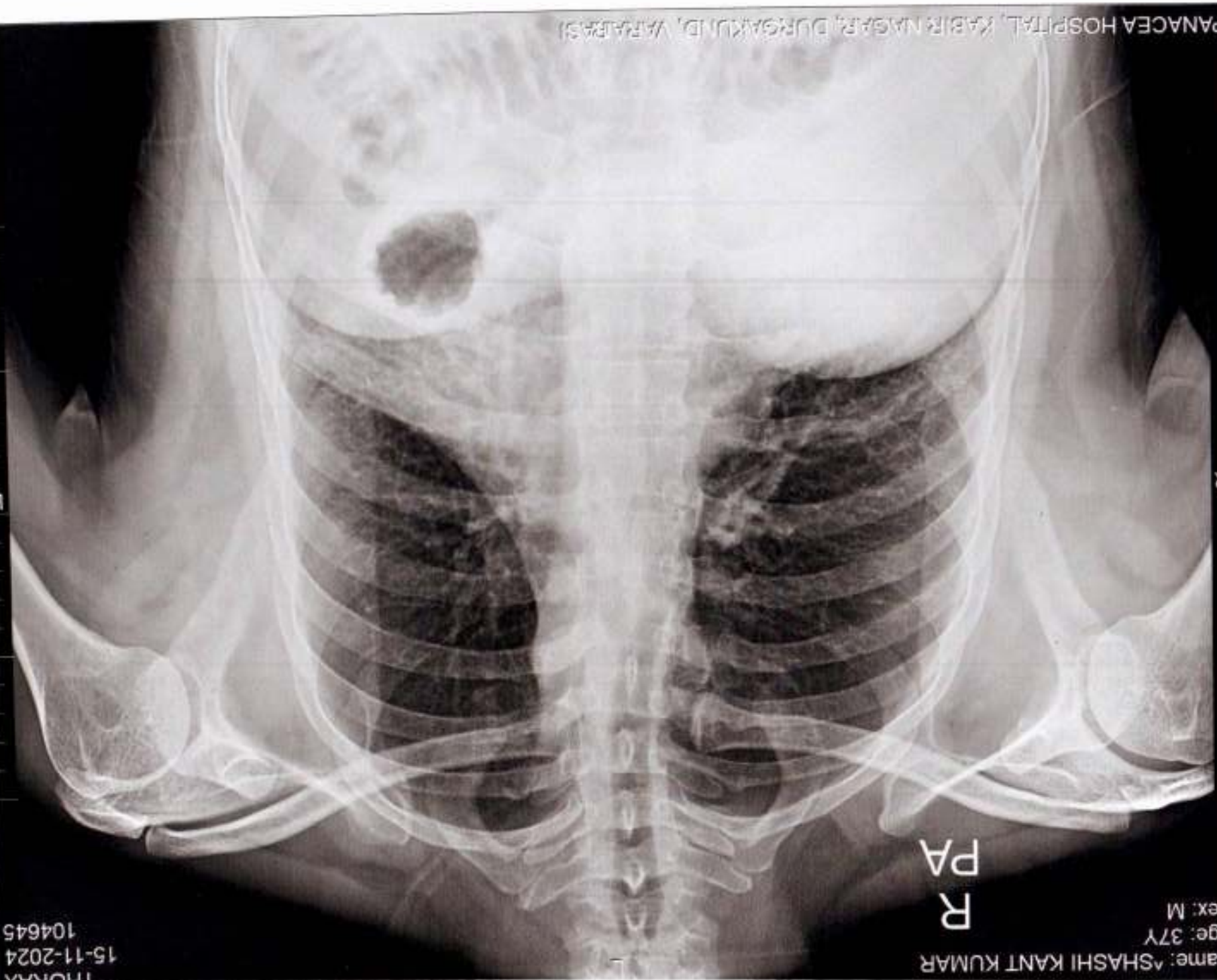
## X-RAY CHEST (AP VIEW)

- Lung fields show hazy opacities in both parahilar, basal zone with mild prominent brochopulmonary markings.
- Rest of the bilateral lung fields appear normal.
- Trachea and mediastinum appear normal in position.
- Both hila appear normal in size and are symmetrical.
- Transverse cardiac diameter is within normal limits.
- Both CP angles appear clear. Normal position and contour diaphragms noted.
- Bony rib cage and soft tissue shadows appear normal.

*Thanks for reference.*

*Radiologist*  
**Dr. Rahul Kumar Tiwari**  
MBBS, MCh (Spillo) Diagnost  
MCI Reg. No. 57557

PANACEA HOSPITAL, KABIR NAGAR, DURGAKUND, VARANASI



R

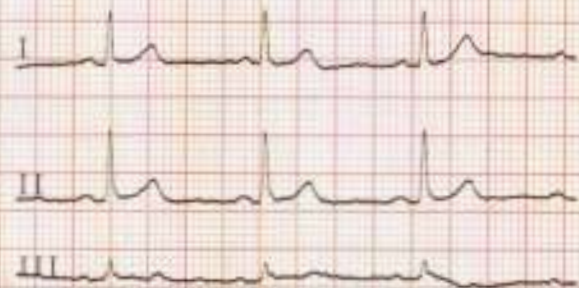PA  
R

Sex: M  
Age: 37Y

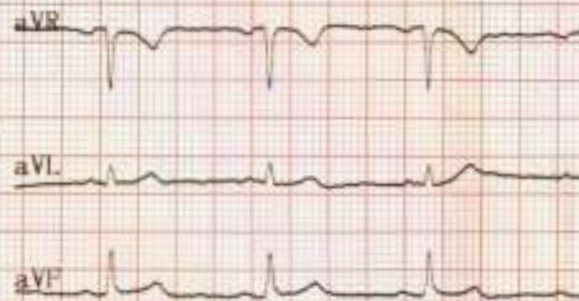Name: SHASHI KANT KUMAR

THORAX  
15-11-2024  
104645

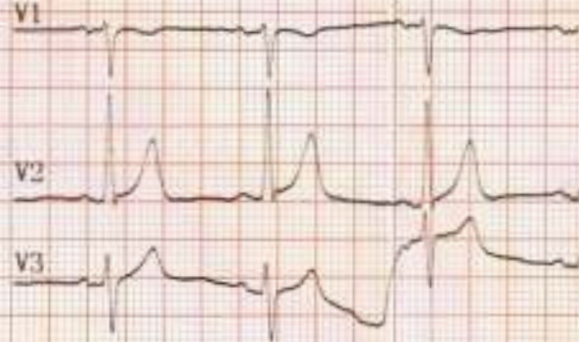AUTO 10mm/mV



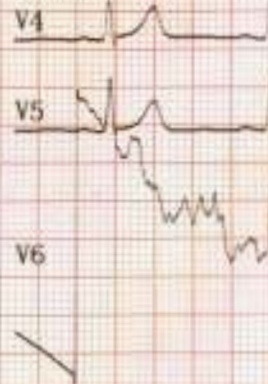10mm/mV



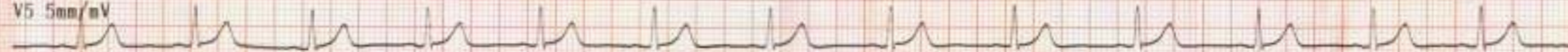
10mm/mV



5mm/mV

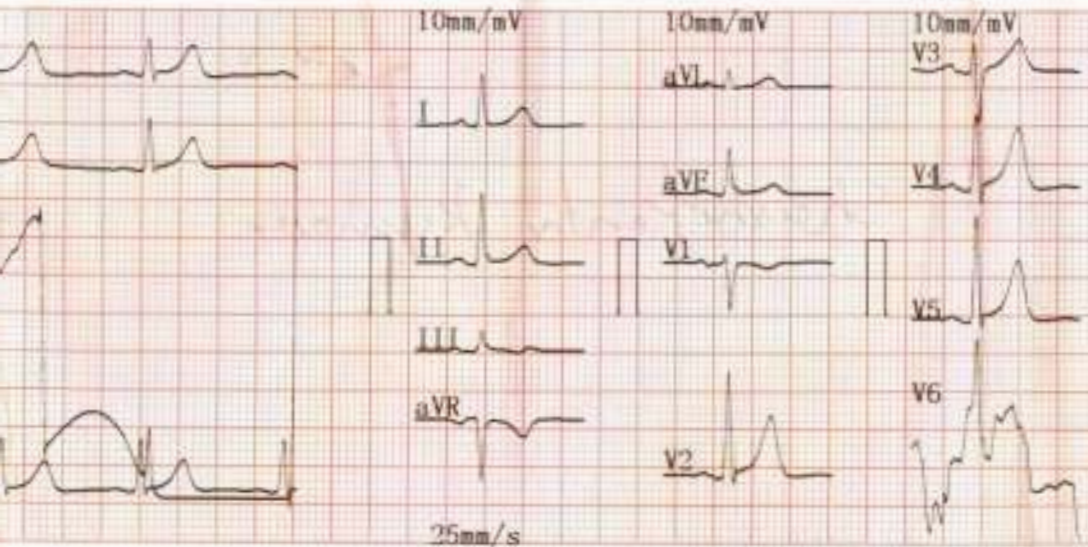


V5 5mm/mV



25mm/s AC50Hz+EMG35Hz+DFT





2024-11-15 11:00

<< Conclusions >>

ID :  
 Name : Shashi Kant Kumar  
 Sex : M Age : 37  
 Height : 166 Weight : 67.2kg  
 SYS :  
 DIA :

Cardiac electric axis normal.  
 I AV block.  
 \*\*Report need physician confirm\*\*

HR (bpm) : 95  
 PR Interval (ms) : 271  
 P Duration (ms) : 120  
 QRS Duration (ms) : 71  
 T Duration (ms) : 166  
 QT/QTc (ms) : 332/417  
 P/QRS/T Axis (deg) : 54.4/48.5/34.7  
 R(V5)/S(V1) (mV) : 1.40/0.62  
 R(V5) - S(V1) (mV) : 2.01

*Dr. Poojati Misra*  
**Dr. Poojati Misra**  
 MBBS, MD (General Medicine)  
 MCI Reg. No. 52033

Physician \_\_\_\_\_