

MEDICAL EXAMINATION REPORT

DATE: 20/07/2023

NAME: Deepak Chari

AGE: 45 yrs

GENDER: Male

TEMPERATURE: 98°F

HEIGHT: 165 cms

WEIGHT: 59.3 kgs

BMI: 21.78

CHEST MEASUREMENTS: Inspiration: 87cms

Expiration: 86cms

Abdominal girth: 84 cms

HISTORY: Nil significant history

PAST HISTORY: s/h/o Rt. Forearm fracture in 1991, no scar present. H/o kidney stones in left kidney in 2023, Circumcision in 1990

PERSONAL HISTORY: Nil significant history

NEUROLOGICAL HISTORY: Nil significant history

FAMILY HISTORY: Nil significant history

ALLERGIC HISTORY: Nil significant history

ONGOING TREATMENT: Nil

GENERAL EXAMINATION:

No evidence of pallor, icterus, clubbing, cyanosis, lymphadenopathy, pedal oedema

BUILT: Thinly built

NUTRITION: Good

PULSE: 76 bpm

BP: 100/60 mmHg

RS: NAD

CVS: NAD

CNS: No specific abnormalities detected

PA: Soft, non-tender

SKIN: NAD

MUSCULOSKELETAL: NAD

VISION: Without Glasses

(R)

(L)

Distant: 6/9

Distant: 6/9

Near : N-18

Near : N-18

With Glasses

(R)

(L)

Distant: 6/6

Distant: 6/6

Near : N-12

Near : N-12

Colour vision: Normal

ENT: NAD

Dental: Dental treatment ongoing, Left side premolar and molar removed

POSITIVE FINDINGS IN BLOOD TESTS REPORTS: (reports attached)

URINE & STOOL REPORT: (reports attached)

OTHER REPORTS: (refer attached reports)

MEDICAL EVALUATION & ADVICE: (Refer prescription if provided)

Continue proper diet and exercise



DR. SHALAK NAIK

(MBBS)

DR. SHALAK NAIK
MBBS
GMC Reg. No. 3770

Dr. SHALAK NAIK
MBBS
GMC Reg. No. 3770

| | | | |
|-------------------|--------------------|--------------|---------------|
| Patient ID | : 19063 | SampleID | : 36452 |
| Patient Name | : Mr. DEEPAK CHARI | Receipt Date | : 20-Jul-2024 |
| Age/ Sex | : 45 Years / Male | Report Date | : 20-Jul-2024 |
| Consultant Doctor | : MEDIWHEEL | LabCode | |

| INVESTIGATION | RESULT | REFERENCE RANGE | UNIT |
|---------------|--------|-----------------|------|
|---------------|--------|-----------------|------|

HAEMATOLOGY

CBC

| | | | |
|----------------------------|------|------------|------------|
| Haemoglobin | 15.5 | 13.5-18.0 | gm% |
| Total Leucocyte Count(TLC) | 6500 | 4000-10000 | cells/cumm |

Differential Leucocyte Count(DLC)

| | | | |
|--------------------------|------|---------|----------------|
| Neutrophil | 57.1 | 50-70 | % |
| Lymphocyte | 36.6 | 20-40 | % |
| Monocyte | 4.5 | 0-8 | % |
| Eosinophil | 1.7 | 0-4 | % |
| Basophil | 0.10 | 0-1 | % |
| Packed Cell Volume (PCV) | 48.4 | 36-48 | % |
| Total RBC Count | 5.26 | 3.5-5.5 | millions/cu mm |

| | | | |
|-----------------|------|----------|-----------|
| Platelets Count | 2.63 | 1.45-4.5 | lakh/cumm |
|-----------------|------|----------|-----------|

RBC Indices

| | | | |
|--------|-------|-----------|------------|
| MCV | 92.02 | 80-99 | Cu microns |
| MCH | 29.4 | 26-32 | Picograms |
| MCHC | 32.02 | 32-36 | g/dl |
| E.S.R. | 20 | H upto 15 | mm/hr |

Blood Group

| | |
|------------|----------|
| ABO | "A" |
| RH- Typing | POSITIVE |



Marzook
Dr. Marzook Mustafa Sheikh
M.B.B.S MD (Microbiology)
Reg No. 1848

| Patient Name | : DEEPAK CHARI | Receipt Date:20-Jul-2024 | |
|-------------------|-------------------|--------------------------|------|
| Age/ Sex | : 45 YEARS / Male | Report Date:20-Jul-2024 | |
| Consultant Doctor | : MEDIWHEEL | | |
| INVESTIGATION | RESULT | REFERENCE RANGE | UNIT |

BIOCHEMISTRY

BLOOD SUGAR FASTING

Blood Sugar (F) 85 70-110 mg/dl

BLOOD SUGAR POST PRANDIAL

Blood Sugar (PP) 114 80-140 mg/dl

Hba1c- GLYCOSYLATED HAEMOGLOBIN
(EDTA SAMPLE)

HbA1c : 5.2 **DIAGNOSTIC REFERENCE RANGE**

Non-diabetic:4.0-6.0 %

THERAPEUTIC GOALS FOR GLYCEMIC CONTROL

Ideal control: 6.0-7.0

Good control: 7.0-8.0

Poor control: >8.0

Estimated Average : 108 mg/dl



Marzook
Dr. Marzook Mustafa Sheikh
M.B.B.S MD (Microbiology)
Reg No. 1848

| | | | |
|-------------------|--------------------|--------------|---------------|
| Patient ID | : 19063 | SampleID | : 36452 |
| Patient Name | : Mr. DEEPAK CHARI | Receipt Date | : 20-Jul-2024 |
| Age/ Sex | : 45 Years / Male | Report Date | : 20-Jul-2024 |
| Consultant Doctor | : MEDIWHEEL | LabCode | |

| INVESTIGATION | RESULT | REFERENCE RANGE | UNIT |
|---------------|--------|-----------------|------|
|---------------|--------|-----------------|------|

BIOCHEMISTRY

Complete Liver Profile

| | | | |
|----------------------|------|---------------|-------|
| Bilirubin Total | 0.50 | upto 1.0 | mg/dl |
| Direct Bilirubin | 0.16 | upto 0.3 | mg/dl |
| Indirect Bilirubin | 0.34 | upto 0.9 | mg/dl |
| S.G.O.T | 40 | upto 45 | IU/L |
| S.G.P.T | 36 | upto 49 | IU/L |
| GAMMA GT | 21 | 11-61 | U/L |
| Alkaline Phosphatase | 283 | 110-310 | U/L |
| Total Protein | 7.1 | 6.5-8.5 | gm/dl |
| Albumin | 4.0 | 3.2 - 5.5 | gm/dl |
| Globulin | 3.10 | 1.8 - 3.6 | gm/dl |
| Albumin:Globulin | 1.29 | 1.1 - 2.2 : 1 | |

LIPID PROFILE

| | | | |
|-------------------------------------|--------|------------|-------|
| Cholesterol | 227 | H upto 200 | mg/dl |
| Triglyceride | 195 | H 60-165 | mg/dl |
| HDL (High Density Lipoprotein) | 50 | 35-55 | mg/dl |
| LDL (Low Density Lipoprotein) | 138.00 | H 80-120 | mg/dl |
| VLDL (Very Low Density Lipoprotein) | 39.00 | H 5-30 | mg/dl |
| CHOL:HDL | 4.54 | H 0-4.4 | mg/dl |

Complete Renal Profile

| | | | |
|----------------|-----|---------|-------|
| Blood UREA | 16 | 15-45 | mg/dl |
| BUN | 7 | 7-20 | mg/dl |
| Sr. CREATININE | 0.9 | 0.5-1.5 | mg/dl |



Marzook
Dr. Marzook Mustafa Sheikh
M.B.B.S MD (Microbiology)
Reg No. 1848

| | | | |
|-------------------|--------------------|--------------|---------------|
| Patient ID | : 19063 | SampleID | : 36452 |
| Patient Name | : Mr. DEEPAK CHARI | Receipt Date | : 20-Jul-2024 |
| Age/ Sex | : 45 Years / Male | Report Date | : 20-Jul-2024 |
| Consultant Doctor | : MEDIWHEEL | LabCode | |

| INVESTIGATION | RESULT | REFERENCE RANGE | UNIT |
|---------------|--------|-----------------|------|
|---------------|--------|-----------------|------|

URINE ANALYSIS

Urine Routine/Microscopic Exam

PHYSICAL EXAMINATION

| | | | |
|------------|-------------|-------------|--|
| COLOUR | PALE YELLOW | | |
| APPEARANCE | CLEAR | | |
| SP.GRAVITY | 1.025 | 1.003-1.030 | |

CHEMICAL EXAMINATION

| | | | |
|---------------|--------|--|--|
| REACTION | ACIDIC | | |
| SUGAR | NIL | | |
| ALBUMIN | NIL | | |
| UROBILINOGEN | NORMAL | | |
| KETONE BODIES | ABSENT | | |
| BLOOD | ABSENT | | |
| LEUKOCYTES | ABESNT | | |

MICROSCOPIC EXAMINATION

| | | | |
|------------------|--------|-----|------|
| PUS CELLS | 2-3 | | |
| RBC's | NIL | 0-2 | /HPF |
| EPITHELIAL CELLS | 1-2 | 0-6 | /HPF |
| CRYSTALS | ABSENT | | /HPF |
| CASTS | ABSENT | | |
| BACTERIA | ABSENT | | |
| YEAST CELLS | ABSENT | | |



Marzook

Dr. Marzook Mustafa Sheikh
M.B.B S MD (Microbiology)
Reg No. 1848

| | |
|---------------------------------|--|
| Patient Name : Mr. DEEPAK CHARI | Collected : 20/Jul/2024 03:36PM |
| Age/Gender : 45 Y O M O D M | Received : 20/Jul/2024 03:39PM |
| UHID/MR No : DDFG.0000006546 | Reported : 20/Jul/2024 05:28PM |
| Visit ID : DDFGOPV6885 | Status : Final Report |
| Ref Doctor : DR SELF | Client Name : PUP NEW VRUNDAVAN MEDICAL RESE |
| IP/OP NO : | Center location : VASCO,VASCO |

DEPARTMENT OF IMMUNOLOGY

| Test Name | Result | Unit | Bio. Ref. Range | Method |
|--|--------|--------|-----------------|--------|
| THYROID PROFILE TOTAL (T3, T4, TSH) , SERUM | | | | |
| TRI-iodothyronine (T3, TOTAL) | 0.82 | ng/mL | 0.67-1.81 | ELFA |
| THYROXINE (T4, TOTAL) | 5.50 | µg/dL | 4.66-9.32 | ELFA |
| THYROID STIMULATING HORMONE (TSH) | 0.990 | µIU/mL | 0.25-5.0 | ELFA |

Comment:

| For pregnant females | Bio Ref Range for TSH in uIU/ml (As per American Thyroid Association) |
|----------------------|---|
| First trimester | 0.1 - 2.5 |
| Second trimester | 0.2 - 3.0 |
| Third trimester | 0.3 - 3.0 |

1. TSH is a glycoprotein hormone secreted by the anterior pituitary. TSH activates production of T3 (Triiodothyronine) and its prohormone T4 (Thyroxine). Increased blood level of T3 and T4 inhibit production of TSH.
2. TSH is elevated in primary hypothyroidism and will be low in primary hyperthyroidism. Elevated or low TSH in the context of normal free thyroxine is often referred to as sub-clinical hypo- or hyperthyroidism-respectively.
3. Both T4 & T3 provides limited clinical information as both are highly bound to proteins in circulation and reflects mostly inactive hormone. Only a very small fraction of circulating hormone is free and biologically active.
4. Significant variations in TSH can occur with circadian rhythm, hormonal status, stress, sleep deprivation, medication & circulating antibodies.

| TSH | T3 | T4 | FT4 | Conditions |
|-------|------|------|------|---|
| High | Low | Low | Low | Primary Hypothyroidism, Post Thyroidectomy, Chronic Autoimmune Thyroiditis |
| High | N | N | N | Subclinical Hypothyroidism, Autoimmune Thyroiditis, Insufficient Hormone Replacement Therapy. |
| N/Low | Low | Low | Low | Secondary and Tertiary Hypothyroidism |
| Low | High | High | High | Primary Hyperthyroidism, Goitre, Thyroiditis, Drug effects, Early Pregnancy |
| Low | N | N | N | Subclinical Hyperthyroidism |
| Low | Low | Low | Low | Central Hypothyroidism, Treatment with Hyperthyroidism |
| Low | N | High | High | Thyroiditis, Interfering Antibodies |
| N/Low | High | N | N | T3 Thyrotoxicosis, Non thyroidal causes |
| High | High | High | High | Pituitary Adenoma; TSHoma/Thyrotropinoma |

Page 1 of 2



Swati Sahay

Dr. Swati Sahay
M.B.B.S, M.D(Pathology)
Consultant Pathologist

SIN No:IM07912944

Name : DEEPAK CHARI
Age : 45yrs/ MALE
Date : 20/07/2024

X-RAY CHEST PA VIEW

Bony cage is normal

Trachea is central

Heart shadow is normal

Both the domes of diaphragms are normally placed

Both cardio pulmonary angles are clear

Both costo-phrenic angles are clear

Lungs fields are normal

Soft tissues appears normal

IMPRESSION:

- CHEST X-RAY APPEARS WITHIN NORMAL LIMITS.

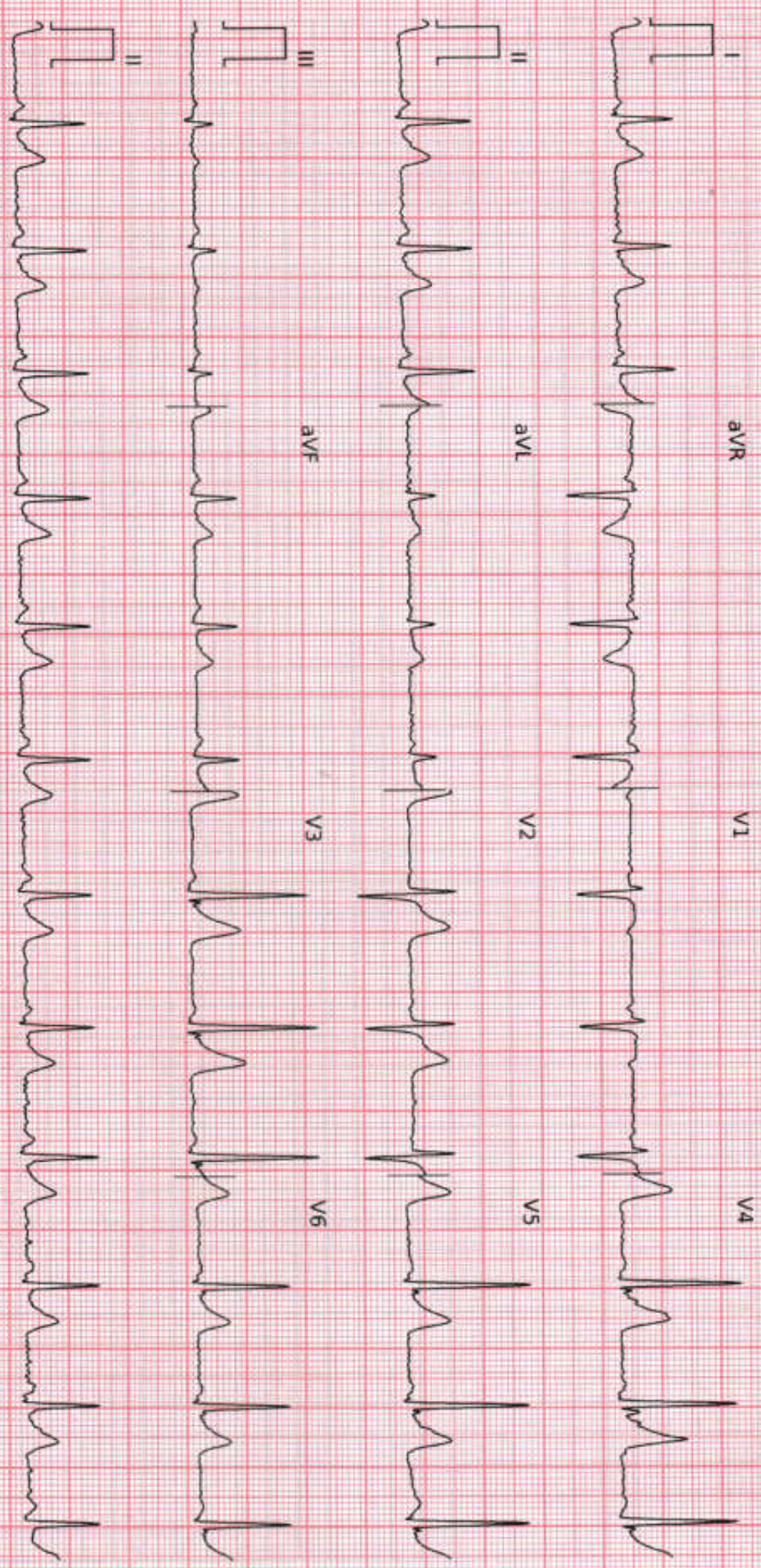

DR. SIGNATURE



Patient Name: Deepak Chari
Gender: M, Age: 45 Years
Pat ID:
Recording Date: 20-Jul-2024 10:05:37
Attended by: New Vinudayan Daycare Centre
Remote Viewer: Dr. Shalok D Naik

Vent Rate: 72BPM
AVG RR: 833ms PR: 120ms
QRS dur: 104ms ST dur: 42ms

P-R-T Axes: 62° 42° -39°
IMPORTANT: See NOTE 1



Dr. Shalok D Naik (20-Jul-2024 11:21:10):
Findings: Within Normal Limits



Shalok

Dr. Shalok D Naik
MDS
3778

Filter: 0.5Hz - 35Hz Scale: 10mm/mV 25mm/sec

NOTE 1: Diagnosis is required to verify and measure all shown measurements: Vent Rate, Avg RR, PR, QRS dur, ST dur, QT/QTc, P-R-T Axes

Version: ERG 0.1.0.0

mobimon

Product by Kallovs Engineering India

CARDIO BEATS

Subject: Health Check up Booking Confirmed Request(35ES7421),Package Code-PKG10000450, Beneficiary Code-317908

From: Mediwheel <wellness@mediwheel.in>

Date: 7/19/2024, 2:55 PM

To: hospital@newvrundavan.com

CC: customercare@mediwheel.in

011-41195959

Hi **New Vrundavan Hospital,**

The following booking has been confirmed. It is requested to honor the said booking & provide priority services to our client

Hospital Package Name : Mediwheel Annual Health Checkup Female Starter

Patient Package Name : MediWheel Full Body Health Checkup Female 40 to 50 For Self and Spouse

Hospital Address : 13/864, 4th Floor Miramar, Panaji, Goa

Contact Details : 9764681474

Appointment Date : 20-07-2024

Confirmation Status : Booking Confirmed

Preferred Time : 8:30am

| Member Information | | |
|----------------------|---------|--------|
| Booked Member Name | Age | Gender |
| SIDDHI DEEPAK CHARI | 37 year | Female |
| Deepak Prakash Chari | 45 year | Male |

We request you to facilitate the employee on priority.

Thanks,

Mediwheel Team

Please Download Mediwheel App



You have received this mail because your e-mail ID is registered with Arcofemi Healthcare Limited This is a system-generated e-mail please don't reply to this message.

INDIAN UNION DRIVING LICENCE
GOA STATE

FORM-7

Number: **GA05 19970012198**
 Name: **DEEPAK CHARI**

Si/D/W of: **PRAKASH CHARI**

Address: **M. NO E-2 NEAR
 MATRUCHAYA DHAWALI
 PORBOL GOA**

Issued on: **28-10-1987**
 DoB: **21-04-1979** BG:

Is licence to drive

| | | | | |
|---------------|------------|------------|--|--|
| Vehicle Class | LMV | BCWG | | |
| Date of issue | 28-10-1987 | 28-10-1987 | | |


Valid till (Transport) **31-03-2028**

Valid till (Non-Transport) **31-03-2028**



[Signature]
 Director of Licenses, Goa

[Signature]
 Registrar



GPS Map
Camera Lite

D-15, Behind Mc Donalds, St Mary's Colony, Miramar, Panaji, Goa
403001, India

Latitude
15.486085°

Longitude
73.81224999999999°

Local 09:01:42 AM
GMT 03:31:42 AM

Altitude 10 meters
Saturday, 20.07.2024