



Surge

3 By 20/11

24/02/2024

PICU

Vitals :

Chief Complaints :

Patient
Lactating

PI - 10th MOD
1/24/20

H/O Present illness :

c/o discharge
per vaginam

CMP - 24/02/2024

cycles 4-5/35-40d
normal flow

Past History :

Investigation :

Drug Allergies : (if any)

PIA - safe

Treatment :

PI -

PI -

not done as
patient bleeding

IP
AARS



Rx

- ① TAB METROGYL 400 MG TWICE
DAILY AFTER MEAL x 7 DAYS.
- ② CANSOFT CC PESSARY FOR
VAGINAL INSERTION AT BED
TIME x 6 NIGHTS
- ③ TAB DANTOP 40 MG ENIT x
STOMACH IN MORNING x 7 DAYS

Review of the period

Swati

Dr. YASHIKA MOTWANI
MBBS MD DCR
Obs & Gynae. IV. Specialist
DMC No. 08057

A



GG 5686

MRS SHILPA
34/F

Vitals :

Chief Complaints :

Routine eye checkup

H/O Present Illness :

bu } 6/6
 } 6/6 unaided

NCT } 12.00
 } 11.9

Past History :

MU } MB
 } MB

Investigation :

Drug Allergies : (if any)

Treatment :

codon mndr - Nozmet (ISE)

Fundas - Normal





Shupa / 33/F

24/2/24

9pm

Adv:

Vitals :

Chief Complaints :

→ Melanin
under eye
lesion

H/O Present illness :

(2YA) ————— (2)

Past History :

2 MONTH

Investigation :

Drug Allergies : (if any)

→ Inevitable gold
sunscreen

Treatment :

8am - 12pm

= Eye S/O





Park Hospital

GROUP SUPER SPECIALITY HOSPITAL



ENT

Ear }
Nose } NAD.
Throat }

Vitals :

Chief Complaints :

H/O Present illness :

Past History :

Investigation :

Drug Allergies : (if any)

Treatment :

20/08/24

Gurgaon

Q Block South City 11, Sohna Road, Main Sector-47, Gurgaon, Haryana Ph.: 0124-49000000 Fax : 0124-2218733
E-mail : parkmedcenters@gmail.com

● West Delhi ● South Delhi ● Faridabad ● Panipat ● Karnal

the health care providers

the health care providers



Dental

Vitals :

Chief Complaints : *CC routine dental checkup.*

H/O Present Illness :

Past History :

Investigation :

Drug Allergies : (if any)

Treatment :

Adv. Scaling and Polishing





Height - 54''
BP - 110/80
Wt. - 80.2 Kg

Vitals :

Chief Complaints :

H/O Present Illness :

Past History :

Investigation :

Drug Allergies : (if any)

Treatment :



DEPARTMENT OF BIOCHEMISTRY

Patient Name : Mrs. SHILPA
MR No : 695686
Age/Sex : 33 Years / Female
Type : OPD
TPA/Corporate : MEDIWHEEL PVT LTD

Bill Date : 24/02/2024
Reporting Date : 24/02/2024
Sample ID : 252422
Bill/Req. No. : 25253874
Ref Doctor : Dr.RMO

Test	Result	Bio. Ref. Interval	Units	Method
BLOOD SUGAR FASTING				
PLASMA GLUCOSE FASTING	80	60 - 110	mg/dl	GOD TRINDERS

***** END OF THE REPORT *****



Sample no.

Dr. JAY PRAKASH SINGH
MBBS, MD (PATHOLOGY)

Dr. ISHA RASTOGI
MD, MBBS MICROBIOLOGY
CONSULTANT CLINICAL MICROBIOLOGIST



USER NM ARUN



MC-4838

(This is only professional opinion and not the diagnosis, please correlate clinically)

Q Block, South City -II, Sohna Road, Sector-47, Gurgaon, Haryana

Ph.: 0124-4900000 (100 Lines), Toll Free No. : 1800-102-6767, Mob.: 62 62 82 82 35, Email: customercare@parkhospital.in

PARK GROUP OF HOSPITALS : West Delhi - Gurugram - Faridabad - Sonapat - Panipat - Karnal - Ambala - Patiala - Behror - Jaipur



DEPARTMENT OF BIOCHEMISTRY

Patient Name : Mrs. SHILPA
MR No : 695686
Age/Sex : 33 Years / Female
Type : OPD
TPA/Corporate : MEDIWHEEL PVT LTD

Bill Date : 24/02/2024
Reporting Date : 24/02/2024
Sample ID : 252422
Bill/Req. No. : 25253874
Ref Doctor : Dr.RMO

Test	Result	Bio. Ref. Interval	Units	Method
BLOOD SUGAR 2 HR. PP				
BLOOD SUGAR P.P.	107	80 - 150	mg/dl	

***** END OF THE REPORT *****



Sample no.

Dr. JAY PRAKASH SINGH
MBBS, MD (PATHOLOGY)

Dr. ISHA RASTOGI
MD, MBBS MICROBIOLOGY
CONSULTANT CLINICAL MICROBIOLOGIST

USER NM



MC - 4830

(This is only professional opinion and not the diagnosis, please correlate clinically)

Q Block, South City -II, Sohna Road, Sector-47, Gurgaon, Haryana Page 1 of 1
Ph.: 0124-4900000 (100 Lines), Toll Free No. : 1800-102-6767, Mob.: 62 62 82 82 35, Email: customercare@parkhospital.in

PARK GROUP OF HOSPITALS : West Delhi - Gurugram - Faridabad - Sonapat - Panipat - Karnal - Ambala - Patiala - Behror - Jaipur



DEPARTMENT OF PATHOLOGY

Patient Name : Mrs. SHILPA
 MR No : 695686
 Age/Sex : 33 Years / Female
 Type : OPD
 TPA/Corporate : MEDIWHEEL PVT LTD

Bill Date : 24/02/2024
 Reporting Date : 24/02/2024
 Sample ID : 252422
 Bill/Req. No. : 25253874
 Ref Doctor : Dr.RMO

Test	Result	Bio. Ref. Interval	Units	Method
URINE ROUTINE AND MICROSCOPY				
PHYSICAL CHARACTERISTICS				
QUANTITY	30ml	5 - 100	ml	Manual Method
COLOUR	Pale Yellow	Pale Yellow		
TURBIDITY	Clear	clear		
SPECIFIC GRAVITY	1.030	1.000-1.030		urinometer
PH - URINE	6.5	5.0 - 9.0		
CHEMICAL EXAMINATION-1				
UROBILINOGEN	Negative	NIL		Ehrlich Protein error indicator
URINE PROTEIN	Absent	NIL	mg/dl	
BLOOD	+	NIL		
URINE BILIRUBIN	NIL	NIL		GOD-POD/Benedicts SOD.
GLUCOSE	NIL	NIL	mg/dL	
URINE KETONE	NIL	NIL		
MICRO.EXAMINATION				
PUS CELL	2-4	0-5	cells/hpf	Microscopic
RED BLOOD CELLS	4-8	0-2	cells/hpf	
EPITHELIAL CELLS	2-3	0-5	cells/hpf	
CASTS	NIL	NIL	/pf	
CRYSTALS	NIL	NIL	/hpf	
OTHER	Bacteria present,			
AMORPHOUS URINE	Absent			

***** END OF THE REPORT *****



Sample no.

Dr. JAY PRAKASH SINGH
 MBBS, MD (PATHOLOGY)

Dr. ISHA RASTOGI
 MD, MBBS MICROBIOLOGY
 CONSULTANT CLINICAL MICROBIOLOGIST

USER NM



MC - 4230

(This is only professional opinion and not the diagnosis, please correlate clinically)

Q Block, South City -II, Sohna Road, Sector-47, Gurgaon, Haryana

Ph.: 0124-4900000 (100 Lines), Toll Free No. : 1800-102-6767, Mob.: 62 62 82 82 35, Email: customercare@parkhospital.in

PARK GROUP OF HOSPITALS : West Delhi - Gurugram - Faridabad - Sonapat - Panipat - Karnal - Ambala - Patiala - Behror - Jaipur



DEPARTMENT OF HAEMATOLOGY

Patient Name : Mrs. SHILPA
MR No : 695686
Age/Sex : 33 Years / Female
Type : OPD
TPA/Corporate : MEDIWHEEL PVT LTD

Bill Date : 24/02/2024
Reporting Date : 24/02/2024
Sample ID : 252422
Bill/Req. No. : 25253874
Ref Doctor : Dr.RMO

Test	Result	Bio. Ref. Interval	Units	Method
BLOOD GROUPING AND RH FACTOR				
BLOOD GROUP	* O * RH POSITIVE			ABO/Rh (D) SLIDE

***** END OF THE REPORT *****



Sample no.

Dr. JAY PRAKASH SINGH
MBBS, MD (PATHOLOGY)

Dr. ISHA RASTOGI
MD, MBBS MICROBIOLOGY
CONSULTANT CLINICAL MICROBIOLOGIST

USER NM



MC - 4830

(This is only professional opinion and not the diagnosis, please correlate clinically)

Q Block, South City -II, Sohna Road, Sector-47, Gurgaon, Haryana Page 1 of 1
Ph.: 0124-4900000 (100 Lines), Toll Free No. : 1800-102-6767, Mob.: 62 62 82 82 35, Email: customercare@parkhospital.in

PARK GROUP OF HOSPITALS : West Delhi - Gurugram - Faridabad - Sonapat - Panipat - Karnal - Ambala - Patiala - Behror - Jaipur



DEPARTMENT OF MICROBIOLOGY

Patient Name : Mrs. SHILPA
MR No : 695686
Age/Sex : 33 Years / Female
Type : OPD
TPA/Corporate : MEDIWHEEL PVT LTD

Bill Date : 24/02/2024
Reporting Date : 26/02/2024
Sample ID : 252422
Bill/Req. No. : 25253874
Ref Doctor : Dr.RMO

Test	Result	Bio. Ref. Interval	Units	Method
URINE C/S				
NAME OF SPECIMEN	Urine (Uncentrifuged)			Aerobic culture
ORGANISM IDENTIFIED	NO ORGANISM GROWN IN CULTURE AFTER 48HRS OF INCUBATION AT 37 C DEGREE.			
Method :				

Note : URINE CULTURE :
Presence of >105 cfu/ml (100000) in midstream urine sample is considered clinically significant. However in symptomatic patients or urine sample collection from catheter or patients with indwelling catheters, even a smaller count of bacteria may signify infection (100-10000cfu/ml). Kindly correlate clinically.

***** END OF THE REPORT *****



Sample no.

Dr. JAY PRAKASH SINGH
MBBS, MD (PATHOLOGY)

Dr. ISHA RASTOGI
MD, MBBS MICROBIOLOGY
CONSULTANT CLINICAL MICROBIOLOGIST

USER NM



(This is only professional opinion and not the diagnosis, please correlate clinically)

Q Block, South City -II, Sohna Road, Sector-47, Gurgaon, Haryana
Ph.: 0124-4900000 (100 Lines), Toll Free No. : 1800-102-6767, Mob.: 62 62 82 82 35, Email: customercare@parkhospital.in

PARK GROUP OF HOSPITALS : West Delhi - Gurugram - Faridabad - Sonapat - Panipat - Karnal - Ambala - Patiala - Behror - Jaipur



DEPARTMENT OF IMMUNOLOGY

Patient Name : Mrs. SHILPA
 MR No : 695686
 Age/Sex : 33 Years / Female
 Type : OPD
 TPA/Corporate : MEDIWHEEL PVT LTD

Bill Date : 24/02/2024
 Reporting Date : 25/02/2024
 Sample ID : 252422
 Bill/Req. No. : 25253874
 Ref Doctor : Dr.RMO

Test	Result	Bio. Ref. Interval	Units	Method
THYROID PROFILE				
TRI-IODOTHYRONINE (T3)	1.13	0.60 - 1.81	ng/ml	Chemiluminescence
THYROXINE (T4)	6.3	5.01 - 12.45	µg/dL	Chemiluminescence
THYROID STIMULATING HORMONE	8.10	H 0.5-5.50	µIU/ml	Chemiluminescence
SPECIMEN TYPE	SERUM			

Method : chemiluminescent immunoassay

Note : Clinical Significance:

Thyroid function tests (TFTs) is a collective term for blood tests used to check the function of the thyroid. TFTs may be requested if a patient is thought to suffer from hyperthyroidism (overactive thyroid) or hypothyroidism (underactive thyroid), or to monitor the effectiveness of either thyroid-suppression or hormone replacement therapy. It is also requested routinely in conditions linked to thyroid disease, such as atrial fibrillation and anxiety disorder. A TFT panel typically includes thyroid hormones such as thyroid-stimulating hormone (TSH, thyrotropin) and thyroxine (T4), and triiodothyronine (T3) depending on local laboratory policy.

Note: Please correlate with clinical condition

***** END OF THE REPORT *****



Sample no.

Dr. JAY PRAKASH SINGH
 MBBS, MD (PATHOLOGY)

Dr. ISHA RASTOGI
 MD, MBBS MICROBIOLOGY
 CONSULTANT CLINICAL MICROBIOLOGIST

USER NM



(This is only professional opinion and not the diagnosis, please correlate clinically)

Q Block, South City -II, Sohna Road, Sector-47, Gurgaon, Haryana

Ph.: 0124-4900000 (100 Lines), Toll Free No. : 1800-102-6767, Mob.: 62 62 82 82 35, Email: customercare@parkhospital.in

PARK GROUP OF HOSPITALS : West Delhi - Gurugram - Faridabad - Sonapat - Panipat - Karnal - Ambala - Patiala - Behror - Jaipur



DEPARTMENT OF BIOCHEMISTRY

Patient Name : Mrs. SHILPA
 MR No : 695886
 Age/Sex : 33 Years / Female
 Type : OPD
 TPA/Corporate : MEDIWHEEL PVT LTD

Bill Date : 24/02/2024
 Reporting Date : 24/02/2024
 Sample ID : 252422
 Bill/Req. No. : 25253874
 Ref Doctor : Dr.RMO

Test	Result	Bio. Ref. Interval	Units	Method
LFT (LIVER FUNCTION TEST)				
LFT				
TOTAL BILIRUBIN	0.5	0 - 1.2	mg/dL	DIAZO
DIRECT BILIRUBIN	0.2	0 - 0.4	mg/dL	DIAZO
INDIRECT BILIRUBIN	0.3	0.10 - 0.6	mg/dL	CALCULATED
SGOT (AST)	15	0 - 45	U/L	IFCC WITHOUT
SGPT (ALT)	16	0 - 45	U/L	IFCC WITHOUT
ALKALINE PHOSPHATASE	67	30 - 170	IU/L	MODIFIED IFCC
TOTAL PROTEINS	6.3	6.4 - 8.0	g/dL	BIURET
ALBUMIN	3.8	3.3 - 5.5	g/dL	BCG DYE
GLOBULIN	2.5	2.3 - 4.5	g/dL	CALCULATED
A/G RATIO	1.52	1.1 - 2.2	g/dL	CALCULATED
SAMPLE TYPE:	SERUM			

***** END OF THE REPORT *****



Sample no.

Dr. JAY PRAKASH SINGH
 MBBS, MD (PATHOLOGY)

Dr. ISHA RASTOGI
 MD, MBBS MICROBIOLOGY
 CONSULTANT CLINICAL MICROBIOLOGIST

USER NM



MC - 4839

(This is only professional opinion and not the diagnosis, please correlate clinically)

Q Block, South City -II, Sohna Road, Sector-47, Gurgaon, Haryana

Ph.: 0124-4900000 (100 Lines), Toll Free No. : 1800-102-6767, Mob.: 62 62 82 82 35, Email: customercare@parkhospital.in

PARK GROUP OF HOSPITALS : West Delhi - Gurugram - Faridabad - Sonapat - Panipat - Karnal - Ambala - Patiala - Behror - Jaipur



DEPARTMENT OF BIOCHEMISTRY

Patient Name : Mrs. SHILPA
 MR No : 695686
 Age/Sex : 33 Years / Female
 Type : OPD
 TPA/Corporate : MEDIWHEEL PVT LTD

Bill Date : 24/02/2024
 Reporting Date : 24/02/2024
 Sample ID : 252422
 Bill/Req. No. : 25253874
 Ref Doctor : Dr.RMO

Test	Result	Bio. Ref. Interval	Units	Method
KFT (RENAL PROFILE)				
KFT				
SERUM UREA	32	10 - 45	mg/dL	MODIFIED JAFFES URICASE ISE ISE ARSENazo III AMMONIUM
SERUM CREATININE	0.9	0.4 - 1.4	mg/dL	
SERUM URIC ACID	4.7	2.5 - 7.0	mg/dL	
SERUM SODIUM	138	135 - 150	mmol/L	
SERUM POTASSIUM	4.0	3.5 - 5.5	mmol/L	
SERUM CALCIUM	8.6	8.5 - 10.5	mg/dL	
SERUM PHOSPHORUS	2.5	2.5 - 4.5	mg/dL	
SAMPLE TYPE:	SERUM			

***** END OF THE REPORT *****



Sample no.

Dr. JAY PRAKASH SINGH
 MBBS, MD (PATHOLOGY)

Dr. ISHA RASTOGI
 MD, MBBS MICROBIOLOGY
 CONSULTANT CLINICAL MICROBIOLOGIST

USER NM



MC - 4830

(This is only professional opinion and not the diagnosis, please correlate clinically)

Q Block, South City -II, Sohna Road, Sector-47, Gurgaon, Haryana
 Ph.: 0124-4900000 (100 Lines), Toll Free No. : 1800-102-6767, Mob.: 62 62 82 82 35, Email: customercare@parkhospital.in

PARK GROUP OF HOSPITALS : West Delhi - Gurugram - Faridabad - Sonapat - Panipat - Karnal - Ambala - Patiala - Behror - Jaipur



DEPARTMENT OF BIOCHEMISTRY

Patient Name : Mrs. SHILPA
 MR No : 695688
 Age/Sex : 33 Years / Female
 Type : OPD
 TPA/Corporate : MEDIWHEEL PVT LTD

Bill Date : 24/02/2024
 Reporting Date : 24/02/2024
 Sample ID : 252422
 Bill/Req. No. : 25253874
 Ref Doctor : Dr.RMO

Test	Result	Bio. Ref. Interval	Units	Method
LIPID PROFILE				
TOTAL CHOLESTEROL	149	0 - 250	mg/dL	CHOD -Trinder
SERUM TRIGLYCERIDES	110	60 - 165	mg/dl	GPO-TRINDER
HDL-CHOLESTEROL	39	30 - 70	mg/dl	DIRECT
VLDL CHOLESTEROL	22	6 - 32	mg/dL	calculated
LDL	88	50 - 135	mg/dl	calculated
LDL CHOLESTEROL/HDL RATIO	2.26	1.0 - 3.0	mg/dL	calculated
TOTAL CHOLESTEROL/HDL RATIO	3.82	2.0 - 5.0	mg/dl	calculated
SAMPLE TYPE:	SERUM			

Note : ATP III Guidelines At-A-Glance Quick Desk Reference

Step 1 - Determine lipoprotein levels obtain complete lipoprotein profile after 9- to 12-hour fast.

ATP III Classification of LDL, Total, and HDL Cholesterol (mg/dL):-
 LDL Cholesterol Primary Target of Therapy
 <100 Optimal
 130-159 Borderline high
 >190 Very high.

Total Cholesterol
 <200 Desirable
 200-239 Borderline high
 >240 High

HDL Cholesterol
 <40 Low
 >60 High

***** END OF THE REPORT *****



Sample no.

Dr. JAY PRAKASH SINGH
 MBBS, MD (PATHOLOGY)

Dr. ISHA RASTOGI
 MD, MBBS MICROBIOLOGY
 CONSULTANT CLINICAL MICROBIOLOGIST

USER NM

ARUN



MC - 4830

(This is only professional opinion and not the diagnosis, please correlate clinically)

Q Block, South City -II, Sohna Road, Sector-47, Gurgaon, Haryana Page 1 of 1

Ph.: 0124-4900000 (100 Lines), Toll Free No. : 1800-102-6767, Mob.: 62 62 82 82 35, Email: customercare@parkhospital.in

PARK GROUP OF HOSPITALS : West Delhi - Gurugram - Faridabad - Sonapat - Panipat - Karnal - Ambala - Patiala - Behror - Jaipur



Park Ho
GROUP SUPER SPECIAL



Vitals :

Chief Complaints :

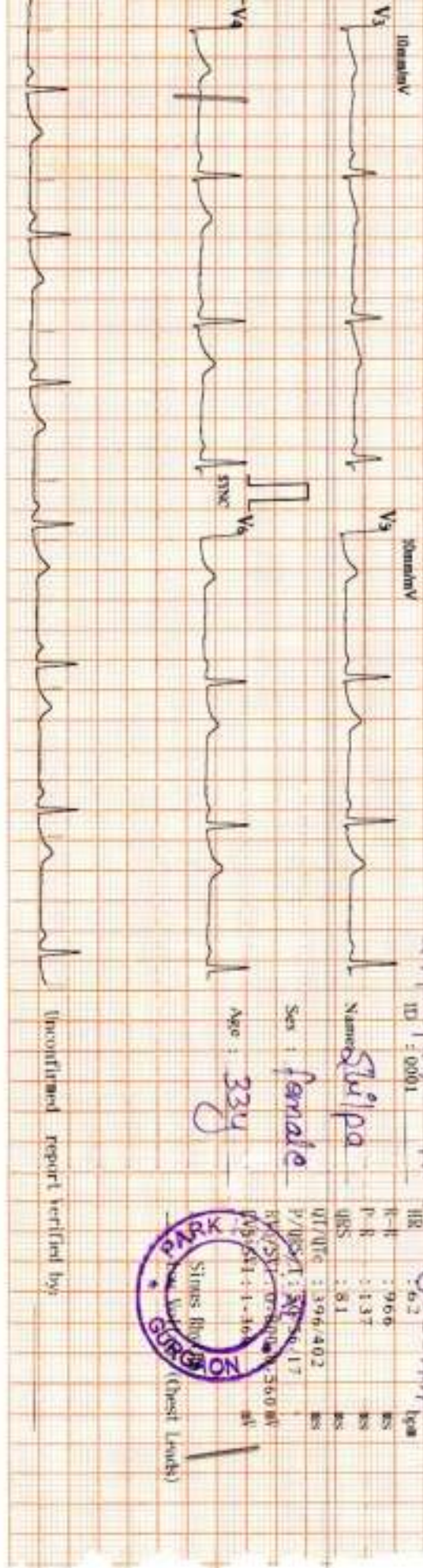
H/O Present Illness :

Past History :

Investigation :

Drug Allergies : (if any)

Treatment :



Gurgaon

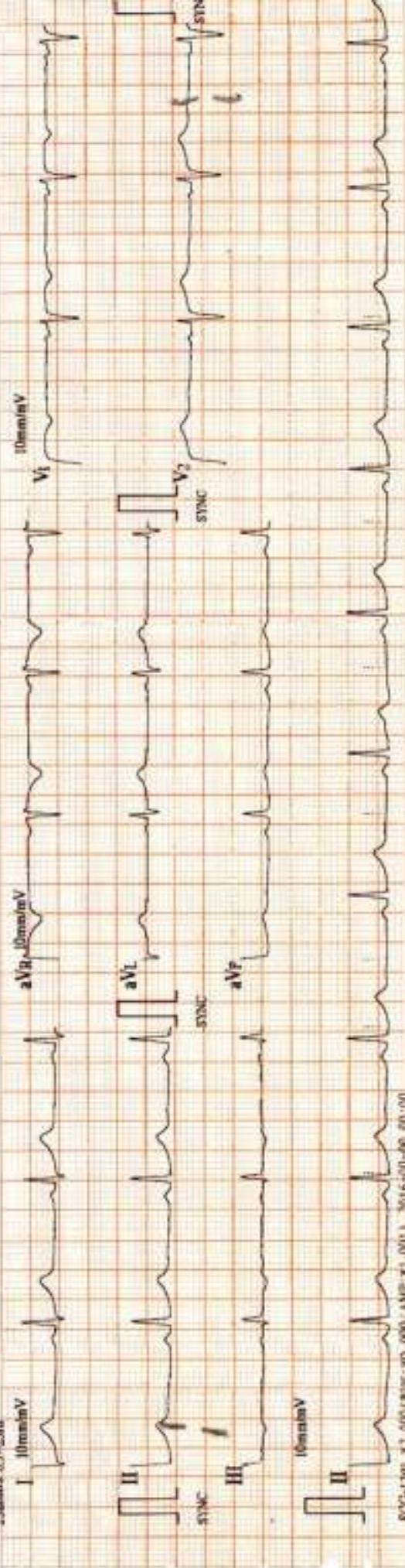
Q Block South City 11, Sohna Road, Main Sector-47, Gurgaon, Haryana Ph.: 0124-4900000 Fax : 0124-2218733
 E-mail : parkmedcenters@gmail.com

● West Delhi ● South Delhi ● Faridabad ● Panipat ● Karnal

the health care providers

the health care providers

25mm/s 0.5-23Hz





NAME	: MRS. SHILPA	DATE	: 24 / 2 / 2024
Age Sex	: 33 Years / Female	Inpatient No	: 695686
PERFORMED BY	: Dr. ELA MADAAN	BILL NO.	: 25253874

TRANS THORACIC ECHO CARDIOGRAPHY REPORT

MITRAL VALVE

Morphology AML: Normal / Thickening / Calcification / Flutter / Vegetation / Non significant Prolapse / SAM
PML: Normal / Thickening / Calcification / Prolapse / Paradoxical Motion / Fixed.
Subvalvular deformity: Present / Absent

Doppler Normal / Abnormal
Mitral Stenosis Present / Absent
Mitral Regurgitation; Absent / Normal / Mild / Trace / Moderate / Severe

TRICUSPID VALVE

Morphology Normal / Atresia / Thickening / Calcification / Prolapse / Vegetation / Doming.
Doppler Normal / Abnormal

Tricuspid Stenosis: Present / Absent.
Tricuspid Regurgitation: Absent / Mild / Trace / Moderate

PULMONARY VALVE

Morphology Normal / Atresia / Thickening / Calcified / Doming / Vegetation.
Doppler Normal / Abnormal.

Pulmonary Stenosis: Present / Absent
Pulmonary regurgitation: Present / Absent

AORTIC VALVE

Morphology Normal / Thickened / Mildly / Calcified / Flutter / Vegetation / Restricted / Opening
No. of Cusps 1 / 2 / 3 / 4

Doppler Normal / Abnormal
Aortic Stenosis : Present / Absent
Aortic regurgitation : Present / Absent / Mild / Trace / Moderate / Severe



Cert. No. H-2016-0309

(This is only professional opinion and not the diagnosis, please correlate clinically)

Q Block, South City -II, Sohna Road, Sector-47, Gurgaon, Haryana

Ph.: 0124-4900000 (100 Lines), Toll Free No. : 1800-102-6767, Mob.: 62 62 82 82 35, Email: customercare@parkhospital.in

PARK GROUP OF HOSPITALS : West Delhi - Gurugram - Faridabad - Sonapat - Panipat - Karnal - Ambala - Patiala - Behror - Jaipur



Measurements

IVSD	: 0.8cm	(0.6-1.1cm)
LVIDd	: 4.4cm	(3.7-5.6cm)
LVIDs	: 2.4cm	(0.6-1.1cm)
EF	: 60%	(55% - 80%)
Any Other		

Normal Values

Measurements

LA	: 2.3cm	(1.9-4.0cm)
AORTA	: 2.0cm	(2.0-3.7cm)
IVSmotion	:	Normal / Flat / Paradoxical

Normal Value

CHAMBERS:-

- LV **Normal** / Enlarged / **Clear** / Thrombus / Contraction Normal LV shows concentric LVH, no gradient across LVOT / Inetic / Intra capillary Regional wall motion abnormality: **Absent** / Present
- LA **Normal** / Enlarged / Clear / Thrombus / Myxoma; **LAA: Clear** / Thrombus
- RA **Normal** / **Clear** / Thrombus, Dilated.
- RV **Normal** / Mildly Dilated / Enlarged / **Clear** / Thrombus / Hypertrophied
- PERICARDIUM **Normal** / Thickening / Calcification / Effusion.

SUMMARY:-

- All Cardiac Chambers dimensions are within normal limits.
- LVEF -60%
- NORMAL LV FUNCTION
- NO RWMA
- NO LVDD
- NO AR / NO MR / NO TR
- GOOD RV FUNCTION
- IAS/IVS. No Flow seen across IAS/IVS.
- No Thrombus/Mass in any chamber.
- No Pericardial Effusion.

COMMENTS:- Normal LV Function

Please correlate clinically

Dr. SWATI SINGH
M.D. (Medicine)
D.M. (Cardiology)

Dr. JOGINDER S. DUHAN
M.D. (Medicine)
D.M. (Cardiology)

Dr. SACHIN BANSAL
M.D. (Medicine)
D.M. (Cardiology)



Cart. No. H-2016-8389

(This is only professional opinion and not the diagnosis, please correlate clinically)
Q Block, South City -II, Sohna Road, Sector-47, Gurgaon, Haryana

Ph: 0124-4900000 (100 Lines), Toll Free No.: 1800-102-6767, Mob.: 62 62 82 82 35, Email: customercare@parkhospital.in

PARK GROUP OF HOSPITALS : West Delhi - Gurugram - Faridabad - Sonapat - Panipat - Karnal - Ambala - Patiala - Behror - Jaipur



DEPARTMENT OF RADIOLOGY

Patient Name	Mrs. SHILPA	Billed Date	: 24/02/2024
Reg No	695686	Reported Date	: 24/02/2024
Age/Sex	33 Years / Female	Req. No.	: 25253874
Type	OPD	Consultant Doctor	: Dr. RMO

USG WHOLE ABDOMEN

The real time, B mode, gray scale sonography of the abdominal organs was performed.

LIVER : The liver is normal in size (14.9cm), shape and echotexture. No evidence of any focal lesion. IHBR is not dilated;

GALL BLADDER : The gall bladder is well distended. No evidence any calculus or mass seen. GB wall thickness with in normal limits. No evidence of pericholecystic fluid is seen.

BILE DUCT :The common bile duct is normal in caliber. No evidence of calculus is noted in common bile duct.

SPLEEN :The spleen is normal in size (10.0cm) and shape.Its echotexture is homogeneous.No evidence of focal lesion is noted.

PANCREAS :The pancreas is normal in size, shape, contours and echotexture.No evidence of solid or cystic mass lesion is noted.MPD is not dilated. No evidence of peripancreatic collection.

KIDNEYS : Right kidney measures 9.8 x 3.5 cm. Left kidney measures 10.1 x 4.0 cm. The bilateral kidneys are normal in size and echotexture. Cortico-medullary differentiation is maintained.There is no evidence of obvious calculus or hydronephrosis.

URINARY BLADDER :The urinary bladder is well distended.It shows uniformly thin walls and sharp mucosa.No evidence of calculus is seen. No evidence of mass or diverticulum is noted.

UTERUS : The uterus is anteverted. It measures 5.9 x 4.7 x 4.2 cms. in the longitudinal, anteroposterior and transverse dimensions respectively. The uterine margins are smooth and does not reveal any contour abnormalities.



Ph.: 0124-4900000 (100 Lines), Toll Free No. : 1800-102-6767, Mob.: 62 62 82 82 35, Email: customercare@parkhospital.in

PARK GROUP OF HOSPITALS : West Delhi - Gurugram - Faridabad - Sonapat - Panipat - Karnal - Ambala - Patiala - Mohali - Behror - Jaipur



Park Hospital

GROUP SUPER SPECIALITY HOSPITAL

The uterine myometrium shows homogeneous echotexture.
 No evidence of leiomyoma is noted. No solid or cystic mass lesion is noted.
 The endometrial echo is in the midline and measures 5.0 mm.
 The ovaries on the either side show normal echotexture.
 No adnexal mass is seen.No cyst is seen in ovaries.
 No evidence of ascites or interbowel free fluid is seen.
 No evidence of obvious retroperitoneal or mesentric lymphadenopathy is seen.
Bowel loop distended with gas.

IMPRESSION- No obvious abnormalities noted.

To be correlated clinically.



Dr. ANSHU K. SHARMA
 MBBS, MD
 CONSULTANT RADIOLOGIST

H-2016-0389

Dr. MANJEET SEHRAWAT
 MBBS, MD, POCC
 CONSULTANT RADIOLOGIST

Dr. NEENA SIKKA
 MBBS, DNB
 CONSULTANT RADIOLOGIST

(This is only professional opinion and not the diagnosis, please consult your physician)

Q Block, South City -II, Sohna Road, Sector-47, Gurgaon, Haryana

Ph.: 0124-4900000 (100 Lines), Toll Free No. : 1800-102-6767, Mob.: 62 62 82 82 35, Email: customercare@parkhospital.in

PARK GROUP OF HOSPITALS : West Delhi - Gurugram - Faridabad - Sonapat - Panipat - Karnal - Ambala - Patiala - Mohali - Behror - Jaipur



DEPARTMENT OF RADIOLOGY

Patient Name	Mrs. SHILPA	Billed Date	: 24/02/2024
Reg No	695686	Reported Date	: 24/02/2024
Age/Sex	33 Years / Female	Req. No.	: 25253874
Type	OPD	Consultant Doctor	: Dr. RMO

X-RAY CHEST AP/PA

Bilateral lungs appears normal.
 No focal lung lesion seen.
 No evidence of free fluid is seen.
 Both hila are normal in size, have equal density and bear normal relationship.
 The heart and trachea are central in position and no mediastinal abnormality is visible.
 The cardiac size is normal for patient age and view.
 The domes of the diaphragms are normal in position, and show smooth outline.
 To be correlated clinically



Dr. ANSHU KESHAVA
MBBS, MD
CONSULTANT RADIOLOGIST
H-2016-0309

Dr. MANJEET SEHRAWAT
MBBS, MD, PDCC

Dr. NEENA SIKKA
MBBS, DNB
CONSULTANT RADIOLOGIST

(This is only professional opinion and not the diagnosis, please correlate clinically)

Q Block, South City -II, Sohna Road, Sector-47, Gurgaon, Haryana
 Ph.: 0124-4900000 (100 Lines), Toll Free No. : 1800-102-6767, Mob.: 62 62 82 82 35, Email: customercare@parkhospital.in

PARK GROUP OF HOSPITALS : West Delhi - Gurugram - Faridabad - Sonapat - Panipat - Karnal - Ambala - Patiala - Mohali - Behror - Jaipur