



Swaminarayan Nagar, Off Mumbai-Agra Highway,
Panchvati, Nashik - 422 003.

QFAHN/BILL/003/V1

Name : Mr. ANIRUDDHA BHASKAR TEMKAR (32/M)

Date : 28/01/2023

Address : MEDIWHEEL NASHIK, NASHIK, MAHARASHTRA, INDIA

apollonashik@apollohospitals.com
www.askapollo.com



Examined by:

UHID : MHN1.0000133286

Package : MediWheel Full Body Health Checkup Male Below 40 Package

AHC No : NSKAH29978



CHIEF COMPLAINTS

For corporate health checkup
No specific complaints

PRESENT KNOWN ILLNESS

No history of - Diabetes mellitus,
Hypertension, Thyroid
disorder, Heart disease,
Stroke, Asthma, COPD,
Cancer



DRUG ALLERGY

NO KNOWN ALLERGY :28/01/2023



SYSTEMIC REVIEW

Cardiovascular system

- Nil Significant



Past medical history

Do you have any - No
allergies?
Do you have any drug - No
allergies?
Past medical history - nil significant
Covid 19 - No



Surgical history

Surgical history - Nil

Immunization history

- Covid Dose1, Covid Dose2



Personal history

Marital status - Married
No. of children - 01
Diet - Mixed Diet
Alcohol - does not consume alcohol
Smoking - No

Chews tobacco - No
Physical activity - Active
- level ground walking



Family history

Family history - Nil significant
Coronary artery - none
disease
Cancer - None

PHYSICAL EXAMINATION



General

General appearance - normal
Build - over weight
Height - 174
Weight - 80.7
BMI - 26.65
Pallor - No
Oedema - no
Temperature - 97
SpO2 - 98



Cardiovascular system

Heart rate (Per minute) - 68
Rhythm - Regular
- B.P. Supine
Systolic(mm of Hg) - 120
Diastolic(mm of Hg) - 70
Heart sounds - S1S2+

Respiratory system

Breath sounds - Normal vesicular breath
sounds



Abdomen

Organomegaly - No
Tenderness - No

Printed By : Shweta Sharad Shardul



Swaminarayan Nagar, Off Mumbai-Agra Highway,
Panchvati, Nashik - 422 003.

QFAHN/BILL/003/V1

Mr. ANIRUDDHA BHASKAR TEMKAR
(32 /M)

+91- 253- 2510250 / 250 / 450 / 550 / 750
UHD : MHN1.0000133286
apollonashik@apollohospitals.com

Date



Package : MediWheel Full Body Health Checkup Male Below 40 Package

AHC No : NSKAH29978

STOOL ROUTINE

Test Name	Result	Unit	Level	Range
Color:	Brownish Yellow			
Consistency :	Semi Formed			
Mucus:	Absent			
Blood:	Absent			
Pus:	Absent			
Reaction:	Alkaline			7.2-7.8
Ova:	Absent	/hpf		
Cysts:	Absent	/hpf		
Trochozoite	Absent	/hpf		
RBC	0-1	/hpf		0-2
WBC/Pus Cells :	0-2	/hpf		

BLOOD GROUPING AND TYPING (ABO and Rh)

Test Name	Result	Unit	Level	Range
ABO Group:	O			
Rh (D) Type:	POSITIVE			

LIVER FUNCTION TEST (PACKAGE)

Test Name	Result	Unit	Level	Range
ALT(SGPT) - SERUM / PLASMA	52	U/L		30-65
ALBUMIN - SERUM	4.7	g/dL		3.5-5
GLOBULIN - SERUM: (Calculated)	3.5	g/dL		1.8-3.6
ALBUMIN:GLOBULIN - SERUM(RATIO) (Calculated)	1.3			1.1-1.8

C B C WITH ESR (AUTOMATION + STANDARD METHOD)

Test Name	Result	Unit	Level	Range
Hemoglobin	14.2	g/dl		13.0-18.0
Haematocrit	42.7	%		39.0-54.0
RBC COUNT	4.86	Million/ ul		4.2-6.5
MCV	87.9	fl		75.0-95.0
MCH	29.1	pg		26.0-32.0
MCHC	33.1	g/dl		31.0-36.0
RDW	16	%		11-16
Platelet Count(Optical/Impedance)	312	10 ⁹ /m ³		140-440
TLC Count	5.91	10 ⁹ /m ³		4.0-11.0
Neutrophils	55	%		45-75
Lymphocytes	35	%		20-45
Eosinophils	07 *	%		1-6
Monocytes	03	%		1-10
Basophils	00	%		0-1
ERYTHROCYTE SEDIMENTATION RATE (ESR)	05	mm/1st hr		0-10

ALKALINE PHOSPHATASE - SERUM/PLASMA	67	U/L		0-100
AST (SGOT) - SERUM	42 *	U/L		15-37
BILIRUBIN, TOTAL - SERUM	0.3	mg/dL		0.0-1.0

LIPID PROFILE TEST (PACKAGE)

Test Name	Result	Unit	Level	Range
Total Cholesterol	213 *	mg/dL		0-200

CREATININE - SERUM / PLASMA

Test Name	Result	Unit	Level	Range
CREATININE - SERUM / PLASMA	1.0	mg/dL		0.8-1.3

LIVER FUNCTION TEST (PACKAGE)

Test Name	Result	Unit	Level	Range
GGTP: GAMMA GLUTAMYL TRANSPEPTIDASE - SERUM	36	U/L		0-50

GLUCOSE - SERUM / PLASMA (FASTING)

Test Name	Result	Unit	Level	Range
-----------	--------	------	-------	-------

● Within Normal Range ● Borderline High/Low ● Out of Range



Name

: Mr. ANIRUDDHA BHASKAR TEMKAR
(32 /M)

Package : MediWheel Full Body Health Checkup

Swaminarayan Nagar, Off Mumbai-Agra Highway,
Panchvati, Nashik - 422 003.+91- 253- 2510250 / 250 / 150 / 550 / 750
UHID : MHN1.0000133286

apollonashik@apollohospitals.com

www.askapollo.com

Male Below 40 Package

QFAHN/BILL/003/V1

Date

28/01/2023



AHC No : NSKAH29978

Glucose - Plasma (Fasting) 105 * mg/dL ● 70-100

GLUCOSE - SERUM / PLASMA (POST PRANDIAL)

Test Name	Result	Unit	Level	Range
Glucose - Plasma (POST PRANDIAL)	134	mg/dL	●	70-140

LIPID PROFILE TEST (PACKAGE)

Test Name	Result	Unit	Level	Range
HDL CHOLESTEROL - SERUM / PLASMA	51	mg/dL	●	40-60
TOTAL CHOLESTEROL/HDL CHOLESTEROL RATIO(Calculated)	4.2		●	0.0-4.5

LDL Cholesterol (Direct LDL) 165 mg/dL ●

LIVER FUNCTION TEST (PACKAGE)

Test Name	Result	Unit	Level	Range
PROTEIN, TOTAL - SERUM / PLASMA	8.2	g/dL	●	6.4-8.2

LIPID PROFILE TEST (PACKAGE)

Test Name	Result	Unit	Level	Range
Triglycerides - Serum	154 *	mg/dL	●	0-150

URIC ACID - SERUM

Test Name	Result	Unit	Level	Range
URIC ACID - SERUM	7.3 *	mg/dL	●	3.5-7.2

LIVER FUNCTION TEST (PACKAGE)

Test Name	Result	Unit	Level	Range
BILIRUBIN CONJUGATED (DIRECT) - SERUM	0.2	mg/dL	●	0.0-0.3
BILIRUBIN UNCONJUGATED - SERUM(Calculated)	0.1	mg/dL	●	0.0-0.7

CARDIAC STRESS TEST - (TMT)**ECG**

● Within Normal Range ● Borderline High/Low ● Out of Range

ULTRASOUND - WHOLE ABDOMEN

A simple right renal cyst.
No other significant abnormality is detected.

X-RAY CHEST PA

No significant abnormality is detected.

INVESTIGATIONS NOT DONE / NOT YET REPORTED / NOT PART OF PACKAGE(LAB,RADIOLOGY & CARDIOLOGY)

Biochemistry

TOTAL T3: TRI IODOTHYRONINE - SERUM

TSH: THYROID STIMULATING HORMONE - SERUM

TOTAL T4: THYROXINE - SERUM



Swaminarayan Nagar, Off Mumbai-Agra Highway,
Panchvati, Nashik - 422 003.

QFAHN/BILL/003/V1

Name : Mr. ANIRUDDHA BHASKAR TEMKAR
(32 /M)

+91- 253- 2510250 / 250 / 450 / 550 / 250
UHD : MHN1.0000133286
apollonashik@apollohospitals.com

Date



28/01/2023

Package : MediWheel Full Body Health Checkup Male Below 40 Package

www.askapollo.com

AHC No : NSKAH29978

Printed By :

AHC Physician / Consultant Internal Medicine



Note :- The Health Check-up examinations and routine investigations have certain limitations and may not be able to detect all the diseases. Any new or persisting symptoms should be brought to the attention of the Consulting Physician. Additional tests, consultations and follow up may be required in some cases.



Swaminarayan Nagar, Off Mumbai-Agra Highway,
Panchvati, Nashik - 422 003.

QFAHN/BILL/003/V1

Name : Mr. ANIRUDDHA BHASKAR TEMKAR
(32 /M)

+91- 253- 2510259 / 259 / 450 / 559 / 350
UHD : MHN1.0000133286
apollonashik@apollohospitals.com

Date



28/01/2023

Package : MediWheel Full Body Health Checkup Male Below 40 Package

www.askapollo.com

AHC No : NSKAH29978

AICVD RISK SCORE REPORT

RISK STATUS

Low Risk

YOUR SCORE

2

ACCEPTABLE SCORE

3

Your cardiovascular disease risk in the next 10 years is within the Normal limits for your age and gender

The AICVD risk score developed by Apollo Hospitals is a novel artificial intelligence-based risk scoring system that predicts your risk of having Coronary Artery Disease (CAD) related events in the next ten years. This scoring system uses Indian data and has been validated by multiple national and international institutions. This risk score is more than 92% accurate and has been compiled based on your physical parameters, heart health attributes, lifestyle and medical history. **Note:** The risk category is determined through the ratio between guest score and acceptable score at multiple decimal points. The outputs are shown in whole numbers.

Based on your AICVD risk score you are advised the following:

- Follow the guidance and education on **lifestyle and dietary management provided through the ProHealth program. Maintain a healthy BMI (<25). Avoid tobacco in any form and if you are a smoker, stop smoking.**
- Continue with **medications** for high blood pressure, diabetes, or dyslipidemia, if advised by your physician. Maintain HbA1c <7% (<53mmol/mol), blood pressure <140/90mmHg.
- Follow your physician's advice regarding **follow up tests, consults and annual health assessment**

DISCLAIMER

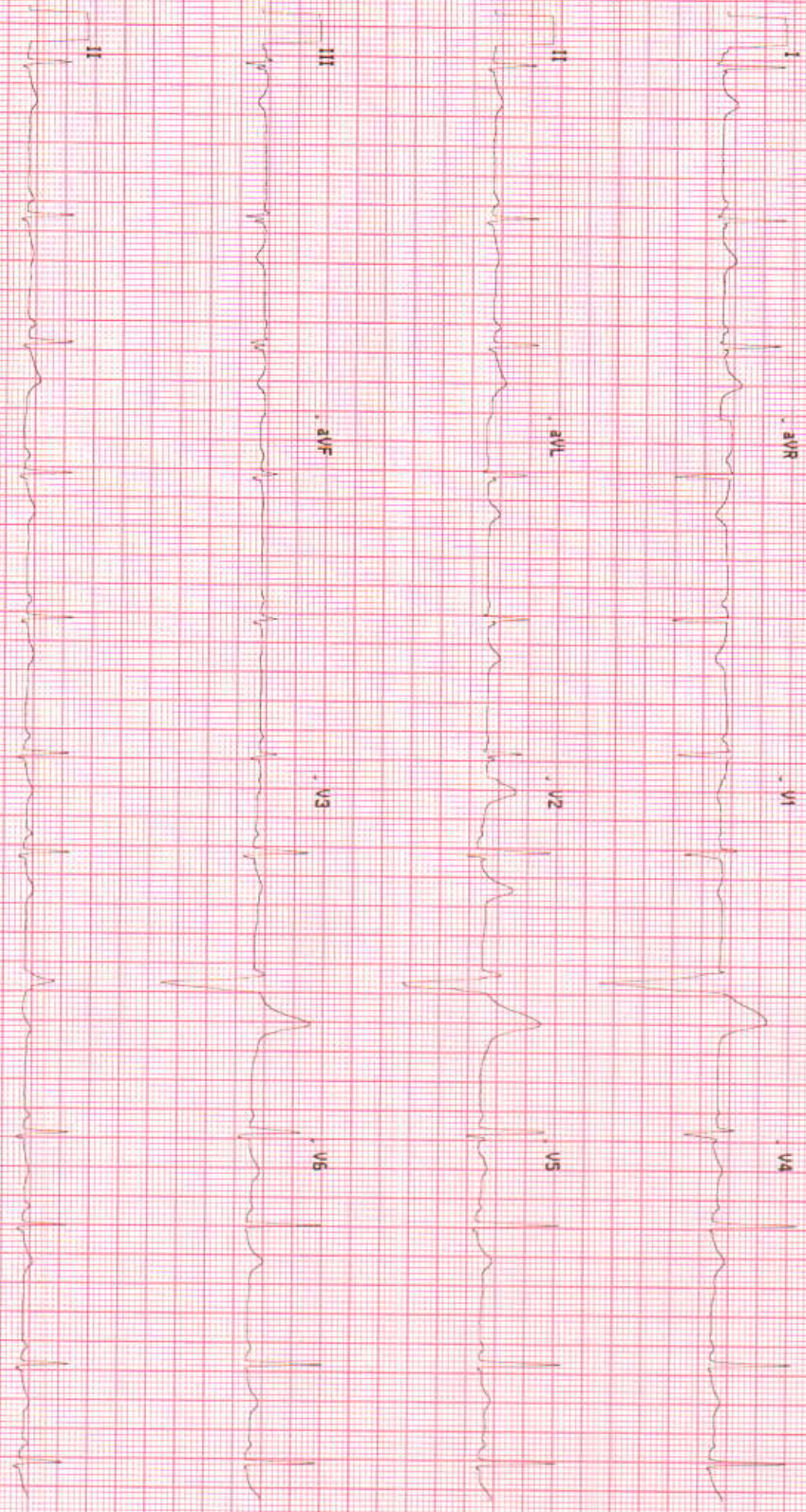
- This is not a diagnostic tool and it does not guarantee accuracy of the result and cannot be acted upon independently.
- This risk score and clinical algorithm is a general guideline for physicians. Any additional laboratory investigations, diagnostic imaging, treatment or patient education related to lifestyle management is under the physician's or cardiologist's discretion.
- To ensure the information in the report is up to date, accurate and correct, doctor shall be consulted for interpretation of the report.
- Apollo Hospitals and its staff does not offer any assurance on the information made available or be liable for any loss or damage as the said report is based on the AICVD risk score without any intervention from their side.
- By usage of the AICVD risk score, it is deemed that the beneficiary of this service has agreed to get the same done at his own risk and further agrees with this disclaimer without any limitation or any clauses or sub-clauses.

The Clinical AI Models and APIs used at Apollo Hospitals are certified by ISO 13485 : 2016 vide certificate no. MD 763515

ID: DOB: 32yr, Male

Vent Rate: 68 BPM
PR int: 136 ms
QRS dur: 97 ms
QT/QTc: 386/403 ms
P-R-T axes: 34 12 2

SINUS RHYTHM WITH MARKED SINUS ARRHYTHMIA
POSSIBLE RIGHT VENTRICULAR CONDUCTION DELAY (RSR) IN V1/V2
BORDERLINE ECG
UNCONFIRMED REPORT





Swaminarayan Nagar, Off Mumbai-Agra Highway,
Panchvati, Nashik - 422 003.
+91- 253 - 2510250 / 350 / 450 / 550 / 750
apoltonashik@apollohospitals.com
www.askapolto.com

QFAHN/BILL/003/V1



Apollo
HOSPITALS
NASHIK

MD (Radiology)

Patient Details : Mr. ANIRUDDHA BHASKAR TEMKAR | Male | 32Yr 5Mth 1Days

UHID : MHN1.0000133286

Patient Location: AHC

Patient Identifier: NSKAH29978



DRN : 123003926

Completed on : 28-JAN-2023 10:15

Ref Doctor : Dr. Rajashri Dhongade

X-RAY CHEST PA

Both lung fields are clear.

Both hila are normal in size and position.

Costophrenic and cardiophrenic angles are clear.

Cardiac size and contour are within normal limits.

Rib cage is normal.

Soft tissues are normal.

Impression

No significant abnormality is detected.


--- END OF THE REPORT ---

Kunal Kalyanrao Patil

Consultant - MD (Radiodiagnosis)



MD (Radiology)

Patient Details : Mr. ANIRUDDHA BHASKAR TEMKAR | Male | 32Yr 5Mth 1Days
UHID : MHN1.0000133286 **Patient Location:** AHC
Patient Identifier: NSKAH29978 
DRN : 223002367 **Completed on :** 28-JAN-2023 12:37
Ref Doctor : Dr. Rajashri Dhongade

ULTRASOUND - WHOLE ABDOMEN

LIVER : Normal in size. Echotexture is uniform and normal.
No I.H.B.D./ focal lesions.

PORTAL VEIN: Normal in size.

GALL BLADDER: Well distended with normal walls and lumen.
No calculi/pericholecystic fluid.

COMMON BILE DUCT: Normal in size.

PANCREAS : Visualized portion of head and body of pancreas appears normal in size and echotexture. Rest of the pancreas is obscured due to bowel gases.

AORTA, IVC and para aortic areas are normal.

SPLEEN : Normal in size and echotexture.

KIDNEYS: Both kidneys are normal in site, size and echotexture.

No evidence of calculi/ hydronephrosis.

Right kidney measures : 10.1 x 4.2 cm

A cortical cyst of size 2.4 x 2.3cm is seen in the upper pole of right kidney.

Left kidney measures : 11.6 x 5.2 cm.

URINARY BLADDER: Well distended with normal walls.

No evidence of calculi/ growth/ diverticula.

PROSTATE : Normal in size with homogenous echogenicity. No evidence of calcification within.



Swaminarayan Nagar, Off Mumbai-Agra Highway,
Panchvati, Nashik - 422 003.
+91- 253 - 2510250 / 350 / 450 / 550 / 750
apoltonashik@apoltohospitals.com
www.askapollo.com

QFAHN/BILL/003/V1



Apollo
HOSPITALS
NASHIK

Mr. ANIRUDDHA BHASKAR TEMKAR

MHN1.0000133286

NSKAH29978

ULTRASOUND - WHOLE ABDOMEN

Prostate measures :11.5gms.

Seminal vesicles are normal.

Visualized bowel loops appear grossly normal.

No evidence of any free fluid in the peritoneal cavity.

Impression

A simple right renal cyst.

No other significant abnormality is detected.

--- END OF THE REPORT ---

Kunal Kalyanrao Patil

Consultant - MD (Radiodiagnosis)

Apollo
HOSPITALS
NASHIK



Swaminarayan Nagar, Off Mumbai-Agra Highway,
Panchvati, Nashik - 422 003.

+91- 253 - 2510250 / 350 / 450 / 550 / 750

apoltonashik@apollohospitals.com

www.askapollo.com

QFAHN/BILL/003/V1



Apollo
HOSPITALS
NASHIK

28/1/23

Mr. Temlekar

32/M.

Dr. Prakash Patil

9096986290

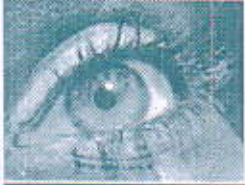- No H/o of DM & HTN.

- Supra & Subgingival plaque seen.

- No Cavities present.

Advis Sealing Req.

Apollo
HOSPITALS
NASHIK



OPHTHALMOLOGY



Name: Mr. Animolha Temkar Date: 28/1/23 UNIT _____

Occupation: _____ Room No. _____ Out Patient

Age: 32 Sex: Male Female S/M/W/D Ref. Physician: _____

Address: N/SK Copies to: _____

Tel. No. _____

REPORT ON OPHTHALMIC EXAMINATION

HISTORY: _____

PRESENT COMPLAINT: _____

PAST HISTORY: DM / HTN / ALLERGY → Aspirin, diclofenac, sulpho, Nimesulid

ON EXAMINATION

RE

LE

VISION :

	RIGHT					LEFT				
	PGP	SPH	CYL	AXIS	VA	SPH	CYL	AXIS	VA	
DIST										
NEAR										

AR / Retinoscopy :

	RIGHT			LEFT		
	SPH	CYL	AXIS	SPH	CYL	AXIS
	R	05	-	05	-	-

Refraction or Acceptance :

	RIGHT					LEFT				
	SPH	CYL	AXIS	VA	SPH	CYL	AXIS	VA		
DIST	R			6/6	R			6/6		
NEAR				05	R			05		

Blue light protection

CV. f(2)

ID: 000133286

Visit:

32years

Male

Asian

BRUCE Total Exercise time: 9:16

Max HR: 176bpm 98% of max predicted 178bpm

Max BP: 130/80 Maximum workload: 10.5METS

28-Jan-2023

14:01:11

Referred by:

Test ind:

25.0 mm/s
10.0 mm/mV
100hz

Phase Name	Stage Name	Time in Stage	Speed (mph)	Grade (%)	WorkLoad (METS)	HR (bpm)	BP (mmHg)	RPP (x100)
PRETEST	SUPINE	0:49	**.*	**.*	1.0	95	110/70	105
	STANDING	0:15	**.*	**.*	1.0	93	110/70	102
	HYPERVENT	0:10	0.0	0.0	1.0	98	110/70	108
EXERCISE	STAGE 1	3:00	1.7	10.0	4.6	137	110/70	151
	STAGE 2	3:00	2.5	12.0	7.0	156	120/80	187
	STAGE 3	3:00	3.4	14.0	10.1	175	130/80	228
	STAGE 4	0:16	4.2	16.0	10.5	176	130/80	229
RECOVERY	Post	3:01	**.*	**.*	1.0	115	130/80	150

TMT

Negative for S11

