



A.L.C. Advance Imaging Dignostics

ISO 9001:2015 Certified center

(A Unit of Subham Imaging P.K. Arogyam Health & Wellness Center)

E-95, P.C. Colony, Near Sai Netryalaya Transformer, Kankarbagh, Patna - 20

alcdiagnostics@gmail.com

www.pkarogayamhealthcheckup.com

7050037694, 8271206196

OPINION MUST BE CORRELATES WITH CLINICALLY & OTHER INVESTIGATION FOR FINAL DIAGNOSIS. NOT FOR MEDICO LEGAL PURPOSE

PATIENT NAME : Mr. KANHAIYA LAL GUPTA

PATIENT ID: 2642

COL DATE : 10/12/2022 REPORTING DATE: 10/12/2022 AGE SEX:- 38 YRS/M

REF.BY : DR. / MEDIWHEEL.

TEST NAME	RESULT	Unit	REF.RANGE
ESR	12 mm/hr		<20 mm/hr
CBC			
Total W.B.C. Count	9,300 /cumm		4000 -11,000 /cumm
R B C COUNT	5.82 Million/ CUmm		4 - 7 Million/ CUmm
Platelets count	2.42 Lakh/ cumm		1.5-5.0 Lakh/ cumm
Differential Count of W.B.C.			
Neutrophils	61 %		40-70%
Lymphocytes	33 %		25-40%
Eosinophils	04 %		01-05%
Mnonocytes	02 %		00-02%
Basophiles	00 %		00-0%
HAEMOGLOBIN	15.8 gm/dl (108.2 %		14.6 gm/dl = 100%
PCV	46.3 %		35-47 %
MCV	89.6 fl		76-96 fl
MCH	29.2 pg		29-35 pg
MCHC	35.0 %		30-38 %



[Signature]
10/12/22

Consultant Radiologist

ESTB BY:-

Dr. P. K. Tiwari

MD, M.Sc (Radio Imaging)
Ph.D (Ab Nuclear Medicine)
Consultant Imagonologist & Sonologist

Dr. S. Kumar

MD (Pat)
Consultant Pathologist

Dr. Abhishek Kumar

MBBS, MD
Consultant Neuropatho Physiologist

Dr. Kumari Suman

MBBS, DGO, MD
Consultant (TVS & HSG Specialist)

Dr. A. K. Singh

MBBS, PGDMCH
Consultant Radiologist & Sonologist

PRINTING MISTAKE SHOULD BE REPORTED BACK IMMEDIATELY/ यहाँ जन्म से पहले भ्रुण का लिंग जाँच नहीं होता है ।



A.L.C. Advance Imaging Diagnostics

ISO 9001:2015 Certified center

(A Unit of Subham Imaging P.K. Arogyam Health & Wellness Center)

E-95, P.C. Colony, Near Sai Netryalaya Transformer, Kankarbagh, Patna - 20

✉ alcdiagnostics@gmail.com

🌐 www.pkarogyamhealthcheckup.com

☎ 7050037694, 9271206196

OPINION MUST BE CORRELATES WITH CLINICALLY & OTHER INVESTIGATION FOR FINAL DIAGNOSIS. NOT FOR MEDICO LEGAL PURPOSE

PATIENT NAME : Mr. KANHAIYA LAL GUPTA

PATIENT ID: 2642

COL DATE : 10/12/2022 REPORTING DATE: 10/12/2022 AGE SEX:- 38 YRS/M

REF.BY : DR./ MEDIWHEEL..

TEST NAME	RESULT	Unit	REF.RANGE
-----------	--------	------	-----------

BLOOD GROUP	:	' AB '	
-------------	---	--------	--

Rh Typing	:	POSITIVE	
-----------	---	----------	--

Note: Do always cross – matching before blood transfusion



[Handwritten Signature]
10/12/22

Consultant Radiologist

ESTB BY:-

Dr. P. K. Tiwari

MD, M.Sc (Radio Imaging)

M.D (AI) Nuclear Medicine

Consultant Imagingologist & Sonologist

Dr. S. Kumar

MD (Pat)

Consultant Pathologist

Dr. Abhishek Kumar

MBBS, MD

Consultant Neuropatho Physiologist

Dr. Kumari Suman

MBBS, DGO, MD

Consultant (TVS & HSG Specialist)

Dr. A. K. Singh

MBBS, PGDMCH

Consultant Radiologist & Sonologist

PRINTING MISTAKE SHOULD BE REPORTED BACK IMMEDIATELY/ यहाँ जन्म से पहले भ्रूण का लिंग जाँच नहीं होता है ।



A.L.C. Advance Imaging Diagnostics

ISO 9001:2015 Certified center

(A Unit of Subham Imaging P.K. Arogyam Health & Wellness Center)

E-95, P.C. Colony, Near Sai Netryalaya Transformer, Kankarbagh, Patna - 20

alcdiagnostics@gmail.com

www.pkarogayamhealthcheckup.com

7050037694, 8271206196

OPINION MUST BE CORRELATES WITH CLINICALLY & OTHER INVESTIGATION FOR FINAL DIAGNOSIS. NOT FOR MEDICO LEGAL PURPOSE

PATIENT NAME : Mr. KANHAIYA LAL GUPTA

PATIENT ID: 2642

COL DATE : 10/12/2022 REPORTING DATE: 10/12/2022 AGE SEX : 38 YRS/M

REF.BY : DR./ MEDIWHEEL.

GLYCOSYLATED HEMOGLOBIN

TEST NAME	RESULT	Unit	REF.RANGE
HbA1c	4.4 %		Below 5.7 % : Normal 5.7 – 6.4 % : Prediabetic > = 6.5 % : Diabetic
AVERAGE PLASMA GLUCOSE	96.0 mg/dl		90 – 120 mg/dl : Good Control 121– 150 mg/dl : Fair Control 151- 180 mg/dl: Unsatisfactory Control >180 mg/dl : Poor Control



[Handwritten Signature]
10/12/22

Consultant Radiologist

ESTB BY:-

Dr. P. K. Tiwari
MD, M.Sc (Radio Imaging)
Ph.D (AI) Nuclear Medicine
Consultant Imagonologist & Sonologist

Dr. S. Kumar
MD (Pat)
Consultant Pathologist

Dr. Abhishek Kumar
MBBS, MD
Consultant Neuropatho Physiologist

Dr. Kumari Suman
MBBS, DGO, MD
Consultant (TVS & HSG Specialist)

Dr. A. K. Singh
MBBS, PGDMCH
Consultant Radiologist & Sonologist

PRINTING MISTAKE SHOULD BE REPORTED BACK IMMEDIATELY/ यहाँ जन्म से पहले भुण का लिंग जाँच नहीं होता है ।



A.L.C. Advance Imaging Diagnostics

ISO 9001:2015 Certified center

(A Unit of Subham Imaging P.K. Arogyam Health & Wellness Center)

E-95, P.C. Colony, Near Sai Netryalaya Transformer, Kankarbagh, Patna - 20

alcdiagnostics@gmail.com

www.pkarogyamhealthcheckup.com

7050037694, 8271206196

OPINION MUST BE CORRELATES WITH CLINICALLY & OTHER INVESTIGATION FOR FINAL DIAGNOSIS. NOT FOR MEDICO LEGAL PURPOSE

PATIENT NAME : Mr. KANHAIYA LAL GUPTA

PATIENT ID: 2642

COL DATE : 10/12/2022 REPORTING DATE: 10/12/2022 AGE SEX : 38 YRS/M

REF.BY : DR. /MEDIWHEEL.

TEST NAME	RESULT	Unit	REF.RANGE
-----------	--------	------	-----------

H.I.V (1/2)	NON.REACTIVE		
-------------	--------------	--	--

BLOOD SUGAR (F)	97.0 mg/dl		70 - 110 mg/dl
-------------------	------------	--	----------------

LIPID PROFILE:-

TOTAL CHOLESTROL	233.0 mg/dl		130 -250 mg/dl
------------------	-------------	--	----------------

TRIGLYCERIDE	166.1 mg/dl		50 -160 mg/dl
--------------	-------------	--	---------------

HDL CHOLESTROL	51.0 mg/dl		30 - 60 mg/dl
----------------	------------	--	---------------

LDL CHOLESTROL	146.8 mg/dl		80 -130 mg/dl
----------------	-------------	--	---------------

VLDL CHOLESTROL	33.2 mg/dl		15 - 40 mg/dl
-----------------	------------	--	---------------

T.CH./HDL RATIO	4.5:1		Upto 5:1
-----------------	-------	--	----------

LDL./HDL RATIO	2.8:1		2 - 4:1
----------------	-------	--	---------



10/12/22
Consultant Radiologist

ESTB BY:-

Dr. P. K. Tiwari
MD, M.Sc (Radio Imaging)
Ph.D (Alb Nuclear Medicine)
Consultant Imagiologist & Sonologist

Dr. S. Kumar
MD (Pat)
Consultant Pathologist

Dr. Abhishek Kumar
MBBS, MD
Consultant Neuropatho Physiologist

Dr. Kumari Suman
MBBS, DGO, MD
Consultant (TVS & HSG Specialist)

Dr. A. K. Singh
MBBS, PGDMCH
Consultant Radiologist & Sonologist

PRINTING MISTAKE SHOULD BE REPORTED BACK IMMEDIATELY/ यहाँ जन्म से पहले भ्रुण का लिंग जाँच नहीं होता है ।



A.L.C. Advance Imaging Dignostics

ISO 9001 2015 Certified center

(A Unit of Subham Imaging P.K. Arogyam Health & Wellness Center)

E-95, P.C. Colony, Near Sai Netryalaya Transformer, Kankarbagh, Patna - 20

alcdiagnostics@gmail.com

www.pkarogyamhealthcheckup.com

7050037694, 8271206196

OPINION MUST BE CORRELATES WITH CLINICALLY & OTHER INVESTIGATION FOR FINAL DIAGNOSIS. NOT FOR MEDICO LEGAL PURPOSE

PATIENT NAME : Mr. KANHAIYA LAL GUPTA

PATIENT ID: 2642

COL DATE : 10/12/2022 REPORTING DATE: 10/12/2022 AGE SEX:- 38 YRS/M

REF.BY : DR./ MEDIWHEEL..

TEST NAME	RESULT	Unit	REF.RANGE
LFT:-			
SGPT	91.0	IU/L	5 - 48 IU/L
SGOT	57.1	IU/L	5 - 40 IU/L
ALKALINE PHOSPHATASE	112.5	IU/L	25 - 147 IU/L
TOTAL PROTIN	7.3	g/dl	6.0 - 8.7 g/dl
SERUM ALBUMIN	4.4	g/dl	3.5 - 5.4 g/dl
SERIUM GLUBLINE	2.9	g/dl	2.3 - 3.6 g/dl
AG RATIO	1.5 : 1		1.0 - 2.3 g/dl
BILIRUBIN			
TOTAL	0.78	mg/dl	0.1 - 1.1 mg/dl
IRECT	0.24	mg/dl	0.0 - 0.32 mg/dl
INDIRECT	0.54	mg/dl	0.0 - 0.78 mg/dl
GGTP (GGT)	21.9	iu/L	8 - 38 iu/L
KFT/RFT			
URIC ACID	5.2	mg/dl	3.2 - 7.0 mg/dl
SERUM CREATNINE	1.0	mg/dl	0.6 - 1.5 mg/dl
BLOOD URIA	31.0	mg/dl	5 - 45 mg/dl
BLOOD URIA NITROZEN(BUN).	14.4	mg/dl	5 - 24 mg/dl

ESTB BY:-

Dr. P. K. Tiwari

MD, M.Sc (Radio Imaging)
Ph.D (Ab) Nuclear Medicine)
Consultant Imacionologist & Sonologist

Dr. S. Kumar

MD (Pat)
Consultant Pathologist

Dr. Abhishek Kumar

MBBS, MD
Consultant Neuropatho Physiologist

Dr. Kumari Suman

MBBS, DGO, MD
Consultant (TVS & HSG Specialist)

Dr. A. K. Singh

MBBS, PGDMCH
Consultant Radiologist & Sonologist



AK
10/12/22

Consultant Radiologist

PRINTING MISTAKE SHOULD BE REPORTED BACK IMMEDIATELY/ यहाँ जन्म से पहले भ्रुण का लिंग जाँच नहीं होता है ।



A.L.C. Advance Imaging Diagnostics

ISO 9001:2015 Certified center

(A Unit of Subham Imaging P.K. Arogyam Health & Wellness Center)

E-95, P.C. Colony, Near Sai Netryalaya Transformer, Kankarbagh, Patna - 20

alcdiagnostics@gmail.com

www.pkarogayamhealthcheckup.com

7050037694, 8271206196

OPINION MUST BE CORRELATES WITH CLINICALLY & OTHER INVESTIGATION FOR FINAL DIAGNOSIS. NOT FOR MEDICO LEGAL PURPOSE

PATIENT NAME : Mr. KANHAIYA LAL GUPTA PATIENT ID: 2642
COL DATE : 10/12/2022 REPORTING DATE: 10/12/2022 AGE SEX : 38 YRS/M
REF.BY : DR. / MEDIWHEEL..

TEST NAME	RESULT	Unit	REF.RANGE
Total Triiodothyronin T3	1.59	ng/mL	0.80 -2.00 ng/mL
Total Thyroxin T4	9.67	µg/dL	5.10 -14.10 µg/dL
Serum TSH	2.31	µIU/mL	0.27 – 4.20 µIU/mL

THYROID DISORDER (>: Increase: < Decrease: n Normal

1. T3(n) T4(n) TSH(n) :EUTHYROID STATE:
2. T3(>) T4(>) TSH(<): HYPERTHYROIDISM:
3. T3(<)T4(<) TSH(>): HYPOTHYROIDISM:
4. T3(n)T4(n) TSH(>) : SUB-CLINICAL HYPO-THYROIDISM:
5. T3(n)T4(n) TSH(<): SUB-CLINICAL HYPER-THYROIDISM:
6. T3(>) T4(n) TSH(<): T3 THYROTOXICOSIS:

Total T3/T4 level is dependent on Level:

So determination of free T3/T4is a better MARKER of Thyroid Function.



Consultant Radiologist

ESTB BY:-

Dr. P. K. Tiwari
MD, M.Sc (Radio Imaging)
Ph.D (Alt Nuclear Medicine)
Consultant Imagiologist & Sonologist

Dr. S. Kumar
MD (Pat)
Consultant Pathologist

Dr. Abhishek Kumar
MBBS, MD
Consultant Neuropatho Physiologist

Dr. Kumari Suman
MBBS, DGO, MD
Consultant (TVS & HSG Specialist)

Dr. A. K. Singh
MBBS, PGDMCH
Consultant Radiologist & Sonologist

PRINTING MISTAKE SHOULD BE REPORTED BACK IMMEDIATELY/ यहाँ जन्म से पहले भ्रुण का लिंग जाँच नहीं होता है ।



A.L.C. Advance Imaging Dignostics

ISO 9001:2015 Certified center

(A Unit of Subham Imaging P.K. Arogyam Health & Wellness Center)

E-95, P.C. Colony, Near Sai Netryalaya Transformer, Kankarbagh, Patna - 20

alcdiagnostics@gmail.com

www.pkarogyamhealthcheckup.com

7050037694, 8271206196

OPINION MUST BE CORRELATES WITH CLINICALLY & OTHER INVESTIGATION FOR FINAL DIAGNOSIS. NOT FOR MEDICO LEGAL PURPOSE

PATIENT NAME : Mr .KANHAIYA LAL GUPTA

PATIENT ID: 2642

COL DATE : 10/12/2022 REPORTING DATE: 10/12/2022 AGE SEX:- 38 YRS/M

REF.BY : DR. /MEDIWHEEL.

ROUTINE EXAMINATION OF URINE

PHYSICAL EXAMINATION

Quantity	30 ml	Colour... .	Straw
Appearance...	Clear	Sediment ...	Nil
Specific gravity....	1.010		

CHEMICAL EXAMINATION

Reaction	6.0	Nitrite.....	Not done
Sugar	Nil	Bile Pigment	Not done
Albumin	Nil	Urobilinogen....	Not done
Excess of Phosphate....	Nil	Chile.....	Not done
Bile Salt	Not Done	Acetone...	Not done

MICROSCOPIC EXAMINATION

Erythrocytes....	Nil	Casts	Nil
Leucocytes	1-5/ HPE	Crystals....	Nil
Epith. Cell	A, Few	Others	Nil



AK
10/12/22

Consultant Radiologist

ESTB BY:-

Dr. P. K. Tiwari
MD, M.Sc (Radio Imaging)
Ph.D (Alt Nuclear Medicine)
Consultant Imagonologist & Sonologist

Dr. S. Kumar
MD (Pat)
Consultant Pathologist

Dr. Abhishek Kumar
MBBS, MD
Consultant Neuropatho Physiologist

Dr. Kumari Suman
MBBS, DGO, MD
Consultant (TVS & HSG Specialist)

Dr. A. K. Singh
MBBS, PGDMCH
Consultant Radiologist & Sonologist

PRINTING MISTAKE SHOULD BE REPORTED BACK IMMEDIATELY/ यहाँ जन्म से पहले भ्रुण का लिंग जाँच नहीं होता है ।

ID: 2642 CASE:

KANHAIYA LAL GUPTA

10/12/2022 11:23:28

AGE: 38Y 0M 0D

MALE

ALC ADVANCE IMAGING DIAGNOSTICS
E95 PC COLONY KANKARBAGH PATNA

Cms KG

RATE : 73 bpm SINUS ARRHYTHMIA
 R-R : 820 ms POSSIBLE SEQUENCE ERROR: V2,V3 OMITTED
 P-R : 158 ms
 QRS : 100 ms
 QT : 352 ms
 QTc : 375 ms

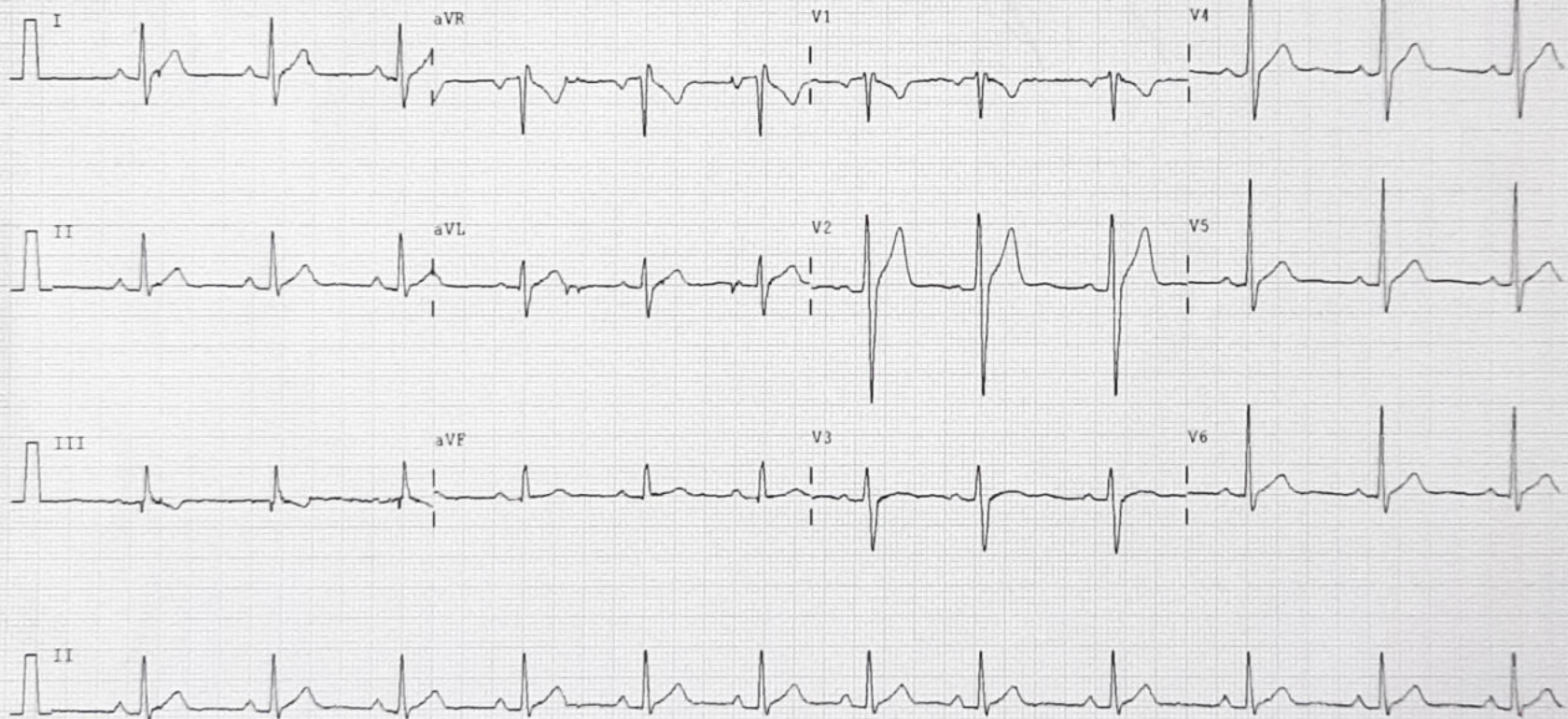
--AXIS--

P : 33°
 QRS : 57° NORMAL ECG
 T : 15°

12 SL: REPORT FORMAT: 3x4+1L SQ

REF DR B O B

Dr. DR ABHISHEK KUMAR





A.L.C. Advance Imaging Diagnostics

ISO 9001:2015 Certified center

(A Unit of Subham Imaging P.K. Arogyam Health & Wellness Center)

E-95, P.C. Colony, Near Sai Netryalaya Transformer, Kankarbagh, Patna - 20

alcdiagnostics@gmail.com

www.pkarogyamhealthcheckup.com

7050037694, 8271206196

OPINION MUST BE CORRELATES WITH CLINICALLY & OTHER INVESTIGATION FOR FINAL DIAGNOSIS. NOT FOR MEDICO LEGAL PURPOSE

ECHOCARDIOGRAPHY & COLOR DOPPLER REPORT

Patient's Name : Mr.KANHAIYA LAL GUPTA

Age/Sex : 38 Yrs /M

Ref. by : DR./ MEEDIWHEEL

Date : 11-Dec-22

ECHOCARDIOGRAPHIC WINDOW: Fair

2D & M MODE ECHOCARDIOGRAPHY

Left ventricle

EDD:	27	mm (20 - 28 mm / m ²)	ESD:	19	mm(13 - 21 mm / m ²)
IVS :	10	mm (6 - 11 mm)	PW:	8	mm(6 - 11 mm)
Ejection fraction:	60% (61 ± 8%)		FS:	35	%(34 - 44 %)
IVS:	Intact		LV clot	Absent	

Left atrium/ Aorta 34/31 mm

Right ventricle Normal

Right atrium Normal

Pericardium Normal with no pericardial effusion

2D:

Normal LA/LV Size and normally contracting left ventricle. No RWMA, concentric LVH

Mitral valve

AML/ PML: Normal

Tricuspid valve Normal

Aortic valve Normal

Pulmonary valve Normal

Continuous & Pulse Wave Doppler study

Valve	Velocity (m/sec)			Gradient (mmHg)			Valve area (PHT Method)	Regurg.
	Peak	Mean	EDV	Peak	Mean	EDG		
Mitral	E=07 A=0.6			2.3	2.0			Nil
Tricuspid	E=0.5 A=0.3			1.9	0.2			Nil
Aortic	1.12			5.0	2.5			Nil
Pulmonary	0.9			3.5	1.7			Nil

Consultant Radiologist

ESTB BY:-

Dr. P. K. Tiwari
MD, M.Sc (Radio Imaging)
Ph.D (Alt Nuclear Medicine)
Consultant Imagiologist & Sonologist

Dr. S. Kumar
MD (Pat)
Consultant Pathologist

Dr. Abhishek Kumar
MBBS, MD
Consultant Neuropatho Physiologist

Dr. Kumari Suman
MBBS, DGO, MD
Consultant (TVS & HSG Specialist)

Dr. A. K. Singh
MBBS, PGDMCH
Consultant Radiologist & Sonologist

PRINTING MISTAKE SHOULD BE REPORTED BACK IMMEDIATELY/ यहाँ जन्म से पहले भ्रुण का लिंग जाँच नहीं होता है ।

A.L.C. Advance Imaging Dignostics

ISO 9001:2015 Certified center

(A Unit of Subham Imaging P.K. Arogyam Health & Wellness Center)

E-95, P.C. Colony, Near Sai Netryalaya Transformer, Kankarbagh, Patna - 20

alcdiagnostics@gmail.com

www.pkarogayamhealthcheckup.com

7050037694, 8271206196

OPINION MUST BE CORRELATES WITH CLINICALLY & OTHER INVESTIGATION FOR FINAL DIAGNOSIS. NOT FOR MEDICO LEGAL PURPOSE

Colour Flow Imaging

No TR, No MR/PR, No AR

No flow shunt

COMMENTS :

- ◆ Normal size all chamber
- ◆ Normal LV filling Pressure
- ◆ No RWMA
- ◆ Normal LV systolic function
- ◆ Grade I LV diastolic dysfunction.
- ◆ Global LVEF = 60%
- ◆ All cardiac valves are normal
- ◆ No PAH, Mild concentric LVH
- ◆ No MS / TS / AS / PS / PR
- ◆ No clot / vegetation / pericardial effusion.

IMPRESSION:

All chambers are normal

No RWMA, No PAH

Grade I LV diastolic dysfunction.

Normal LV systolic function, LVEF – 66%

Please correlate clinically

DR. SANDEEP KUMAR MBBS MD

ESTB BY:-

Dr. P. K. Tiwari

MD, M.Sc (Radio Imaging)
Ph.D (Alt Nuclear Medicine)
Consultant Imagiologist & Sonologist

Dr. S. Kumar

MD (Pat)
Consultant Pathologist

Dr. Abhishek Kumar

MBBS, MD
Consultant Neuropatho Physiologist

Dr. Kumari Suman

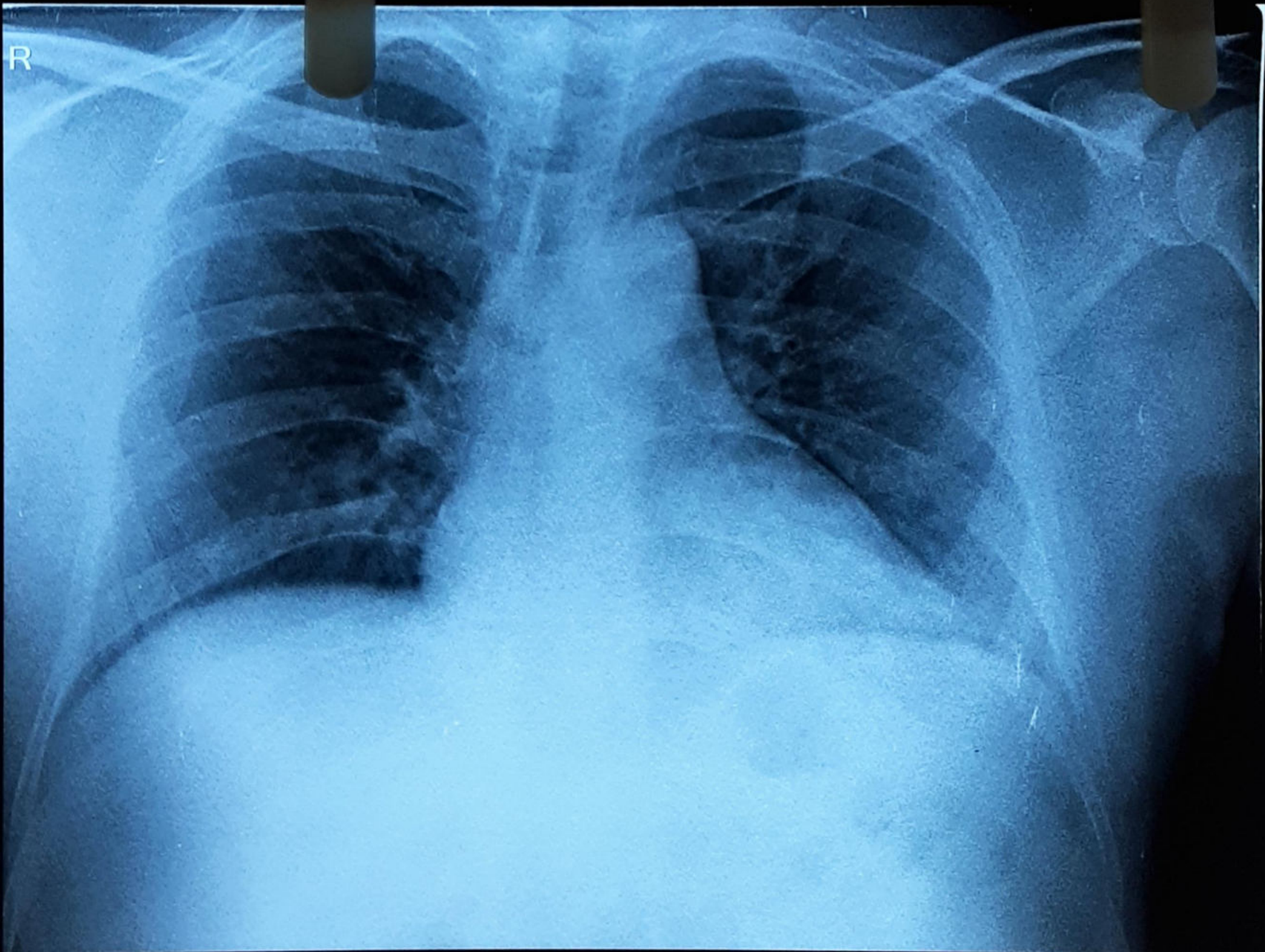
MBBS, DGO, MD
Consultant (TVS & HSG Specialist)

Consultant Radiologist

Dr. A. K. Singh

MBBS, PGDMCH
Consultant Radiologist & Sonologist

PRINTING MISTAKE SHOULD BE REPORTED BACK IMMEDIATELY/ यहाँ जन्म से पहले भ्रुण का लिंग जाँच नहीं होता है ।



KANHAIYA LAL GUPTA 38YRS. 2642 DR. B O B CHEST,FRN P->A 12/09/2022

A.L.C. Advance Imaging Diagnostics Centre PATNA - 20



Pl. Name :- KANHAIYA LAL GUPTA

Ref. By :- DR / MEEDIWHEEL

Date:- 11-Dec-22

Age / Sex - 38 Yrs. M.

Thanks for your kind referral

X-RAYCHEST (P.A.VIEW)

The lungs on the either side show equal translucency.

The peripheral pulmonary vasculature is normal.

No focal lung lesion is seen.

The pleural spaces are normal.

Both hila are normal in size, have equal density and bear normal relationship.

The heart and trachea are central in position and no mediastinal abnormality is visible.

The cardiac size is normal.

The domes of the diaphragms are normal in position, and show smooth outline.

IMPRESSION

- NO EVIDENCE OF PULMONARY OR CARDIAC PATHOLOGY IS NOTED.

Consultant Radiologist

ESTD BY:-

Dr. P. K. Tiwari

MD, M.Sc (Radio Imaging)

Ph.D (AI) Nuclear Medicine

Consultant Imaginologist & Sonologist

Dr. S. Kumar

MD (Path)

Consultant Pathologist

Dr. Abhishek Kumar

MBBS, MD

Consultant Neuropatho Physiologist

Dr. Kumari Suman

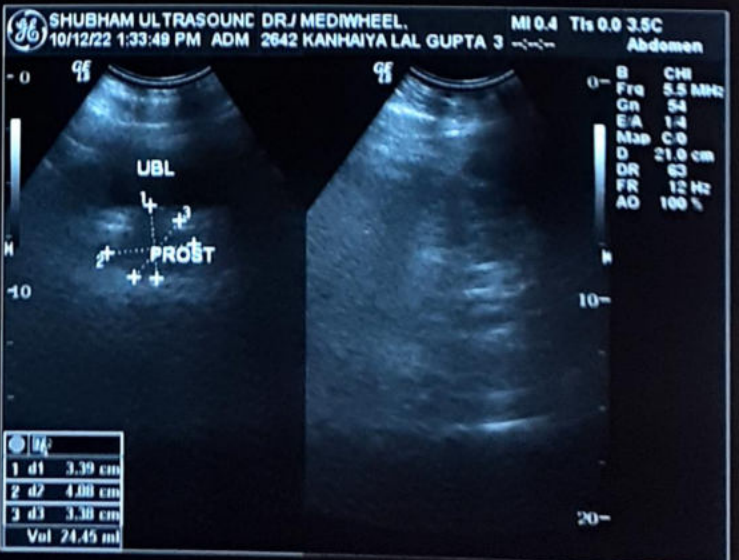
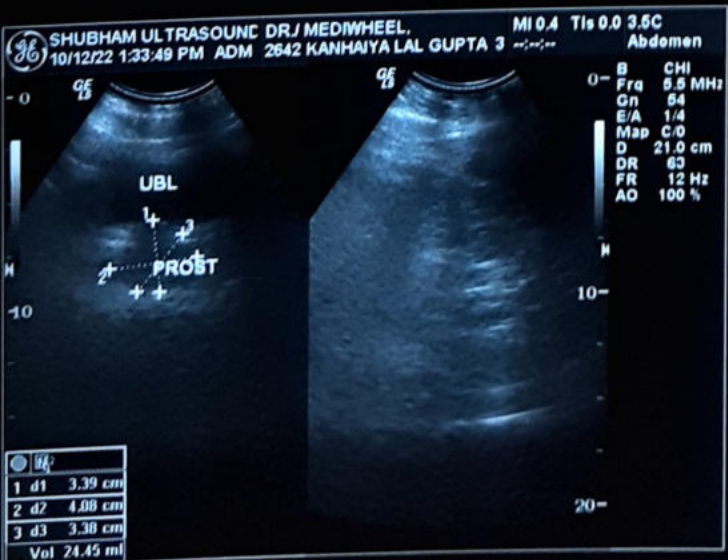
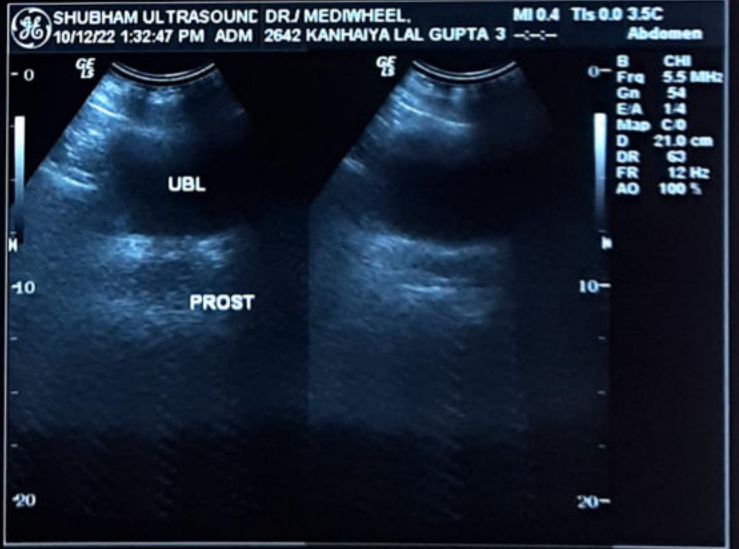
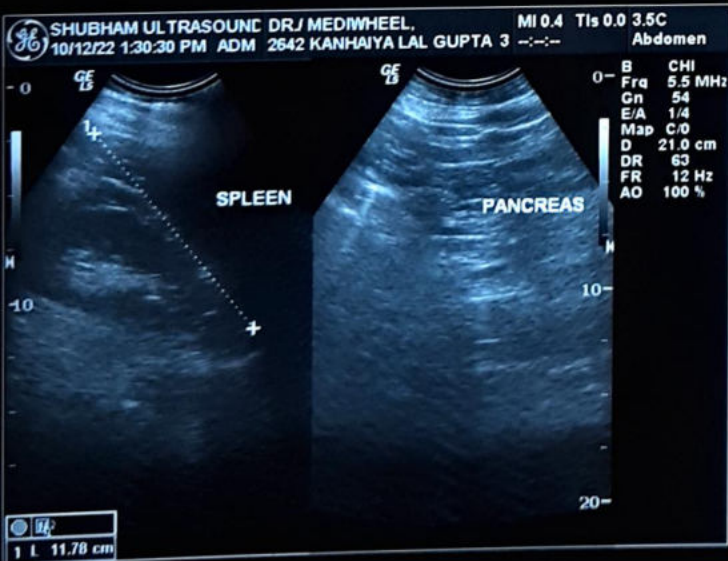
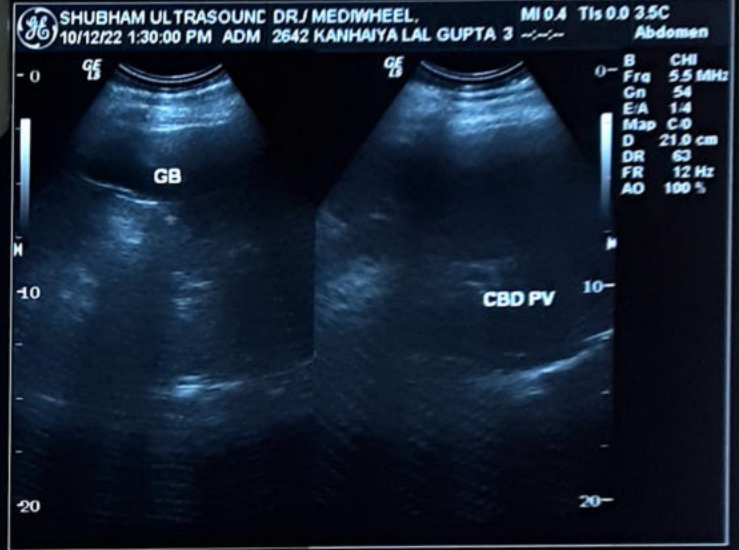
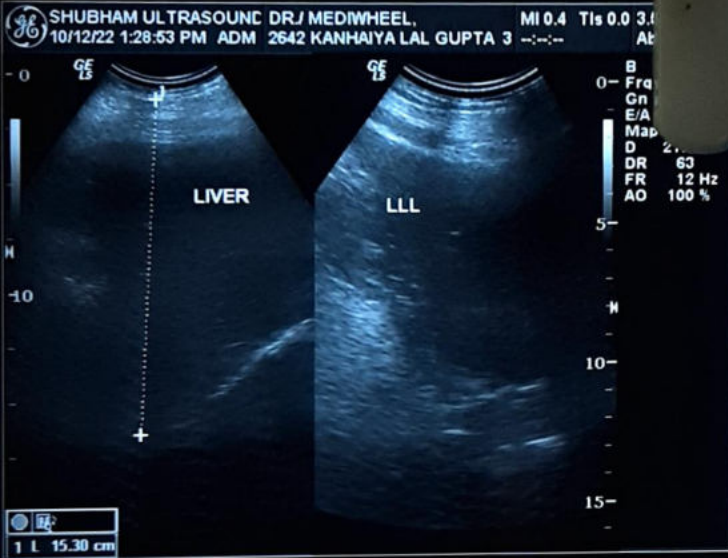
MBBS, DGO, MD

Consultant (TVS & HSG Specialist)

Dr. A. K. Singh

MBBS, PGDMCH

Consultant Radiologist & Sonologist





A.L.C. Advance Imaging Dignostics

ISO 9001:2015 Certified center

(A Unit of Subham Imaging P.K. Arogyam Health & Wellness Center)

E-95, P.C. Colony, Near Sai Netryalaya Transformer, Kankarbagh, Patna - 20

alcdiagnostics@gmail.com

www.pkarogayamhealthcheckup.com

7050037694, 8271206196

OPINION MUST BE CORRELATES WITH CLINICALLY & OTHER INVESTIGATION FOR FINAL DIAGNOSIS. NOT FOR MEDICO LEGAL PURPOSE

Pt. Name :- **KANHAIYA LAL GUPTA**

Ref. By :- **DR /MEEDIWHEEL**

Date:- **10-Dec-22**

Age / Sex – **38 Yrs. M.**

REAL TIME U.S.G. OF WHOLE ABDOMEN

Thanks for your kind referral

(Report.)

LIVER :- Measures 15.30 cm. Mild Enlarged in shape , size and echo texture fatty change seen in liver parenchyma .I.H.B.R. are not dilated.

Hepatic veins are normal. No SOL seen.

G.BL. :- Lumen is echo free. Wall thickness appears normal.

C.B.D. :- Measures 3.5 mm in diameter with echo free lumen. No calculi or mass seen.

P.V. :- Measures 7.7 mm in diameter. Appears normal. No thrombus seen.

PANCREAS :- Normal in shape, size and echo texture. No calcification mass seen.

SPLEEN :- Measures 11.78 cm. Normal in shape, size and echo texture.
No SOL seen.

KIDNEY :- Both kidney shows normal shape, size & echotexture. C.M.D.intact.
P.C.S.is not dilated. No calculi, cyst or hydronephrosis seen on either side.

Right Kidney :- Measures 9.40 X 4.50 cm.

Left Kidney :- Measures 9.80 X 4.70 cm.

URETER :- Not dilated .No apparent calculi seen.

U.BLADDER:- Shows normal in outline with echo free lumen. No calculi or mass seen.

Pre void – 320 ml. Post void – is in significant

PROSTATE :- Measures 24 gms.(approx). Mild Enlarged in size, shape, and echo texture.

No calcification , mass ,growth seen. capsule is intact.

R.I.F. :- Son graphically no appendicular mass or collection seen.

OTHERS :- No Ascites . no Lymph Adenopathy. No pleural effusion seen on either side .

IMPRESSION

- **Mild Hepatomegaly With fatty liver G-I**
- **Mild Enlarged Prostate (BPH) Grade I with 40 ml PVR**
- **Adv:- Further work up/other investigation**
Otherwise son graphically normal scan. of rest organs

Handwritten signature and date: 10/12/22

ESTB BY:-

Consultant Radiologist

Dr. P. K. Tiwari
MD, M.Sc (Radio Imaging)
Ph.D (Alt Nuclear Medicine)
Consultant Imagiologist & Sonologist

Dr. S. Kumar
MD (Pat)
Consultant Pathologist

Dr. Abhishek Kumar
MBBS, MD
Consultant Neuropathology Physiologist

Dr. Kumari Suman
MBBS, DGO, MD
Consultant (TVS & HSG Specialist)

Dr. A. K. Singh
MBBS, PGDMCH
Consultant Radiologist & Sonologist

PRINTING MISTAKE SHOULD BE REPORTED BACK IMMEDIATELY/यहाँ जन्म से पहले भ्रुण का लिंग जाँच नहीं होता है ।