

**DR. MAHENDRA CHOURASIYA**  
M.D.,D.M.  
CONSULTANT CARDIOLOGIST

**UNIQUE DIAGNOSTIC CENTRE**  
45-B, Jaora Compound,  
Opp. M.Y.Hospital, M.Y.H. Road,  
INDORE - 452 001. ( M. P. ).  
Phone : 2704118. 4082228

## **ECHOCARDIOGRAPHY REPORT**

NAME : MRS. SWATINAHETA Age : 37 Yrs/ F  
REFERRED BY : BOB Date : 30th Mar, 2023

### **ECHOCARDIOGRAPHIC OPINION**

INTERPRETATION :-

- \*\* Normal sized cardiac chambers.
- \*\* Normal biventricular functions. LVEF : 60 %.
- \*\* Normal cardiac valves.

**DR. MAHENDRA CHOURASIYA. M.D.,D.M.**  
Dr. Mahendra Chourasiya  
M.D., D.M. (Cardio)



---

## TWO DIMENSIONAL ECHOCARDIOGRAPHY

---

M Mode examination revealed normal movement of both mitral leaflets during diastole.

No SAM or mitral valve prolapse is seen.

Aortic cusps are not thickened and enclosure line is central.

Tricuspid valve is normal, pulmonary valve is normal, aortic root is normal in size, dimensions of left atrium and left ventricle are normal.

2 - D imaging in PLAX, SAX and apical views revealed a normal sized left ventricle.

Movement of septum, anterior, posterior, inferior and lateral walls is normal. Global LVEF is 60 %.

Mitral valve opening is normal. No evidence of mitral valve prolapse is seen.

Aortic valve has three cusps and its opening is not restricted.

Right atrium and right ventricle are normal in size.

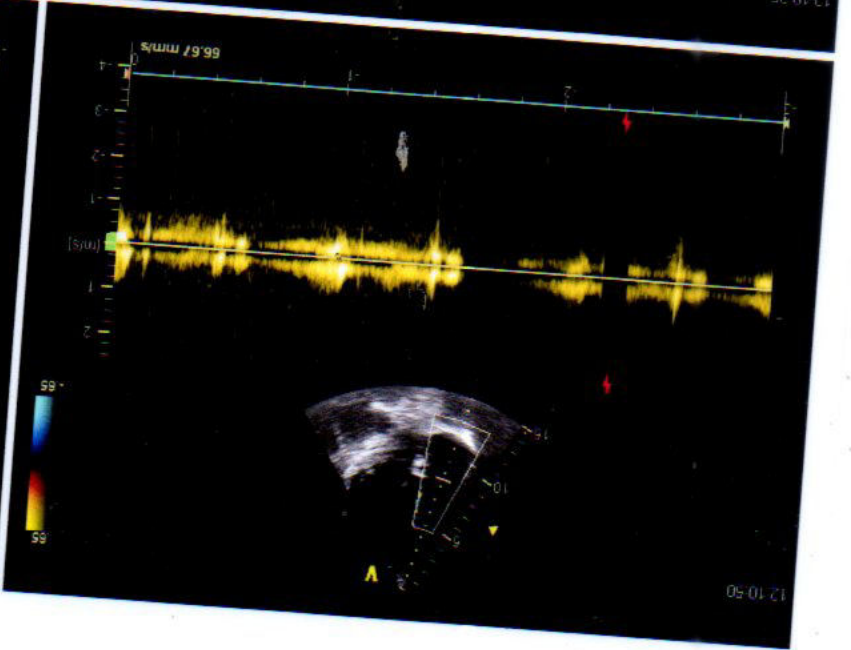
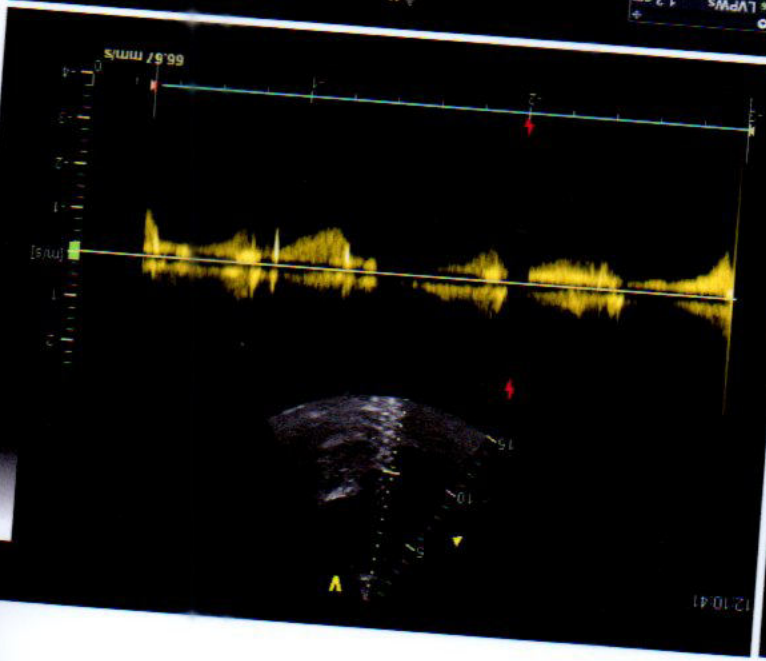
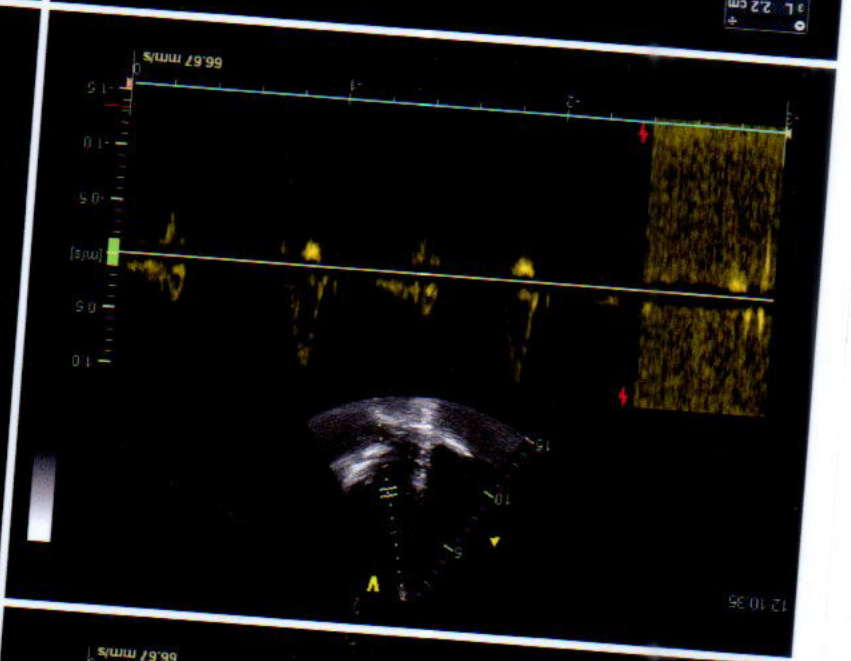
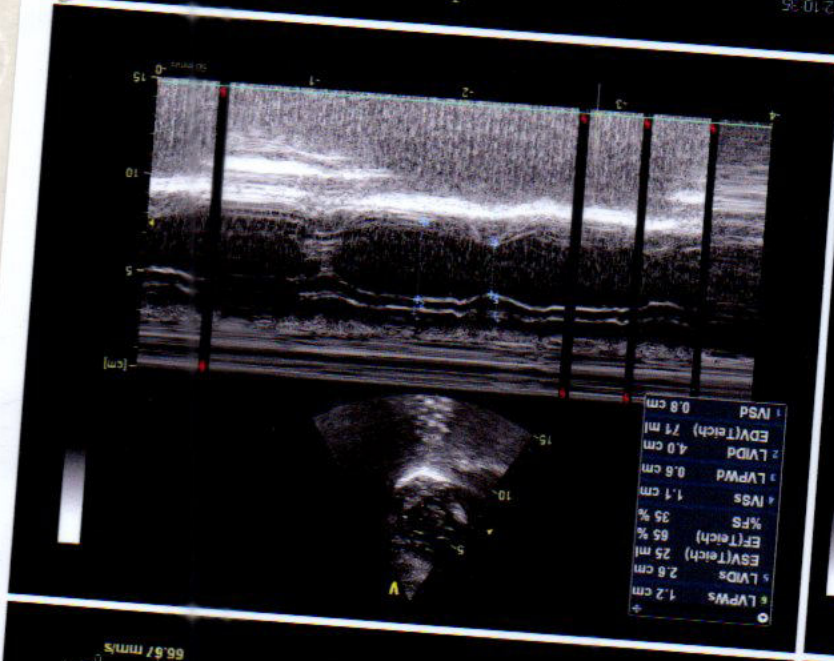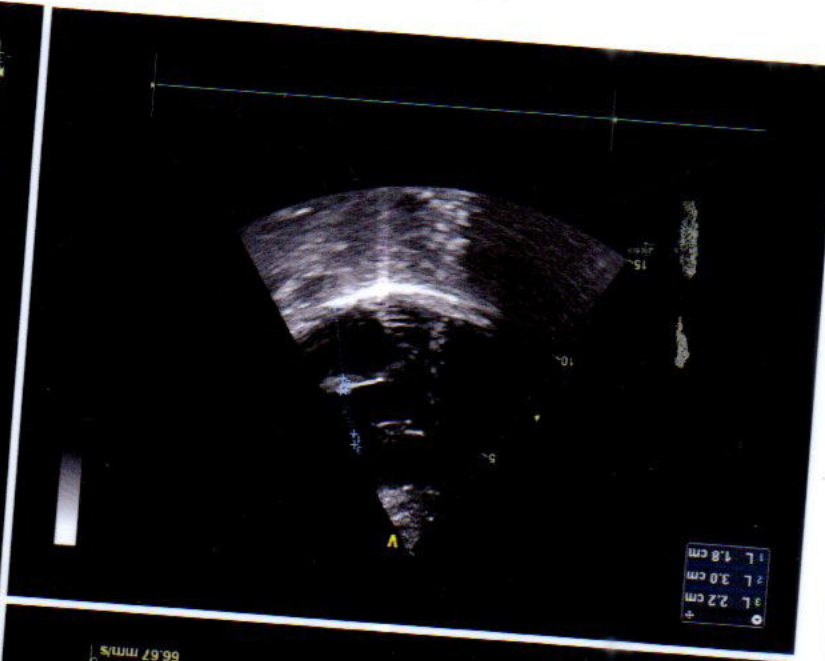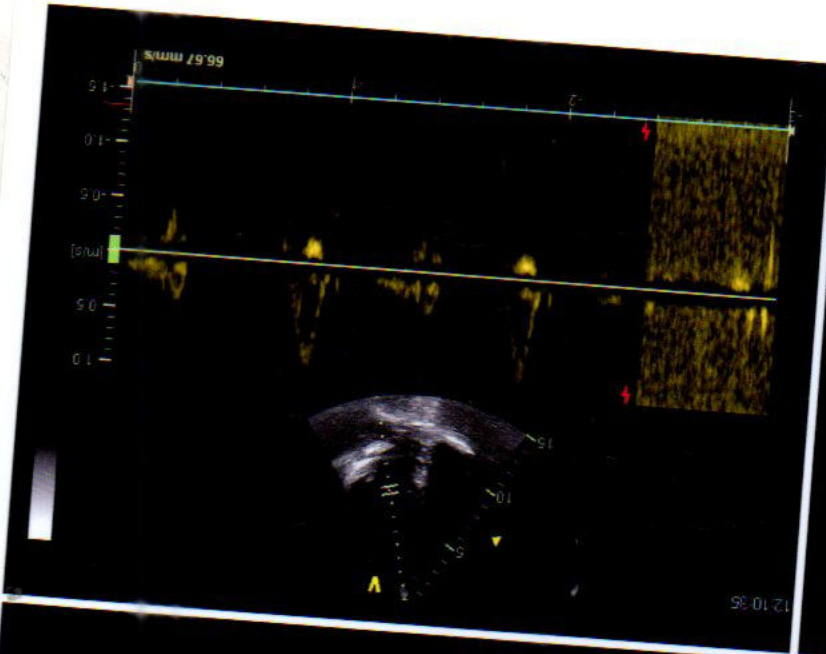
Tricuspid valve leaflets move normally.

Pulmonary valve is normal.

Interatrial and interventricular septa are intact.

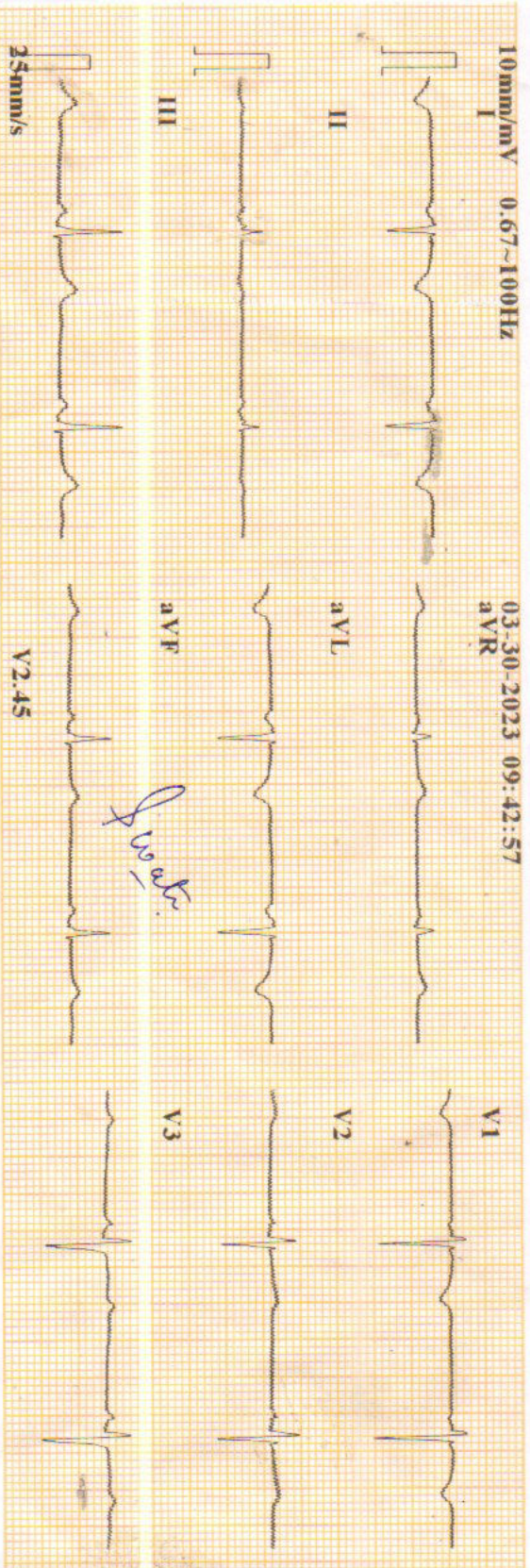
No intracardiac mass or thrombus is seen.

No pericardial pathology is observed.



10mm/mV 0.67~100Hz

03-30-2023 09:42:57



CARDIART

BPL

ID	: 230330-0943
Name	: Sweet
Age	: 37 yr
Sex	: Female
BP	: mmHg
Height	: cm
Weight	: kg
HR	: 55 bpm
P Dur	: 68 ms
PR int	: 104 ms
QRS Dur	: 94 ms
QT/QTc int	: 440/424 ms
P/QRS/T axis	: 76/117/131 °
RV5/SV1 amp	: 0.881/1.031 mV
RV5+SV1 amp	: 1.912 mV
RV6/SV2 amp	: 1.479/0.729 mV

NAME Mrs. Sweet  
 Age 27/A  
 Date 30/03/2023

*Handwritten signature*

Dr. Mahendra Chourasiya  
 M.D. (D.M. (Cardio))

