

Patient's name	: VISHAL VINODCHANDRA PATEL	Age/Sex	: 30 Years/Male
Referred by	: Self	Reg. No	: 4426
Date	: 02/10/2021	Mobile	: 9428341499
Patient's Id	: VP331	Ref ID.	:

Fitness Certificate

GENERAL EXAMINATION

Height (cms) : 175

Weight (kgs) : 74.7

Blood Pressure : 120/80mmHg

Pulse : 76/Min

No Clubbing/Cynosis/Pallor/Pedel Oedem

Systemic Examination:

Cardio vascular System - S1,S2 Normal, No Murmur

Respiratory system - AEBE

Central Nervous System - No FND


Abdomen - Soft, Non Tender, No Organomegaly

Comments : He is clinically fit on examination


----- End of Report -----

This is an electronically authenticated report.
Note:(LL-Very Low, L-Low, HH-Very High)

Approved On : 02/10/2021 3:25:00 PM
Generated On : 02/10/2021 15:31



Dr Jinen M Shah
DNB (Medicine)FCCS (USA)



Vishal

ધારક કે રાખક
Signature of Holder


નામ
Name: Vishal Vinodvandre Patel

કર્મચોરી કોડ નં.
Employee Code No: 125656

WNS Shah
આપણાં પુસ્તકાળી
Issuing Authority

Shah

Shah
Dr. Jinen M. Shah
DNB (Medicine) FRCGS (USA)
Reg. No.: G-20693



Patient's name : VISHAL VINODCHANDRA PATEL	Age/Sex : 30 Years/Male
Referred by : Self	Reg. No : 4426
Date : 02/10/2021	Mobile : 9428341499
Patient's Id : VP331	Ref ID. :


HEMOGRAM REPORT

Performed on 5-Part Fully Auto Hematology Analyzer SIEMENS ADVIA 2120i

Test	Result	Unit	Biological Reference Interval
Sample Type:	EDTA		
Haemoglobin:	13.5	gm/dL	13.5 - 18.0
Total WBC Count:	5600	/microlitre	4000 - 10500
Platelets Count:	348000	/microlitre	1,50,000 - 4,50,000
Differential Count:			
Neutrophils:	56	%	40-80
Lymphocytes:	38	%	20-40
Eosinophils:	02	%	Upto 6
Monocytes:	04	%	2-10
Basophils:	00	%	<1-2
RBC indices:			
RBC Count:	4.45	*10 ⁶ /microL	4.5 - 5.5
HCT:	41.8	%	40 - 50
MCV:	93.9	fL	83-101
MCH:	30.3	pg	27-32
MCHC:	32.3	%	31.5-34.5
RDW:	13.9	%	11.6 - 14.0
Erythrocytes Sedimentation Rate(ESR): (By AUTO ESR-10, USA)			
ESR 1st Hr:	04	mm	2 - 15 mm in 1Hr.
Thick Smear Preparation:			
Haemoparasite:	Malarial parasites are not seen.		
Peripheral Smear Examination:			
RBCs:	Normocytic & Normochromic.		
Platelet:	Platelet adequate & normal on smear.		

This is an electronically authenticated report.
Note:((LL-Very Low, L-Low, HH-Very High)

Approved On : 02/10/2021 15:54:00
Generated On : 04/10/2021 14:26



End of Report


Dr. KEYUR Patel
M.B.DCP

Patient's name : VISHAL VINODCHANDRA PATEL
Referred by : Self
Date : 02/10/2021
Patient's Id : VP331

Age/Sex : 30 Years/Male
Reg. No : 4426
Mobile : 9428341499
Ref ID. :

BLOOD GROUP

Sample Type: EDTA
ABO Group : "O"
Rh Type : Positive

BLOOD GLUCOSE LEVEL

Test	Result	Unit	Biological Reference Interval
Sample Type:	Flouride		
Fasting Blood Glucose (Hexokinase) Collection Time:	87.8	mg/dl	70-110
Collection Time: Post Prandial Blood Glucose (2 Hrs) (Hexokinase)	102.7	mg/dl	80-140

Tests Performed on Fully Auto DRY Chemistry Analyzer VITROS-250

----- End of Report -----


Dr. KEYUR Patel
M.B.DCP

This is an electronically authenticated report.
Note:(LL-Very Low, L-Low, HH-Very High)

Approved On : 04/10/2021 13:11:00
Generated On : 04/10/2021 14:26



Patient's name : VISHAL VINODCHANDRA PATEL
Referred by : Self
Date : 02/10/2021
Patient's Id : VP331

Age/Sex : 30 Years/Male
Reg. No : 4426
Mobile : 9428341499
Ref ID. :

GLYCOSYLATED HAEMOGLOBIN (HbA1C) ESTIMATION

Test	Result	Unit	Biological Reference Interval
Sample Type: EDTA			
Glycosylated Haemoglobin (HbA1C)	4.80	%	Pre-Diabetic (Adult): 5.7 - 6.4 Diabetic (Adult): >6.5 Therapeutic goal for glycemic control: <7.0
Mean Blood Glucose Level (An average of 2 -3 Months)	91.06		

Method : HPLC on D-10, Bio-Rad,USA

INTERPRETATION:

- * Blood sample can be drawn at any time. Fasting is not required.
- * Reflects average blood sugar levels for the 2 to 3 months period before the test.
- * Provides information for evaluating diabetic treatment modalities and tracks control of blood glucose of particular value in diabetic children, diabetics in whom the renal threshold for glucose is abnormal, unstable insulin dependent diabetics where blood sugars vary markedly from day to day.
- * High value in poorly controlled DM and moves towards normal in patients with optimal control.


----- End of Report -----



Dr. KEYUR Patel
M.B.DCP

This is an electronically authenticated report.
Note:((LL-Very Low, L-Low, HH-Very High)

Approved On : 02/10/2021 15:54:00
Generated On : 04/10/2021 14:26



Patient's name : VISHAL VINODCHANDRA PATEL
 Referred by : Self
 Date : 02/10/2021
 Patient's Id : VP331

Age/Sex : 30 Years/Male
 Reg. No : 4426
 Mobile : 9428341499
 Ref ID. :

LIPID PROFILE

(Performed on Semi Auto Chemistry Analyzer BeneSphera)


Test	Result	Unit	Biological Reference Interval
Sample Type: Fasting Serum			
S.Cholesterol (Oxidase Peroxidase)	166	mg/dL	< 200 Desirable 200-239 Boderline High > 240 High
S.HDLC (Direct) (Phosphotungsstic Acid)	42.9	mg/dL	< 40 Low > 60 High
S.Triglyceride (GPO-POD)	96.1	mg/dL	< 150 mg/dl Normal 150-199 Boderline High 200-499 High > 500 Very High
S.VLDL (Calculated)	19.22	mg/dL	10-40 Normal
S.LDLC (Calculated)	103.88	mg/dL	< 100 Optimal 100-129 Near to above optimal 130-159 Boderline high 160-189 High >190 Very High
S.Cholesterol / HDLC Ratio (Calculated)	3.87		< 4 Normal 4-6 Borderline 6-8 Risklevel > 8 High Risk
S.LDLC / HDLC Ratio (Calculated)	2.42		< 3 Normal 3-4 Borderline 4-6 Risk Level > 6 High Risk
Cholesterol / HDLC Ratio (Calculated)	3.87		< 3.5 Normal
Triglyceride / HDLC Ratio (Calculated)	2.24		< 2 Normal > 4 Risk Level > 6 High Risk
Non HDLC (Calculated)	123.1		< 130 Normal 130 - 159 Near Normal 160 - 189 Borderline 190 - 219 Risklevel > 220 High Risk

----- End of Report -----


 Dr. KEYUR Patel
 M.B.DCP

This is an electronically authenticated report.
 Note:((LL-Very Low, L-Low, HH-Very High)

Approved On : 02/10/2021 15:54:00
 Generated On : 04/10/2021 14:25



'B' Block, Mondeal Business Park, Near Gurudwara, Bodakdev, S.G. Highway, Ahmedabad-380054, Gujarat.

Patient's name : VISHAL VINODCHANDRA PATEL
Referred by : Self
Date : 02/10/2021
Patient's Id : VP331

Age/Sex : 30 Years/Male
Reg. No : 4426
Mobile : 9428341499
Ref ID. :

LIVER FUNCTION TEST

(Performed on Fully Auto DRY Chemistry Analyzer VITROS-250)

Test	Result	Unit	Biological Reference Interval
Sample Type: Serum			
S.Bilirubin			
Total Bilirubin (Azobilirubin)	0.48	mg/dl	0 - 1.2
Conjugated Bilirubin (Dual Wavelength spectrophotometric)	0.11	mg/dl	0 - 0.4
Unconjugated Bilirubin (Dual Wavelength spectrophotometric)	0.37	mg/dl	0.0 - 1.1
S.G.P.T. (ALT) (Kinetic with Pyridoxal 5-Phosphate)	25.9	IU/L	0 - 49
S.G.O.T. (AST) (Kinetic with Pyridoxal 5-Phosphate)	18.9	IU/L	Up to 46
S.ALP (Alkaline Phosphatase) (4-Nitrophenyl phosphate)	154.7	U/L	80 - 306
S.Protein			
Total Protein (Biuret)	7.28	gm/dl	6.3 - 8.2
Albumin (BCG)	4.95	gm/dl	3.5 - 5.2
Globulin (Calculated)	2.33	gm/dl	1.9 - 3.5
Albumin Globulin Ratio	2.12		
S.GammaGT (L-Gamma Glutamyl-4-Nitroanalide)	22.4	IU/L	15-73

SERUM LDH LEVEL

Test	Result	Unit	Biological Reference Interval
Sample Type: Serum			
LDH Activity (Lactate Dehydrogenase): Pyruvate to lactate Kinetic Method	132.00	U/L	120 - 246


#Tests Performed on Fully Auto DRY Chemistry Analyzer VITROS-250

----- End of Report -----


 Dr. KEYUR Patel
 M.B.DCP

This is an electronically authenticated report.
 Note:((LL-Very Low, L-Low, HH-Very High)

Approved On : 02/10/2021 15:54:00
 Generated On : 04/10/2021 14:26



'B' Block, Mondeal Business Park, Near Gurudwara, Bodakdev, S.G. Highway, Ahmedabad-380054, Gujarat.

Patient's name : VISHAL VINODCHANDRA PATEL
Referred by : Self
Date : 02/10/2021
Patient's Id : VP331

Age/Sex : 30 Years/Male
Reg. No : 4426
Mobile : 9428341499
Ref ID. :

RENAL FUNCTION TEST

(Performed on Fully Auto DRY Chemistry Analyzer VITROS-250)

Test	Result	Unit	Biological Reference Interval
Sample Type: Serum			
S.Urea (Urease with indicator dye)	17.9	mg/dl	Male: 19.6-43.6 Female: 15.2-37.0
S.Creatinine (Enzymatic)	0.82	mg/dL	0.55 - 1.30
S.Uric Acid (Uricase)	3.54	mg/dL	Male: 3.5-8.5 Female: 2.5-6.2

Prostate Specific Antigen

(Carried out on miniVIDAS, Biomerieux)


Test	Result	Unit	Reference Interval
S.PSA : (Prostate Specific Antigen)	0.280	ng/ml	M : Healthy Male upto 4.00

----- End of Report -----


Dr. KEYUR Patel
M.B.DCP

This is an electronically authenticated report.
Note:((LL-Very Low, L-Low, HH-Very High)

Approved On : 02/10/2021 15:54:00
Generated On : 04/10/2021 14:26



Patient's name : VISHAL VINODCHANDRA PATEL
Referred by : Self
Date : 02/10/2021
Patient's Id : VP331

Age/Sex : 30 Years/Male
Reg. No : 4426
Mobile : 9428341499
Ref ID. :

THYROID FUNCTION TEST
(by CLIA on SIEMENS ADVIA Centaur XP)


Test	Result	Unit	Biological Reference Interval
Sample Type: Serum			
S.T3 (Total Triiodothyronine by CLIA)	1.46	ng/mL	1 - 23 Months: 1.17 - 2.39 2 - 12 Years: 1.05 - 2.07 13 - 20 Years: 0.86 - 1.92 Adult: 0.6 - 1.81
S.T4 (Total Thyroxine by CLIA)	6.70	mcg/dL	3.2 - 12.6
S.TSH (Thyroid Stimulating Hormone by CLIA)	2.447	microU/mL	0 -12 Yrs: 0.77 - 5.64 12-19 Yrs: 0.75-3.69 19-100 Yrs: 0.35 -5.50

----- End of Report -----


Dr. KEYUR Patel
M.B.DCP

This is an electronically authenticated report.
Note:((LL-Very Low, L-Low, HH-Very High)

Approved On : 02/10/2021 15:54:00
Generated On : 04/10/2021 14:26



Patient's name : VISHAL VINODCHANDRA PATEL
 Referred by : Self
 Date : 02/10/2021
 Patient's Id : VP331

Age/Sex : 30 Years/Male
 Reg. No : 4426
 Mobile : 9428341499
 Ref ID. :

URINE ROUTINE ANALYSIS

Sample Type: Fresh Urine

Physical Examination

(Naked Eye Observation)

Physical Examination	Result	Biological Ref. Value
Amount	20 ml	>10 ml
Colour	Pale Yellow	Pale Yellow
Appearance	Clear	Clear

Chemical Examination

pH (Dip stick)	7.5	4.5-8.0
Specific Gravity (Bromothymol Blue)	1.015	1.002-1.030
Albumin (Tetrabromophenol)	Absent	Absent
Glucose (Specific Glucose Oxidase/Peroxidase)	Absent	Absent
Bilirubin (Azo-coupling reaction)	Absent	Absent
Acetone (Sodium Nitroprusside Reaction)	Absent	Absent
Urobilinogen (Modified Ehrlich Reaction)	Absent	Absent
Nitrites (Diazolization Reaction)	Absent	Absent

Microscopic Examination

(After centrifugation at 1500 RPM for 10min./hpf)


Pus Cells(WBCs)	Absent	Absent
Red Blood Cells(RBCs)	Absent	Absent
Epithelial cells	Absent	
T.Vaginals	Absent	Absent
Spermatozoa	Absent	Absent
Casts	Absent	Absent
Crystals	Absent	Absent
Amorphous Material	Absent	Absent

----- End of Report -----


 Dr. KEYUR Patel
 M.B.DCP

This is an electronically authenticated report.
 Note:((LL-Very Low, L-Low, HH-Very High)

Approved On : 02/10/2021 15:54:00
 Generated On : 04/10/2021 14:26



'B' Block, Mondeal Business Park, Near Gurudwara, Bodakdev, S.G. Highway, Ahmedabad-380054, Gujarat.

Patient's name	: VISHAL VINODCHANDRA PATEL	Age/Sex	: 30 Years/Male
Referred by	: Self	Reg. No	: 4426
Date	: 02/10/2021	Mobile	: 9428341499
Patient's Id	: VP331	Ref ID.	:

Electrocardiogram

Findings

Normal Sinus Rhythm.


Within Normal Limit.

----- End of Report -----

This is an electronically authenticated report.
Note:((LL-Very Low, L-Low, HH-Very High)

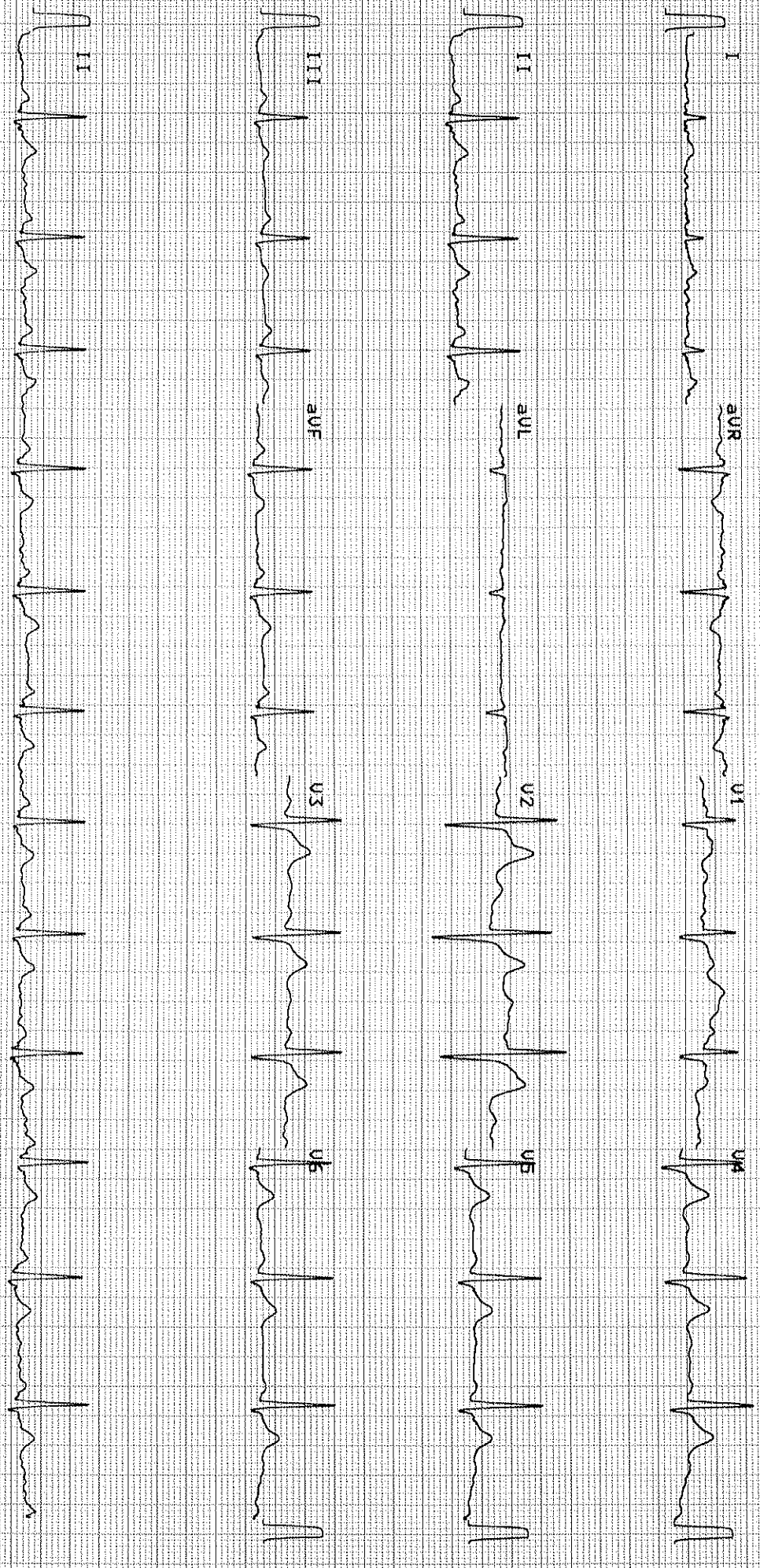

Dr Jinen M Shah
Dir (Medicine) FCCS (USA)

Approved On : 02/10/2021 3:26:00 PM
Generated On : 02/10/2021 15:31



Ushah
Patel
7
30 years
175 cm / 75 kg
Male

HR 76/min
Axis: P 66°
QRS 67°
T 47°
Intervals: RR 787 ms
P 112 ms
PR 134 ms
QRS 102 ms
QT 354 ms
QTc 402 ms
(Bazett)
10 mm/mV



10 mm/mV
25 mm/s
0.05-25 Hz F50 55F 59S 22.10.2021 10:34:09
CURIOUS HEALTHCARE
ST-1020ms 1.24

Patient's name	: VISHAL VINODCHANDRA PATEL	Age/Sex	: 30 Years/Male
Referred by	: Self	Reg. No	: 4426
Date	: 02/10/2021	Mobile	: 9428341499
Patient's Id	: VP331	Ref ID.	:

2D Echo Colour Doppler

OBSERVATION:

2 D Echo and color flow studies were done in long and short axis, apical and Sub costal views.

1. Normal LV size. No RWMA at rest.
2. Normal RV and RA. No Concentric LVH.
3. All Four valves are structurally normal.
4. Good LV systolic function. LVEF = 60%.
5. Normal LV Compliance.
6. Trivial TR. Mild MR. No AR.
7. Mild PAH. RVSP = 40 mmHG.
8. Intact IAS and IVS.
9. No Clot, No Vegetation.
10. No pericardial effusion.

CONCLUSION

1. Normal LV size with Good LV systolic function.
2. No Concentric LVH . Normal LV Compliance
3. Trivial TR with Mild PAH. Mild MR. No AR
4. No RWMA at rest.

This echo doesn't rule out any kind of congenital cardiac anomalies.


----- End of Report -----



Dr Jinen M Shah
DND (Medicine) FCCS (USA)

This is an electronically authenticated report.
Note:((LL-Very Low, L-Low, HH-Very High)

Approved On : 02/10/2021 3:25:00 PM
Generated On : 02/10/2021 15:31



Patient's name : VISHAL VINODCHANDRA PATEL
Referred by : Self
Date : 02/10/2021
Patient's Id : VP331

Age/Sex : 30 Years/Male
Reg. No : 4426
Mobile : 9428341499
Ref ID. :

X RAY CHEST PA

Both lung fields appear clear.

No evidence of any active infiltrations or consolidation.

Cardiac size appears within normal limits.

Both costo-phrenic angles appear free of fluid.

Both domes of diaphragm appear normal.

Bony thorax appears normal.

COMMENT: No significant abnormality is detected.

----- End of Report -----

Dr. Jaimin Shah
DMRD
Consultant Radiologist

This is an electronically authenticated report.
Note:((LL-Very Low, L-Low, HH-Very High)

Approved On : 02/10/2021 2:56:00 PM
Generated On : 02/10/2021 14:56



Patient's name : VISHAL VINODCHANDRA PATEL
Referred by : Self
Date : 02/10/2021
Patient's Id : VP331
Age/Sex : 30 Years/Male
Reg. No : 4426
Mobile : 9428341499
Ref ID. :

USG ABDOMEN

Liver appears normal in size, show homogenous parenchymal echo. No evidence of focal solid or cystic lesion seen. No evidence of dilatation of intra-hepatic biliary or portal radicals. PV is normal in caliber.
Gall bladder is normally distended. No evidence of calculus or mass seen. Gall bladder wall thickness appears normal.
Pancreas Visualized portion appears normal in size and echopattern. No evidence of focal lesions.
Spleen appears normal in size & normal in echopattern. No evidence of focal lesions.

Both kidneys are normal in size, shape and position. C.M. differentiation on both sides is maintained. No evidence of hydronephrosis, calculus or solid mass on either side.
Urinary bladder contour is normal, No evidence of calculus or mass.
Prostate is normal in size and show homogenous echo, outline is smooth.
No evidence of para-aortic lymph adenopathy.
No evidence of dilated small bowel loops.
No evidence of free fluid in peritoneal cavity.

COMMENTS :

NO SIGNIFICANT ABNORMALITY DETECTED


----- End of Report -----

Jms

Dr. Jalmin Shah
DMRD
Consultant Radiologist

This is an electronically authenticated report.
Note:((LL-Very Low, L-Low, HH-Very High)

Approved On : 02/10/2021 2:57:00 PM
Generated On : 02/10/2021 14:57



Patient's name : VISHAL VINODCHANDRA PATEL Age/Sex : 30 Years/Male
Referred by : Self Reg. No : 4426
Date : 02/10/2021 Mobile : 9428341499
Patient's Id : VP331 Ref ID. :

Eye Check - Up

RIGHT EYE

SP: +0.00
CY: -1.75
AX: 87

LEFT EYE

SP: -1.00
CY: -0.25
AX: 108

	Without Glasses	With Glasses
Right Eye	6/6	6/5
Left Eye	6/6	6/5

Near Vision: Right Eye -N/6, Left Eye - N/6

Fundus Examination: Within Normal Limits.

Colour Vision: Normal

Comments: Normal

Dr.Kejal Patel
MB,DO(Ophth)

Approved On : 02/10/2021 3:27:00 PM
Generated On : 02/10/2021 15:31

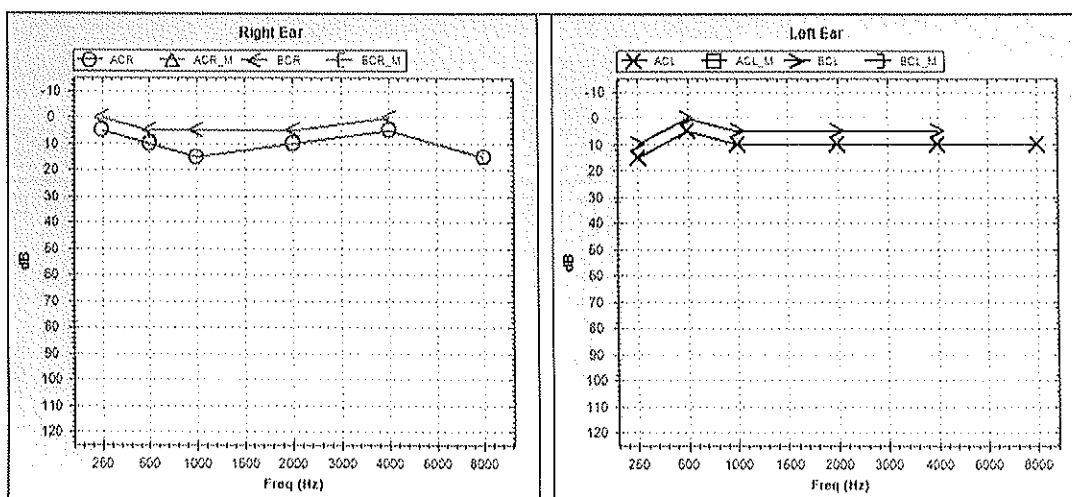


CLIENT NAME: -VISHAL PATEL.

AGE:- 30Y/ M

DATE:- 02/10/2021

AUDIOGRAM



EAR	MODE	Air Conduction		Bone Conduction		Colour Code	Threshold In dB	RIGHT	LEFT
		Masked	UnMasked	Masked	UnMasked				
LEFT		□	×	☐	>	Blue		10.5	10.5
RIGHT		△	○	☐	<	Red			
NO RESPONSE : Add ↓ below the respective symbols							SPEECH		

Comments:-

Bilateral Hearing Sensitivity Within Normal Limits.

