



H Swaminarayan Nagar, Off Mumbai-Agra Highway,
Panchvati, Nashik - 422 003.

+91- 253 - 2510250 / 350 / 450 / 550 / 750

apollonashik@apollohospitals.com

www.askapollo.com

QFAHN/BILL/003/V1



Name : Mrs. MANJUSHA VIVEK MULAY (59 /F)

Date : 22/10/2022

Address : PLOT NO 36 SHRI NIVAS VIDHATA NAGAR WADDA SHIVAR NASHIK, NASHIK,
NASHIK, MAHARASHTRA, INDIA

Examined by:

UHID : MHN1.0000127303

Package : MediWheel Full Body Health Checkup Female Above 40
Package

AHC No : NSKAH28055

CHIEF COMPLAINTS

For corporate health checkup
No specific complaints

PRESENT KNOWN ILLNESS

Present known illness

No history of : - Hypertension, Thyroid disorder, Heart disease, Stroke, Asthma, COPD, Cancer
Diabetes mellitus : Since - 6 yrs; Medication - regular

Asymedic medicines

DRUG ALLERGY

NO KNOWN ALLERGY

:22/10/2022

SYSTEMIC REVIEW

Cardiovascular system

- Nil Significant

Past medical history

Do you have any allergies? - No

Do you have any drug allergies? - No

Past medical history - nil significant

Covid 19 - No

Surgical history

Surgical history - Nil

Immunization history

- Covid Dose1, Covid Dose2

Personal history

Marital status - Married

No. of children - 02
Diet - Vegetarian
Alcohol - does not consume alcohol
Smoking - No
Chews tobacco - No
Physical activity - Active
- home exercise

Family history

Hypertension - mother, brother
Coronary artery disease - none
Cancer - None

PHYSICAL EXAMINATION

General

General appearance - normal
Build - normal
Height - 153
Weight - 72
BMI - 30.76
Pallor - No
Oedema - no
Temperature - 96.2
SpO2 - 98



H Swaminarayan Nagar, Off Mumbai-Agra Highway,
Panchvati, Nashik - 422 003.

+91- 253 - 2510250 / 350 / 450 / 550 / 750

apollonashik@apollohospitals.com

www.askapollo.com

QFAHN/BILL/003/V1



Name : Mrs. MANJUSHA VIVEK MULAY (59 /F)

UHID : MHN1.0000127303

Date : 22/10/2022

Package : MediWheel Full Body Health Checkup Female Above 40 Package

AHC No : NSKAH28055

Cardiovascular system


Heart rate (Per minute) - 56
Rhythm - Regular
- B.P. Supine
Systolic(mm of Hg) - 120
Diastolic(mm of Hg) - 70
Heart sounds - S1S2+

Respiratory system

Breath sounds - Normal vesicular breath sounds

Abdomen

Organomegaly - No
Tenderness - No





H Swaminarayan Nagar, Off Mumbai-Agra Highway,
Panchvati, Nashik - 422 003.
+91- 253 - 2510250 / 350 / 450 / 550 / 750
apollonashik@apollohospitals.com
www.askapollo.com

QFAHN/BILL/003/V1



Name : Mrs. MANJUSHA VIVEK MULAY (59 /F) UHID : MHN1.0000127303 Date : 22/10/2022
Package : MediWheel Full Body Health Checkup Female Above 40 Package AHC No : NSKAH28055

URINE ROUTINE (CUE)

Test Name	Result	Unit	Level	Range
Specific Gravity	1.025		●	1.016-1.026
Color,:	PALE YELLOW			
Transparency:	Clear			
Reaction:	Acidic			7.2-7.8
Protein :	Negative			
Sugar:	Trace			
Blood:	5.5		●	4.6-8
Ketone	Negative			
Bile Pigments:	Negative			
Bile Salts :	Negative			
Urobilinogen	Normal			
Nitrite	Negative			
RBC	00	/hpf	●	0-2
WBC/Pus Cells	0-2/hpf	/hpf	●	0-2
Tc/Sqc(Transitional/Squamous epithelial cells)	3-4/hpf	/hpf	●	

Test Name	Result	Unit	Level	Range
Neutrophils	55	%	●	40-75
Lymphocytes	40	%	●	20-45
Eosinophils	02	%	●	1-6
Monocytes	03	%	●	1-10
Basophils	00	%	●	0-1
ERYTHROCYTE SEDIMENTATION RATE (ESR)	17	mm/1st hr	●	0-20

BLOOD GROUPING AND TYPING (ABO and Rh)

Test Name	Result	Unit	Level	Range
ABO Group:	B			
Rh (D) Type:	POSITIVE			

LIVER FUNCTION TEST (PACKAGE)

Test Name	Result	Unit	Level	Range
ALT(SGPT) - SERUM / PLASMA	35	U/L	●	30-65
ALBUMIN - SERUM	4.4	g/dL	●	3.5-5
GLOBULIN - SERUM: (Calculated)	3.9 *	g/dL	●	1.8-3.6
ALBUMIN:GLOBULIN - SERUM(RATIO) (Calculated)	0.5 *		●	1.1-1.8
ALKALINE PHOSPHATASE - SERUM/PLASMA	96	U/L	●	0-100
AST (SGOT) - SERUM	30	U/L	●	15-37
BILIRUBIN, TOTAL - SERUM	0.6	mg/dL	●	0.0-1.0

C B C WITH ESR (AUTOMATION + STANDARD METHOD)

Test Name	Result	Unit	Level	Range
Hemoglobin	13.9	g/dl	●	11.0-16.0
Haematocrit	42.5	%	●	34.0-48.0
RBC COUNT	5.20	Million/ul	●	3.7-5.6
MCV	81.7	fl	●	75.0-95.0
MCH	26.7	pg	●	26.0-32.0
MCHC	32.7	g/dl	●	31.0-36.0
RDW	14.7	%	●	11-16
Platelet Count(Optical/Impedance)	233	10 ³ /m ³	●	140-440
TLC Count	6.00	10 ³ /m ³	●	4.0-11.0

LIPID PROFILE TEST (PACKAGE)

Test Name	Result	Unit	Level	Range
Total Cholesterol	197	mg/dL	●	0-200

CREATININE - SERUM / PLASMA

Test Name	Result	Unit	Level	Range
-----------	--------	------	-------	-------

● Within Normal Range ● Borderline High/Low ● Out of Range



Swaminarayan Nagar, Off Mumbai-Agra Highway,
Panchvati, Nashik - 422 003.

+91- 253 - 2510250 / 350 / 450 / 550 / 750

apollonashik@apollohospitals.com

www.askapollo.com

QFAHN/BILL/003/V1



Name : Mrs. MANJUSHA VIVEK MULAY (59 /F)

UHID : MHN1.0000127303

Date : 22/10/2022

Package : MediWheel Full Body Health Checkup Female Above 40 Package

AHC No : NSKAH28055

CREATININE - SERUM 0.6 mg/dL 0.6-1.0
/ PLASMA

LDL Cholesterol (Direct 145 mg/dL
LDL)

LIVER FUNCTION TEST (PACKAGE)

Test Name	Result	Unit	Level	Range
GGTP: GAMMA GLUTAMYL TRANSPEPTIDASE - SERUM	39	U/L	●	0-50

LIVER FUNCTION TEST (PACKAGE)

Test Name	Result	Unit	Level	Range
PROTEIN, TOTAL - SERUM / PLASMA	8.3 *	g/dL	●	6.4-8.2
PROTEIN, TOTAL - SERUM / PLASMA	8.3 *	g/dL	●	6.4-8.2

GLUCOSE - SERUM / PLASMA (FASTING)

Test Name	Result	Unit	Level	Range
Glucose - Plasma (Fasting)	264 *	mg/dL	●	70-100
URINE GLUCOSE(FASTING): (Strip Method)	Trace			

THYROID PROFILE - I(T3,T4 AND TSH)

Test Name	Result	Unit	Level	Range
TOTAL T3: TRI IODOTHYRONINE - SERUM	171	ng/dL	●	Healthy Adults: 69 - 215
TOTAL T4: THYROXINE - SERUM	11.1	µg/dL	●	Healthy Adults:5.2 - 12.7

GLUCOSE - SERUM / PLASMA (POST PRANDIAL)

Test Name	Result	Unit	Level	Range
Glucose - Plasma (POST PRANDIAL)	403 *	mg/dL	●	70-140
URINE GLUCOSE(POST PRANDIAL):(Strip Method)	4+			

LIPID PROFILE TEST (PACKAGE)

Test Name	Result	Unit	Level	Range
Triglycerides - Serum	140	mg/dL	●	0-150

THYROID PROFILE - I(T3,T4 AND TSH)

Test Name	Result	Unit	Level	Range
TSH: THYROID STIMULATING HORMONE - SERUM	3.4	uIU/mL	●	Healthy Adults: 0.3 - 4.5

GLYCOSYLATED HEMOGLOBIN (HbA1C) - WHOLE BLOOD

Test Name	Result	Unit	Level	Range
Glycosylated Hemoglobin (HbA1c)	9.5	%	●	0.0-6.0
Mean Plasma Glucose (MPG) Estimate:	260.90	mg/dL		

UREA - SERUM / PLASMA

Test Name	Result	Unit	Level	Range
UREA - SERUM / PLASMA	15	mg/dL	●	15-38
UREA NITROGEN SERUM/PLASMA: (Calculated)	7	mg/dL	●	7-18

LIPID PROFILE TEST (PACKAGE)

Test Name	Result	Unit	Level	Range
HDL CHOLESTEROL - SERUM / PLASMA	47	mg/dL	●	40-60
TOTAL CHOLESTEROL/HDL CHOLESTEROL RATIO(Calculated)	4.2		●	0.0-4.5

URIC ACID - SERUM

Test Name	Result	Unit	Level	Range
URIC ACID - SERUM	3.5	mg/dL	●	2.6-6.0

LIVER FUNCTION TEST (PACKAGE)

● Within Normal Range ● Borderline High/Low ● Out of Range



Swaminarayan Nagar, Off Mumbai-Agra Highway,
Panchvati, Nashik - 422 003.

+91- 253 - 2510250 / 350 / 450 / 550 / 750

apollonashik@apollohospitals.com

www.askapollo.com

QFAHN/BILL/003/V1



Name : Mrs. MANJUSHA VIVEK MULAY (59 /F)

UHID : MHN1.0000127303

Date : 22/10/2022

Package : MediWheel Full Body Health Checkup Female Above 40 Package

AHC No : NSKAH28055

Test Name	Result	Unit	Level	Range
BILIRUBIN CONJUGATED (DIRECT) - SERUM	0.2	mg/dL	●	0.0-0.3
BILIRUBIN UNCONJUGATED - SERUM(Calculated)	0.4	mg/dL	●	0.0-0.7

CARDIAC STRESS TEST - (TMT)

ECG

MAMMOGRAPHY

- 1) No significant abnormality is seen on this study.
- 2) BI - RADS - Category 1.

Suggest : Clinical correlation.

ULTRASOUND - WHOLE ABDOMEN

Grade I fatty infiltration of liver.

No other significant abnormality is detected.

Suggest : Clinical correlation.

X-RAY CHEST PA

No significant abnormality noted.


INVESTIGATIONS NOT DONE / NOT YET REPORTED / NOT
PART OF PACKAGE(LAB,RADIOLOGY & CARDIOLOGY)

Haematology

STOOL ROUTINE

Histopathology

CERVICAL/VAGINAL SMEAR II SLIDE



● Within Normal Range ● Borderline High/Low ● Out of Range



H Swaminarayan Nagar, Off Mumbai-Agra Highway,
Panchvati, Nashik - 422 003.

+91- 253 - 2510250 / 350 / 450 / 550 / 750

apollonashik@apollohospitals.com

www.askapollo.com

QFAHN/BILL/003/V1



Name : Mrs. MANJUSHA VIVEK MULAY (59 /F)

UHID : MHN1.0000127303

Date : 22/10/2022


Package : MediWheel Full Body Health Checkup Female Above 40 Package

AHC No : NSKAH28055

Printed By :

AHC Physician / Consultant Internal Medicine

Need strict sugar control.



[Handwritten signature]

Note :- The Health Check-up examinations and routine investigations have certain limitations and may not be able to detect all the diseases. Any new or persisting symptoms should be brought to the attention of the Consulting Physician. Additional tests, consultations and follow up may be required in some cases.



H Swaminarayan Nagar, Off Mumbai-Agra Highway,
Panchvati, Nashik - 422 003.

+91- 253 - 2510250 / 350 / 450 / 550 / 750

apollonashik@apollohospitals.com

www.askapollo.com

QFAHN/BILL/003/V1



Name : Mrs. MANJUSHA VIVEK MULAY (59 /F)

UHID : MHN1.0000127303

Date : 22/10/2022

Package : MediWheel Full Body Health Checkup Female Above 40 Package

AHC No : NSKAH28055

AICVD RISK SCORE REPORT

RISK STATUS

Low Risk

YOUR SCORE

6

ACCEPTABLE SCORE

7

Your cardiovascular disease risk in the next 10 years is within the Normal limits for your age and gender

The AICVD risk score developed by Apollo Hospitals is a novel artificial intelligence-based risk scoring system that predicts your risk of having Coronary Artery Disease (CAD) related events in the next ten years. This scoring system uses Indian data and has been validated by multiple national and international institutions. This risk score is more than 92% accurate and has been compiled based on your physical parameters, heart health attributes, lifestyle and medical history. **Note:** The risk category is determined through the ratio between guest score and acceptable score at multiple decimal points. The outputs are shown in whole numbers.

Based on your AICVD risk score you are advised the following:

- Follow the guidance and education on lifestyle and dietary management provided through the ProHealth program. Maintain a healthy BMI (<25). Avoid tobacco in any form and if you are a smoker, stop smoking.
- Continue with medications for high blood pressure, diabetes, or dyslipidemia, if advised by your physician. Maintain HbA1c <7% (<53mmol/mol), blood pressure <140/90mmHg.
- Follow your physician's advice regarding follow up tests, consults and annual health assessment

DISCLAIMER

- This is not a diagnostic tool and it does not guarantee accuracy of the result and cannot be acted upon independently.
- This risk score and clinical algorithm is a general guideline for physicians. Any additional laboratory investigations, diagnostic imaging, treatment or patient education related to lifestyle management is under the physician's or cardiologist's discretion.
- To ensure the information in the report is up to date, accurate and correct, doctor shall be consulted for interpretation of the report.
- Apollo Hospitals and its staff does not offer any assurance on the information made available or be liable for any loss or damage as the said report is based on the AICVD risk score without any intervention from their side.
- By usage of the AICVD risk score, it is deemed that the beneficiary of this service has agreed to get the same done at his own risk and further agrees with this disclaimer without any limitation or any clauses or sub-clauses.

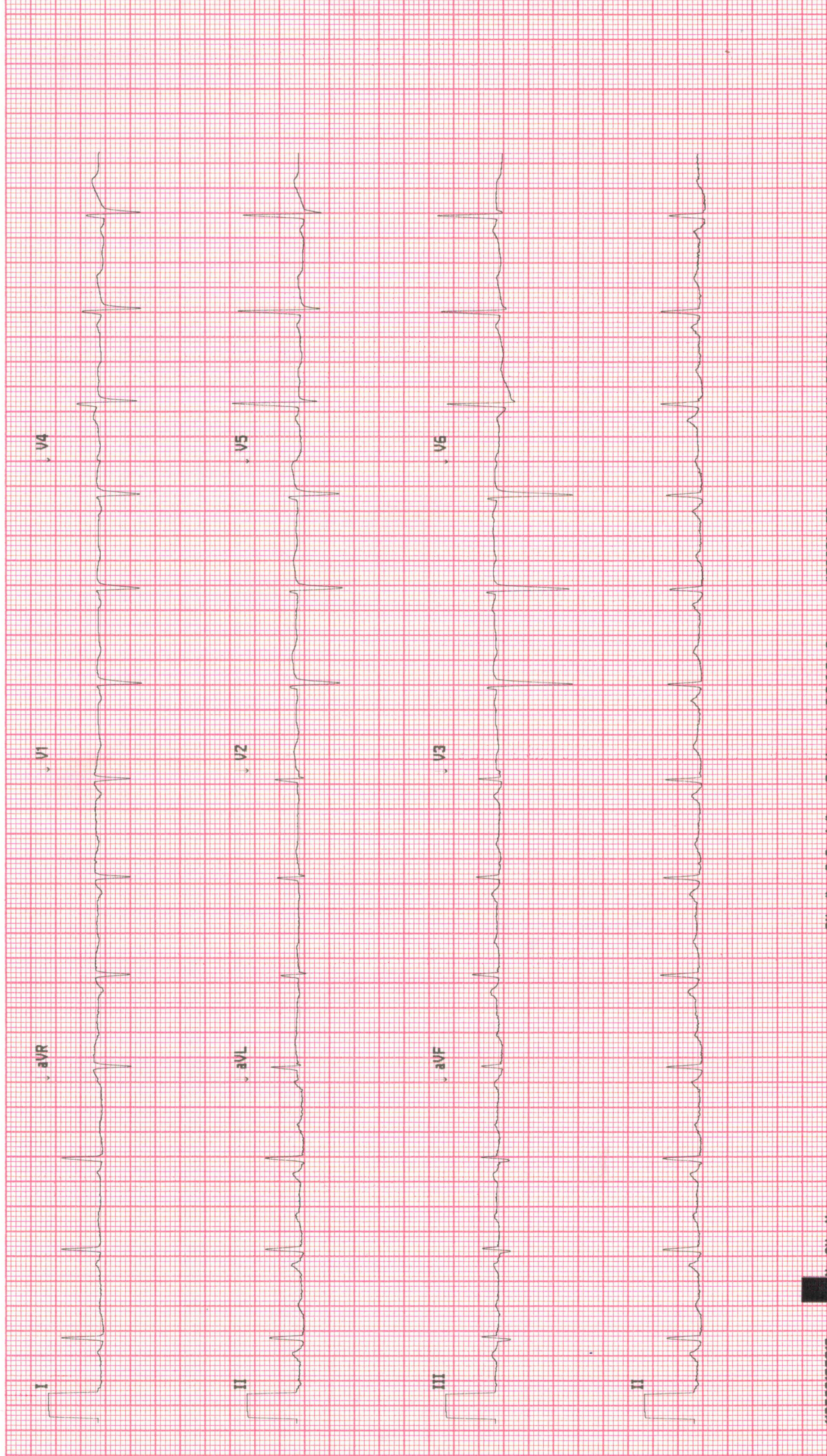
The Clinical AI Models and APIs used at Apollo Hospitals are certified by ISO 13485 : 2016 vide certificate no. MD 763515

Muley, Manjusha
ID:
DOB:
59yr, Female

22-Oct-2022 12:02:54

Vent rate: 99 BPM
PR int: 159 ms
QRS dur: 93 ms
QT/QTc: 374/408 ms
P-R-T axes: 64 32 68

SINUS RHYTHM
NONSPECIFIC T-WAVE ABNORMALITY
BORDERLINE ECG
UNCONFIRMED REPORT





H Swaminarayan Nagar, Off Mumbai-Agra Highway,
Panchvati, Nashik - 422 003.

+91- 253 - 2510250 / 350 / 450 / 550 / 750

apollonashik@apollohospitals.com

www.askapollo.com

QFAHN/BILL/003/V1



Screening Echocardiography Report

Name: - Mrs. MANJUSHA VIVEK MULAY

UHID No: - MHN1. 0000127303

Referred by: -Dr. Nirmal Kolte.

Echo window: - Good

Age/Sex: 59/F

DATE: 22/10/2022

Echo No: -30920

Normal all rest of valves and chambers.

Normal LV systolic function. No RWMA at rest.

Normal RV systolic function.

AO/LA= 30 mm/ 35 mm, LVIDd/LVIDs= 43 mm/ 27 mm, IVS/PW= 11 mm/ 11 mm.

No PAH.

No Clot/ Vegetation/Pericardial effusion.

No Coarctation.

Normal Echo Study.

Impression: -

Normal all rest of valves and chambers.


Normal LV systolic function. No RWMA at rest.

Normal RV systolic function.

No PAH.

No clot/ vegetation/pericardial effusion.

No Coarctation.


DR. Nirmal Kolte.



H Swaminarayan Nagar, Off Mumbai-Agra Highway,
Panchvati, Nashik - 422 003.

+91- 253 - 2510250 / 350 / 450 / 550 / 750

apollonashik@apollohospitals.com

www.askapollo.com

QFAHN/BILL/003/V1



Radiology

Patient Details : Mrs. MANJUSHA VIVEK MULAY | Female | 59Yr 1Mth 27Days

UHID : MHN1.0000127303

Patient Location: AHC

Patient Identifier: NSKAH28055



DRN : 1322002901

Completed on : 22-OCT-2022 14:39

Ref Doctor : Dr. Rajashri Dhongade

MAMMOGRAPHY

Bilateral mammograms have been obtained using a low radiation dose film screen technique in the craniocaudal and oblique projections. Film markers are in the axillary/lateral portions of the breasts.

The study reveals :

Both breasts reveal mixed fatty and fibroglandular parenchyma.

There is no obvious evidence of a focal spiculated mass lesion, architectural distortion, focal asymmetry or clusters of microcalcifications seen to suggest presence of a malignancy.

Nipple and subcutaneous tissues are normal.

Impression

- 1) No significant abnormality is seen on this study.
- 2) BI - RADS - Category 1.

Suggest : Clinical correlation.

---- END OF THE REPORT ----

Dr. Harshal S Dhongade

Consultant - Radiology



H Swaminarayan Nagar, Off Mumbai-Agra Highway,
Panchvati, Nashik - 422 003.
+91- 253 - 2510250 / 350 / 450 / 550 / 750
apollonashik@apollohospitals.com
www.askapollo.com

QFAHN/BILL/003/V1



Radiology

Patient Details : Mrs. MANJUSHA VIVEK MULAY | Female | 59Yr 1Mth 27Days

UHID : MHN1.0000127303

Patient Location: AHC

Patient Identifier: NSKAH28055



DRN : 222025288

Completed on : 22-OCT-2022 11:44

Ref Doctor : Dr. Rajashri Dhongade

ULTRASOUND - WHOLE ABDOMEN

LIVER : Normal in size and measures 14.4cm. Diffuse increase in echogenicity of the liver parenchyma is suggestive of fatty infiltration.
No I.H.B.D./ focal lesions.

PORTAL VEIN: Normal in size.

GALL BLADDER: Well distended with normal walls and lumen.
No calculi/pericholecystic fluid.

COMMON BILE DUCT: Normal in size.

PANCREAS : Visualized portion of head and body of pancreas appears normal in size and echotexture. Rest of the pancreas is obscured due to bowel gases.

SPLEEN : Normal in size (11.3 cm) and echotexture.

KIDNEYS: Both kidneys are normal in site, size and echotexture.
No evidence of calculi/ hydronephrosis.
Right kidney measures: 12.2 x 5.5 cm.
Left kidney measures : 13 x 5.0 cm.

URINARY BLADDER: Well distended with normal walls.
No evidence of calculi/ growth/ diverticula .

Uterus and both ovaries are atrophic
Endometrium is thin and midline (post menopausal status).
A subcentimeter sized focus of calcification is noted in posterior myometrium on left side.



H Swaminarayan Nagar, Off Mumbai-Agra Highway,
Panchvati, Nashik - 422 003.

+91- 253 - 2510250 / 350 / 450 / 550 / 750

apollonashik@apollohospitals.com

www.askapollo.com

QFAHN/BILL/003/V1



Mrs. MANJUSHA VIVEK MULAY

MHN1.0000127303

NSKAH28055

ULTRASOUND - WHOLE ABDOMEN

Visualized bowel loops appear grossly normal.

No evidence of any free fluid in the peritoneal cavity.

Impression

Grade I fatty infiltration of liver.

No other significant abnormality is detected.

Suggest : Clinical correlation.

END OF THE REPORT

Dr. Samruddhi Sonawane

Dr. Samruddhi Sonawane

Consultant - Radiology





H Swaminarayan Nagar, Off Mumbai-Agra Highway,
Panchvati, Nashik - 422 003.

+91- 253 - 2510250 / 350 / 450 / 550 / 750

apollonashik@apollohospitals.com

www.askapollo.com

QFAHN/BILL/003/V1



MD (Radiology)

Patient Details : Mrs. MANJUSHA VIVEK MULAY | Female | 59Yr 1Mth 27Days

UHID : MHN1.0000127303 **Patient Location:** AHC

Patient Identifier: NSKAH28055



DRN : 122041316 **Completed on** : 22-OCT-2022 12:42

Ref Doctor : Dr. Rajashri Dhongade

X-RAY CHEST PA

Both lung fields are clear.

Both hila are normal in size and position.

Costophrenic and cardiophrenic angles are clear.

Cardiac size and contour are within normal limits.

Rib cage is normal.

Soft tissues are normal.

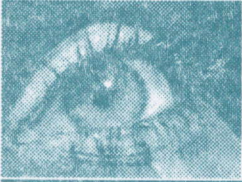Impression

No significant abnormality noted.

---- END OF THE REPORT ----

Kunal Kalyanrao Patil

Consultant - MD (Radiodiagnosis)



OPHTHALMOLOGY



Name : Mrs. Maryasha Malay Date 22/10/22 UNIT _____
 Occupation : _____ Room No. _____ Out Patient
 Age : 59 Sex : Male Female S/M/W/D Ref. Physician : _____
 Address : Nile Copies to : _____
 Tel. No. _____

REPORT ON OPHTHALMIC EXAMINATION

HISTORY : _____

PRESENT COMPLAINT : _____

PAST HISTORY : DM HTN / ALLERGY

ON EXAMINATION Subjude Pop RE 6/60 LE 6/60

VISION :

	RIGHT					LEFT				
	PGP	SPH	CYL	AXIS	VA	SPH	CYL	AXIS	VA	
DIST										
NEAR										

Handwritten notes: Vn 6/60, Ph 9/60

AR / Retinoscopy :


	RIGHT			LEFT		
	SPH	CYL	AXIS	SPH	CYL	AXIS
	<u>4.5</u>	<u>1.5</u>	<u>1°</u>	<u>2.25</u>	<u>2.00</u>	<u>125</u>

Refraction or Acceptance :

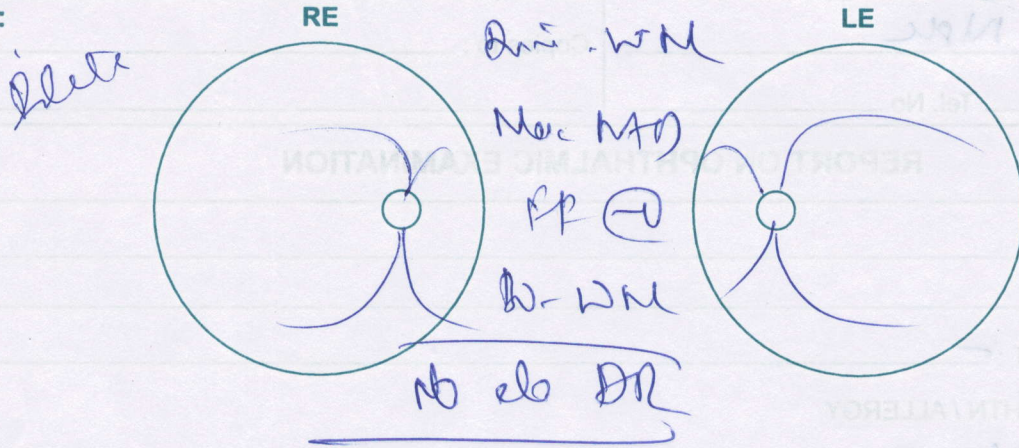
	RIGHT					LEFT				
	SPH	CYL	AXIS	VA	SPH	CYL	AXIS	VA		
DIST	<u>4.5</u>	<u>1.5</u>	<u>180°</u>	<u>6/60</u>	<u>2.5</u>	<u>2.00</u>	<u>180°</u>	<u>6/6</u>		
NEAR	<u>2.25</u>			<u>M</u>	<u>2.25</u>			<u>M</u>		

Handwritten notes: Add, can to

Anterior Segment :



Fundus :



Diagnosis : (B) Myopia = Astigmatism = Presbyopia

Advise / Rx:

- STREET DM CONTROL
- FU Myopia

LEFT				RIGHT			
VA	CYL	SPH	AXIS	VA	CYL	SPH	AXIS
20/20	0.00	-1.00	180	20/20	0.00	-1.00	180
M				M			

CONSULTANT OPHTHALMOLOGIST



H Swaminarayan Nagar, Off Mumbai-Agra Highway,
Panchvati, Nashik - 422 003.

+91- 253 - 2510250 / 350 / 450 / 550 / 750

apollonashik@apollohospitals.com

www.askapollo.com

QFAHN/BILL/003/V1



22/10/22

Mrs. Manjusha Mulay

IP.

- H/o of DM

- No H/o of HTN.

- Supra & subgingival plaque present.

- Generalised marginal gingivitis & localised periodontitis

Adv 1- Scaling Reg

Gunex