



Shubham Imaging & ALC Diagnostic Center

ISO 9001:2015 Certified Center

(A Unit of P. K. Arogyam Health & Wellness Center)

E-95, P.C. Colony, Near Sai Netryalaya Transformer, Kankarbagh, Patna - 20

✉ : alcdiagnostics@gmail.com

🌐 : www.pkarogyamhealthcheckup.com

☎ : 7050037694, 9153988577

OPINION MUST BE CORRELATES WITH CLINICALLY & OTHER INVESTIGATION FOR FINAL DIAGNOSIS. NOT FOR MEDICO LEGAL PURPOSE

PATIENT NAME : Mrs. VEENA KUMARI PATIENT ID : 1445
COL DATE : 23/10/2024 REPORTING DATE: 23/10/2024 AGE SEX : 37 YRS/F
REF.BY : DR. / MEDIWHEEL

TEST NAME	RESULT	Unit	REF.RANGE
BLOOD SUGAR (F)	93.0 mg/dl		70 - 110 mg/dl
LIPID PROFILE:-			
TOTAL CHOLESTROL	179.0 mg/dl		130 -250 mg/dl
TRIGLYCERIDE	237.5 mg/dl		50 -160 mg/dl
HDL CHOLESTROL	43.0 mg/dl		30 - 60 mg/dl
LDL CHOLESTROL	82.1 mg/dl		80 -130 mg/dl
VLDL CHOLESTROL	47.5 mg/dl		15 - 40 mg/dl
T.CH./HDL RATIO	4.1 :1		Upto 5 :1
LDL /HDL RATIO	2.0 : 1		2 - 4:1

ESTB BY:-


Dr. P. K. Tiwari
MD, M.Sc (Radio Imaging)
Ph.D (AI Nuclear Medicine)
Consultant Imagingologist

Dr. S. Kumar
MD, (Pat)
Consultant Pathologist

Dr. Abhishek Kumar
MBBS, MD
Consultant Neuropathology Physiologist

Dr. Kumari Suman
MBBS, DGO, MD
Consultant (TVS & HSG Specialist)

Dr. A. K. Singh
MBBS, FGD/MCH
Consultant Radiologist & Sonologist


23/10/24
Consultant Radiologist

PRINTING MISTAKE SHOULD BE REPORTED BACK IMMEDIATELY / यहाँ जन्म से पहले धुण का लिंग जाँच नहीं होता है।



Shubham Imaging & ALC Diagnostic Center

ISO 9001:2015 Certified Center

(A Unit of P. K. Arogyam Health & Wellness Center)

E-95, P.C. Colony, Near Sai Netryalaya Transformer, Kankarbagh, Patna - 20

✉ : alcdiagnostics@gmail.com

🌐 : www.pkarogyamhealthcheckup.com

☎ : 7050037694, 9153988577

OPINION MUST BE CORRELATES WITH CLINICALLY & OTHER INVESTIGATION FOR FINAL DIAGNOSIS. NOT FOR MEDICO LEGAL PURPOSE

PATIENT NAME : Mrs. VEENA KUMARI

PATIENT ID :1445

COL DATE : 23/10/2024 REPORTING DATE: 23/10/2024 AGE SEX:- 37 YRS/F

REF.BY : DR. / MEDIWHEEL .

TEST NAME	RESULT	Unit	REF.RANGE
LFT:-			
SGPT	19.0	IU/L	5 - 40 IU/L
SGOT	17.4	IU/L	5 - 40 IU/L
ALKALINE PHOSPHATASE	86.2	IU/L	M - 53 - 165 IU/L F - 42 - 136 IU/L
TOTAL PROTIN	7.3	g/dl	6.0 - 8.7 g/dl
SERUM ALBUMIN	4.4	g/dl	3.5 - 5.4 g/dl
SERIUM GLUBLINE	2.9	g/dl	2.3 - 3.6 g/dl
AG RATIO	1.5: 1		1.0 - 2.3 g/dl
BILIRUBIN			
TOTAL	0.51	mg/dl	0.1 - 1.1 mg/dl
DIRECT	0.22	mg/dl	0.0 - 0.32 mg/dl
INDIRECT	0.29	mg/dl	0.0 - 0.78 mg/dl
GGTP(GGT)	16.0	iu/L	8 - 38 iu/L
KFT/RFT			
URIC ACID	3.6	mg/dl	3.2 - 7.0 mg/dl
SERUM CREATNINE	0.8	mg/dl	0.6 - 1.5 mg/dl
BLOOD URIA	26.2	mg/dl	5 - 45 mg/dl
BLOOD URIA NITROZEN(BUN).	12.2	mg/dl	5 - 23 mg/dl

ESTB BY:-


Consultant Radiologist

Dr. P. K. Tiwari
MD, M Sc (Radio Imaging)
Ph D (AI Nuclear Medicine)
Consultant Imagianologist

Dr. S. Kumar
MD, (Pat)
Consultant Pathologist

Dr. Abhishek Kumar
MBBS, MD
Consultant Neuropatha Physiologist

Dr. Kumari Suman
MBBS, DGO, MD
Consultant (TVS & HSG Specialist)

Dr. A. K. Singh
MBBS, PGDMCH
Consultant Radiologist & Sonologist

PRINTING MISTAKE SHOULD BE REPORTED BACK IMMEDIATELY / यहाँ जन्म से पहले धुण का लिंग जाँच नहीं होता है।



Shubham Imaging & ALC Diagnostic Center

ISO 9001:2015 Certified Center

(A Unit of P. K. Arogyam Health & Wellness Center)

E-95, P.C. Colony, Near Sai Netryalaya Transformer, Kankarbagh, Patna - 20

✉ : alcdiagnostics@gmail.com

🌐 : www.pkarogayamhealthcheckup.com

☎ : 7050037694, 9153988577

OPINION MUST BE CORRELATES WITH CLINICALLY & OTHER INVESTIGATION FOR FINAL DIAGNOSIS. NOT FOR MEDICO LEGAL PURPOSE

PATIENT NAME : Mrs. VEENA KUMARI

PATIENT ID: 1445

COL DATE : 23/10/2024 REPORTING DATE: 23/10/2024 AGE SEX :- 37 YRS/F

REF.BY : DR. / MEDIWHEEL .

TEST NAME	RESULT	Unit	REF.RANGE
ESR	16 mm/hr		<20 mm/hr
CBC			
Total W.B.C. Count	8,400 /cumm		4,000 - 11,000 /cumm
R B C COUNT	4.10 Million/ CUmm		4 - 7 Million/ CUmm
Platelets count	1.90 Lakh/ cumm		1.5 - 5.0 Lakh/ cumm
Differential Count of W.B.C.			
Neutrophils	58 %		40 - 70%
Lymphocytes	37 %		25 - 40%
Eosinophils	04 %		01 - 05%
Mnonocytes	01 %		00 - 02%
Basophiles	00 %		00 - 0 %
HAEMOGLOBIN	13.4 gm/dl (91.7 %)		14.6 gm/dl = 100%
PCV	37.5 %		35 - 47 %
MCV	90.6 fl		76 - 96 fl
MCH	32.4 pg		29 - 35 pg
MCHC	35.7 %		30 - 38 %

ESTB BY:-

23/10/24
Consultant Radiologist

Dr. P. K. Tiwari
MD, M.Sc (Radio Imaging)
Ph.D (AI Nuclear Medicine)
Consultant Imagiologist

Dr. S. Kumar
MD, (Pa)
Consultant Pathologist

Dr. Abhishek Kumar
MBBS, MD
Consultant Neuropathologist

Dr. Kumari Suman
MBBS, DGO, MD
Consultant (TVS & HSG Specialist)

Dr. A. K. Singh
MBBS, PGDMCH
Consultant Radiologist & Sonologist

PRINTING MISTAKE SHOULD BE REPORTED BACK IMMEDIATELY / यहाँ जन्म से पहले धुण का लिंग जाँच नहीं होता है।



Shubham Imaging & ALC Diagnostic Center

ISO 9001:2015 Certified Center

(A Unit of P. K. Arogyam Health & Wellness Center)

E-95, P.C. Colony, Near Sai Netryalaya Transformer, Kankarbagh, Patna - 20

✉ : alcdiagnostics@gmail.com

🌐 : www.pkarogyamhealthcheckup.com

☎ : 7050037694, 9153988577

OPINION MUST BE CORRELATES WITH CLINICALLY & OTHER INVESTIGATION FOR FINAL DIAGNOSIS. NOT FOR MEDICO LEGAL PURPOSE

PATIENT NAME : Mrs. VEENA KUMARI

PATIENT ID : 1445


COL DATE : 23/10/2024 REPORTING DATE: 23/10/2024 AGE SEX : 37 YRS/F

REF.BY : DR./ MEDIWHEEL.

GLYCOSYLATED HEMOGLOBIN

TEST NAME	RESULT	Unit	REF.RANGE
HbA1c	3.7 %		Below 5.7 % : Normal 5.7 – 6.4 % : Prediabetic > = 6.5 % : Diabetic
AVERAGE PLASMA GLUCOSE	96.0 mg/dl		90 – 120 mg/dl : Good Control 121– 150 mg/dl : Fair Control 151- 180 mg/dl: Unsatisfactory Control >180 mg/dl : Poor Control

ESTB BY:-


Consultant Radiologist

Dr. P. K. Tiwari
MD, M.Sc (Radio Imaging)
Ph. D (AI) Nuclear Medicine
Consultant Imagingologist

Dr. S. Kumar
MD (Pat)
Consultant Pathologist

Dr. Abhishek Kumar
MBBS, MD
Consultant Neuropatho Physiologist

Dr. Kumari Suman
MBBS, DGO, MD
Consultant (TVS & HSG Specialist)

Dr. A. K. Singh
MBBS, PGDMCH
Consultant Radiologist & Sonologist

PRINTING MISTAKE SHOULD BE REPORTED BACK IMMEDIATELY / यहां जन्म से पहले भ्रूण का लिंग जांच नहीं होता है।



Shubham Imaging & ALC Diagnostic Center

ISO 9001:2015 Certified Center

(A Unit of P. K. Arogyam Health & Wellness Center)

E-95, P.C. Colony, Near Sai Netryalaya Transformer, Kankarbagh, Patna - 20

✉ : alcdiagnostics@gmail.com

🌐 : www.pkarogayamhealthcheckup.com

☎ : 7050037694, 9153988577

OPINION MUST BE CORRELATES WITH CLINICALLY & OTHER INVESTIGATION FOR FINAL DIAGNOSIS. NOT FOR MEDICO LEGAL PURPOSE

PATIENT NAME : Mrs. VEENA KUMARI PATIENT ID : 1445

COL DATE : 23/10/2024 REPORTING DATE: 23/10/2024 AGE SEX : 37 YRS/F

REF.BY : DR. / MEDIWHEEL.


TEST NAME	RESULT	Unit	REF.RANGE
-----------	--------	------	-----------

BLOOD GROUP : ' B '

Rh Typing : POSITIVE

Note: Do always cross – matching before blood transfusion

ESTB BY:-


23/10/24
Consultant Radiologist

Dr. P. K. Tiwari
MD, M. Sc (Radio Imaging)
Ph D (AI) Nuclear Medicine
Consultant Imaginologist

Dr. S. Kumar
MD, (Pat)
Consultant Pathologist

Dr. Abhishek Kumar
MBBS, MD
Consultant Neuropatho Physiologist

Dr. Kumari Suman
MBBS, DGO, MD
Consultant (TVS & HSG Specialist)

Dr. A. K. Singh
MBBS, PGDMCH
Consultant Radiologist & Sonologist

PRINTING MISTAKE SHOULD BE REPORTED BACK IMMEDIATELY / यहाँ जन्म से पहले भ्रुण का लिंग जाँच नहीं होता है।



Shubham Imaging & ALC Diagnostic Center

ISO 9001:2015 Certified Center

(A Unit of P. K. Arogyam Health & Wellness Center)

E-95, P.C. Colony, Near Sai Netryalaya Transformer, Kankarbagh, Patna - 20

✉ : alcdiagnostics@gmail.com

🌐 : www.pkarogayamhealthcheckup.com

☎ : 7050037694, 9153988577

OPINION MUST BE CORRELATES WITH CLINICALLY & OTHER INVESTIGATION FOR FINAL DIAGNOSIS. NOT FOR MEDICO LEGAL PURPOSE

PATIENT NAME : Mrs. VEENA KUMARI

PATIENT ID : 1445

COL DATE : 23/10/2024 REPORTING DATE: 23/10/2024 AGE SEX : 37 YRS/F

REF.BY : DR. / MEDIWHEEL.

Investigation	Result	Normal Range
Total Triiodothyronin T3	1.20 ng/mL	0.80 - 2.00 μ ng/mL
Total Thyroxin T4	8.14 ug/mL	5.10 - 14.10 ug/dL
Serum TSH	5.71 μ g/mL	0.27 - 4.20 μ g/mL

THYROID DISORDER (>: Increase: < Decrease: n Normal

1. T3(n) T4(n) TSH(n) :EUTHYROID STATE:
2. T3(>) T4(>) TSH(<): HYPERTHYROIDISM:
3. T3(<)T4(<) TSH(>): HYPOTHYROIDISM:
4. T3(n)T4(n) TSH(>) : SUB-CLINICAL HYPO-THYROIDISM:
5. T3(n)T4(n) TSH(<): SUB-CLINICAL HYPER-THYROIDISM:
6. T3(>) T4(n) TSH(<): T3 THYROTOXICOSIS:

Total T3/T4 level is dependent on Level:

So determination of free T3/T4is a better MARKER of Thyroid Function.

*FREE T3/T4 ESTIMATION FACILITY IS AVAILABALE ON REQUEST.:

ESTB BY:-

Consultant Radiologist

Dr. P. K. Tiwari
MD, M Sc (Radio Imaging)
Ph D (AI) Nuclear Medicine)
Consultant Imagionologist

Dr. S. Kumar
MD, (Pat)
Consultant Pathologist

Dr. Abhishek Kumar
MBBS, MD
Consultant Neuropatho Physiologist

Dr. Kumari Suman
MBBS, DGO, MD
Consultant (TVS & HSG Specialist)

Dr. A. K. Singh
MBBS, FGDmch
Consultant Radiologist & Sonologist

PRINTING MISTAKE SHOULD BE REPORTED BACK IMMEDIATELY / यहाँ जन्म से पहले भ्रुण का लिंग जाँच नहीं होता है।



Shubham Imaging & ALC Diagnostic Center

ISO 9001:2015 Certified Center

(A Unit of P. K. Arogyam Health & Wellness Center)

E-95, P.C. Colony, Near Sai Netryalaya Transformer, Kankarbagh, Patna - 20

✉ : alcdiagnostics@gmail.com

🌐 : www.pkarogayamhealthcheckup.com

☎ : 7050037694, 9153988577

OPINION MUST BE CORRELATES WITH CLINICALLY & OTHER INVESTIGATION FOR FINAL DIAGNOSIS. NOT FOR MEDICO LEGAL PURPOSE

PATIENT NAME : Mrs. VEENA KUMARI

PATIENT ID: 1445

COL DATE : 23/10/2024

REPORTING DATE: 23/10/2024

AGE SEX : 37 YRS/F

REF.BY : DR. / MEDIWHEEL..

ROUTINE EXAMINATION OF URINE

PHYSICAL EXAMINATION

Quantity	20 ml	Colour....	Pale Yellow
Appearance...	Clear	Sediment ...	Nil
Specific gravity....	1.010		

CHEMICAL EXAMINATION

Reaction	6.0	Nitrite.....	Not done
Sugar	Nil	Bile Pigment ...	Not done
Albumin	Nil	Urobilinogen....	Not done
Excess of Phosphate....	Nil	Chile.....	Not done
Bile Salt	Not Done	Acetone...	Not done

MICROSCOPIC EXAMINATION

Erythrocytes....	Nil	Casts	Nil
Leucocytes	1-4 / HPE	Crystals....	Nil
Epith. Cell	A, Few	Others	Nil

ESTB BY:-


Consultant Radiologist

Dr. P. K. Tiwari
MD, M.Sc (Radio Imaging)
Ph.D (AI) Nuclear Medicine
Consultant Imagingologist

Dr. S. Kumar
MD, (Patl)
Consultant Pathologist

Dr. Abhishek Kumar
MBBS, MD
Consultant Neurophysiologist

Dr. Kumari Suman
MBBS, DGO, MD
Consultant (TVS & HSG Specialist)

Dr. A. K. Singh
MBBS, PGDMCH
Consultant Radiologist & Sonologist

PRINTING MISTAKE SHOULD BE REPORTED BACK IMMEDIATELY / यहाँ जन्म से पहले भ्रूण का लिंग जाँच नहीं होता है।



Shubham Imaging & ALC Diagnostic Center

ISO 9001:2015 Certified Center

(A Unit of P. K. Arogyam Health & Wellness Center)

E-95, P.C. Colony, Near Sai Netryalaya Transformer, Kankarbagh, Patna - 20

✉ : alcdiagnostics@gmail.com

🌐 : www.pkarogyamhealthcheckup.com

☎ : 7050037694, 9153988577

OPINION MUST BE CORRELATES WITH CLINICALLY & OTHER INVESTIGATION FOR FINAL DIAGNOSIS. NOT FOR MEDICO LEGAL PURPOSE

Pt. Name :- VEENA KUMAR.
Ref. By :- DR./MEDIWHEEL.

Date:- 23-Oct-24
Age / Sex - 37 Yrs. F.

REAL TIME U.S.G. OF WHOLE ABDOMEN

Thanks for your kind referral

(Report.)

- LIVER** :- Measures 12.16 cm. Normal in shape, size and echo texture. There is hyperechoic multiple bright foci largest one measure 1.06 cm with casting posterior acoustic shadow seen at Rt. Lobe of liver. I.H.B.R. are not dilated. Hepatic veins are normal. No SOL seen.
- G.BL. :- Lumen is echo free. Wall thickness appears normal.
- C.B.D. :- Measures 3.5 mm in diameter with echo free lumen. No calculi or mass seen.
- P.V. :- Measures 7.1 mm in diameter. Appears normal. No thrombus seen.
- PANCREAS :- Normal in shape, size and echo texture. No calcification mass seen.
- SPLEEN :- Measures 11.84 cm. Normal in shape, size and echo texture. No SOL seen.
- KIDNEY :- Both kidney shows normal shape, size & echotexture. C.M.D intact. P.C.S are not dilated. No calculi, cyst or hydronephrosis seen on either side.
Right Kidney :- Measures 9.04 x 4.45 cm.
Left Kidney :- Measures 9.51 x 4.30 cm.
- URETER :- Not dilated. No apparent calculi seen.
- U.BLADDER :- Shows normal in outline with echo free lumen. No calculi or mass seen.
Pre void - 320 ml. Post void - is in significant
- UTERUS** :- Is Enlarged and bulky in size measures 9.65 X 6.89 cm and Anteverted in Position. Echogenicity of Myometrium is increased. Endometrial thickness is 8.2 mm. No focal mass lesion seen. cervix appear normal.
- ADNEXA :- Both ovary appears normal in size and shape.
Rt Ovary Measures - 2.79 cm. Lt Ovary Measures 3.00 cm
- P.O.D** :- Mild collection seen in P.O.D.
- R.I.F. :- Sonographically no appendicular mass or collection seen.
- OTHERS** :- Excess Gasses bowel distention seen in Abdomen. No Ascites No Lymph Adenopathy. No pleural Effusion seen on either side.

IMPRESSION

- Normal Size with Multiple Hepatic Calcification.
 - Enlarge Bulky Uterus with Mild Collection seen in P.O.D -? PID
 - Excess Gasses Bowel Distention Seen In Abdomen.
 - Adv :- Further Workup / Other Investigation.
- Otherwise sonographically normal scan. of rest organs*

23/10/24

ESTB BY:-

Consultant Radiologist

Dr. P. K. Tiwari
MD, M.Sc (Radio Imaging)
Ph.D (AI Nuclear Medicine)
Consultant Imaginologist

Dr. S. Kumar
MD, (Patl)
Consultant Pathologist

Dr. Abhishek Kumar
MBBS, MD
Consultant Neuropath Physiologist

Dr. Kumari Suman
MBBS, DGO, MD
Consultant (TVS & HSG Specialist)

Dr. A. K. Singh
MBBS, PGDMCH
Consultant Radiologist & Sonologist

PRINTING MISTAKE SHOULD BE REPORTED BACK IMMEDIATELY / यहाँ जन्म से पहले धुण का लिंग जाँच नहीं होता है।



Shubham Imaging & ALC Diagnostic Center

ISO 9001:2015 Certified Center

(A Unit of P. K. Arogyam Health & Wellness Center)

E-95, P.C. Colony, Near Sai Netryalaya Transformer, Kankarbagh, Patna - 20

✉ : alcdiagnostics@gmail.com

🌐 : www.pkarogayamhealthcheckup.com

☎ : 7050037694, 9153988577

OPINION MUST BE CORRELATES WITH CLINICALLY & OTHER INVESTIGATION FOR FINAL DIAGNOSIS. NOT FOR MEDICO LEGAL PURPOSE

Pt. Name :- VEENA DEVI
Ref. By :- DR. MEDIWHEEL

Date:- 23-Oct-24
Age / Sex - 37 Yrs. F.

Thanks for your kind referral

X-RAYCHEST (P.A.VIEW)

- The lungs on the either side show equal translucency.
- The peripheral pulmonary vasculature is normal.
- No focal lung lesion is seen.
- The pleural spaces are normal.
- Both hila are normal in size, have equal density and bear normal relationship.
- The heart and trachea are central in position and no mediastinal abnormality is visible.
- The cardiac size is normal.
- The domes of the diaphragms are normal in position, and show smooth outline.

IMPRESSION

- NO EVIDENCE OF PULMONARY OR CARDIAC PATHOLOGY IS NOTED.


23/10/24

ESTB BY:-

Consultant Radiologist

Dr. P. K. Tiwari
MD, M.Sc (Radio Imaging)
Ph.D (All Nuclear Medicine)
Consultant Imagingologist

Dr. S. Kumar
MD, (Pat)
Consultant Pathologist

Dr. Abhishek Kumar
MBBS, MD
Consultant Neuropatho Physiologist

Dr. Kumari Suman
MBBS, DGO, MD
Consultant (TVS & HSG Specialist)

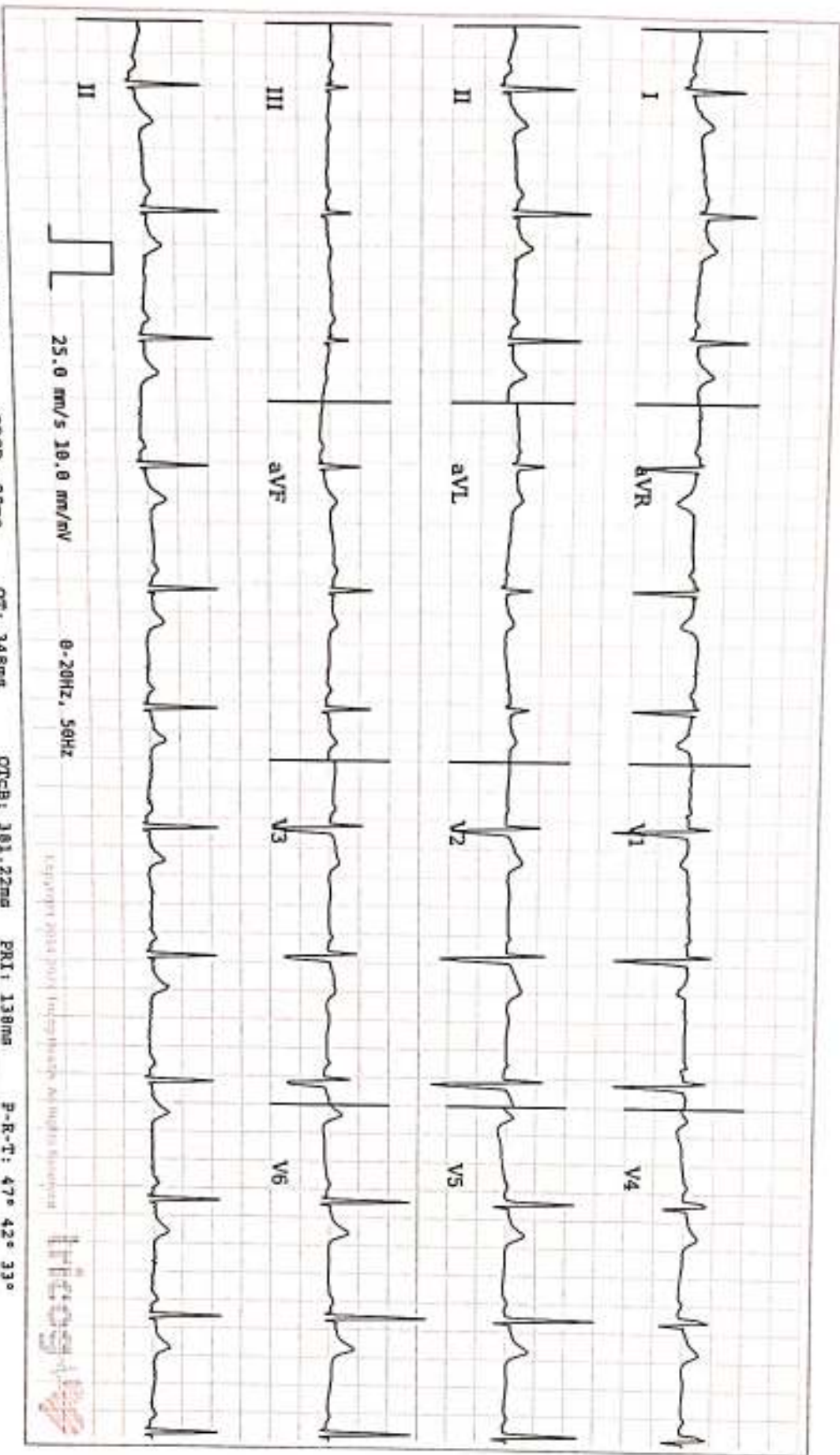
Dr. A. K. Singh
MBBS, PGDMSI
Consultant Radiologist & Sonologist

PRINTING MISTAKE SHOULD BE REPORTED BACK IMMEDIATELY / यहाँ जन्म से पहले भ्रूण का लिंग जाँच नहीं होता है।

P. K AROGYAM

Age / Gender: 37 / Female
 Patient ID: 1445
 Patient Name: Veena kumari

Date and Time: 23rd Oct 24 12:36 PM



AR: 73bpm VR: 72bpm QRSD: 80ms QT: 348ms QTcB: 101.22ms PRI: 138ms P-R-T: 47° 42° 33°

ECG Within Normal Limits: Sinus Rhythm. Please correlate clinically.

(Handwritten signature)

Disclaimer: Analysis in this report is based on ECG alone and should be used as an adjunct to clinical history, symptoms, and results of other sensitive and semi-sensitive tests and must be interpreted by a qualified physician. Patients with arrhythmias or bundle branch block may have abnormal ECGs. This report is generated by an AI algorithm (generally validated over millions of ECGs). However, algorithm inaccuracies are intended to only aid and do not replace clinical judgment. Please consult your physician for a complete diagnosis.

