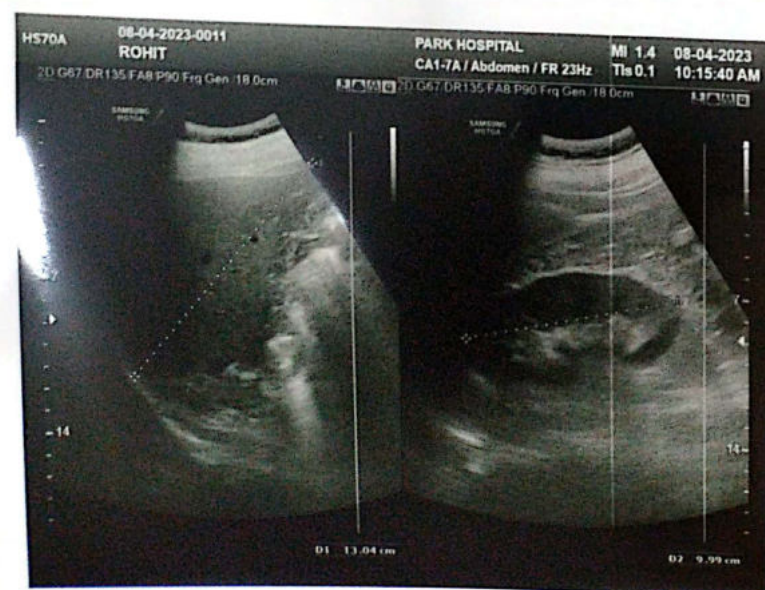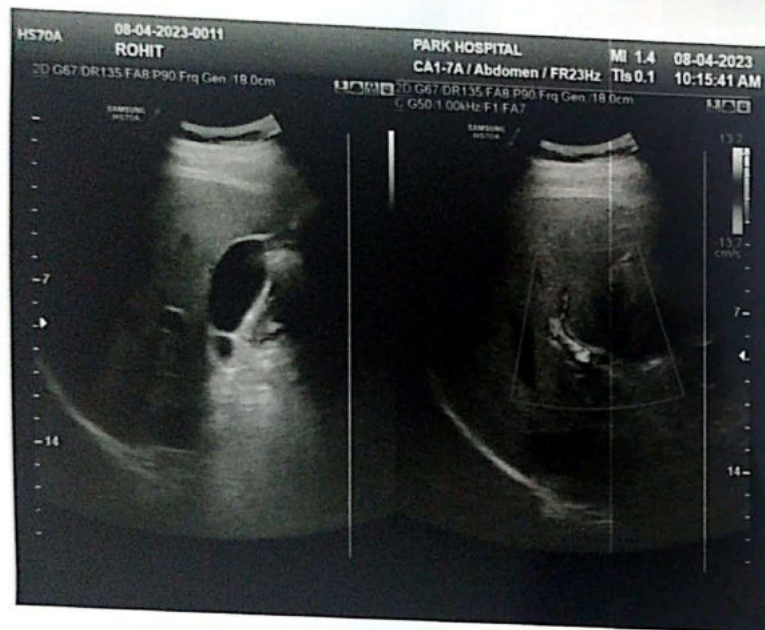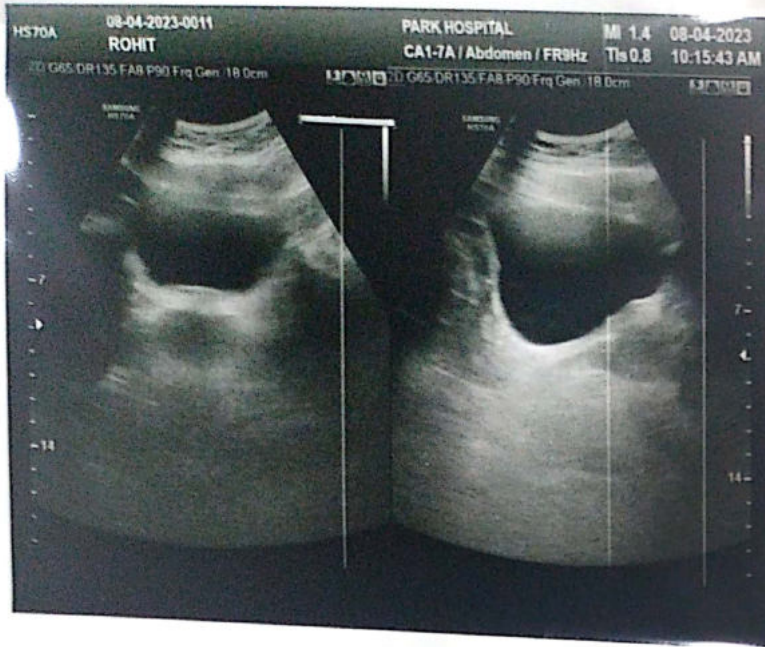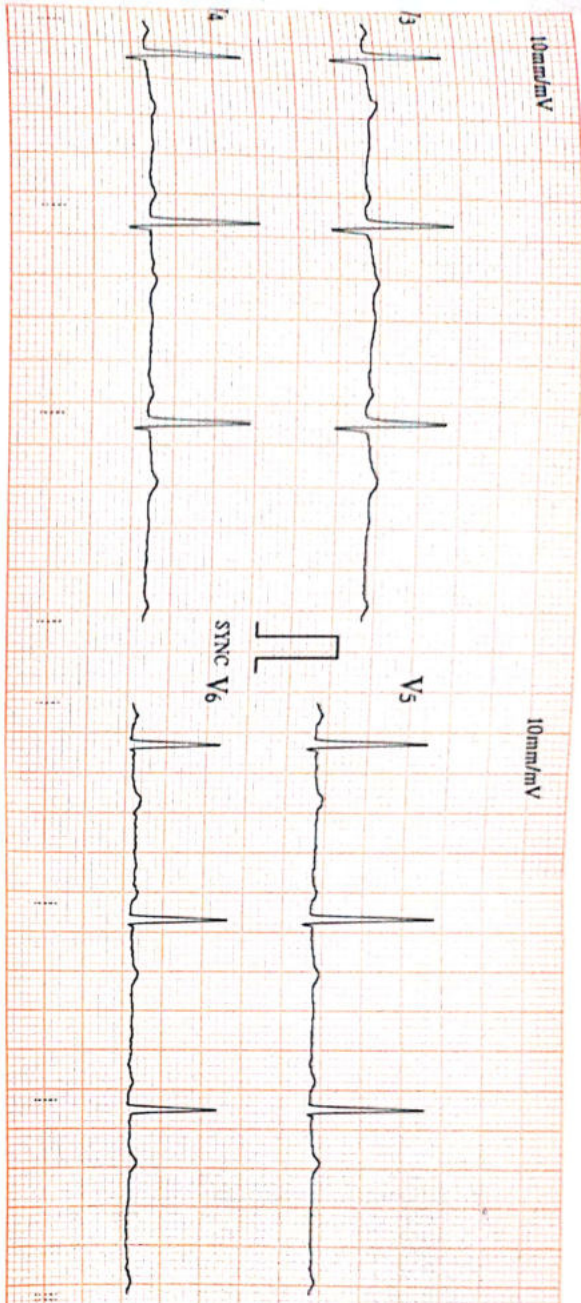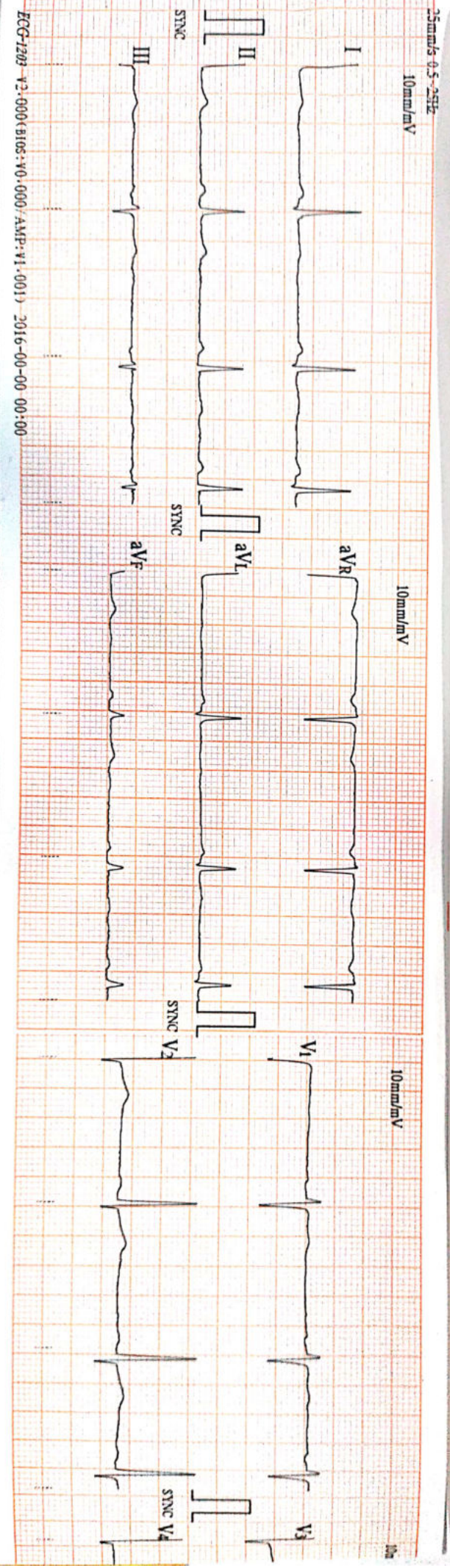


ID : 0002 **21/1/19**
 Name: **MK RAHAT**
 Sex : **male**
 Age : **35 yr**

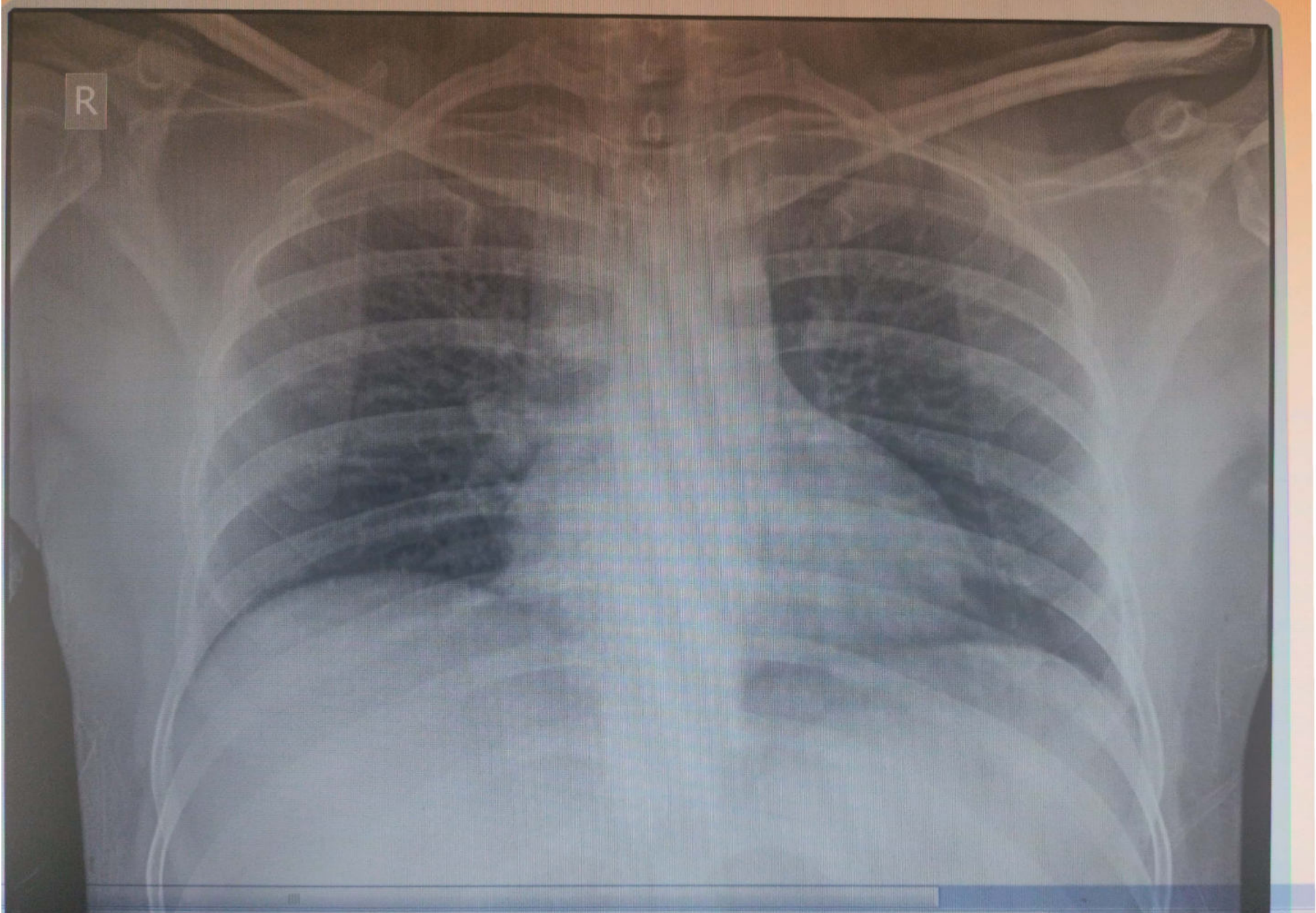
HR	: 66	bpm
R-R	: 901	ms
P-R	: 164	ms
QRS	: 82	ms
QT/QTc	: 409/430	ms
P/QRS/T	: 10/24/51	°
RV5/SV1	: 1.48/0.76	mV
RV5+SV1	: 2.24	mV

- Sinus Rhythm
- Subendocardial Infarction
- Marked Counter Clockwise Rotation
- Mild Left Axis Deviation

Unconfirmed report Verified by: _____



25mm/s 0.5-25Hz
 10mm/mV
 ECG-1203 v2.0001 BIOS: V0.0000/ANP: V1.0011 2016-00-00 00:00



ROHIT CHATTERJEE 33Y M Male Chest AP REQ-24072368 4/8/2023 11:48:05 AM
PARK HOSPITAL, SOUTH CITY II, GURGAON, HARYANA



8/4/23

Revis Charayie
33/M

No skin lesions at present

Adm :-

Rx when
lesions /
Complains
at present



(This is only professional opinion and not the diagnosis, Please correlate clinically)

Q Block South City 11, Sohna Road, Main Sector-47, Gurgaon, Haryana

Ph.: 0124-4900000 (100 Lines) Fax : 0124-2218733 E-mail : parkmedicenters@gmail.com

PARK GROUP OF HOSPITALS : West Delhi • South Delhi • Gurgaon • Karnal • Panipat • Hodal • Ambala • Behror

8/4/23

Mr. Rohit Chatterjee

33/M

Park Hospital

GROUP SUPER SPECIALITY HOSPITAL




Cert. No. MC - 4830



Cert. No. H-2016-0369

Ears.



Nose - Bk Turbinate hypertrophy (+)
Septum - midline.

Oral - Bk Tonsils grade I enlarged
not congested.

Dr
PTA



8/4/23

(This is only professional opinion and not the diagnosis, Please correlate clinically)

Q Block South City 11, Sohna Road, Main Sector-47, Gurgaon, Haryana
Ph.: 0124-4900000 (100 Lines) Fax : 0124-2218733 E-mail : parkmedicenters@gmail.com

PARK GROUP OF HOSPITALS : West Delhi • South Delhi • Gurgaon • Karnal • Panipat • Hodal • Ambala • Behror

the **health** care providers

the **health** care providers



Ophthalmology

IP-675671

Name - Rohit Chatterjee
33 y/m

Date - 8/9/23

Vitals :

Chief Complaints :

Routine eyes checkup

H/O Present Illness :

VU { 6/6 = glasses
6/6

Past History :

MU { MG
MG

MCT { 11
12

Investigation :

Drug Allergies : (if any)

Treatment :

Color Vision - Normal BE

Fundus Examination - Normal





Park Hospital

GROUP SUPER SPECIALITY HOSPITAL



Rohit.

8/11/23

- Skin & Calcule

- $\frac{1}{7}$ RCF + Hrud

Vitals :

Chief Complaints :

- Multiple Cancer

H/O Present Illness :

Her skin scanty

Past History :

- $\frac{1}{7}$ COPD

- Restlessness

Investigation :

Drug Allergies : (if any)



Treatment :

Gurgaon

Q Block South City 11, Sohna Road, Main Sector-47, Gurgaon, Haryana Ph.: 0124-49000000 Fax : 0124-2218733
E-mail : parkmedicenters@gmail.com

● West Delhi ● South Delhi ● Faridabad ● Panipat ● Karnal

the **health** care providers

the **health** care providers



Park Hospital

GROUP SUPER SPECIALITY HOSPITAL

DEPARTMENT OF PATHOLOGY

Patient Name : Mr. ROHIT CHATTERJEE
MR No : 675671
Age/Sex : 33 Years / Male
Type : OPD
TPA/Corporate : MEDIWHEEL PVT LTD
Ref Doctor : Dr.RMO

Bill Date : 08/04/2023 9.24 AM
Sample Col Dt/Tm : 08/04/2023 10:10 am
Sample Rec Dt/Tm : 08/04/2023 10:10 am
Reporting Date : 2023-04-08 00:00:00
Sample ID : 122101
Bill/Req. No. : 24072368

Test	Result	Bio. Ref. Interval	Units	Method
BLOOD SUGAR FASTING				
PLASMA GLUCOSE FASTING	88	60 - 110	mg/dl	GOD TRINDERS

***** END OF THE REPORT *****



Dr. PRADIP KUMAR
Consultant (Microbiology)

Dr. SONIA KUMARI
MD Pathology (Gold Medalist)

Dr. NISHA TIWARI
MBBS, MD (Microbiology)
USER NM SONU



Cert. No. H-2016-0369 Cert. No. MC - 4830

(This is only professional opinion and not the diagnosis, please correlate clinically)

Q Block, South City -II, Sohna Road, Sector-47, Gurgaon, Haryana
Ph.: 0124-4900000 (100 Lines), Toll Free No. : 1800-102-6767, Mob.: 62 62 82 82 35, Email: customer@parkhospital.in

PARK GROUP OF HOSPITALS : West Delhi - Gurugram - Faridabad - Sonapat - Panipat - Karnal - Ambala - Patiala - Behror - Jaipur

the health care providers

the health care providers



Park Hospital

GROUP SUPER SPECIALITY HOSPITAL

DEPARTMENT OF PATHOLOGY

Patient Name : Mr. ROHIT CHATTERJEE
 MR No : 675671
 Age/Sex : 33 Years / Male
 Type : OPD
 TPA/Corporate : MEDIWHEEL PVT LTD

Bill Date : 08/04/2023
 Reporting Date : 08/04/2023
 Sample ID : 122101
 Bill/Req. No. : 24072368
 Ref Doctor : Dr.RMO

Test	Result	Bio. Ref. Interval	Units	Method
BLOOD SUGAR 2 HR. PP				
BLOOD SUGAR P.P.	97	80 - 150	mg/dl	

***** END OF THE REPORT *****



Sample no.

Dr. SONIA KUMARI
 MBBS, MD (PATHOLOGY) Gold medalist

Dr. PRADIP KUMAR
 Consultant (Microbiology)

Dr. NISHA TIWARI
 MBBS, MD (Microbiology)

USER NM ARUN



Cert. No. H-2016-0369 Cert. No. MC - 4830

(This is only professional opinion and not the diagnosis, please correlate clinically)
 Q Block, South City -II, Sohna Road, Sector-47, Gurgaon, Haryana

Ph.: 0124-4900000 (100 Lines), Toll Free No. : 1800-102-6767, Mob.: 62 62 82 82 35, Email: customercare@parkhospital.in

PARK GROUP OF HOSPITALS : West Delhi - Gurugram - Faridabad - Sonapat - Panipat - Karnal - Ambala - Patiala - Behror - Jaipur

the health care providers

the health care providers



DEPARTMENT OF PATHOLOGY

Patient Name : Mr. ROHIT CHATTERJEE
MR No : 675671
Age/Sex : 33 Years / Male
Type : OPD
TPA/Corporate : MEDIWHEEL PVT LTD

Bill Date : 08/04/2023
Reporting Date : 08/04/2023
Sample ID : 122101
Bill/Req. No. : 24072368
Ref Doctor : Dr.RMO

Test	Result	Bio. Ref. Interval	Units	Method
URINE ROUTINE AND MICROSCOPY				
PHYSICAL CHARACTERSTICS				
QUANTITY	30ml	5 - 100	ml	
COLOUR	Pale Yellow	Pale Yellow		Vishal
TURBIDITY	Clear	clear		
SPECIFIC GRAVITY	1.020	1.000-1.030		urinometer
PH	Acidic	Acidic/Alkaline		PH PAPER
CHEMICAL EXAMINATION-1				
UROBILINOGEN	NIL	NIL		Ehrlich
URINE PROTEIN	NIL	NIL	mg/dl	Protein error indicator
BLOOD	NIL	NIL		
URINE BILIRUBIN	NIL	NIL		
GLUCOSE	NIL	NIL	mg/dL	GOD-POD/Benedicts
URINE KETONE	NIL	NIL		SOD.
MICRO.EXAMINATION				
PUS CELL	2-4	0-5	cells/hpf	Microscopic
RED BLOOD CELLS	Nil	0-2	cells/hpf	
EPITHELIAL CELLS	1-2	0-5	cells/hpf	
CASTS	NIL	NIL	/lpf	
CRYSTALS	NIL	NIL	/hpf	
OTHER	NIL			

***** END OF THE REPORT *****



Sample no.

Dr. SONIA KUMARI
 MBBS, MD (PATHOLOGY) Gold medalist

Dr. PRADIP KUMAR
 Consultant (Microbiology)

Dr. NISHA TIWARI
 MBBS, MD (Microbiology)

USER NM ARUN



Cert. No. H-2016-0369 Cert. No. MC - 4830

(This is only professional opinion and not the diagnosis, please correlate clinically)

Page 1 of 1

Q Block, South City -II, Sohna Road, Sector-47, Gurgaon, Haryana

Ph.: 0124-4900000 (100 Lines), Toll Free No. : 1800-102-6767, Mob.: 62 62 82 82 35, Email: customercare@parkhospital.in

PARK GROUP OF HOSPITALS : West Delhi - Gurugram - Faridabad - Sonapat - Panipat - Karnal - Ambala - Patiala - Behror - Jaipur



Park Hospital

GROUP SUPER SPECIALITY HOSPITAL

DEPARTMENT OF PATHOLOGY

Patient Name : Mr. ROHIT CHATTERJEE
MR No : 675671
Age/Sex : 33 Years / Male
Type : OPD
TPA/Corporate : MEDIWHEEL PVT LTD

Bill Date : 08/04/2023
Reporting Date : 08/04/2023
Sample ID : 122095
Bill/Req. No. : 24072368
Ref Doctor : Dr.RMO

Test	Result	Bio. Ref. Interval	Units	Method
BLOOD GROUPING AND RH FACTOR				
BLOOD GROUP	" O " RH POSITIVE			MATRIX GEL

***** END OF THE REPORT *****



Sample no.

Dr. SONIA KUMARI
 MBBS, MD (PATHOLOGY) Gold medalist

Dr. PRADIP KUMAR
 Consultant (Microbiology)

Dr. NISHA TIWARI
 MBBS, MD (Microbiology)

USER NM SONU



Cert. No. H-2016-0369 Cert. No. MC - 4830

(This is only professional opinion and not the diagnosis, please correlate clinically)

Page 1 of 1

Q Block, South City -II, Sohna Road, Sector-47, Gurgaon, Haryana

Ph.: 0124-4900000 (100 Lines), Toll Free No. : 1800-102-6767, Mob.: 62 62 82 82 35, Email: customercare@parkhospital.in

PARK GROUP OF HOSPITALS : West Delhi - Gurugram - Faridabad - Sonapat - Panipat - Karnal - Ambala - Patiala - Behror - Jaipur

the health care providers

the health care providers



DEPARTMENT OF PATHOLOGY

Patient Name : Mr. ROHIT CHATTERJEE
 MR No : 675671
 Age/Sex : 33 Years / Male
 Type : OPD
 TPA/Corporate : MEDIWHEEL PVT LTD

Bill Date : 08/04/2023
 Reporting Date : 08/04/2023
 Sample ID : 122095
 Bill/Req. No. : 24072368
 Ref Doctor : Dr.RMO

Test	Result	Bio. Ref. Interval	Units	Method
CBC				
HAEMOGLOBIN	13.2	12 - 16	gm/dL	COLORIMETRY
TOTAL LEUCOCYTE COUNT	5300	4000-11000	/ μ L	ELECTRICAL
DIFFERENTIAL COUNT				
NEUTROPHILS	60	40.0 - 80.0	%	FLOW CYTOMETRY
LYMPHOCYTES	35	20.0 - 40.0	%	FLOW CYTOMETRY
MONOCYTES	03	2.0 - 10.0	%	FLOW CYTOMETRY
EOSINOPHILS	02	0.0 - 5.0	%	FLOW CYTOMETRY
BASOPHILS	00	0.0 - 2.0	%	FLOW CYTOMETRY
RED BLOOD CELL COUNT	4.8	3.5 - 5.5	millions/ μ L	ELECTRICAL
PACKED CELL VOLUME	42.3	35.0 - 50.0	%	ELECTRICAL
MEAN CORPUSCULAR VOLUME	86.8	83 - 101	fL	ELECTRICAL
MEAN CORPUSCULAR HAEMOGLOBIN	27.1	27 - 31	Picogrammes	CALCULATED
MEAN CORPUSCULAR HB CONC	31.2	L 33 - 37	g/dl	CALCULATED
PLATELET COUNT	98	L 150 - 450	thou/ μ L	ELECTRICAL
RDW	13.4	11.6 - 14.5	%	CALCULATED

***** END OF THE REPORT *****



Sample no.

Dr. SONIA KUMARI
 MBBS, MD (PATHOLOGY) Gold medalist

Dr. PRADIP KUMAR
 Consultant (Microbiology)

Dr. NISHA TIWARI
 MBBS, MD (Microbiology)

USER NM SONU



Cert. No. H-2016-0369 Cert. No. MC - 4830

(This is only professional opinion and not the diagnosis, please correlate clinically)

Q Block, South City -II, Sohna Road, Sector-47, Gurgaon, Haryana

Ph.: 0124-4900000 (100 Lines), Toll Free No. : 1800-102-6767, Mob.: 62 62 82 82 35, Email: customercare@parkhospital.in

PARK GROUP OF HOSPITALS : West Delhi - Gurugram - Faridabad - Sonapat - Panipat - Karnal - Ambala - Patiala - Behror - Jaipur



Park Hospital

GROUP SUPER SPECIALITY HOSPITAL

DEPARTMENT OF PATHOLOGY

Patient Name : Mr. ROHIT CHATTERJEE
MR No : 675671
Age/Sex : 33 Years / Male
Type : OPD
TPA/Corporate : MEDIWHEEL PVT LTD

Bill Date : 08/04/2023
Reporting Date : 08/04/2023
Sample ID : 122095
Bill/Req. No. : 24072368
Ref Doctor : Dr.RMO

Test	Result	Bio. Ref. Interval	Units	Method
ESR (WESTERGREN)				
E.S.R. - II HR.	35		mm II Hr.	Westergren

***** END OF THE REPORT *****



Sample no.

Dr. SONIA KUMARI
MBBS, MD (PATHOLOGY) Gold medalist

Dr. PRADIP KUMAR
Consultant (Microbiology)

Dr. NISHA TIWARI
MBBS, MD (Microbiology)

USER NM SONU



Cert. No. H-2016-0369

Cert. No. MC - 4830

(This is only professional opinion and not the diagnosis, please correlate clinically)

Q Block, South City -II, Sohna Road, Sector-47, Gurgaon, Haryana
Ph.: 0124-4900000 (100 Lines), Toll Free No. : 1800-102-6767, Mob.: 62 62 82 82 35, Email: customercare@parkhospital.in

PARK GROUP OF HOSPITALS : West Delhi - Gurugram - Faridabad - Sonapat - Panipat - Karnal - Ambala - Patiala - Behror - Jaipur

the **health** care providers

the **health** care providers



Park Hospital

GROUP SUPER SPECIALITY HOSPITAL

DEPARTMENT OF PATHOLOGY

Patient Name : Mr. ROHIT CHATTERJEE
 MR No : 675671
 Age/Sex : 33 Years / Male
 Type : OPD
 TPA/Corporate : MEDIWHEEL PVT LTD

Bill Date : 08/04/2023
 Reporting Date : 10/04/2023
 Sample ID : 122095
 Bill/Req. No. : 24072368
 Ref Doctor : Dr.RMO

Test	Result	Bio. Ref. Interval	Units	Method
URINE C/S				
NAME OF SPECIMEN	URINE			Aerobic culture
ORGANISM IDENTIFIED	NO GROWTH SEEN IN CULTURE AFTER 48HRS OF INCUBATION AT 37 C DEGREE.			

Method :

Note :

***** END OF THE REPORT *****



Sample no.

Dr. SONIA KUMARI
 MBBS, MD (PATHOLOGY) Gold medalist

Dr. PRADIP KUMAR
 Consultant (Microbiology)

Dr. NISHA TIWARI
 MBBS, MD (Microbiology)

USER NM ANJALIPA911



Cert. No. H-2016-0369 Cert. No. MC - 4830

(This is only professional opinion and not the diagnosis, please correlate clinically)

Page 1 of 1

Q Block, South City -II, Sohna Road, Sector-47, Gurgaon, Haryana

Ph.: 0124-4900000 (100 Lines), Toll Free No. : 1800-102-6767, Mob.: 62 62 82 82 35, Email: customercare@parkhospital.in

PARK GROUP OF HOSPITALS : West Delhi - Gurugram - Faridabad - Sonapat - Panipat - Karnal - Ambala - Patiala - Behror - Jaipur

the health care providers

the health care providers



DEPARTMENT OF PATHOLOGY

Patient Name : Mr. ROHIT CHATTERJEE
MR No : 675671
Age/Sex : 33 Years / Male
Type : OPD
TPA/Corporate : MEDIWHEEL PVT LTD

Bill Date : 08/04/2023
Reporting Date : 08/04/2023
Sample ID : 122095
Bill/Req. No. : 24072368
Ref Doctor : Dr.RMO

Test	Result	Bio. Ref. Interval	Units	Method
THYROID PROFILE				
TRI-IODOTHYRONINE (T3)	0.89	0.60 - 1.81	ng/ml	Chemiluminescence
THYROXINE (T4)	7.2	5.01 - 12.45	µg/dL	Chemiluminescence
THYROID STIMULATING HORMONE	4.30	0.5-5.50	µIU/ml	
SPECIMEN TYPE	SERUM			

Method : chemiluminescent immunoassay

Note : Clinical Significance:

Thyroid function tests (TFTs) is a collective term for blood tests used to check the function of the thyroid. TFTs may be requested if a patient is thought to suffer from hyperthyroidism (overactive thyroid) or hypothyroidism (underactive thyroid), or to monitor the effectiveness of either thyroid-suppression or hormone replacement therapy. It is also requested routinely in conditions linked to thyroid disease, such as atrial fibrillation and anxiety disorder. A TFT panel typically includes thyroid hormones such as thyroid-stimulating hormone (TSH, thyrotropin) and thyroxine (T4), and triiodothyronine (T3) depending on local laboratory policy.

Note: Please correlate with clinical condition

***** END OF THE REPORT *****



Sample no.

Dr. SOMIA KUMARI
 MBBS, MD (PATHOLOGY) Gold medalist

Dr. PRADIP KUMAR
 Consultant (Microbiology)

Dr. NISHA TIWARI
 MBBS, MD (Microbiology)

USER NM PAWAN



Cert. No. H-2016-0369 Cert. No. MC - 4830

(This is only professional opinion and not the diagnosis, please correlate clinically)

Page 1 of 1

Q Block, South City -II, Sohna Road, Sector-47, Gurgaon, Haryana

Ph.: 0124-4900000 (100 Lines), Toll Free No. : 1800-102-6767, Mob.: 62 62 82 82 35, Email: customercare@parkhospital.in

PARK GROUP OF HOSPITALS : West Delhi - Gurugram - Faridabad - Sonapat - Panipat - Karnal - Ambala - Patiala - Behror - Jaipur



DEPARTMENT OF PATHOLOGY

Patient Name : Mr. ROHIT CHATTERJEE
MR No : 675671
Age/Sex : 33 Years / Male
Type : OPD
TPA/Corporate : MEDIWHEEL PVT LTD

Bill Date : 08/04/2023
Reporting Date : 08/04/2023
Sample ID : 122095
Bill/Req. No. : 24072368
Ref Doctor : Dr.RMO

Test	Result	Bio. Ref. Interval	Units	Method
LFT (LIVER FUNCTION TEST)				
LFT				DIAZO
TOTAL BILIRUBIN	0.7	0 - 1.2	mg/dL	DIAZO
DIRECT BILIRUBIN	0.3	0 - 0.4	mg/dL	CALCULATED
INDIRECT BILIRUBIN	0.4	0.10 - 0.6	mg/dL	IFCC WITHOUT
SGOT (AST)	23	0 - 45	U/L	IFCC WITHOUT
SGPT (ALT)	62	<i>H</i> 0 - 45	U/L	MODIFIED IFCC
ALKALINE PHOSPHATASE	103	30 - 170	IU/L	BIURET
TOTAL PROTEINS	6.3	<i>L</i> 6.4 - 8.0	g/dL	BCG DYE
ALBUMIN	3.9	3.3 - 5.5	g/dL	CALCULATED
GLOBULIN	2.4	2.3 - 4.5	g/dL	CALCULATED
A/G RATIO	1.63	1.1 - 2.2		

***** END OF THE REPORT *****



Sample no.

Dr. SONIA KUMARI
 MBBS, MD (PATHOLOGY) Gold medalist

Dr. PRADIP KUMAR
 Consultant (Microbiology)

Dr. NISHA TIWARI
 MBBS, MD (Microbiology)

USER NM SONU



Cert No. H-2016-0360 Cert No. MC - 4830

(This is only professional opinion and not the diagnosis, please correlate clinically)
 Q Block, South City -II, Sohna Road, Sector-47, Gurgaon, Haryana

Ph.: 0124-4900000 (100 Lines), Toll Free No. : 1800-102-6767, Mob.: 62 62 82 82 35, Email: customercare@parkhospital.in

PARK GROUP OF HOSPITALS : West Delhi - Gurugram - Faridabad - Sonapat - Panipat - Karnal - Ambala - Patiala - Behror - Jaipur



DEPARTMENT OF PATHOLOGY

Patient Name : Mr. ROHIT CHATTERJEE
 MR No : 675671
 Age/Sex : 33 Years / Male
 Type : OPD
 TPA/Corporate : MEDIWHEEL PVT LTD

Bill Date : 08/04/2023
 Reporting Date : 08/04/2023
 Sample ID : 122095
 Bill/Req. No. : 24072368
 Ref Doctor : Dr.RMO

Test	Result	Bio. Ref. Interval	Units	Method
KFT (RENAL PROFILE)				
KFT				
SERUM UREA	23	10 - 45	mg/dL	UREASE-GLDH
SERUM CREATININE	1.0	0.4 - 1.4	mg/dL	MODIFIED JAFFES
SERUM URIC ACID	5.1	2.5 - 7.0	mg/dL	URICASE
SERUM SODIUM	138	136 - 148	mmol/L	ISE
SERUM POTASSIUM	5.2	3.5 - 5.5	meq/l	ISE
SERUM CALCIUM	8.6	8.5 - 10.5	mg/dL	ARSENazo III
SERUM PHOSPHORUS	2.7	2.5 - 4.5	mg/dL	AMMONIUM

***** END OF THE REPORT *****



Sample no.

Dr. SONIA KUMARI
 MBBS, MD (PATHOLOGY) Gold medalist

Dr. PRADIP KUMAR
 Consultant (Microbiology)

Dr. NISHA TIWARI
 MBBS, MD (Microbiology)

USER NM SONU



Cert. No. H-2016-0369 Cert. No. MC - 4830

(This is only professional opinion and not the diagnosis, please correlate clinically)

Page 1 of 1

Q Block, South City -II, Sohna Road, Sector-47, Gurgaon, Haryana

Ph.: 0124-4900000 (100 Lines), Toll Free No. : 1800-102-6767, Mob.: 62 62 82 82 35, Email: customercare@parkhospital.in

PARK GROUP OF HOSPITALS : West Delhi - Gurugram - Faridabad - Sonapat - Panipat - Karnal - Ambala - Patiala - Behror - Jaipur



DEPARTMENT OF PATHOLOGY

Patient Name : Mr. ROHIT CHATTERJEE
MR No : 675671
Age/Sex : 33 Years / Male
Type : OPD
TPA/Corporate : MEDIWHEEL PVT LTD

Bill Date : 08/04/2023
Reporting Date : 08/04/2023
Sample ID : 122095
Bill/Req. No. : 24072368
Ref Doctor : Dr.RMO

Test	Result	Bio. Ref. Interval	Units	Method
LIPID PROFILE				
LIPID PROFILE				
TOTAL CHOLESTEROL	290	H 0 - 250	mg/dL	CHOD -Trinder
SERUM TRIGLYCERIDES	161	60 - 165	mg/dl	GPO-TRINDER
HDL-CHOLESTEROL	37	30 - 70	mg/dl	DIRECT
VLDL CHOLESTEROL	32	6 - 32	mg/dL	calculated
LDL	221	H 50 - 135	mg/dl	calculated
LDL CHOLESTEROL/HDL RATIO	5.9	H 1.0 - 3.0	mg/dL	calculated
TOTAL CHOLESTEROL/HDL RATIO	7.8	H 2.0 - 5.0	mg/dl	calculated

***** END OF THE REPORT *****



Sample no.

Dr. SONIA KUMARI
 MBBS, MD (PATHOLOGY) Gold medalist

Dr. PRADIP KUMAR
 Consultant (Microbiology)

Dr. NISHA TIWARI -
 MBBS, MD (Microbiology)

USER NM SONU



Cert. No. H-2016-0369

Cert. No. MC - 4830

(This is only professional opinion and not the diagnosis, please correlate clinically)

Q Block, South City -II, Sohna Road, Sector-47, Gurgaon, Haryana

Ph.: 0124-4900000 (100 Lines), Toll Free No. : 1800-102-6767, Mob.: 62 62 82 82 35, Email: customercare@parkhospital.in

PARK GROUP OF HOSPITALS : West Delhi - Gurugram - Faridabad - Sonapat - Panipat - Karnal - Ambala - Patiala - Behror - Jaipur



DEPARTMENT OF IMMUNOLOGY

Patient Name : Mr. ROHIT CHATTERJEE
MR No : 675671
Age/Sex : 33 Years / Male
Type : OPD
TPA/Corporate : MEDIWHEEL PVT LTD
Ref Doctor : Dr.RMO

Bill Date : 08/04/2023 9:24 AM
Sample Col Dt/Tm : 08/04/2023 10:10 am
Sample Rec Dt/Tm : 08/04/2023 10:10 am
Reporting Date : 2023-04-08 00:00:00-01 15:54:
Sample ID : 122095
Bill/Req. No. : 24072368

Test	Result	Bio. Ref. Interval	Units	Method
PSA TOTAL				
PROSTATE SPECIFIC ANTIGEN(PSA)	0.47	L 0.57 - 4.0	ng/ml	Chemiluminescence
SPECIMEN TYPE	SERUM			

Method : chemiluminescent immunoassay

Note : Clinical Use: -

An aid in the early detection of Prostate cancer in Male. Follow up and amazement of Prostate cancer patients. Detect metastatic or persistent disease in patients following surgical or medical treatment of Prostate cancer

Note : -

False negative / positive results are observed in patients receiving mouse monoclonal antibodies for diagnosis or therapy. PSA levels may appear consistently elevated / depressed due to the interference by heterophilic antibodies & non-specific protein binding. PSA values regardless of levels should not be interpreted as absolute evidence of the presence or absence of disease. All values should be correlated with clinical findings and results of other investigations.

***** END OF THE REPORT *****



Dr. PRADIP KUMAR
 Consultant (Microbiology)

Dr. SONIA KUMARI
 MD Pathology (Gold Medalist)

Dr. NISHA TIWARI
 MBBS, MD (Microbiology)
 USER NM PAWAN



(This is only professional opinion and not the diagnosis, please correlate clinically) Page 1 of 1

Cert. No. H-2016-0369 Cert. No. MC - 4830

Q Block, South City -II, Sohna Road, Sector-47, Gurgaon, Haryana
 Ph.: 0124-4900000 (100 Lines), Toll Free No. : 1800-102-6767, Mob.: 62 62 82 82 35, Email: customercare@parkhospital.in

PARK GROUP OF HOSPITALS : West Delhi - Gurugram - Faridabad - Sonapat - Panipat - Karnal - Ambala - Patiala - Behror - Jaipur



DEPARTMENT OF RADIOLOGY

Patient Name	Mr ROHIT CHATTERJEE	Billed Date	: 08/04/2023	9.24 AM
Reg No	675671	Reported Date	: 08/04/2023	
Age/Sex	33 Years / Male	Req. No.	: 24072368	
Type	OPD	Consultant Doctor	: Dr. RMO	

USG WHOLE ABDOMEN

The Real time, B mode, gray scale sonography of the abdominal organs was performed.

LIVER : The liver is normal in size, 13.0cm **with fatty infiltration**. . No evidence of any focal lesion. IHBR is not dilated.

GALL BLADDER :The gall bladder is well distended. No evidence any calculus or mass seen.No evidence of pericholecystic fluid is seen.

BILE DUCT :The common bile duct is normal in caliber. No evidence of calculus is noted in common bile duct.

SPLEEN :The spleen is normal in size 10.3 cm and shape.Its echotexture is homogeneous.No evidence of focal lesion is noted.

PANCREAS :The pancreas is normal in size, shape, contours and echotexture.No evidence of solid or cystic mass lesion is noted.MPD is not dilated. No evidence of peripancreatic collection.

KIDNEYS :The bilateral kidneys are normal in size and echotexture. Cortico-medullary differentiation is maintained.There is no evidence of obvious calculus or hydronephrosis.

URINARY BLADDER :The urinary bladder is well distended.Wall thickness within normal limits.No evidence of calculus is seen.No evidence of mass or diverticulum is noted.

PROSTATE: Prostate appears normal in shape, size and echotexture.

No evidence of ascites or interbowel free fluid is seen.

No evidence of obvious retroperitoneal or mesenteric lymphadenopathy is seen.

Bowel loop distended with gas.

IMPRESSION- Fatty liver grade-I



To be correlated clinically

Dr.ANSHU K.SHARMA
MBBS,MD
CONSULTANT RADIOLOGIST

Dr,MANJEET SEHRAWAT
MBBS,MD,PDCC
CONSULTANT RADIOLOGIST

Dr. NEENA SIKKA
MBBS,DNB
CONSULTANT RADIOLOGIST



Cert. No. H-2016-0369

Cert. No. MC - 4830

(This is only professional opinion and not the diagnosis, please correlate clinically)

Q Block, South City -II, Sohna Road, Sector-47, Gurgaon, Haryana

Ph.: 0124-4900000 (100 Lines), Toll Free No. : 1800-102-6767, Mob.: 62 62 82 82 35, Email: customercare@parkhospital.in

PARK GROUP OF HOSPITALS : West Delhi - Gurugram - Faridabad - Sonapat - Panipat - Karnal - Ambala - Patiala - Behror - Jaipur



DEPARTMENT OF RADIOLOGY

Patient Name	Mr ROHIT CHATTERJEE	Billed Date	: 08/04/2023	9.24 AM
Reg No	675671	Reported Date	: 08/04/2023	
Age/Sex	33 Years / Male	Req. No.	: 24072368	
Type	OPD	Consultant Doctor	: Dr. RMO	

X-RAY CHEST AP/PA

X-RAY CHEST P.A. VIEW

Bilateral lungs appears normal.

No focal lung lesion seen.

No evidence of free fluid is seen.

Both hila are normal in size, have equal density and bear normal relationship.

The heart and trachea are central in position and no mediastinal abnormality is visible.

The cardiac size is normal for patient age and view.

The domes of the diaphragms are normal in position, and show smooth outline.

To be correlated clinically



Dr. ANSHU K. SHARMA
MBBS, MD
CONSULTANT RADIOLOGIST

Dr. MANJEET SEHRAWAT
MBBS, MD, PDCC
CONSULTANT RADIOLOGIST

Dr. NEENA SIKKA
MBBS, DNB
CONSULTANT RADIOLOGIST



Cert. No. H-2016-0369 Cert. No. MC - 4830

(This is only professional opinion and not the diagnosis, please correlate clinically)

Q Block, South City -II, Sohna Road, Sector-47, Gurgaon, Haryana

Ph.: 0124-4900000 (100 Lines), Toll Free No. : 1800-102-6767, Mob.: 62 62 82 82 35, Email: customercare@parkhospital.in