

PTO

or calculus is noted.

Right Kidney is normal in size, shape and position. Corticomedullary differentiation (CMD) is well maintained. Normal cortical thickness is noted. No E/O hydronephrosis

No evidence of free fluid is noted.

No evidence of lymphadenopathy is noted.

IVC and aorta appear to be normal.

Spleen is normal / enlarged in size and normal in echo texture.

Pancreas appear normal in size, shape and echo texture with smooth contour. No peripancreatic pathology seen. (Not seen due to gases)

duct reveals normal course and caliber. (lot of gases & subcostally deep breaths could not be seen)

Gall Bladder is physiologically well distended / collapsed. No E/O echogenic foci in GB lumen. GB wall is normal / thickened. No E/O pericholecystic collection. common

No E/O Subdiaphragmatic Collection.

Liver appears normal / enlarged in size and shape with smooth in outline. Normal / increased parenchymal echogenicity is noted. No E/O focal lesion / IHBR dilatation is seen. Hepatic veins and portal veins appear normal.

Indication : H/O GB *concretions*

WHOLE ABDOMEN ULTRASOUND REPORT

R/B

Health check-up

Name : Mrs.

Anupam 'Inedi' 40f male

Age

YRS./F

Date

No.

10/12/2022

PNDT Registration : MPPCPNDT/BPL/2017/206

Clinic Registration : CL/5392/Jun/2017

Mob. : 89896649694, 9516333619

34, भूतल, मोहिनी अदिति आर्कड, शाहपुरा मस्जिद के पास
 भगत नगर रोड, ई-7/194, अररो कॉलोनी, भोपाल - 462038



डा. सविता प्रीतिक



Left Kidney is normal is size, shape and position. CMD is well maintained. Normal cortical thickness is noted. No E/O hydronephrosis or calculus is noted.

Urinary Bladder is well distended (physiological) / collapsed. Its contents are echo free. No E/O bladder wall thickening is noted. ~~Post-void residue is insignificant.~~

Prostate is normal in size, shape and echo texture with smooth outline. No E/O focal lesion is noted.

Uterus is ante / retro verted and normal in size, shape and echotexture with smooth outline. No E/O focal lesion is noted, endometrial echo appear normal. Cervical and vaginal shadows appear normal.

Right Ovary appears Enlarged / Normal in size, shape and echo texture.

Left Ovary appears Enlarged / Normal in size, shape and echo texture.

Impression: ~~Normal study.~~ **Make I fatty liver**

No concentration in GB seen. **Advised to review with patient**

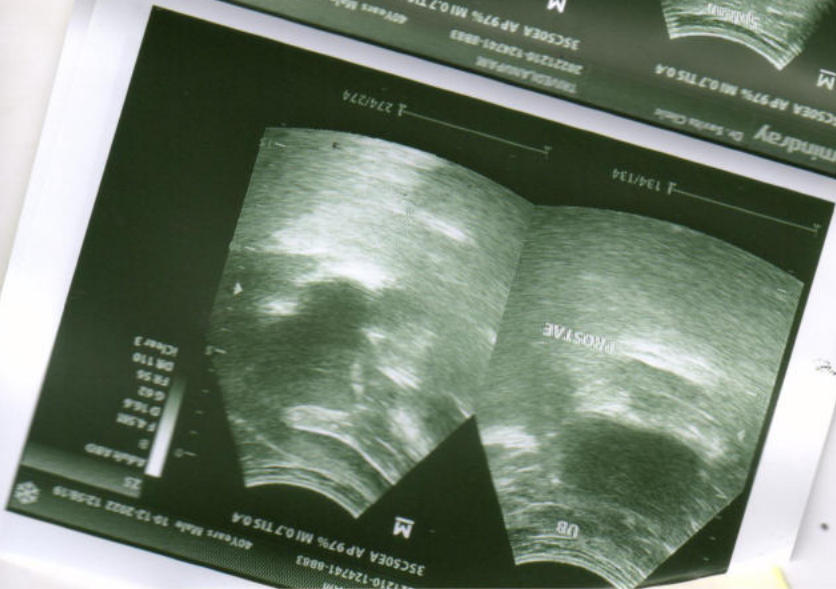
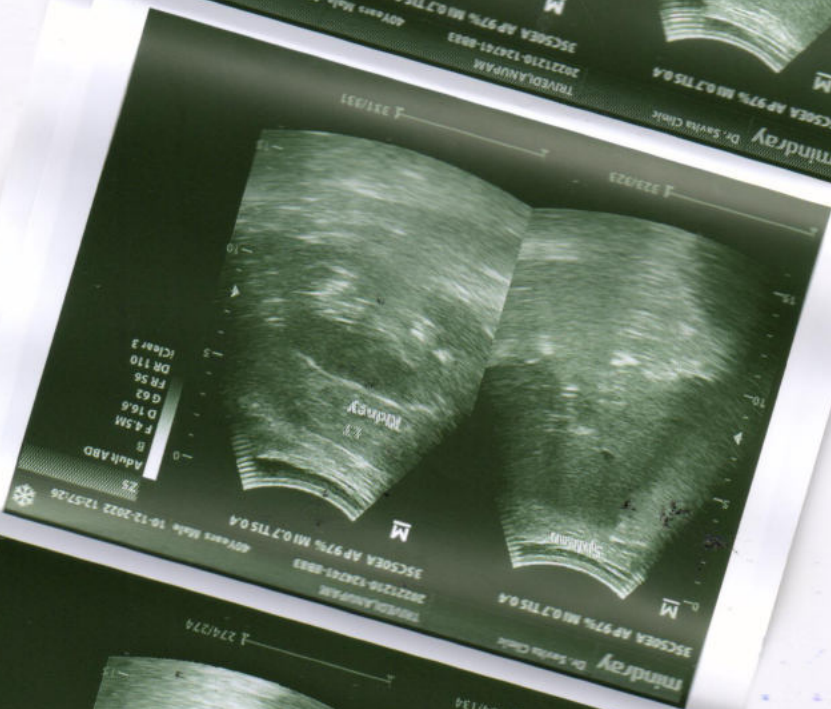
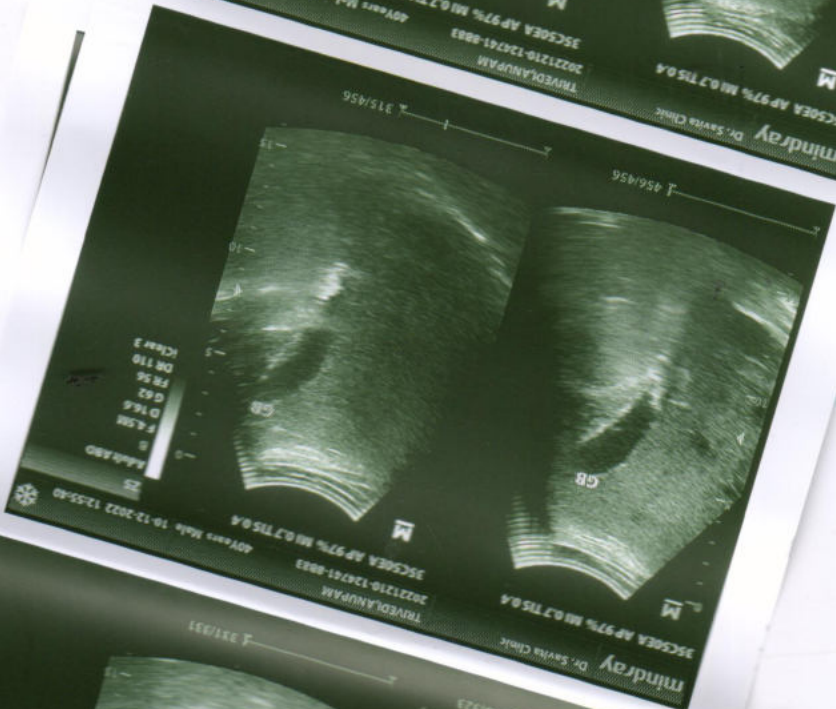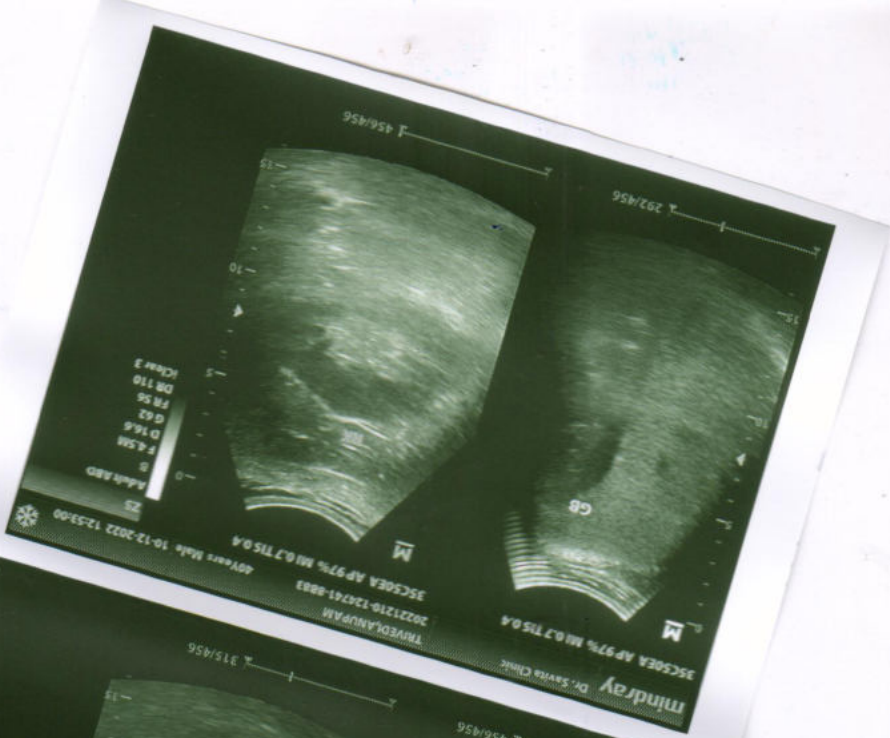
Advised clinical Correlation.

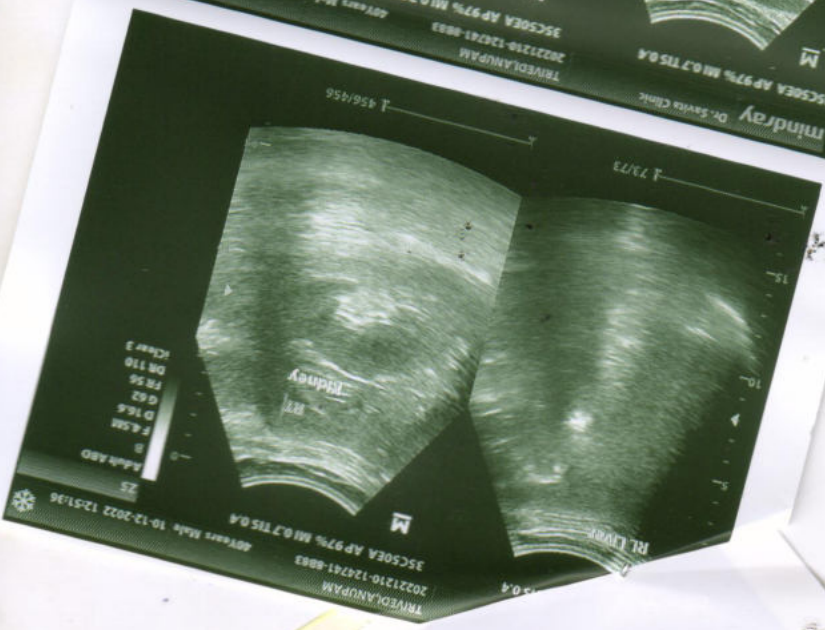
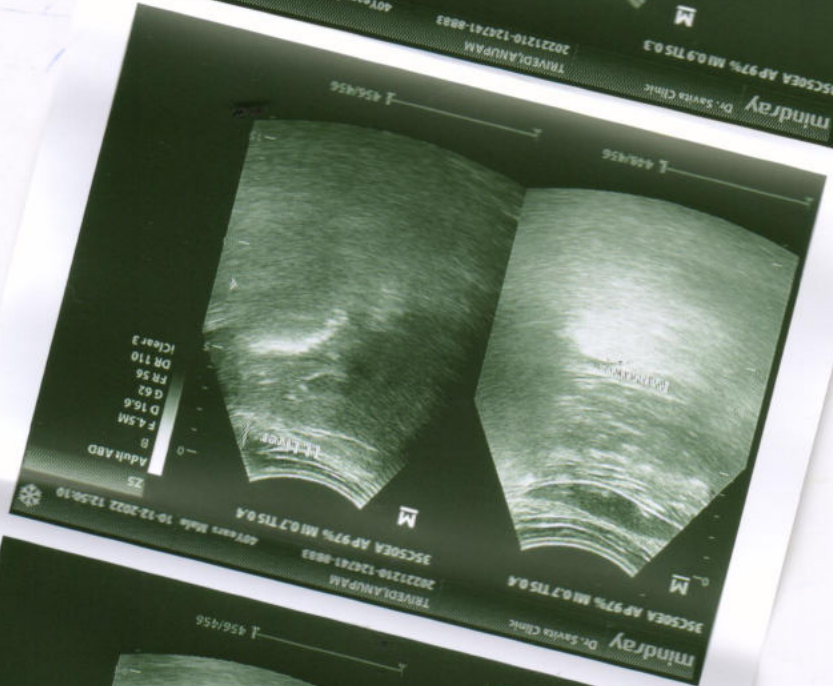
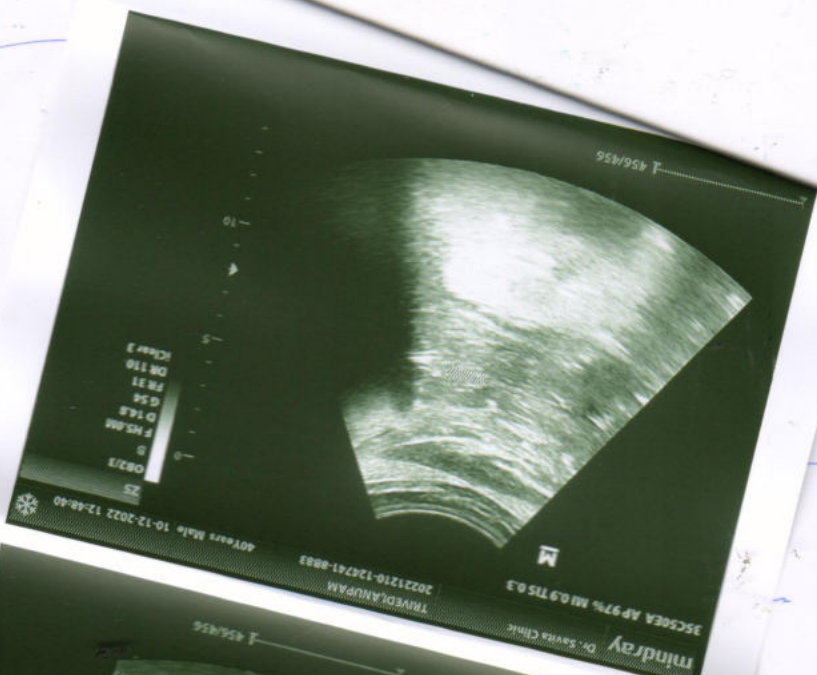
preparation.

- Job @ Coimbatore 24th

Set of day prior

9302255001
9302255001
9302255001





डिवाकर सायनॉरि-टेक सेन्टर



E-7/636, पंजाब रेगुलर बँक के पास, धर रोड, अरुण कॉलोनी श्यामल (म.प.)
 फोन: 0755-2465288, 0755-3520545 फा: 9826340190

Pt Name :- Mr. Anupam Trivedi
 Age :- 40/M
 Lab. No. :- 04
 Date :- 10/12/2022

EXAMINATION OF BLOOD

TEST	RESULT	NORMAL VALUE
Haemoglobin	15.7gms%	Female 12-16gms%, Male 14-18gms%
Red Cell count	5.20	4.5-5.6 million /cumm
Platelet Count	2.39	1.5-5.6 Lac/cumm
Leucocytes per.cumm	7600/cumm	5000-11000/cumm
Neutrophils	67%	50-70%
Lymphocytes	36%	20-40%
Eosinophils	03%	0-7%
Monocytes	04%	2-8%
PCV	47.4	37-47
MCV	91.3	76-96
MCH	30.1	27-32
MCHC	33.1	31-35
ESR	08	Male 0-9, Female 0-20mm/FHR
Blood Group	"A" Positive	By slide method
Total Serum Cholesterol	190.0	100-250 mg%
Serum Triglyceride	160.0	Up to 150 mg%
' Serum Cholesterol HDL	53.0	Up to 65 mg%
Serum Cholesterol LDL	110.0	Up to 125 mg%
VLDL	27.0	Up to 30 mg%
S.Bilirubin(Total)	0.89	0.2-1.0mg/dl
Direct	0.49	0.0-0.25mg/dl
Indirect	0.40	
SGOT	25.0	5-35U/L
SGPT	23.0	8-40U/L
Alk Phosphatase	10.5	3-13 KA units
S. Protein(Total)	6.1	6.0-8.0mg%
Albumin	4.1	3.7-5.3mg%
Globulin	2.0	1.5 to 3.5 mg%
Blood Urea	29.9	Up to 40 mg%
S.Creatine	1.0	0.5-1.4mg/dl
S. Uric Acid	6.9	3.5-7.5mg%
GGTP	21.0	5-35 U/L/dl
Fasting Blood Sugar	95.2	Up to 110 mg%
PP Blood Sugar	125.0	Up to 125 mg%
' Glycosylated Hemoglobin	5.9	Below - 6.0 % -Non Diabetic control 6-7 % -Excellent control Above- 8 % -Poor control
Thyrod Stimulating Hormone(TSH)	3.01	0.27-4.2

Pathologist

All test have technical limitation. Collaborative clinic pathological interpretation is mandatory. In case of disparity test may be repeated immediately. Typographical mistakes should be get correct instantly. This report is not valid for medico legal purpose

Dr. B. M. Agarwal
 MBBS, DCP
 Consultant Pathologist





Pathologist

Dr. B. M. Agarwal
MBBS, DCP
Consultant Pathologist

A. PHYSICAL EXAMINATION	
1. Colour	Pale Yellow
2. Appearance	Clear
3. Specific Gravity	Q.N.S.
B. CHEMICAL EXAMINATION	
1. Reaction	Acidic
2. Albumin	Nil
3. Sugar	Nil
4. Bile Salts	Absent
C. MICROSCOPIC EXAMINATION	
Pus Cells	2-3/HPF
R.B.C.	Nil
Epithelial Cell	occ
Cast	Nil
Crystals(Cal.Oxa)	Nil
Bacteria	Nil
Amorphous	Nil
T. Vaginitis	Nil

URINE ANALYSIS

Pt Name :- Mr. Anupam Trivedi
Age :- 40/M
Lab. No. :- 04
Date :- 10/12/2022

E-7/636, पंजाब रोड, अरुण कालोनी भापाल (म.प्र.)
फोन: 0755-2465288, 0755-3520545 मो: 9826340190

डिवाकर डायग्नोस्टिक सेंटर



Diwakar Diagnostic Centre
E-7/636, Arera Colony, Bhopal

900 / ANUPAM TRIVEDI / 40 Yrs / M / 0 Cms / 0 Kg Date: 10-Dec-2022 Refd By : BOB

Report

(GEM213180307)(R)Allengers



Report :

TEST OBJECTIVE : ROUTINE CHECK UP
RISK FACTOR : MALE
ACTIVITY : MODERATE ACTIVE
MEDICATION : NONE
REASON FOR TERMINATION : HEART RATE ACHIEVED
EXERCISE TOLERANCE : GOOD
EXERCISE INDUCED ARRHYTHMIAS : NO
HAEMODYNAMIC RESPONSE : NORMAL
CHRONOTROPIC RESPONSE : NORMAL
FINAL IMPRESSION : STRESS TEST IS NEGATIVE FOR EXERCISE INDUCED ISCHAEMIC HEART DISEASE

Dr. Anupam Trivedi



Stage	Time	Duration	Belt Speed (mph)	Elevation	METS	Rate	% THR Achieved	BP	RPP	PVC	Comments
Supine	00:11	0:01	00.0	00.0	01.0	84	47 %	118/78	099	00	
Standing	00:21	0:01	00.0	00.0	01.0	84	47 %	118/78	099	00	
HV	00:32	0:01	00.0	00.0	01.0	076	42 %	118/78	089	00	
Warm Up	00:44	0:01	01.0	00.0	01.0	076	42 %	118/78	089	00	
ExStart	00:52	0:06	01.7	10.0	01.1	082	46 %	118/78	096	00	
BRUCE Stage 1	03:52	3:00	01.7	10.0	04.7	117	65 %	124/84	145	00	
BRUCE Stage 2	06:52	3:00	02.5	12.0	07.1	132	73 %	130/90	171	00	
PeakEx	08:06	1:14	03.4	14.0	08.4	153	85 %	130/90	198	00	
Recovery	09:05	1:00	00.0	00.0	01.2	113	63 %	126/88	142	00	
Recovery	10:05	2:00	00.0	00.0	01.0	102	57 %	122/80	124	00	
Recovery	10:17	2:11	00.0	00.0	01.0	105	58 %	122/80	128	00	

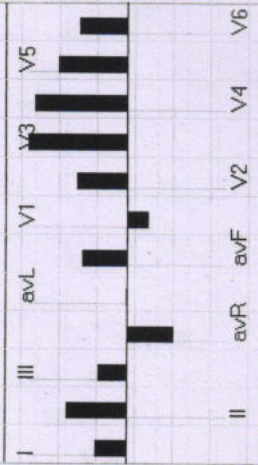
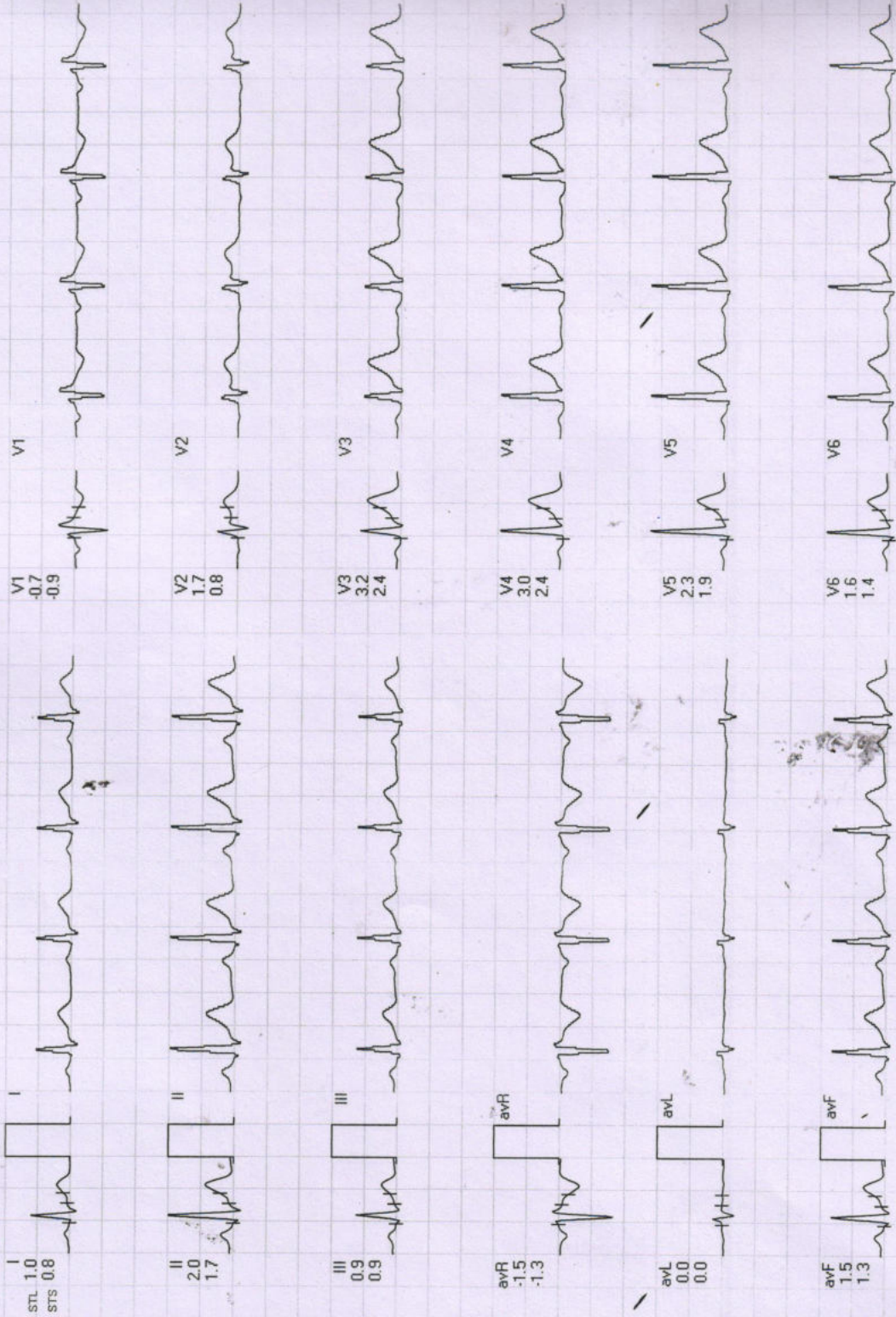
Findings :

Exercise Time : 07:15
 Max HR Attained : 153 bpm 85% of Target 180
 Max BP Attained : (Sys) 130/90
 Max WorkLoad Attained : 8.4 Fair response to induced stress
 Test End Reasons : Heart Rate Acheived

Date: 10-Dec-2022 10:50:02 AM METS: 1.0/ 84 bpm 46% of THR BP: 118/78 mmHg Raw ECG/BLC On/ Notch On/ HF 0.05 Hz/LF 20 Hz

EXTime: 00:10 0.0 mph, 0.0%
25 mm/Sec. 1.0 Cm/mV

4X 88 mS Post J



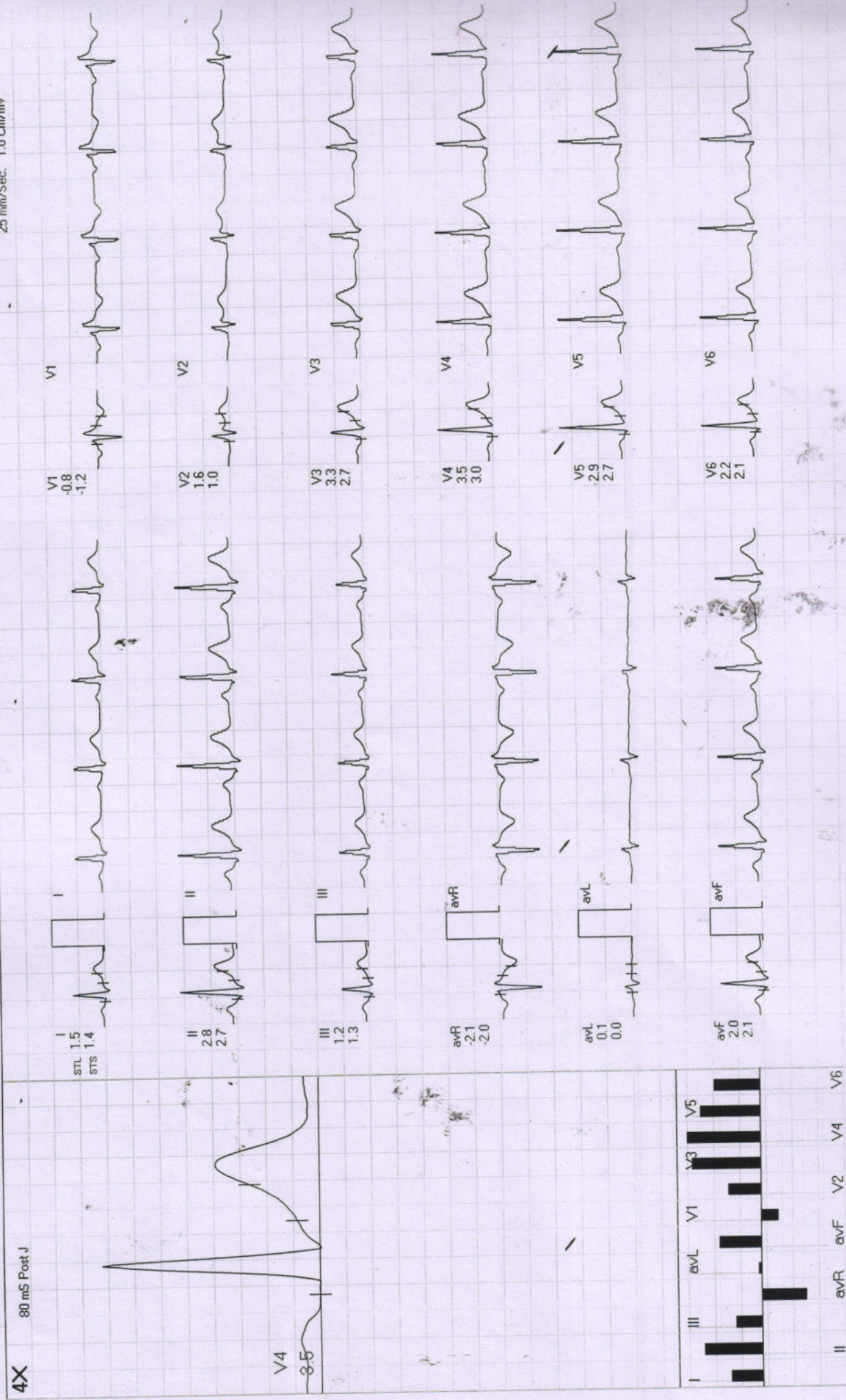STANDING

Diwakar Diagnostic Centre

900 / ANUPAM TRIVEDI / 40 Yrs / M

ExTime: 00:20 0.0 mph, 0.0%
25 mm/Sec. 1.0 Cm/mV

Date: 10-Dec-2022 10:50:02 AM METS: 1.0/84 bpm 46% of THR BP: 118/78 mmHg Raw ECG/BLC On/ Notch On/ HF 0.05 Hz/LF 20 Hz

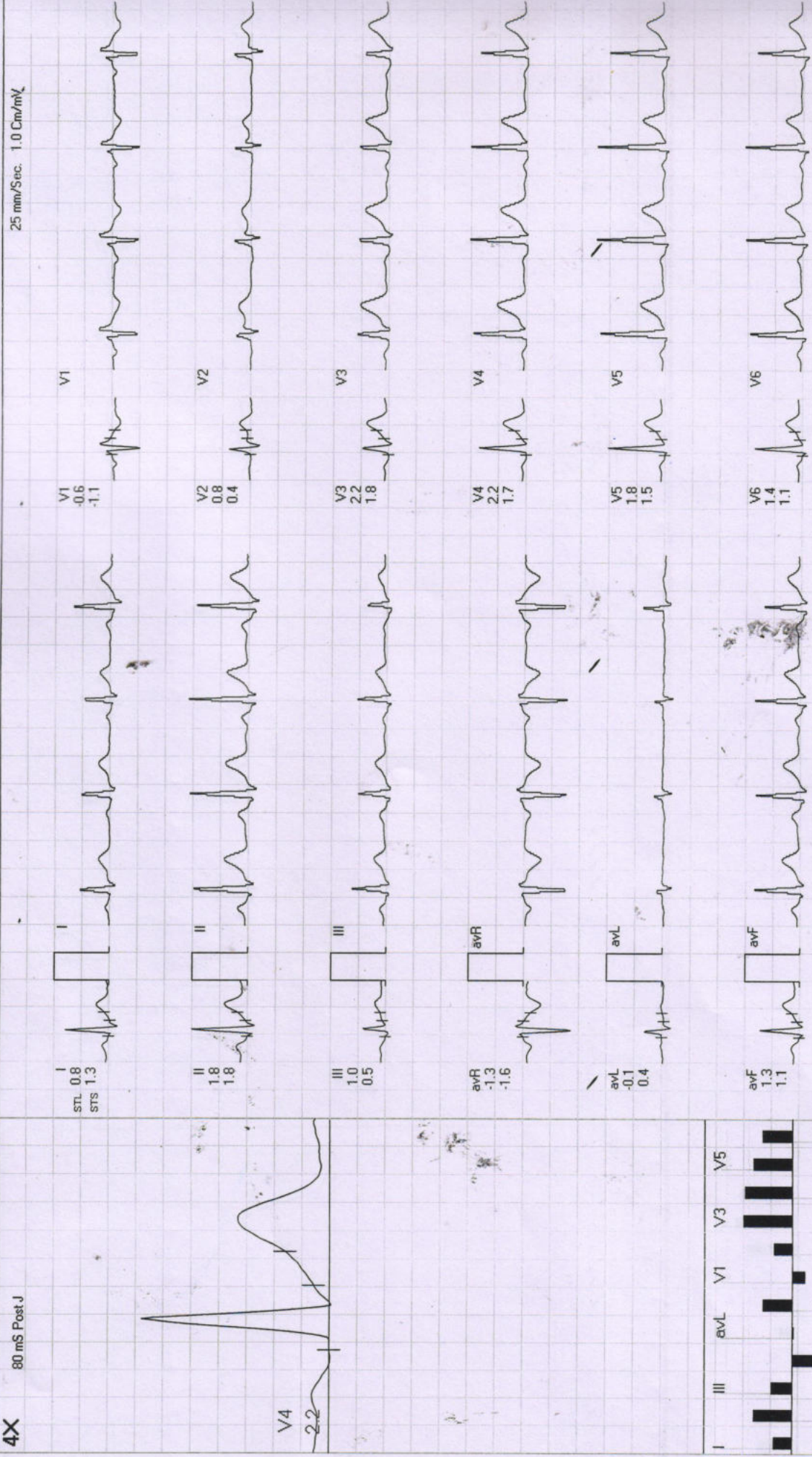


REMARKS:

Date: 10-Dec-2022 10:50:02 AM METS: 1.0/76 bpm 42% of THR BP: 118/78 mmHg Raw ECG/BLC On/ Natch On/ HF 0.05 Hz/LF 20 Hz

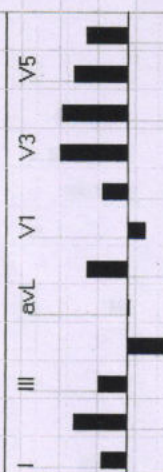
ExtTime: 00:31 0.0 mph, 0.0%

25 mm/Sec. 1.0 Cm/mV

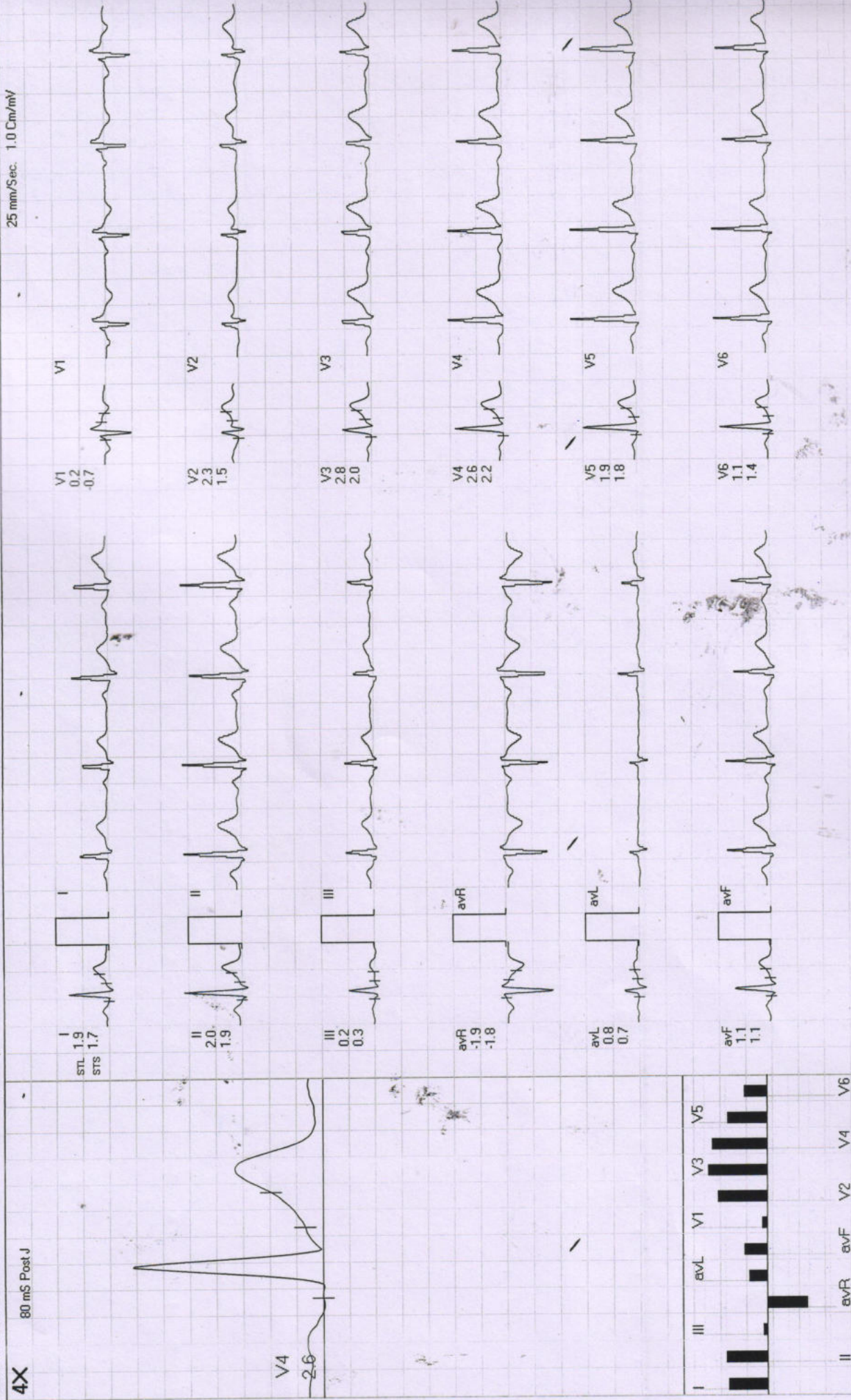


4X

80 mS Post J



REMARKS:



REMARKS:

Diwakar Diagnostic Centre

900 / ANUPAM TRIVEDI / 40 Yrs / M

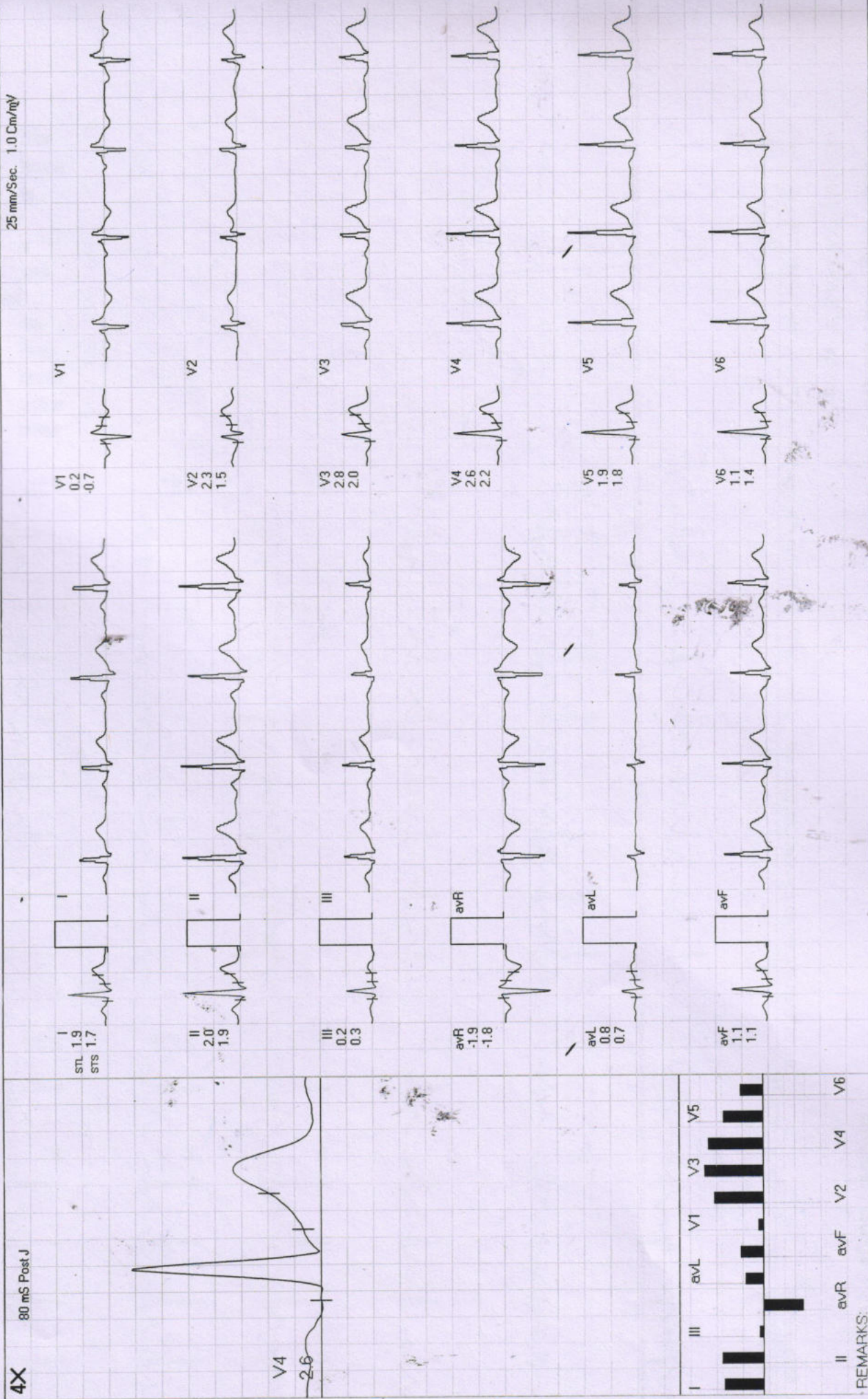
ExStrt

Date: 10-Dec-2022 10:50:02 AM METS: 1.0/76 bpm 42% of THR BP: 118/78 mmHg Raw ECG/ BLC On/ Natch On/ HF 0.05 Hz/LF 20 Hz

ExTime: 00:00 0.0 mph, 0.0%

4X

80 mS Post J



REMARKS:

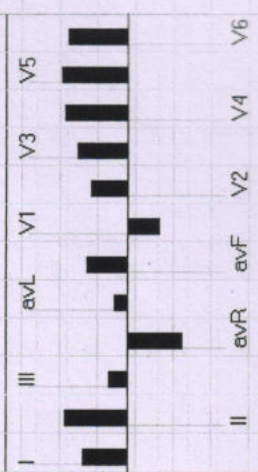
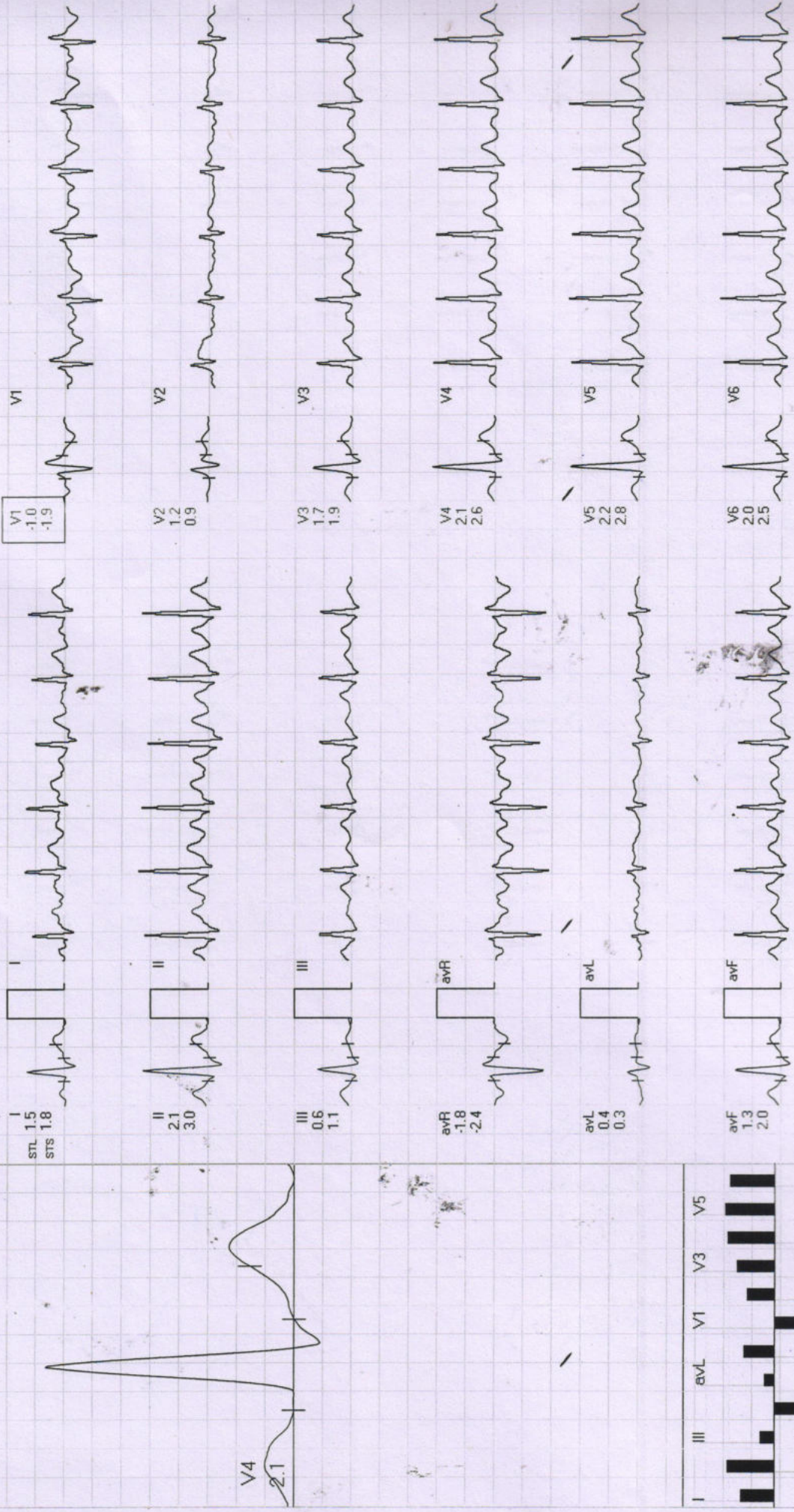


Date: 10-Dec-2022 10:50:02 AM METS: 4.7 / 117 bpm 65% of THR BP: 124/84 mmHg Raw ECG/BLC Only / Notch On/ HF 0.05 Hz/LF 20 Hz

ExTime: 03:00 1.7 mph, 10.0%

4X 80 mS Post J

25 mm/Sec. 1.0 Cm/mV




REMARKS:

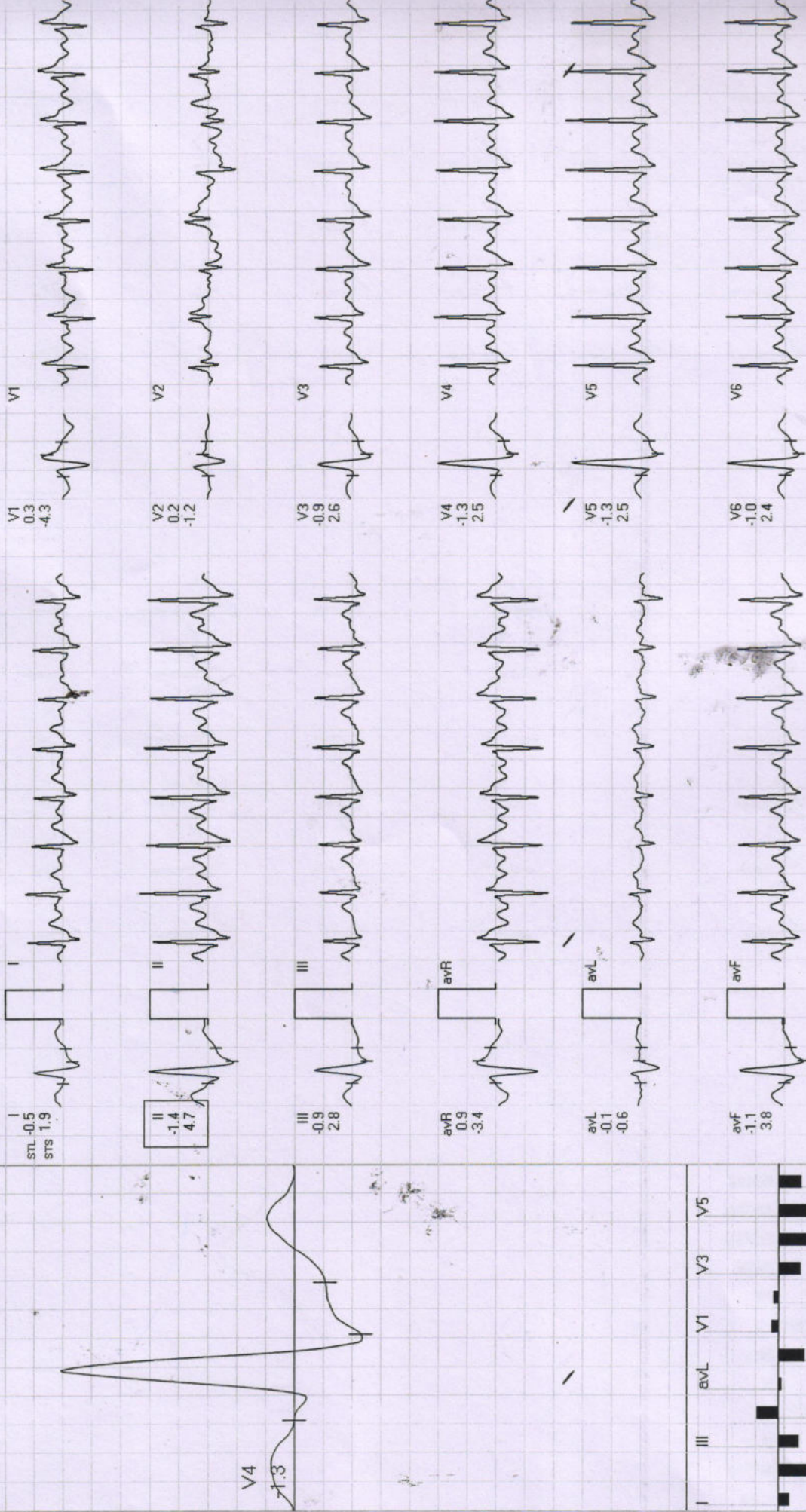


Date: 10-Dec-2022 10:50:02 AM METS: 7.1 / 132 bpm 73% of THR. BP: 130/90 mmHg Raw ECG/ BLC On/ HF 0.05 Hz/LF 20 Hz

ExTime: 06:00 2.5 mph, 12.0%



4X 60 mS Post J



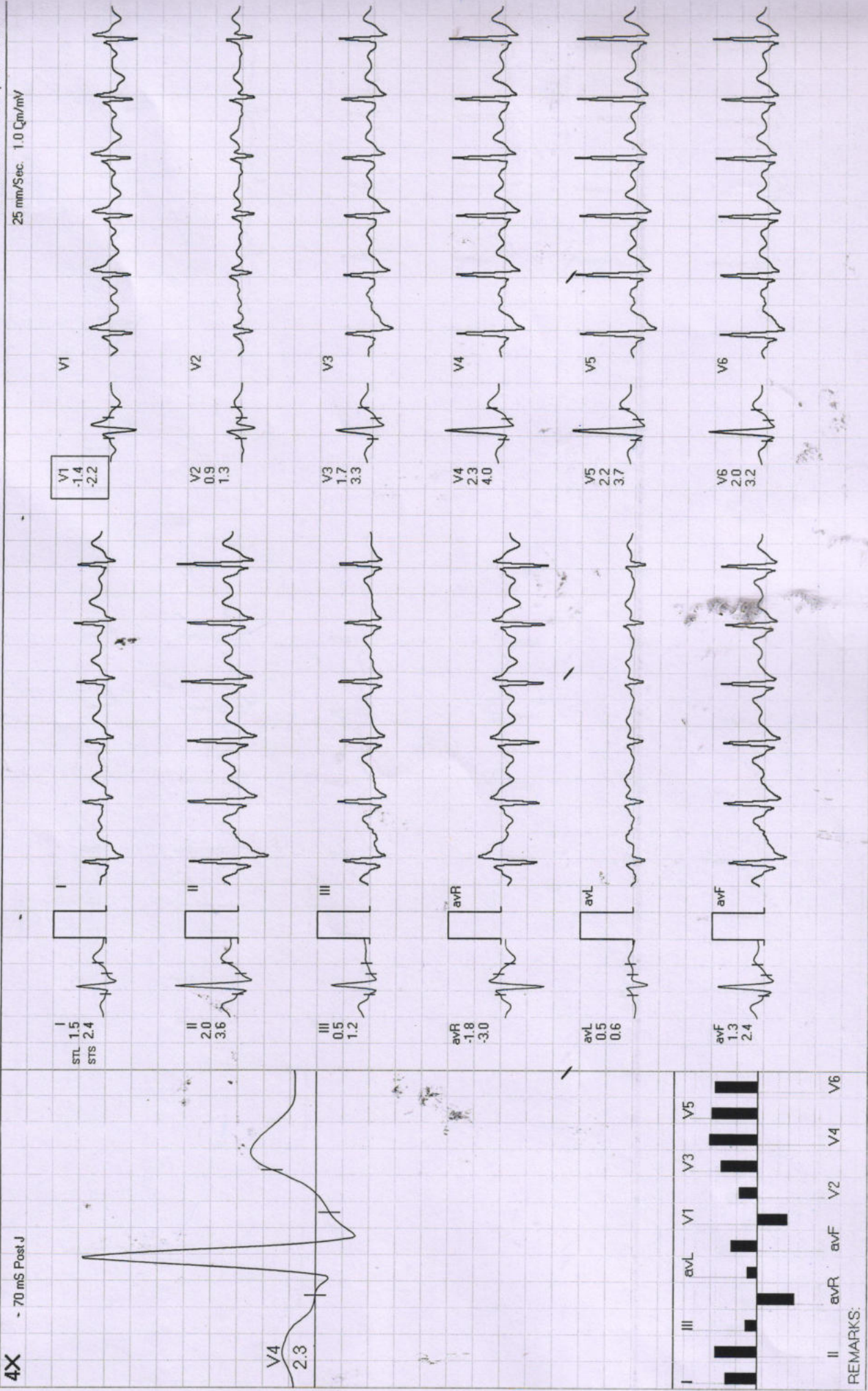
REMARKS:



Date: 10-Dec-2022 10:50:02 AM METS: 1.1/113 bpm 62% of THR BP: 126/88 mmHg Raw ECG/BLC Onr/ Natch Onr/ HF 0.05 Hz/LF 20 Hz

ExTime: 07:14 0.0 mph, 0.0%

4X - 70 mS Post J



REMARKS:

Diwakar Diagnostic Centre

900 / ANUPAM TRIVEDI / 40 Yrs / M

Recovery : (02:00)


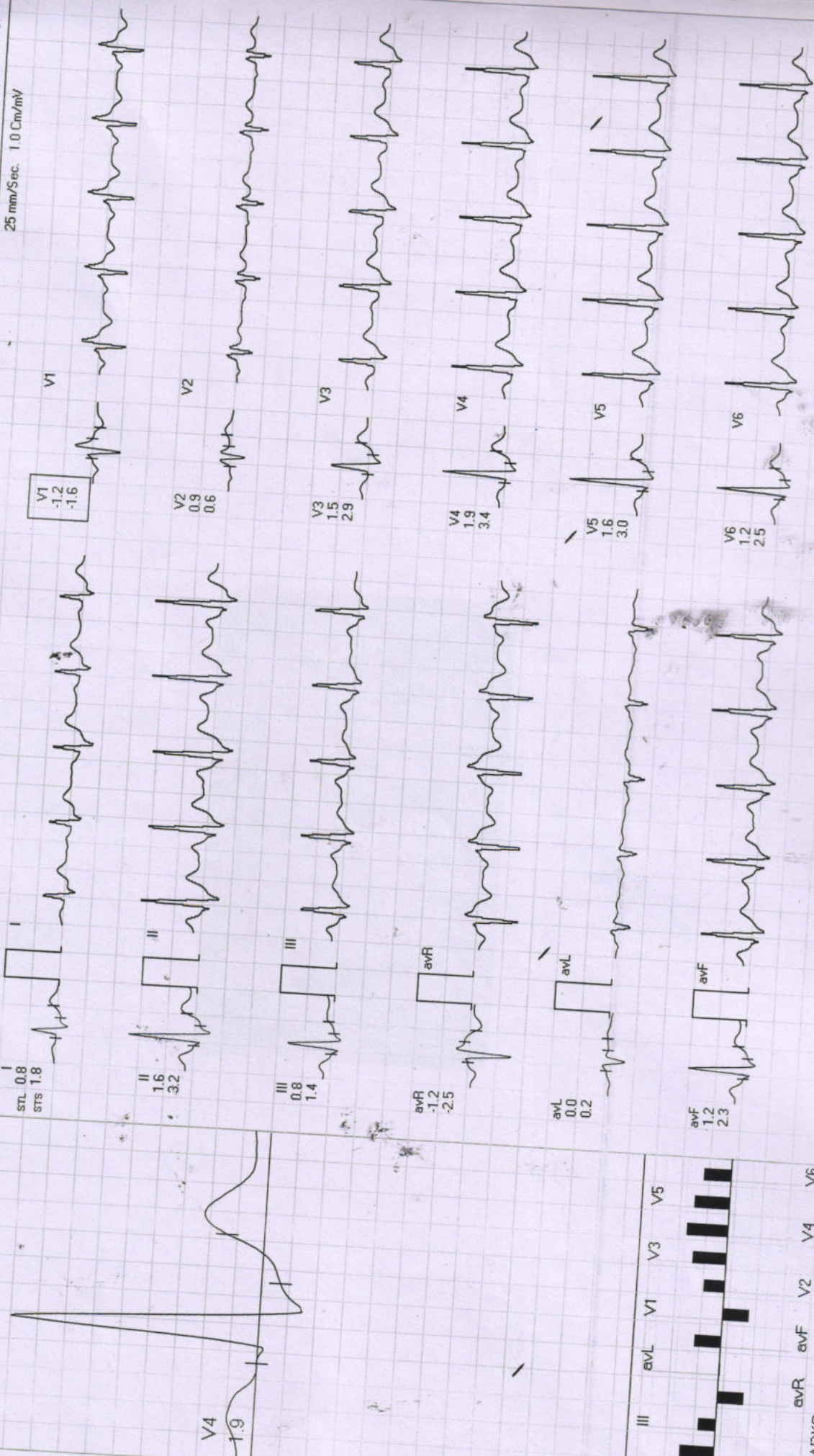


Date: 10-Dec-2022 10:50:02 AM METS: 1.0/102 bpm 56% of THR BP: 122/80 mmHg Raw ECG/BLC On/ Notch On/ HF 0.05 Hz/LF 20 Hz

ExTime: 07:14 0.0 mph, 0.0%
25 mm/Sec. 1.0 Cm/mV

4X

80 mS Post J






REMARKS:

अनुपम त्रिवेदी
Anupam Trivedi
जन्म तिथि/ DOB: 03/02/1982
पुरुष / MALE

5775 2343 4940

डॉ. अनुपम त्रिवेदी का अस्पताल



Handwritten signature in blue ink.