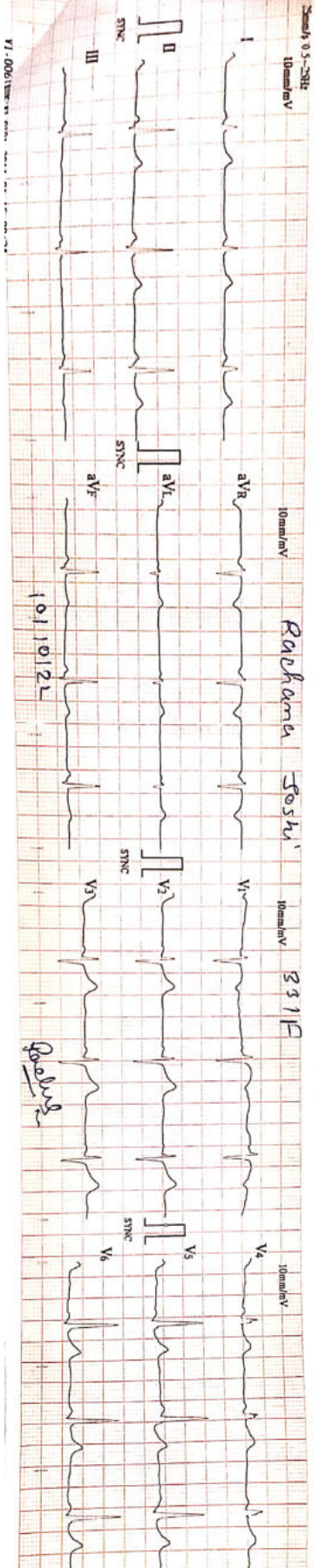

HR : 60  
 R-R : 899  
 P-R : 108  
 QRS : 86  
 QT/QTc : 367/386  
 P/QRS/T : 45/65/24  
 RS/SV1 : 1.60/0.710W  
 RS/SV1 : 1.870 AV

ID : 0007  
 Name : Rajkumar Soshi  
 Date : 10/10/22  
 Doctor : Dr. Anil Kumar  
 Department : Cardiology  
 Hospital : ...  
 Location : ...

Sinus Rhythm  
 Short P-R Interval  
 T Abnormality/Flat  
 UMW  
 Unconfirmed report  
 MD. P. S. ...  
 Associate Consultant-Cardiology  
 Reg. No. G-50510

# Heart & General Clinic

iCure Heart & Diet Clinic, 402, Epsilon tower, opp Pasha bhai park, Race course, Vadodara

## :: PERSONAL HEALTH REPORT ::

Name!- Rachana Joshi

\*DATE 10/10/2022

SR. NO.  
SEX. Female  
AGE 33 Year  
HEIGHT 146 cm  
WEIGHT 61 kg.

### HISTORY

Present History : no  
 Past Illness History : no Diabetes/Hypertension/Tuberculosis/Asthma/Epilepsy  
 Past Occupational History : no  
 Family History : no  
 Personal History : She had Caesarean for ectopic pregnancy in 2011 & C-section in 2012  
 Addiction : no Tobacco/Gutkha/Smoking/Alcohol

### GENERAL EXAMINATION

T.P.R. 71/min B.P. : 124/80 mm Hg mm Hg :

Pallor/Icterus/Cyanosis/Varicosity/Lymph Nodes/Thyroid/Oedema/NVE/Other :

### SYSTEMIC EXAMINATION

R.S. : Normal  
 C.V.S : Normal  
 C.N.S : Normal  
 A.S. : Normal  
 Musculo-skelet System : Normal

E.N.T. Ex.	<u>Normal</u>	ACUITY OF VISION		RT EYE	LT EYE
		Dental Ex.	<u>Normal</u>	Without Glass	DISTANT 6/ <u>6</u>
Skin Ex.	<u>Normal</u>		Near 6/ <u>6</u>	6/ <u>6</u>	
Psychic Ex.	<u>Normal</u>	With Glass	DISTANT 6/ <u>6</u>	6/ <u>6</u>	
			Near 6/ <u>6</u>	6/ <u>6</u>	
		COLOUR BLINDNESS <u>NAD</u>			

### REMARK

### ADVICE

The Worker is FIT for the assigned job.



Dr. Krish P. Vaidya  
 MD, PEDCC  
 Associate Consultant-Cardiology  
 Reg. No. G-50510  
 DR. KRISH VAIDYA

MD G-50510, CIH



नाम चिराग बलवंतराय जोशी  
Name CHIRAG BALAVANTRAI JOSHI

कार्यकारी .सूचक नं.  
E.C. No. 199322

जारीकर्ता प्राधिकारी  
Issuing Authority



धारक के हस्ताक्षर  
Signature Holder's



भारत सरकार  
Government of India



Issue Date : 09/08/2013



Rachana Chirag Joshi  
DOB : 26/02/1989  
Female

2950 9375 7788

मेरा आधार, मेरी पहचान

*Rachana*





# BARODA DIAGNOSTIC LABORATORY


Name : RACHANA JOSHI  
Ref By : ICURE HEART & DIET CLINIC

Age/Sex : 33 Yrs./F  
Date : 10/10/2022  
Report ID. : 4

## EXAMINATION OF URINE

TEST	RESULT	UNIT
Sample	: FASTING	
<b>PHYSICAL EXAMINATION</b>		
Quantity	: 10	mL
Colour	: PALE YELLOW	
Transparency	: CLEAR	
Specific Gravity	: 1.003	
Reaction	: ACIDIC	
Deposits	: ABSENT	
<b>CHEMICAL EXAMINATION</b>		
Albumin	: NIL	
Sugar	: NIL	
Acetone	: ABSENT	
Bile Salts	: ABSENT	
Bile Pigments	: ABSENT	
Urobilinogen	: NORMAL : ~ < 1.0 mg/dL	
Occult Blood	: ABSENT	
Nitrate	: ABSENT	
<b>MICROSCOPIC EXAMINATION</b>		
Pus Cells	: 0-1 / hpf	
RBC	: NIL	
Epithelial Cells	: NIL	
Crystals	: NIL	
Amorphous Phosphate	: NIL	
Cast	: NIL	

END OF REPORT



**Dr. Nehal Tiwari**  
(MD)  
Consultant Pathologist  
(Reg No G-54530)



302, Trivia Complex, Natubhai Circle, Race Course, Vadodara. ☎ +91 8866009950 / 7405009950 ✉ bdi95950@gmail.com

Laboratory results serve as an aid to diagnosis & should be interpreted in relation to clinical findings. Please refer back to laboratory in case of any discrepancy.



# BARODA DIAGNOSTIC LABORATORY

Name : RACHANA JOSHI  
Ref By : ICURE HEART & DIET CLINIC

Age/Sex : 33 Yrs./F  
Date : 10/10/2022  
Report ID. : 4

## HAEMOGRAM PROFILE

<u>TEST</u>	<u>RESULT</u>
Blood Group	: "O"
Rh Factor (Anti D.)	: "NEGATIVE"

## BIOCHEMISTRY

### FASTING (FBS)

Blood Glucose : 80.0 mg/dL 70.00 - 110.00 mg/dL

Done By Fully Auto Analyzer MIURA, A-1004

## Hb A1C REPORT

Hb A1C - Glycated Hb Glycated Haemoglobin	: 4.5 %	Non Diabetic : 4.3 - 6.3 % Good Control : 6.4 - 7.5 % Moderate Control : 7.5 - 9.0 % Poor Control : 9.0 % & Above
Avg. Blood Glucose Level	: 83 mg/dL	
Estimated Average Glucose eAG	: 82 mg%	

END OF REPORT



**Dr. Nehal Tiwari**  
(MD)  
Consultant Pathologist  
(Reg. No. G-54530)



302, Trivia Complex, Natubhai Circle, Race Course, Vadodara. ☎ +91 8866009950 / 7405009950 ✉ bdi95950@gmail.com

Laboratory results serve as an aid to diagnosis & should be interpreted in relation to clinical findings. Please refer back to laboratory in case of any discrepancy.

## 2D Echocardiography & Color Doppler Report

Kare Heart care, 402, Epollon tower, opp Pasha bhai park, Race course, Vadodara

**Patient Name:** Mrs Rachana Chirag Joshi

**Date:** 10 / 10 / 2022


**Age, Gender:** female - 33 Years

### M. Mode Study:

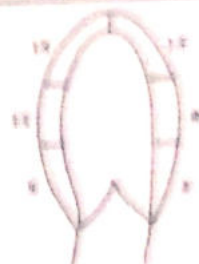
LA	35	IVS	09	PWD	09
AO	28	LVDs	26	LVDd	44

### Doppler Study:

Mitral Valve	E: 0.66 A: 0.48
Aortic Valve	Normal
Tricuspid Valve	Normal
Pulmonary Valve	Normal



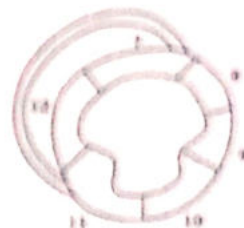Aortic  
2 chamber view



Aortic  
2 chamber view



Aortic  
2 chamber view



Parasternal short  
axis view

### Conclusion:

- Normal LV Systolic function
- LVEF: 60 % ,No RWMA
- Cardiac Chambers: Normal
- Diastolic function: Normal
- TR: Mild PAH: No , RVSP: 20 mmhg
- No Ms , No MR
- No AR , No AS
- ASD/VSD/PDA/Co-A : No
- No Clots or vegetations found
- IVC: Normal



Dr. Krish P. Vaidya  
 MD, PGCC  
 Associate Consultant-Cardiology  
 Reg. No. G-58810

### Note:

Normal 2D echo report does not rule out cardiac diseases  
 this report shall not be used for Medico legal purposes,  
 Clinical Correlation advisable.

**Dr. Krish P Vaidya**  
 Consultant Cardiologist, Diabetologist  
 & General Physician

  
**Heart & General Clinic**

iCure Heart& Diet Clinic, 402, Epsil on tower, opp Pasha bhai park, Race course, Vadodara

NAME : Mrs Rachana Chirag Joshi	AGE : 33 Y/F	DATE : 10/10/2022
---------------------------------	--------------	-------------------

**ULTRASONOGRAPHY OF WHOLE ABDOMEN**

(Screening Only)

**Liver** is normal in size and echotexture and shows normal parenchymal reflectivity. No focal lesion is seen. Hepatic veins appear normal. There is no evidence of any dilated intra hepatic biliary radicals.

**Portal Vein** appears normal in diameter.

**Common Bile Duct** is of normal diameter.

**Gallbladder** is physiologically distended with normal wall thickness. There is no evidence of gallstones. No evidence of peri-cholecystic fluid or probe tenderness.

**Pancreas** is normal in size and shows homogenous reflectivity. There is no evidence of any calcification or ductal dilatation.

**Spleen** is normal size and shows a homogenous echotexture. There is no evidence of any focal lesion.

**Both Kidneys** are normal in position and size. They show normal cortical reflectivity and cortico-medullary distinction. Right kidney measures 89x43mm. Left kidney measures 98x41mm. There is no evidence of renal calculi, hydronephrosis or mass seen.

**Bladder** is well distended and shows normal wall thickness. No evidence of intra-luminal mass or calculi.

**Uterus** appears normal in size. Uterine myometrial echotexture is homogeneous. No focal lesion is seen. CET measures 5mm.

Post Right Ovary Removal with fallopian tube

There is no evidence of ascites.

No evidence of any gross bowel mass seen.

No evidence of any aorto-caval or mesenteric root lymphadenopathy.

No mass or collection in right iliac fossa.

**CONCLUSION:** No sonographic abnormality is seen.



*Mehul Prajapati*

**DR. MEHUL PRAJAPATI  
CONSULTANT RADIOLOGIST**

# Heart & General Clinic

iCure Heart & Diet Clinic, 402, Epsil on tower, opp Pasha bhai park, Race course, Vadodara  
10/10/22

To,

Respected sir/mam

Here is to inform you that client name Rachama Joshi has come for health checkup from Bob at our center on 10/10/22 she was not willing for X-ray, PPZBS (Post prandial blood sugar level) & PEP smear tests so we have not done these three tests on her other than these all other tests have been done & reports are attached with her file so kindly consider this & do the needful for the same.



Thanking you

I cure heart & diet clinic

Dr. Krish P. Vaidya  
MD, PGDC  
Associate Consultant - Cardiology  
Reg. No. G-50510





# BARODA DIAGNOSTIC LABORATORY

302, Trivia Complex, Natubhai Circle, Race Course, Vadodra. ☎ +91 8866009950 / 7405009950 ✉ bdl95950@gmail.com



Patient's name : Rachana Joshi  
Age/Sex : 33 Years/Female  
Referred by : C/o. I Cure Heart & Diet Clinic  
Sample From : LAB  
UHID :

Reg. ID : icure-131-19  
Accession : 21499  
Reg. Date : 10/10/2022  
Collection Time : 10/10/2022 13:19

## COMPLETE BLOOD COUNT

Sample Type: EDTA

Test Name	Result	Units	Biological Reference Interval
<b><u>Blood Counts</u></b>			
Haemoglobin :	13.8	Gms%	12.5 - 16.0
Total R.B.C. :	<u>3.99</u>	mill/c.mm	4.2 - 5.4
Total W. B. C. :	6200	/cu mm	4000 - 10500
Platelet Count :	300000	/cu.mm	1,50,000 - 4,50,000
<b><u>Differential Count</u></b>			
Neutrophils :	55	%	40 - 70
Lymphocytes :	<u>43</u>	%	20 - 40
Eosinophils :	<u>00</u>	%	1 - 4
Monocytes :	02	%	2 - 6
Basophils :	00	%	0 - 01
<b><u>Blood Indices</u></b>			
P. C. V :	<u>35.0</u>	%	37 - 47
M. C. V. :	87.7	fi	78 - 100
M.C.H :	<u>34.6</u>	pg	27 - 31
M. C. H. C :	<u>39.4</u>	%	32 - 36
R.D.W :	11.6	%	11.5 - 14.0
<b><u>E.S.R.( Westergren Method )</u></b>			
After one hour :	12	mm	3 - 12



Page 1 of 2



# BARODA DIAGNOSTIC LABORATORY

302, Triva Complex, Natubhai Circle, Race Course, Vadodara. ☎ +91 8866009950 / 7405009950 📧 bdl95950@gmail.com



Patient's name : Rachana Joshi  
Age/Sex : 33 Years/Female  
Referred by : C/o. I Cure Heart & Diet Clinic  
Sample From : LAB  
UHID :

Reg. ID : icure-131-19  
Accession : 21499  
Reg. Date : 10/10/2022  
Collection Time : 10/10/2022 13:19

## LIVER FUNCTION TEST

Sample Type: Serum

Test Name	Result	Units	Biological Reference Interval
S.G.P.T (ALT) :	18	U/L	0 - 40
S.G.O.T (AST) :	12	U/L	0 - 37
ALK.PHOSPHATASE :	<u>31</u>	U/L	35 - 105
<b><u>Bilirubin</u></b>			
Total :	0.40	mg/dl	0.2 - 1.0
Direct :	0.19	mg/dl	0 - 0.6
Indirect :	0.21	mg/dl	0 - 0.5
<b><u>Serum Proteins</u></b>			
Total Protein :	6.40	gms/dl	6.4 - 8.3
Albumin :	<u>3.54</u>	gms/dl	3.8 - 4.4
Globulins :	2.86	gms/dl	2.3 - 3.5
A/G Ratio :	1.24		0.9 - 2.9

Done on Fully automated biochemistry analyser - COBAS C 111



Page 2 of 2

LAB

LAB USE ONLY (Entered by : AP Enter Date/Time 10/10/2022 15:02:00) (Verify by : OP1 Verify Date/Time 10/10/2022 15:25:00)



# BARODA DIAGNOSTIC LABORATORY

302, Triva Complex, Natubhai Circle, Race Course, Vadodara. ☎ +91 8866009950 / 7405009950 ✉ bdl95950@gmail.com



\* 2 1 5 0 0 \*

Patient's name : Rachana Joshi  
Age/Sex : 33 Years/Female  
Referred by : C/o. I Cure Heart & Diet Clinic  
Sample From : LAB  
UHID :

Reg. ID : icure-132-19  
Accession : 21500  
Reg. Date : 10/10/2022  
Collection Time : 10/10/2022 13:21

## HIV HBsAg

<u>Test</u>	<u>Result</u>	<u>Normal Range</u>
Test for HIV 1 Antibodies :	Non reactive	Non reactive
Test for HIV 2 Antibodies :	Non reactive	Non reactive
HBsAg : (Hepatitis B surface Antigen)	Negative	Negative

Note: The above tests are done as a screening procedure.  
: If clinically suspected, confirmation by ELISA is recommended.  
: Rarely false negativity/positivity may occur.



LAB  
LAB USE ONLY (Entered by :AP Enter Date/Time:10/10/2022 14:51:00) (Verify by :OP1 Verify Date/Time:10/10/2022 15:29:00)



# BARODA DIAGNOSTIC LABORATORY

302, Triva Complex, Natubhai Circle, Race Course, Vadodara. ☎ +91 8866009950 / 7405009950 📧 bdl95950@gmail.com



Patient's name : Rachana Joshi  
Age/Sex : 33 Years/Female  
Referred by : C/o. I Cure Heart & Diet Clinic  
Sample From : LAB  
UHID :

Reg. ID : icurc-132-19  
Accession : 21500  
Reg. Date : 10/10/2022  
Collection Time : 10/10/2022 13:21

## RENAL FUNCTION TEST

Test Name	Result	Units	Biological Reference Interval
Urea :	23	mg/dl	10 - 50
Bun (Calculated) :	10.7	mg/dl	0 - 18
Creatinine :	0.72	mg/dl	0.4 - 1.5
Uricacid :	4.83	mg/dl	3.4 - 7.0
BUN CREAT RATIO :			10:1 - 20:1

Done on Fully automated biochemistry analyser - COBAS C 111



LAB  
LAB USE ONLY (Entered by :AP Enter Date/Time:10/10/2022 14:51:00) (Verify by :OP1 Verify Date/Time:10/10/2022 15:29:00)



# BARODA DIAGNOSTIC LABORATORY

302, Trivia Complex, Natubhai Circle, Race Course, Vadodara. ☎ +91 8866009950 / 7405009950 📧 bdl95950@gmail.com



Patient's name : Rachana Joshi  
Age/Sex : 33 Years/Female  
Referred by : C/o. I Cure Heart & Diet Clinic  
Sample From : LAB  
UHID :

Reg. ID : icure-132-19  
Accession : 21500  
Reg. Date : 10/10/2022  
Collection Time : 10/10/2022 13:21

## LIVER FUNCTION TEST

Sample Type: Serum

Test Name	Result	Units	Biological Reference Interval
G.G.T :	14.6	U/L	8 - 78

Done on Fully automated biochemistry analyser - COBAS C 111



LAB  
LAB USE ONLY (Entered by :AP Enter Date/Time:10/10/2022 14:51:00) (Verify by :OP1 Verify Date/Time:10/10/2022 15:29:00)



# BARODA DIAGNOSTIC LABORATORY

302, Triva Complex, Natubhai Circle, Race Course, Vadodara. ☎ +91 8866009950 / 7405009950 ✉ bdl95950@gmail.com



\* 2 1 5 0 0 \*

Patient's name : Rachana Joshi  
Age/Sex : 33 Years/Female  
Referred by : C/o. I Cure Heart & Diet Clinic  
Sample From : LAB  
UHID :

Reg. ID : icure-132-19  
Accession : 21500  
Reg. Date : 10/10/2022  
Collection Time : 10/10/2022 13:21

## LIPID PROFILE

Sample Type: Serum

Test Name	Result	Units	Biological Reference Interval
Cholesterol :	120	mg/dl	0 - 200
Triglyceride :	106	mg/dL	0 - 150
HDL - Cholesterol :	42	mg/dL	35 - 65
LDL - Cholesterol :	56.8	mg/dL	0 - 130
VLDL - Cholesterol :	21.2	mg/dL	0 - 30
Total Cholesterol/HDL Ratio :	2.86		1 - 6
LDL / HDL Cholesterol Ratio :	1.35		0 - 3.5

Done on Fully automated biochemistry analyser - COBAS C 111



LAB

LAB USE ONLY (Entered by :AP Enter Date/Time:10/10/2022 14:51:00) (Verify by :OP1 Verify Date/Time:10/10/2022 15:29:00)



# BARODA DIAGNOSTIC LABORATORY

302, Triva Complex, Natubhai Circle, Race Course, Vadodara. ☎ +91 8866009950 / 7405009950 ✉ bdi95950@gmail.com



• 2 1 5 0 0 •

Patient's name : Rachana Joshi  
Age/Sex : 33 Years/Female  
Referred by : C/o. I Cure Heart & Diet Clinic  
Sample From : LAB  
UHID :  
Reg. ID : icure-132-19  
Accession : 21500  
Reg. Date : 10/10/2022  
Collection Time : 10/10/2022 13:21

## THYROID FUNCTION

Sample Type: Serum

Test Name	Result	Units	Biological Reference Interval
TOTAL T3 :	1.01	ng/ml	0.84 - 2.0
TOTAL T4 :	6.30	ug/dl	5.1 - 14.0
TSH :	2.10	mIU/L	0.25 - 5.0

Method : CLIA



LAB  
LAB USE ONLY (Entered by :AP Enter Date/Time:10/10/2022 14:51:00) (Verify by :OP1 Verify Date/Time:10/10/2022 15:29:00)