



CID : 2432507854
Name : MRS.ARTI SHINDE
Age / Gender : 43 Years / Female
Consulting Dr. : -
Reg. Location : Borivali West (Main Centre)

Collected : 20-Nov-2024 / 09:29
Reported : 20-Nov-2024 / 14:06

Use a QR Code Scanner
Application To Scan the Code

MEDIWHEEL FULL BODY HEALTH CHECKUP FEMALE ABOVE 40/2D ECHO

CBC (Complete Blood Count), Blood

<u>PARAMETER</u>	<u>RESULTS</u>	<u>BIOLOGICAL REF RANGE</u>	<u>METHOD</u>
<u>RBC PARAMETERS</u>			
Haemoglobin	12.9	12.0-15.0 g/dL	Spectrophotometric
RBC	4.32	3.8-4.8 mil/cmm	Elect. Impedance
PCV	36.9	36-46 %	Measured
MCV	86	80-100 fl	Calculated
MCH	29.8	27-32 pg	Calculated
MCHC	34.9	31.5-34.5 g/dL	Calculated
RDW	14.1	11.6-14.0 %	Calculated
<u>WBC PARAMETERS</u>			
WBC Total Count	8970	4000-10000 /cmm	Elect. Impedance
<u>WBC DIFFERENTIAL AND ABSOLUTE COUNTS</u>			
Lymphocytes	36.5	20-40 %	
Absolute Lymphocytes	3260.0	1000-3000 /cmm	Calculated
Monocytes	6.5	2-10 %	
Absolute Monocytes	580.0	200-1000 /cmm	Calculated
Neutrophils	53.2	40-80 %	
Absolute Neutrophils	4760.0	2000-7000 /cmm	Calculated
Eosinophils	3.2	1-6 %	
Absolute Eosinophils	280.0	20-500 /cmm	Calculated
Basophils	0.6	0.1-2 %	
Absolute Basophils	50.0	20-100 /cmm	Calculated
Immature Leukocytes	-		
WBC Differential Count by Absorbance & Impedance method/Microscopy.			
<u>PLATELET PARAMETERS</u>			
Platelet Count	343000	150000-400000 /cmm	Elect. Impedance
MPV	7.7	6-11 fl	Calculated
PDW	12.9	11-18 %	Calculated
<u>RBC MORPHOLOGY</u>			
Hypochromia	-		
Microcytosis	-		



Use a QR Code Scanner
Application To Scan the Code

CID : 2432507854
Name : MRS.ARTI SHINDE
Age / Gender : 43 Years / Female
Consulting Dr. : -
Reg. Location : Borivali West (Main Centre)

Collected : 20-Nov-2024 / 12:25
Reported : 20-Nov-2024 / 14:56

MEDIWHEEL FULL BODY HEALTH CHECKUP FEMALE ABOVE 40/2D ECHO

<u>PARAMETER</u>	<u>RESULTS</u>	<u>BIOLOGICAL REF RANGE</u>	<u>METHOD</u>
GLUCOSE (SUGAR) FASTING, Fluoride Plasma Fasting	151.4	Non-Diabetic: < 100 mg/dl Impaired Fasting Glucose: 100-125 mg/dl Diabetic: >/= 126 mg/dl	Hexokinase

Note: ADA recommendations, AACC, Wallach's interpretation of diagnostic tests 10th edition.

GLUCOSE (SUGAR) PP, Fluoride Plasma PP	181.4	Non-Diabetic: < 140 mg/dl Impaired Glucose Tolerance: 140-199 mg/dl Diabetic: >/= 200 mg/dl	Hexokinase
----------------------------------------	-------	---------------------------------------------------------------------------------------------------	------------

Note: ADA recommendations, AACC, Wallach's interpretation of diagnostic tests 10th edition.

*Sample processed at SUBURBAN DIAGNOSTICS (INDIA) PVT. LTD Borivali Lab, Borivali West
*** End Of Report ***



Bmhasakar

Dr.KETAKI MHASKAR
M.D. (PATH)
Pathologist



CID : 2432507854
Name : MRS.ARTI SHINDE
Age / Gender : 43 Years / Female
Consulting Dr. : -
Reg. Location : Borivali West (Main Centre)

Collected : 20-Nov-2024 / 09:29
Reported : 20-Nov-2024 / 16:17

Use a QR Code Scanner
Application To Scan the Code

**MEDIWHEEL FULL BODY HEALTH CHECKUP FEMALE ABOVE 40/2D ECHO
KIDNEY FUNCTION TESTS**

PARAMETER	RESULTS	BIOLOGICAL REF RANGE	METHOD
BLOOD UREA, Serum	19.5	12.8-42.8 mg/dl	Kinetic
BUN, Serum	9.1	6-20 mg/dl	Calculated
CREATININE, Serum	0.59	0.51-0.95 mg/dl	Enzymatic
eGFR, Serum	115	(ml/min/1.73sqm) Normal or High: Above 90 Mild decrease: 60-89 Mild to moderate decrease: 45-59 Moderate to severe decrease: 30-44 Severe decrease: 15-29 Kidney failure: <15	Calculated

Note: eGFR estimation is calculated using 2021 CKD-EPI GFR equation

TOTAL PROTEINS, Serum	7.1	6.4-8.3 g/dL	Biuret
ALBUMIN, Serum	3.7	3.5-5.2 g/dL	BCG
GLOBULIN, Serum	3.4	2.3-3.5 g/dL	Calculated
A/G RATIO, Serum	1.1	1 - 2	Calculated
URIC ACID, Serum	5.3	2.4-5.7 mg/dl	Enzymatic
PHOSPHORUS, Serum	2.7	2.7-4.5 mg/dl	Molybdate UV
CALCIUM, Serum	9.2	8.6-10.0 mg/dl	N-BAPTA
SODIUM, Serum	137	135-148 mmol/l	ISE
POTASSIUM, Serum	4.0	3.5-5.3 mmol/l	ISE
CHLORIDE, Serum	101	98-107 mmol/l	ISE

*Sample processed at SUBURBAN DIAGNOSTICS (INDIA) PVT. LTD Borivali Lab, Borivali West
*** End Of Report ***



M Jain

Dr.MILLU JAIN
M.D.(PATH)
Pathologist



CID : 2432507854
Name : MRS.ARTI SHINDE
Age / Gender : 43 Years / Female
Consulting Dr. : -
Reg. Location : Borivali West (Main Centre)

Collected : 20-Nov-2024 / 09:29
Reported : 20-Nov-2024 / 16:00

Use a QR Code Scanner
Application To Scan the Code

MEDIWHEEL FULL BODY HEALTH CHECKUP FEMALE ABOVE 40/2D ECHO
GLYCOSYLATED HEMOGLOBIN (HbA1c)

PARAMETER	RESULTS	BIOLOGICAL REF RANGE	METHOD
Glycosylated Hemoglobin (HbA1c), EDTA WB - CC	6.8	Non-Diabetic Level: < 5.7 % Prediabetic Level: 5.7-6.4 % Diabetic Level: >/= 6.5 %	HPLC
Estimated Average Glucose (eAG), EDTA WB - CC	148.5	mg/dl	Calculated

Intended use:

- In patients who are meeting treatment goals, HbA1c test should be performed at least 2 times a year
- In patients whose therapy has changed or who are not meeting glycemic goals, it should be performed quarterly
- For microvascular disease prevention, the HbA1C goal for non pregnant adults in general is Less than 7%.

Clinical Significance:

- HbA1c, Glycosylated hemoglobin or glycated hemoglobin, is hemoglobin with glucose molecule attached to it.
- The HbA1c test evaluates the average amount of glucose in the blood over the last 2 to 3 months by measuring the percentage of glycosylated hemoglobin in the blood.

Test Interpretation:

- The HbA1c test evaluates the average amount of glucose in the blood over the last 2 to 3 months by measuring the percentage of Glycosylated hemoglobin in the blood.
- HbA1c test may be used to screen for and diagnose diabetes or risk of developing diabetes.
- To monitor compliance and long term blood glucose level control in patients with diabetes.
- Index of diabetic control, predicting development and progression of diabetic micro vascular complications.

Factors affecting HbA1c results:

Increased in: High fetal hemoglobin, Chronic renal failure, Iron deficiency anemia, Splenectomy, Increased serum triglycerides, Alcohol ingestion, Lead/opiate poisoning and Salicylate treatment.

Decreased in: Shortened RBC lifespan (Hemolytic anemia, blood loss), following transfusions, pregnancy, ingestion of large amount of Vitamin E or Vitamin C and Hemoglobinopathies

Reflex tests: Blood glucose levels, CGM (Continuous Glucose monitoring)

References: ADA recommendations, AACC, Wallach's interpretation of diagnostic tests 10th edition.

*Sample processed at SUBURBAN DIAGNOSTICS (INDIA) PVT. LTD Borivali Lab, Borivali West

*** End Of Report ***



J Thakker

Dr. JYOT THAKKER..
M.D. (PATH), DPB
Pathologist & AVP(Medical Services)



CID : 2432507854
Name : MRS.ARTI SHINDE
Age / Gender : 43 Years / Female
Consulting Dr. : -
Reg. Location : Borivali West (Main Centre)

Collected : 20-Nov-2024 / 12:40
Reported : 20-Nov-2024 / 15:10

Use a QR Code Scanner
Application To Scan the Code

MEDIWHEEL FULL BODY HEALTH CHECKUP FEMALE ABOVE 40/2D ECHO
URINE EXAMINATION REPORT

<u>PARAMETER</u>	<u>RESULTS</u>	<u>BIOLOGICAL REF RANGE</u>	<u>METHOD</u>
<u>PHYSICAL EXAMINATION</u>			
Color	Pale yellow	Pale Yellow	-
Transparency	Clear	Clear	-
<u>CHEMICAL EXAMINATION</u>			
Specific Gravity	1.005	1.002-1.035	Chemical Indicator
Reaction (pH)	7.0	5-8	pH Indicator
Proteins	Absent	Absent	Protein error principle
Glucose	Absent	Absent	GOD-POD
Ketones	Absent	Absent	Legals Test
Blood	Absent	Absent	Peroxidase
Bilirubin	Absent	Absent	Diazonium Salt
Urobilinogen	Normal	Normal	Diazonium Salt
Nitrite	Absent	Absent	Griess Test
<u>MICROSCOPIC EXAMINATION</u>			
(WBC)Pus cells / hpf	2-3	0-5/hpf	
Red Blood Cells / hpf	Absent	0-2/hpf	
Epithelial Cells / hpf	1-2	0-5/hpf	
Hyaline Casts	Absent	Absent	
Pathological cast	Absent	Absent	
Calcium oxalate monohydrate crystals	Absent	Absent	
Calcium oxalate dihydrate crystals	Absent	Absent	
Triple phosphate crystals	Absent	Absent	
Uric acid crystals	Absent	Absent	
Amorphous debris	Absent	Absent	
Bacteria / hpf	+(>20/hpf)	0-20/hpf	
Yeast	Absent	Absent	
Others	-		



Use a QR Code Scanner
Application To Scan the Code

CID : 2432507854
Name : MRS.ARTI SHINDE
Age / Gender : 43 Years / Female
Consulting Dr. : -
Reg. Location : Borivali West (Main Centre)

Collected : 20-Nov-2024 / 12:40
Reported : 20-Nov-2024 / 15:10

*Sample processed at SUBURBAN DIAGNOSTICS (INDIA) PVT. LTD Borivali Lab, Borivali West
*** End Of Report ***



J Thakker

Dr.JYOT THAKKER..
M.D. (PATH), DPB
Pathologist & AVP(Medical Services)



Use a QR Code Scanner
Application To Scan the Code

CID : 2432507854
Name : MRS.ARTI SHINDE
Age / Gender : 43 Years / Female
Consulting Dr. : -
Reg. Location : Borivali West (Main Centre)

Collected : 20-Nov-2024 / 09:29
Reported : 20-Nov-2024 / 13:06

MEDIWHEEL FULL BODY HEALTH CHECKUP FEMALE ABOVE 40/2D ECHO
BLOOD GROUPING & Rh TYPING

<u>PARAMETER</u>	<u>RESULTS</u>
ABO GROUP	A
Rh TYPING	Positive

NOTE: Test performed by automated Erythrocytes magnetized technology (EMT) which is more sensitive than conventional methods.

Specimen: EDTA Whole Blood and/or serum

Clinical significance:

ABO system is most important of all blood group in transfusion medicine

Limitations:

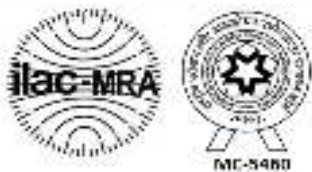- ABO blood group of new born is performed only by cell (forward) grouping because allo antibodies in cord blood are of maternal origin.
- Since A & B antigens are not fully developed at birth, both Anti-A & Anti-B antibodies appear after the first 4 to 6 months of life. As a result, weaker reactions may occur with red cells of newborns than of adults.
- Confirmation of newborn's blood group is indicated when A & B antigen expression and the isoagglutinins are fully developed at 2 to 4 years of age & remains constant throughout life.
- Cord blood is contaminated with Wharton's jelly that causes red cell aggregation leading to false positive result
- The Hh blood group also known as Oh or Bombay blood group is rare blood group type. The term Bombay is used to refer the phenotype that lacks normal expression of ABH antigens because of inheritance of hh genotype.

References:

1. Denise M Harmening, Modern Blood Banking and Transfusion Practices- 6th Edition 2012. F.A. Davis company. Philadelphia
2. AABB technical manual

*Sample processed at SUBURBAN DIAGNOSTICS (INDIA) PVT. LTD SDRL, Vidyavihar Lab

*** End Of Report ***



Anupa

Dr.ANUPA DIXIT
M.D.(PATH)
Consultant Pathologist



CID : 2432507854
Name : MRS.ARTI SHINDE
Age / Gender : 43 Years / Female
Consulting Dr. : -
Reg. Location : Borivali West (Main Centre)

Use a QR Code Scanner Application To Scan the Code
Collected : 20-Nov-2024 / 09:29
Reported : 20-Nov-2024 / 18:41

MEDIWHEEL FULL BODY HEALTH CHECKUP FEMALE ABOVE 40/2D ECHO
LIPID PROFILE

PARAMETER	RESULTS	BIOLOGICAL REF RANGE	METHOD
CHOLESTEROL, Serum	217.0	Desirable: <200 mg/dl Borderline High: 200-239mg/dl High: >/=240 mg/dl	CHOD-POD
TRIGLYCERIDES, Serum	477.0	Normal: <150 mg/dl Borderline-high: 150 - 199 mg/dl High: 200 - 499 mg/dl Very high:>/=500 mg/dl	GPO-POD
HDL CHOLESTEROL, Serum	33.1	Desirable: >60 mg/dl Borderline: 40 - 60 mg/dl Low (High risk): <40 mg/dl	Homogeneous enzymatic colorimetric assay
NON HDL CHOLESTEROL, Serum	183.9	Desirable: <130 mg/dl Borderline-high:130 - 159 mg/dl High:160 - 189 mg/dl Very high: >/=190 mg/dl	Calculated
LDL CHOLESTEROL, Serum	109.6	Optimal: <100 mg/dl Near Optimal: 100 - 129 mg/dl Borderline High: 130 - 159 mg/dl High: 160 - 189 mg/dl Very High: >/= 190 mg/dl	Calculated
VLDL CHOLESTEROL, Serum	74.3	< /= 30 mg/dl	Calculated
CHOL / HDL CHOL RATIO, Serum	6.6	0-4.5 Ratio	Calculated
LDL CHOL / HDL CHOL RATIO, Serum	3.3	0-3.5 Ratio	Calculated

Note : LDL test is performed by direct measurement.

Reference:

- Executive Summary of the Third Report of the National Cholesterol Education Program (NCEP) Expert Panel on Detection, Evaluation, and Treatment of High Blood Cholesterol in Adults (Adult Treatment Panel III).
- Pack Insert.

*Sample processed at SUBURBAN DIAGNOSTICS (INDIA) PVT. LTD Borivali Lab, Borivali West
*** End Of Report ***



M Jain

Dr.MILLU JAIN
M.D.(PATH)
Pathologist



Use a QR Code Scanner
Application To Scan the Code

CID : 2432507854
Name : MRS.ARTI SHINDE
Age / Gender : 43 Years / Female
Consulting Dr. : -
Reg. Location : Borivali West (Main Centre)

Collected : 20-Nov-2024 / 09:29
Reported : 20-Nov-2024 / 15:48

MEDIWHEEL FULL BODY HEALTH CHECKUP FEMALE ABOVE 40/2D ECHO
THYROID FUNCTION TESTS

<u>PARAMETER</u>	<u>RESULTS</u>	<u>BIOLOGICAL REF RANGE</u>	<u>METHOD</u>
Free T3, Serum	5.3	3.5-6.5 pmol/L	ECLIA
Free T4, Serum	14.8	11.5-22.7 pmol/L First Trimester:9.0-24.7 Second Trimester:6.4-20.59 Third Trimester:6.4-20.59	ECLIA
sensitiveTSH, Serum	2.21	0.35-5.5 microU/ml First Trimester:0.1-2.5 Second Trimester:0.2-3.0 Third Trimester:0.3-3.0 microU/ml	ECLIA



Use a QR Code Scanner
Application To Scan the Code

CID : 2432507854
Name : MRS.ARTI SHINDE
Age / Gender : 43 Years / Female
Consulting Dr. : -
Reg. Location : Borivali West (Main Centre)

Collected : 20-Nov-2024 / 09:29
Reported : 20-Nov-2024 / 15:48

Interpretation:

A thyroid panel is used to evaluate thyroid function and/or help diagnose various thyroid disorders.

Clinical Significance:

- 1)TSH Values between high abnormal upto15 microIU/ml should be correlated clinically or repeat the test with new sample as physiological factors can give falsely high TSH.
- 2)TSH values may be trasiently altered becuae of non thyroidal illness like severe infections,liver disease, renal and heart severe burns, trauma and surgery etc.

TSH	FT4 / T4	FT3 / T3	Interpretation
High	Normal	Normal	Subclinical hypothyroidism, poor compliance with thyroxine, drugs like amiodarone, Recovery phase of non-thyroidal illness, TSH Resistance.
High	Low	Low	Hypothyroidism, Autoimmune thyroiditis, post radio iodine Rx, post thyroidectomy, Anti thyroid drugs, tyrosine kinase inhibitors & amiodarone, amyloid deposits in thyroid, thyroid tumors & congenital hypothyroidism.
Low	High	High	Hyperthyroidism, Graves disease, toxic multinodular goiter, toxic adenoma, excess iodine or thyroxine intake, pregnancy related (hyperemesis gravidarum, hydatiform mole)
Low	Normal	Normal	Subclinical Hyperthyroidism, recent Rx for Hyperthyroidism, drugs like steroids & dopamine), Non thyroidal illness.
Low	Low	Low	Central Hypothyroidism, Non Thyroidal Illness, Recent Rx for Hyperthyroidism.
High	High	High	Interfering anti TPO antibodies, Drug interference: Amiodarone, Heparin, Beta Blockers, steroids & anti epileptics.

Diurnal Variation:TSH follows a diurnal rhythm and is at maximum between 2 am and 4 am , and is at a minimum between 6 pm and 10 pm. The variation is on the order of 50 to 206%. Biological variation:19.7%(with in subject variation)

Reflex Tests:Anti thyroid Antibodies,USG Thyroid ,TSH receptor Antibody. Thyroglobulin, Calcitonin

Limitations:

1. Samples should not be taken from patients receiving therapy with high biotin doses (i.e. >5 mg/day) until atleast 8 hours following the last biotin administration.
2. Patient samples may contain heterophilic antibodies that could react in immunoassays to give falsely elevated or depressed results. this assay is designed to minimize interference from heterophilic antibodies.

Reference:

- 1.O.koulouri et al. / Best Practice and Research clinical Endocrinology and Metabolism 27(2013)
- 2.Interpretation of the thyroid function tests, Dayan et al. THE LANCET . Vol 357
- 3.Tietz ,Text Book of Clinical Chemistry and Molecular Biology -5th Edition
- 4.Biological Variation:From principles to Practice-Callum G Fraser (AACC Press)

*Sample processed at SUBURBAN DIAGNOSTICS (INDIA) PVT. LTD Borivali Lab, Borivali West
*** End Of Report ***



Bmhasakar

Dr.KETAKI MHASKAR
M.D. (PATH)
Pathologist



CID : 2432507854
Name : MRS.ARTI SHINDE
Age / Gender : 43 Years / Female
Consulting Dr. : -
Reg. Location : Borivali West (Main Centre)

Collected : 20-Nov-2024 / 09:29
Reported : 20-Nov-2024 / 15:48

Use a QR Code Scanner
Application To Scan the Code

MEDIWHEEL FULL BODY HEALTH CHECKUP FEMALE ABOVE 40/2D ECHO
LIVER FUNCTION TESTS

<u>PARAMETER</u>	<u>RESULTS</u>	<u>BIOLOGICAL REF RANGE</u>	<u>METHOD</u>
BILIRUBIN (TOTAL), Serum	0.35	0.1-1.2 mg/dl	Colorimetric
BILIRUBIN (DIRECT), Serum	0.15	0-0.3 mg/dl	Diazo
BILIRUBIN (INDIRECT), Serum	0.20	0.1-1.0 mg/dl	Calculated
TOTAL PROTEINS, Serum	7.1	6.4-8.3 g/dL	Biuret
ALBUMIN, Serum	3.7	3.5-5.2 g/dL	BCG
GLOBULIN, Serum	3.4	2.3-3.5 g/dL	Calculated
A/G RATIO, Serum	1.1	1 - 2	Calculated
SGOT (AST), Serum	19.6	5-32 U/L	NADH (w/o P-5-P)
SGPT (ALT), Serum	16.4	5-33 U/L	NADH (w/o P-5-P)
GAMMA GT, Serum	14.8	3-40 U/L	Enzymatic
ALKALINE PHOSPHATASE, Serum	79.3	35-105 U/L	Colorimetric

*Sample processed at SUBURBAN DIAGNOSTICS (INDIA) PVT. LTD Borivali Lab, Borivali West
*** End Of Report ***



Bmhasakar

Dr.KETAKI MHASKAR
M.D. (PATH)
Pathologist

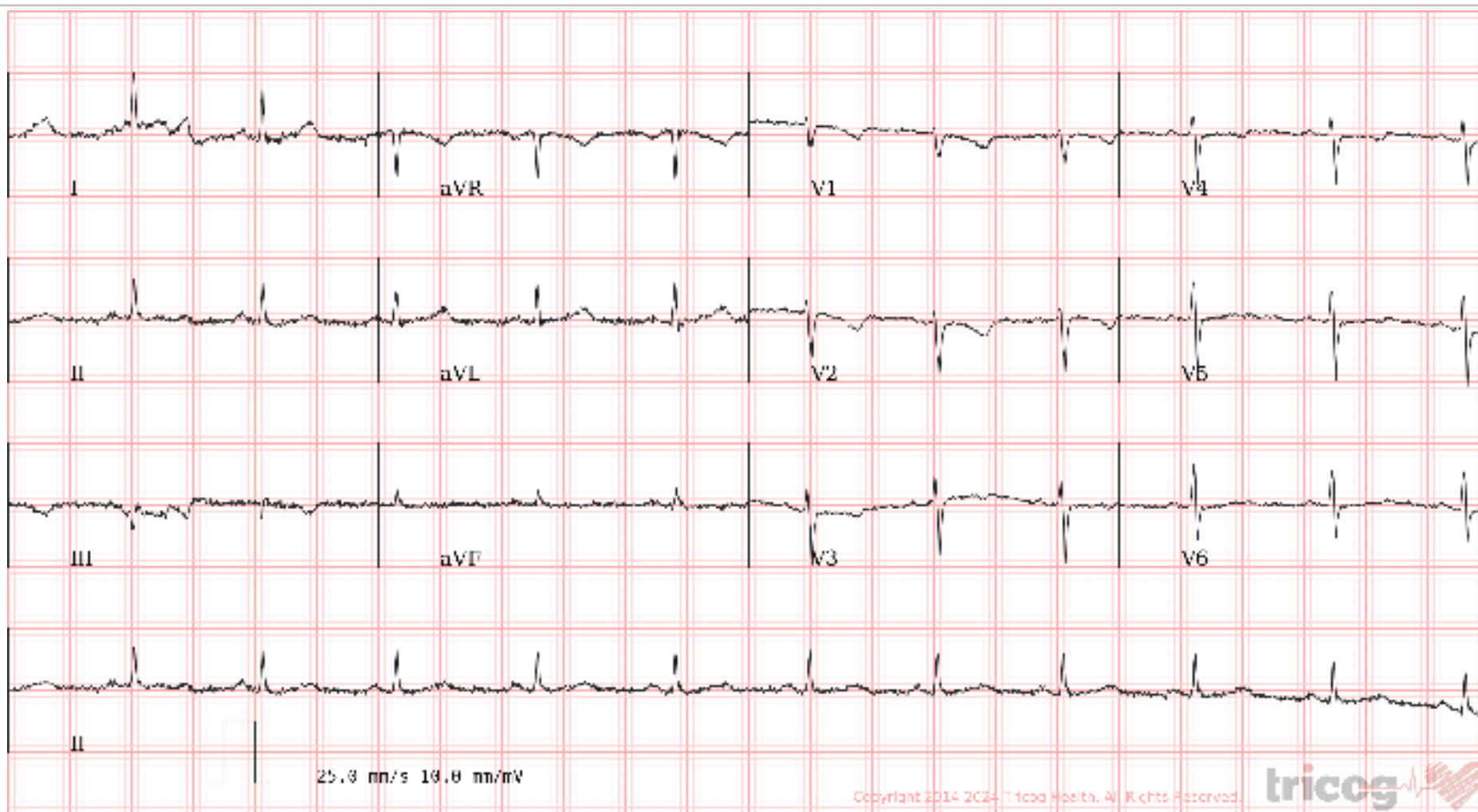
SUBURBAN DIAGNOSTICS - BORIVALI WEST



Patient Name: ARTI SHINDE

Date and Time: 20th Nov 24 9:05 AM

Patient ID: 177807327375



Age **43** NA NA
years months days

Gender **Male**

Heart Rate **70bpm**

Patient Vitals

BP: 130/80 mmHg

Weight: 81 kg

Height: 162 cm

Pulse: NA

Spo2: NA

Resp: NA

Others: _____

Measurements

QRSD: 78ms

QT: 432ms

QTcB: 466ms

PR: 156ms

P-R-T: 37° 18° NA

ECG Within Normal Limits: Sinus Rhythm. Please correlate clinically.

REPORTED BY

Dr Nitin Sonavane
M.B.B.S.AFLH, D.DIAB, D.CARD
Consultant Cardiologist
87714

CID : 2432507854
Name : Mrs ARTI SHINDE
Age / Sex : 43 Years/Female
Ref. Dr :
Reg. Location : Borivali West
Reg. Date : 20-Nov-2024
Reported : 20-Nov-2024 / 16:21

X-RAY CHEST PA VIEW

Both lung fields are clear.
Both costo-phrenic angles are clear.
The cardiac size and shape are within normal limits.
The domes of diaphragm are normal in position and outlines.
The skeleton under review appears normal.

IMPRESSION:

NO SIGNIFICANT ABNORMALITY IS DETECTED.

Kindly correlate clinically.

Note: Investigations have their limitations. Solitary radiological investigations never confirm the final diagnosis. They only help in diagnosing the disease in correlation to clinical symptoms and other related tests. X ray is known to have inter-observer variations. Further / follow-up imaging may be needed in some cases for confirmation / exclusion of diagnosis. Please interpret accordingly. In case of any typographical error / spelling error in the report, patient is requested to immediately contact the centre within 7 days post which the center will not be responsible for any rectification.

-----End of Report-----

Pranali

Dr. Pranali Mahale
MD, Radiodiagnosis
Consultant Radiologist
Reg no. 2019/07/5682

[Click here to view images <<ImageLink>>](#)

CID NO: 2432507854	AGE: 49YRS	SEX: F
NAME: MRS. ARTI SHINDE	DATE: 20/11/2024	
REF. BY : ----		

USG WHOLE ABDOMEN

LIVER: Liver is enlarged in size 16.2 cm, with mild generalized increase in parenchymal echotexture. There is no intra-hepatic biliary radical dilatation. No evidence of any focal lesion.

GALL BLADDER: Gall bladder is minimally distended.

(Tiny polyps/calculi may be missed due to technical limitations, sub-optimal distension of GB, adjacent gases and inter-machine variability in resolution settings)

PORTAL VEIN: Portal vein is normal. **CBD:** CBD is normal.

PANCREAS: Pancreas obscured due to bowel gases.

KIDNEYS: Right kidney measures 11.2 x 5.4 cm. Left kidney measures 10.2 x 5.4 cm. Both kidneys are normal in shape and echotexture. Corticomedullary differentiation is maintained. There is no evidence of any hydronephrosis, hydroureter or calculus.

SPLEEN: Spleen is normal in size, shape and echotexture. No focal lesion is seen.

URINARY BLADDER: Urinary bladder is distended and normal. Wall thickness is within normal limits.

UTERUS: Uterus is retroflexed, normal and measures 7.7 x 4.0 x 4.7 cm. Uterine myometrium shows homogenous echotexture. Endometrium is normal in thickness and measures 3.9 mm. Cervix appears normal.

OVARIES: Both ovaries appear normal in size and echotexture.
The right ovary measures 2.0 x 1.0 x 2.2 cm.
The left ovary measures 1.9 x 1.2 x 1.6 cm.

Bilateral adnexa is clear.

No free fluid or obvious significant lymphadenopathy is seen.

NAME: MRS. ARTI SHINDE	AGE: 49YRS	SEX: F
REF. BY : ----	DATE: 20/11/2024	

Opinion:

- **Grade I fatty infiltration of liver with mild hepatomegaly, Advice LFT & Lipid profile correlation.**

For clinical correlation and follow up.

Note: Investigations have their limitations. Solitary radiological investigations never confirm the final diagnosis. They only help in diagnosing the disease in correlation to clinical symptoms and other related tests. USG is known to have inter-observer variations. Further / Follow-up imaging may be needed in some cases for confirmation / exclusion of diagnosis. Patient was explained in detail verbally about the USG findings, USG measurements and its limitations. In case of any typographical error in the report, patient is requested to immediately contact the center for rectification within 7 days post which the center will not be responsible for any rectification. Please interpret accordingly.

Pranali

Dr. Pranali Mahale
MD, Radiodiagnosis
Consultant Radiologist
Reg no. 2019/07/5682

Name : <u>Arta Shinde</u>	Age / Gender : <u>43 / F.</u>
Dr. :	Date : <u>20/11/24.</u>

GYNAEC EXAMINATION REPORTS

PERSONAL HISTORY

CHIEF COMPLAINTS : Multiple Lypoma.
MARITAL STATUS : ~~Married~~ Single / Unmarried
MENSTRUAL HISTORY :
(i) MENARCHE : 16 yrs -
(ii) PRESENT MENSTRUAL HISTORY : 6/11/24. Reg.
(iii) PAST MENSTRUAL HISTORY : (NO)

OBSTETRIC HISTORY : G. P. A. L. 0
PAST HISTORY : } Hospitalised Covid-19 in 2021. (Weakness @)
PREVIOUS SURGERIES :

ALLERGIES : NO.
FAMILY HISTORY : M - DM, HTN. F - HTN.

DRUG HISTORY : no
BOWEL HABITS : } (NO)
BLADDER HABITS :

Name : Acti Shinde Age / Gender 43 / F
Dr. : _____ Date : 20/11/24

GYNAEC EXAMINATION REPORTS

GENERAL EXAMINATION

TEMPERATURE :

RS :

PULSE :

CVs :

BP :

Breasts :

NAD o/e

Per Abdomen :

Per vaginal :

RECOMMENDATIONS

ADVISE :



DR. MONALI SHAH
BHMS, CGO
Certified Clinical Dietitian
Reg. No. 57282

CID NO: 2432507854	
PATIENT'S NAME: MRS.ARTI SHINDE	AGE/SEX: 43Y/F
REF BY: -----	DATE: 20/11/2024

2-D ECHOCARDIOGRAPHY

1. RA, LA RV is Normal Size.
2. No LV Hypertrophy.
3. Normal LV systolic function. LVEF 60 % by bi-plane
4. No RWMA at rest.
5. Aortic, Pulmonary valves normal.Trivial TR, Trivial MR.
6. Great arteries: Aorta: Normal
 - a. No mitral valve prolaps.
7. Inter-ventricular septum is intact and normal.
8. Intra Atrial Septum intact.
9. Pulmonary vein, IVC, hepatic are normal.
- 10.No LV clot.
- 11.No Pericardial Effusion
- 12.No Diastolic dysfunction. No Doppler evidence of raised LVEDP.

PATIENT'S NAME: MRS.ARTI SHINDE	AGE/SEX: 43Y/F
REF BY: -----	DATE: 20/11/2024

1. AO root diameter	3.0 cm
2. IVSd	1.0 cm
3. LVIDd	4.1 cm
4. LVIDs	2.1 cm
5. LVPWd	1.0 cm
6. LA dimension	3.8 cm
7. RA dimension	3.8 cm
8. RV dimension	3.0 cm
9. Pulmonary flow vel:	0.9 m/s
10. Pulmonary Gradient	3.4 m/s
11. Tricuspid flow vel	1.4 m/s
12. Tricuspid Gradient	9 m/s
13. PASP by TR Jet	19 mm Hg
14. TAPSE	2.4 cm
15. Aortic flow vel	1.3 m/s
16. Aortic Gradient	7 m/s
17. MV:E	0.8 m/s
18. A vel	0.6 m/s
19. IVC	17 mm
20. E/E'	10

Impression:

Normal 2d echo study.

Disclaimer

Echo may have inter/intra observer variations in measurements as the study is observer dependent and changes with Pt's hemodynamics. Please co-relate findings with patients clinical status.

End of Report

DR. S. NTIN
Consultant Cardiologist
Reg. No. 87714

Date:- CID: 20/11/24
Name:- *Arti Shinde* Sex / Age: 43 F

EYE CHECK UP

Chief complaints:
Systemic Diseases:
Past history:
Unaided Vision:
Aided Vision:
Refraction:

Nil

RE LE
6/6 6/6
6/6 6/6

(Right Eye)

(Left Eye)

	Sph	Cyl	Axis	Vn	Sph	Cyl	Axis	Vn
Distance								
Near								

Colour Vision: Normal / Abnormal

Remark: *Suburban Diagnostics (India) Pvt. Ltd.*
18/302, ...
...

CID NO. : 2432507854

Name: MRS. ARTI SHINDE

Ref. by : —

SEX: FEMALE

Date: 20/11/2024

MAMMOGRAPHY

Bilateral mammograms have been obtained a low radiation dose film screen technique in the cranio-caudal and oblique projections. Film markers are in the axillary / lateral portions of the breasts.

Bilateral breasts are symmetrical with mixed fibroglandular pattern is noted. Few well circumscribed radiopaque asymmetric noted in right breast largest in right upper outer quadrant with foci of calcification within. No architectural distortion is seen. No abnormal skin thickening is seen. Skin and nipple shadows are normal. Bilateral axillary lymph nodes seen.

Sonomammography of both breasts show normal parenchymal echotexture.

Right breast

A well defined oval lesion of size 1.8 x 1.3 cm is seen in upper outer quadrant at 11 O'clock position with few macro calcification within.

Another similar morphology lesion seen at 10 o'clock position measuring 8.0 x 5.0 mm.

F/s/o - fibroadenoma .

A well defined oval cystic lesion with post acoustic enhancement measuring of size 9.0 x 4.0 mm is seen at 9 O'clock position .f/s/o complex cysts.

Left breast

Few well defined oval hypoechoic lesions of size 8.0 x 5.5 mm and 5.0 x 4.0 mm are seen at 9 o'clock position in left breast.

F/s/o -fibroadenoma .

Simple cyst of size 10.0 x 5.0 mm seen at 6 o'clock position.

Few dilated ducts seen on left side.

Opinion:

Bilateral simple breasts cysts as described above.

Bilateral - fibroadenomas .

ACR BIRADS II

*Suggest: Follow up mammography after one year is suggested.
Please bring all the films for comparison.*

ACR BIRADS CATEGORY

[American college of radiology breast imaging reporting and data system].

- I Negative IV Suspicious (Indeterminate).
II Benign finding V Highly suggestive of malignancy.
III Probably benign finding.

Investigations have their limitations. They only help in diagnosing the disease in correlation to clinical symptoms and other related tests. Please interpret accordingly.

Note : Investigations have their limitations. Solitary radiological investigations never confirm the final diagnosis. They only help in diagnosing the disease in correlation to clinical symptoms and other related tests. Mammography is known to have inter-observer variations. False negative rate of Mammography is approximately 10 %. Management of palpable abnormality must be based on clinical grounds. Further / Follow-up imaging may be needed in some case for confirmation of findings Please interpret accordingly. Patient has been explained in detail about the Mammography findings and limitations. In case of any typographical error in the report, patient is requested to immediately contact the center for rectification within 7 days post which the center will not be responsible for any rectification. If you detect any lump or any other change in the breast before your next screening, consult your doctor immediately.

Pranali

Dr. Pranali Mahale
MD,Radiodiagnosis
Consultant Radiologist
Reg no. 2019/07/5682