



PARKLINE DIAGNOSTICS PVT. LTD.

L.G. 3, 4 & 5, Bhuvana Towers, S.D. Road, Secunderabad - 500 003.

Tel : +91 40-2784 5852, 6649 1787, 7995421787, 7093445852, Fax : +91 40 2784 7864

Email parklinediagnostics@gmail.com www.parklinediagnostics.com



NABL Accredited
Certificate No.MC-2566

MEDICAL EXAMINATION REPORT

Name	Mr. Subrahmanyam Indraganti		Date	22/2/22		
Company	C/o. Mediwheel		Reg. No.	1818337		
Contact No.	9154804432		Sex	<input checked="" type="checkbox"/> M	Age	<input type="checkbox"/> 43
Type	Pre-Emp		Emp. No.:			
	Overseas		Height	129 cm		
	Annual	<input checked="" type="checkbox"/>	Weight	80 kgs		
Remarks	Both clinical & lab parameters within $\text{\textcircled{N}}$ limits.					
			DR. PRIYANKA SANNIDHI MBBS Reg. No: 11351			
Fitness Status	Medically Fit / Unfit		Physician's Signature			


COMPREHENSIVE MEDICAL EXAMINATION REPORT

NAME Mr. Subrahmayam Indraganti

AGE 43 yrs / Male

MARITAL STATUS Married CHILDREN : M F

IDENTIFICATION (IF ANY) A note on (PT) chin



PAST HISTORY

Any family H/o : High Blood Pressure, Heart Disease, Tuberculosis, Diabetes, Asthma, Cancer

Mother

Any personal H/o Major illness like : Typhoid..... NIL Jaundice..... NIL Etc.

Any H/o STD..... NIL Skin infection..... NIL

H/o Blood Transfusion..... NIL Recent Vaccination..... COVID 19 2 doses

H/o Epilepsy..... NIL Giddiness..... NIL

H/o Surgery..... NIL Fracture in the past..... NIL

Any Personal H/O.

High Blood Pressure, Heart Disease Tuberculosis, Diabetes, Asthma, Cancer

Drug Abuse, Drug Allergy, Micturition, Bowels, Alcohol, Smoking, Sleep, MC, Wt. Loss/Wt. Gain

Present illness / Medication

GENERAL EXAMINATION

Conjunctiva :
Skin :
Ears : NDD
Nose :
Throat & Oral Cavity :

Bone, Joints : (N)
Nutritional Status : well nourished
Lymph Nodes : NPD
Edema Feet : NIL
Varicose Veins : NIL

Distant Vision : Near Vision :

Right Eye: 6/6

Right Eye: N6

With glasses / Without glasses

With glasses / Without glasses

left Eye : 6/6

left Eye : N6

with glasses / without glasses

with glasses / without glasses

Colour Vision : VI normal

Ophthalmologist's Signature

Right Ear

Left Ear

Hearing : (N)

(N)

Rinee's Test ;

Weber Test :

Discharge : NIL

NIL

SYSTEMIC EXAMINATION

Pulse : 60 bpm

B.P. : 130/90 mmHg

Lungs : A. Shape of Chest B/L symmetrical
B. Breath Sounds B/L clear ⊕
C. Adventitious Sounds no

Heart : A. Sounds S1 S2 ⊕
B. Murmurs no murmurs

Nervous System

Abdomen : A. Liver NPD
B. Spleen NPD
C. Piles NIL
D. Any Lump NIL

A. Higher Function :
B. Cranial Nerves :
C. Sensory System : (N)
D. Motor System :
E. Jerks :

General : A. Hernia
B. Hydrocele
C. Varicocele NPD

Breast : Rt — Lt —

CANDIDATE'S DECLARATION

I hereby solemnly declare that I am not suffering from Asthma, Hypertension, Diabetes, Occult Psychological disorders or any other ailment which can be suppressed without my voluntary declaration.

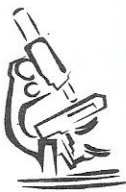Date :



Signature

Place :

Note : General Physical Examination and Investigation included in the health check-up Have certain limitations and may not be able to detect all latent and asymptomatic diseases. Any new symptoms developing after the health check-up or persisting thereafter should be brought to the attention of the treating physician.



PARKLINE DIAGNOSTICS PVT. LTD.

L.G. 3, 4 & 5, Bhuvana Towers, S.D. Road, Secunderabad - 500 003. Tel :+91 40-2784 5852, 6649 1787, 7995421787, 7093445852, Fax : +91 40 2784 7864 Email parklinediagnostics@gmail.com www.parklinediagnostics.com



NABL Accredited
Certificate No.MC-2566

ENT CONSULTATION

S.No. 1818337

Emp.No. 180363

Date 22/2/22

Name Mr. Subrahmanyam
Indraganti

Age 43 Yrs

Sex M/F

EARS :

Right

Left

EAC	:	patent, no effusion	-db-
TM	:	Intact, pearly white, Cone of light (+)	-db-
TFT	:	Rinne's +ve	Rinne's pos.

Weber's - Central

NOSE : Septum (N). Bil. Turbinate (N). Polyp (N) - none

THROAT : Oropharynx (N). Bil. v. cord (N) - none

NECK : (N) Asymmetry b:1

IMPRESSION: ENT clinically normal

Dr. D. Hari Krishna Reddy
MS (ENT)
Head & Neck Surgeon
Reg. No: 88379

Dr. Sowmya Bommakanti
BDS
Implantologist-Harvard (USA)
Cell: +91 7799686970

Padma's
SmileSSS
ORAL HEALTH FOUNDATION

7799686970

Name: Sathya Lakshmi
Sex: M Age: 43

Date: 22/12/22

OPD No: 455

Scaling done
col +

1) taken crown print
(before sleep)

SmileSSS
MULTI SPECIALITY DENTAL CLINIC
B.O.S. IMPLANTOLOGIST (USA)
1-3-1, Rajamudali Street, Kalasiguda,
Secunderabad, Cell : 8977910590.

LG 7, Bhuwana Towers, Beside Minerva Grand Hotel, SD Road, Secunderabad, T.S.
Cell : 7799686970, Email : smilesssdental@gmail.com
Timings : Morning : 9:00 AM to 8:30 PM | Sunday: Only On appointments



PARKLINE DIAGNOSTICS PVT. LTD.

L.G. 3, 4 & 5, Bhuvana Towers, Sarojini Devi Road, Secunderabad - 500 003 Tel. +91 40-2784 5852
6649 1787 Fax :+91 40 2784 7864 Email : parklinediagnostics@gmail.com www.parklinediagnostics.com



NABL Accredited
Certificate No. MC-2566

TEST REPORT

Name	: Mr . SUBRAHMANYAM INDRAGANTI, [1803	TID	: UMR0721153
Age / Gender	: 43 Years / Male	Registered on	: 22-Feb-2022 09:50 AM
Ref.By	: Medi Wheel	Reported On	: 22-Feb-2022 02:42 PM
Req. No	: BIL1818337		

DEPARTMENT OF ULTRASOUND Ultrasound Whole Abdomen

LIVER : Normal in size (13.6 cms) and echotexture. No focal lesions.
No IHBD /CBD dilatation. Portal vein is normal.

SPLEEN : Normal in size and echotexture. No focal lesion seen.

GALL BLADDER : Well distended. No sludge / gall stones / sol.
Gall bladder - Wall thickness is normal.
No pericholecystic oedema.

PANCREAS : Normal in size and echotexture.No calcification / sol.
Pancreatic duct is normal. No peripancreatic fluid collection.

RIGHT KIDNEY : Measures : 9.4 x 4.9 cms.
Normal in size and echotexture.
Cortical thickness is normal.
No evidence of calculi / sol.
Pelvi calyceal system is normal.


LEFT KIDNEY : Measures : 9.9 x4.9 cms.
Normal in size and echotexture.
Cortical thickness is normal.
No evidence of calculi / sol.
Pelvi calyceal system is normal.

URINARY BLADDER : Well distended.Normal in contour.
Wall thickness is normal. No calculus / sol.

PROSTATE : Normal in size and echotexture.
No ascites noted.

IMPRESSION : No sonographic abnormality detected.

Clinical correlation


Dr. Abid Yazden
Consultant Radiologist

The Test marked with*are not accredited by NABL

Lab Timings (Weekdays) : 7.00 am to 8.30 pm

Sundays & Holidays : 7.00 am to 1.00 pm

Radiologists Timings (Weekdays) : 7.00 am to 1.30 pm

Sundays & Holidays : 7.30 am to 9.30 am

Free Home Visit for Sample Collection.

Call : 7995421787, 7093445852, 8121147282, 9885202212



PARKLINE DIAGNOSTICS PVT. LTD.

L.G. 3, 4 & 5, Bhuvana Towers, Sarojini Devi Road, Secunderabad - 500 003 Tel. +91 40-2784 5852
6649 1787 Fax : +91 40 2784 7864 Email : parklinediagnostics@gmail.com www.parklinediagnostics.com



NABL Accredited
Certificate No. MC-2566

TEST REPORT

Name : Mr . SUBRAHMANYAM INDRAGANTI, [1803
Age / Gender : 43 Years / Male
Ref.By : Medi Wheel
Req. No : BIL1818337

TID : UMR0721153
Registered on : 22-Feb-2022 09:50 AM
Reported On : 22-Feb-2022 12:51 PM

DEPARTMENT OF X-RAY X-Ray Chest PA View

Lung fields are clear.

Cardia is normal.


Hila are normal.

C P angles are free.

Bony cage is normal.

Soft tissues are normal.

IMPRESSION : NORMAL CHEST XRAY.


Dr. PRAJAKTA SUKHADEVE
DNB RADIOLOGY
Reg. No. 68493

The Test marked with*are not accredited by NABL

Lab Timings (Weekdays) : 7.00 am to 8.30 pm
Sundays & Holidays : 7.00 am to 1.00 pm

Radiologists Timings (Weekdays) : 7.30 am to 1.30 pm
& 5.30 pm to 7.45 pm
Sundays & Holidays : 7.30 am to 9.30 pm

Free Home Visit for Sample Collection.

Call : 7995421787, 7093445852, 8121147282, 9885202212

ID: 1818337 22-02-2022 12:12:10 PM
MR.SUBRAHMANYAM INDRAGANTI
Male 43Years

CARDIART

HR : 54 bpm
P : 107 ms
PR : 173 ms
QRS : 90 ms
QT/QTc : 425/406 ms
P/QRS/T : 46/38/-16 °
RV5/SV1 : 1.700/0.871 mV

T↓ L↓
NSR
WNL
CS

Diagnosis Information:
Sinus Bradycardia

Dr. NAVEEN KUMAR .C
M.D., B.M.
Consultant Cardiologist
Reg. No. 52291

Report Confirmed by:

PATIENT SUMMARY REPORT

PARKLINE DIAGNOSTICS PVT.LTD

ID : 1818337
NAME : **MR SUBRAHMANYAM INDRAGANTI**
AGE / SEX : 43 / MALE

HEIGHT (cm) : 179
WEIGHT (kg) : 80
PROTOCOL : BRUCE

REF. BY : MEDIWHEEL
DONE BY : DR NAVEEN KUMAR C
TECHNICIAN : G.M.SURESH

CASE HISTORY :

MEDICATION :

OBJECT OF TEST : Routine Check Up.

RISK FACTOR : None.

ACTIVITY : Very Active.

OTHER INVESTIGATION : E C G

REASON FOR TERMINATION : THR ACHIEVED

EXERCISE TOLERANCE : Good (> 10 METS).

EXERCISE INDUCED ARRHYTHMIAS : No.

HAEMO RESPONSE : Normal.

CHRONO RESPONSE : Normal.

FINAL IMPRESSION :

EXTRA COMMENTS : Negative for inducible ischemia

Confirmed By : 
Dr. NAVEEN KUMAR .C
Signature, M.

Consultant Cardiologist
Reg. No. 52291