

CERTIFICATE OF MEDICAL FITNESS

This is to certify that I have conducted the clinical examination of

Sunil Kumar on 30/07/17

After reviewing the medical history and on clinical examination it has been found that he/she is

	Tick
Medically Fit	<input checked="" type="checkbox"/>
<p>It Wit Restrictions Recommendations</p> <p>Though following restrictions have been revealed, in my opinion, these are not impediments to the job.</p> <p>1. <u>C-12 vertebrae lesion</u></p> <p>2. <u>Physician Review</u></p> <p>3. _____</p> <p>However, the employee should follow the advice/medication that has been communicated to him/her.</p> <p>Review after _____</p> <p>Current Unfit.</p> <p>Review after _____ recommended</p> <p>Unfit</p>	

Height: 166cm
Weight: 90kg

Blood Pressure: 112/72mmHg


APOLLO HEALTH AND LIFESTYLE LTD.
APOLLO ONE
 Plot No. 3, Block No. 34, Metro Pillar No. 77
 Pusa Road, WEA Karol Bagh
 New Delhi-110005
 Dr. _____
 Medical Officer

This certificate is not meant for medico-legal purposes

Apollo One (Unit of Apollo Health and Lifestyle Ltd)

Plot no. 3, Block no. 34, Pusa Road, WEA, opposite metro pillar no. 77, Karol Bagh,
New Delhi - 110005. Contact Number 011- 40393610 / Helpline No: 1860 500 7788
Emergency: 1066 / Email: ApolloOnePusaRoad@apolloclinic.com

Registered Office: Apollo Health and Lifestyle Limited
7-1-617/A, 615 and 616, Imperial Towers, 7th Floor,
Amberpet, Hyderabad-500038, U85110TG2000PLC115819

www.apolloclinic.com

Echocardiography Report

Name: MR. SUMIT

Age/Sex: 30Yrs./M

Date: 28.09.2024

Summary of 2D echo

Baseline echocardiography revealed:

- No chamber enlargement seen.
- No RWMA.
- LVEF - 62%
- Normal diastolic function. (E>A)
- Good RV function
- No MR
- Trace TR, NORMAL RVSP
- No thrombus detected.
- No Pericardial effusion seen.
- IVC shows normal inspiratory collapse.

Observations:-Dimensions

LVID d=	33.4	(34-47 mm)
LV IVS=	11.7	(8-11mm)
Pwd =	12.8	(8-11mm)
Ao =	25	(18-36mm)
LA =	34.3	(26-37mm)
LVEF =	62%	(55 +6.2%)

Apollo One (Unit of Apollo Health and Lifestyle Ltd)

Plot no. 3 , Block no. 34, Pusa Road, WEA, opposite metro pillar no. 77, Karol Bagh,
New Delhi - 110005. Contact Number 011- 40393610 / Helpline No: 1860 500 7788
Emergency: 1066 / Email: ApolloOnePusaRoad@apolloclinic.com

Registered Office: Apollo Health and Lifestyle Limited

7-1-617/A, 615 and 616, Imperial Towers, 7th Floor,
Ameerpet, Hyderabad-500038, U85110TG2000PLC115819

Mitral Valve - Normal

- No MR

Aortic valve- Normal

- No AR

Tricuspid Valve -Normal

- Trace TR

Pulmonary Valve-Normal

- No PR

Impression:

- NORMAL VALVE AND CHAMBERS
- No RWMA
- Normal LV systolic function (EF= 62%)
- Normal diastolic function.
- No PAH



DR. RAJNI SHARMA (DM CARDIOLOGY)
SR. CONSULTANT

Apollo One (Unit of Apollo Health and Lifestyle Ltd)
Plot no. 3 , Block no. 34, Pusa Road, WEA, opposite metro pillar no. 77, Karol Bagh,
New Delhi - 110005. Contact Number 011- 40393610 / Helpline No: 1860 500 7788
Emergency: 1066 / Email: ApolloOnePusaRoad@apolloclinic.com

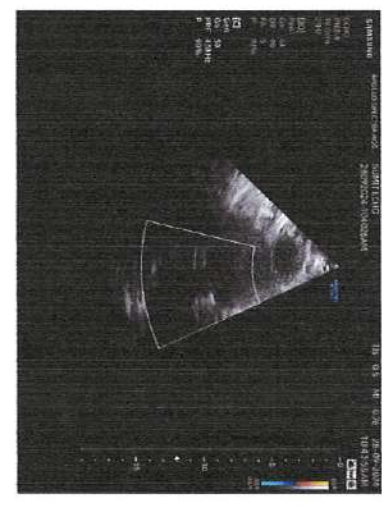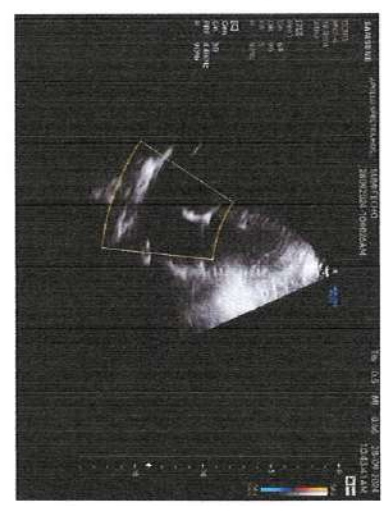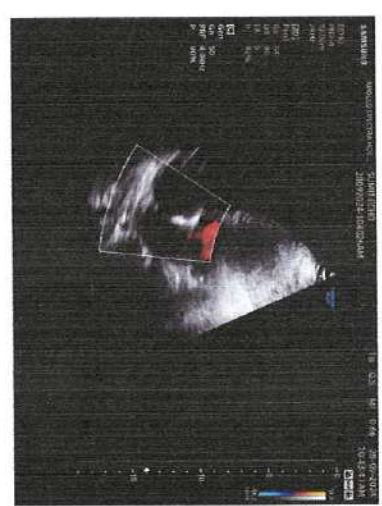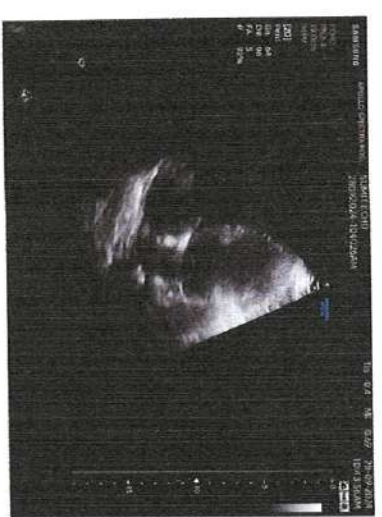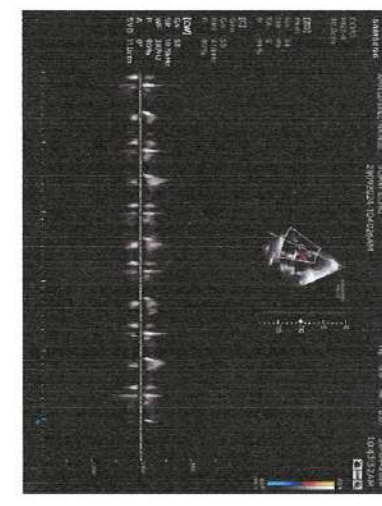
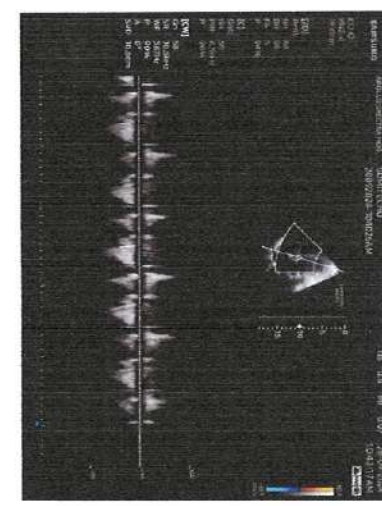

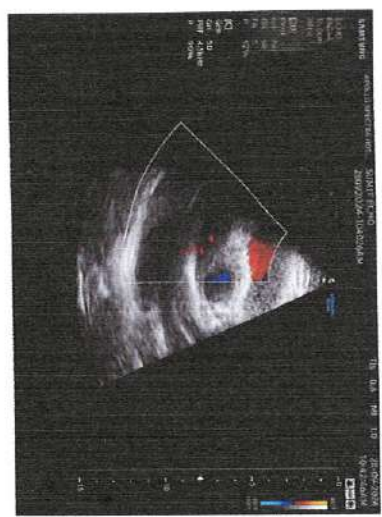
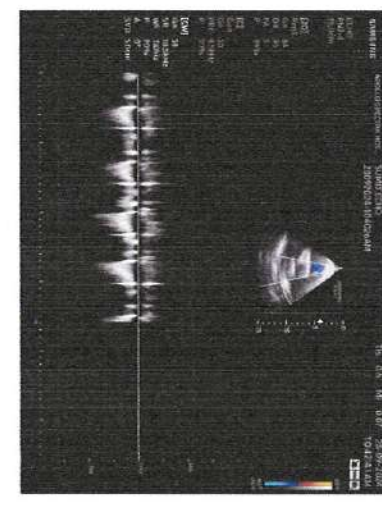
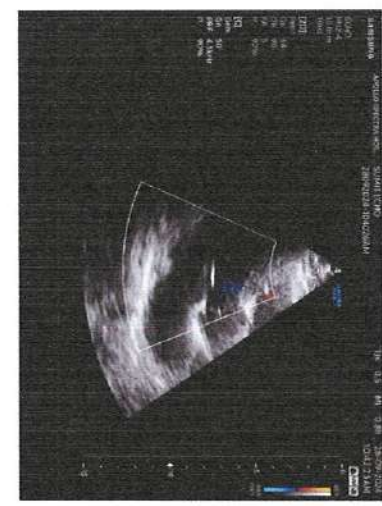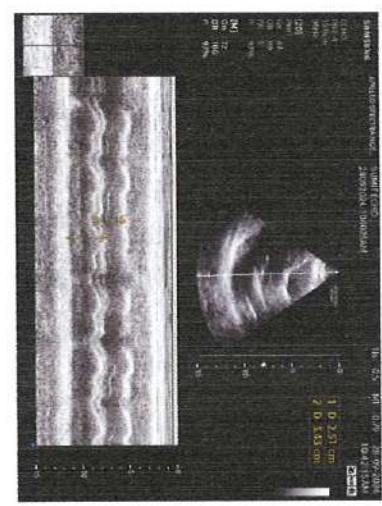
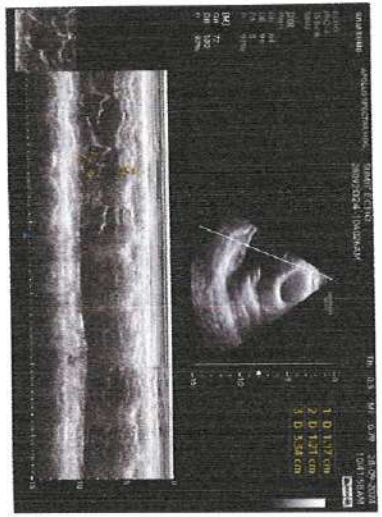
Registered Office: Apollo Health and Lifestyle Limited
7-1-617/A, 615 and 616, Imperial Towers, 7th Floor,
Ameerpet, Hyderabad-500038, U85110TG2000PLC115819

www.apolloclinic.com

Patient
 ID: 28092024-104028AM
 Name: SUMIT ECHO
 Birth Date:
 Gender:

Exam
 Accession #: 28092024-104028AM
 Exam Date: SUMIT ECHO
 Description:
 Operator:

28-09-2024



NAME: SUMIT KUMAR	AGE: 30 /SEX: M
DATE: September 28, 2024	REF.BY: -HEALTH CHECKUP
S.NO.:-	UHID NO.: - CAOP.0000001912

ULTRASOUND WHOLE ABDOMEN

Liver is normal in size(13.5cm) and shows diffuse increase in echotexture with loss of portal vein echogenicity suggestive of Grade II fatty infiltration. No focal lesion seen in the liver. Intrahepatic bile ducts and portal radicals are normal in caliber.

Gall bladder is not visualized h/o post op.

CBD is not dilated.

Portal vein is normal in caliber.

Both kidneys are of normal size (RK 10.1x 4.1cm, LK 9.0x 4.9cm), shape and echo pattern. No growth or hydro nephrotic changes seen in either kidney. The parenchymal thickness is normal & cortico-medullary differentiation is well maintained.

Spleen is normal in size (9.1cm) and echotexture.

Pancreas visualized part appears normal.

No free fluid seen in the peritoneal cavity.

Urinary bladder is partially filled and shows no mural or intraluminal pathology.

Prostate is normal in Size(30x21x23mm), volume ~24cc and Shape. No focal lesion is seen.

IMPRESSION: -Grade II FATTY LIVER

Please correlate clinically.

DR. SEEMA PRAJAPATI
SENIOR RESIDENT
RADIODIAGNOSIS

This report is only a professional opinion and it is not valid for medico-legal purposes

Apollo One (Unit of Apollo Health and Lifestyle Ltd)

Plot no. 3 , Block no. 34, Pusa Road, WEA, opposite metro pillar no. 77, Karol Bagh,
New Delhi - 110005. Contact Number 011- 40393610 / Helpline No: 1860 500 7788
Emergency: 1066 / Email: ApolloOnePusaRoad@apolloclinic.com

Registered Office: Apollo Health and Lifestyle Limited

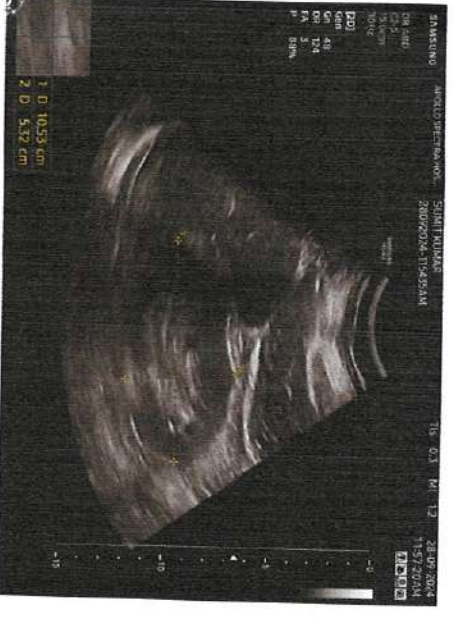
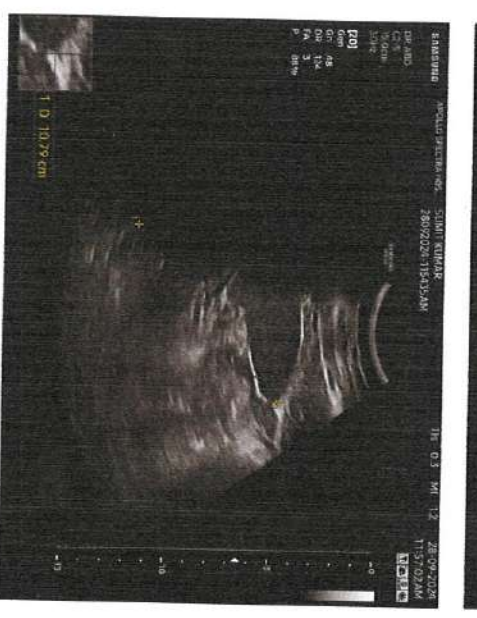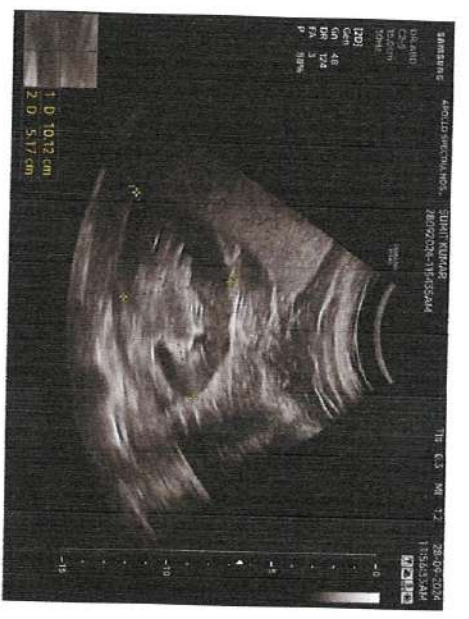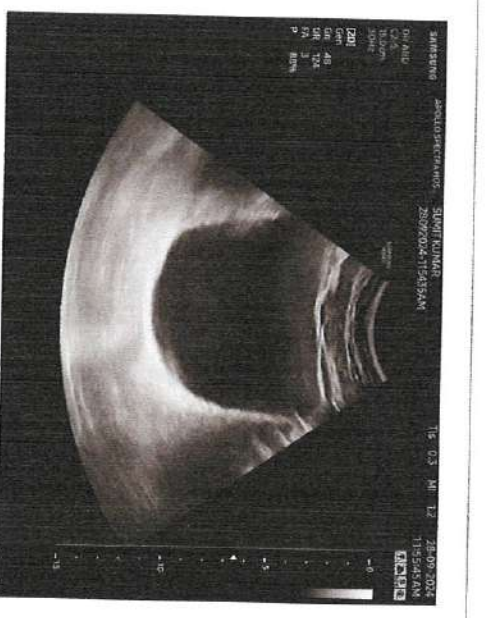
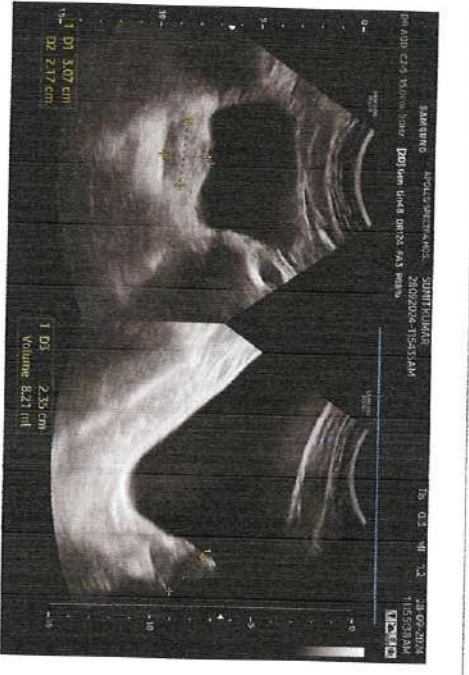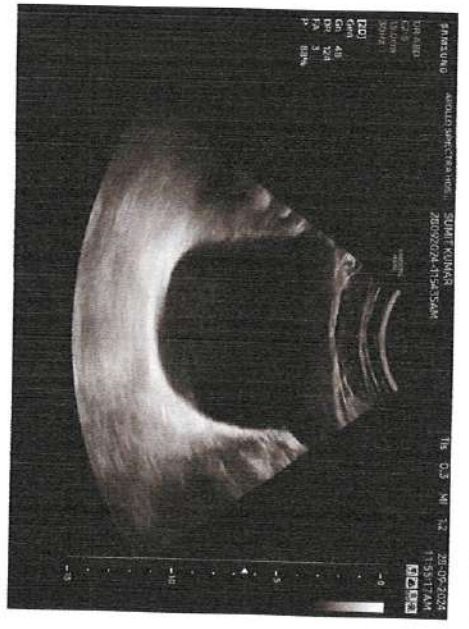
7-1-617/A, 615 and 616, Imperial Towers, 7th Floor,
Ameerpet, Hyderabad-500038, U85110TG2000PLC115819

www.apolloclinic.com

ID
Name
Birth Date
Gender

28092024-115435AM
SUMIT KUMAR

Exam
Accession #
Exam Date
Description
Operator



MR SUMIT KUMAR

Male 30Years

Req. No. :

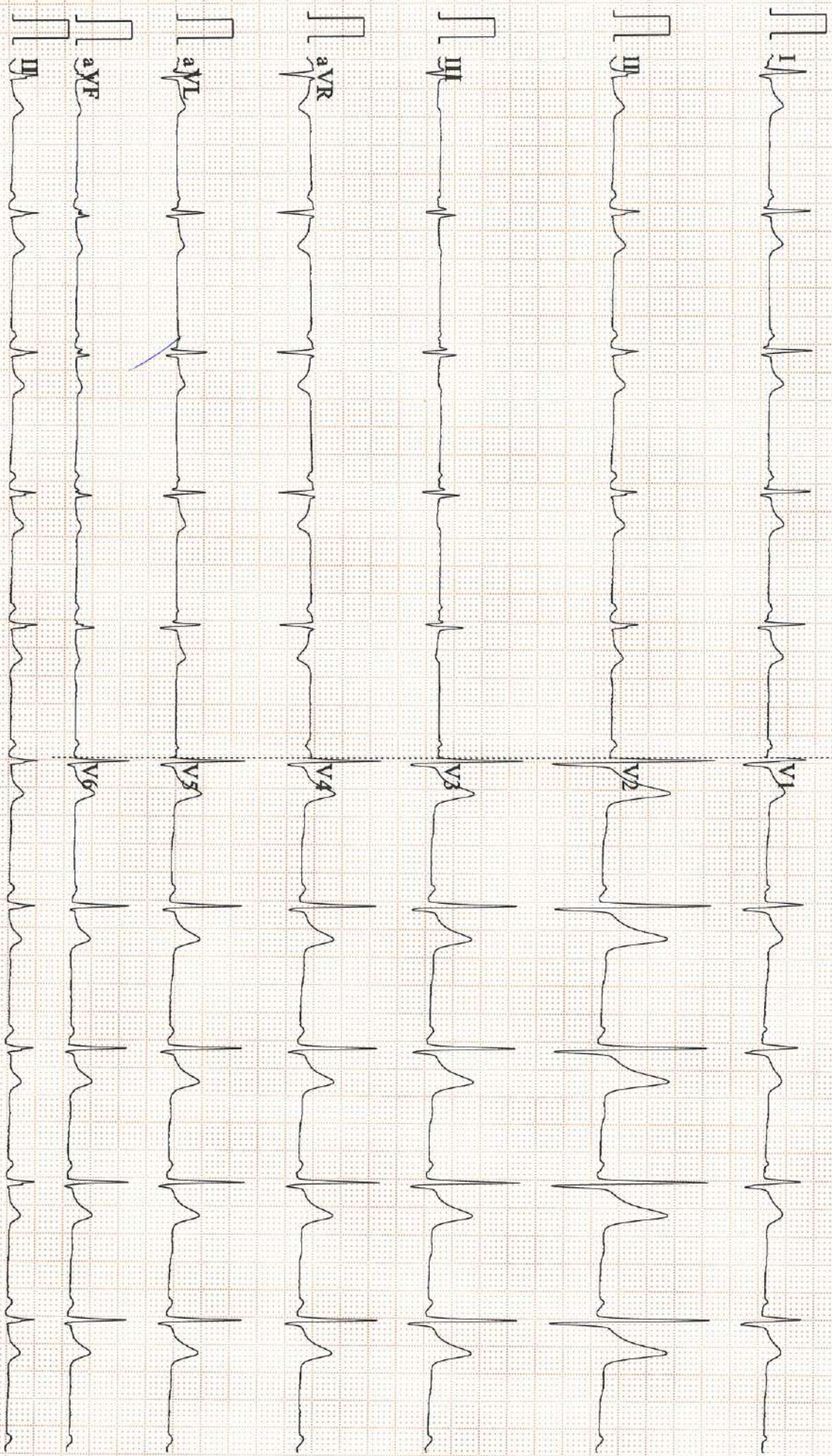
Diagnosis Information:

Sinus Rhythm

Normal ECG

HR	: 60	bpm
P	: 87	ms
PR	: 123	ms
QRS	: 83	ms
QT/QTcBz	: 365/366	ms
P/QRS/T	: 48/47/36	°
RV5/SV1	: 1.304/0.361	mV

Report Confirmed by:



ID caop0000001912	Height 166cm	Age 30	Gender Male	Test Date / Time 28.09.2024. 11:25
----------------------	-----------------	-----------	----------------	---------------------------------------

Body Composition Analysis

	Values	Total Body Water	Soft Lean Mass	Fat Free Mass	Weight
Total Body Water (L)	35.4 (34.1~41.7)	35.4	45.6 (43.7~53.5)	48.3 (46.4~56.7)	80.9 (51.5~69.7)
Protein (kg)	9.6 (9.2~11.2)				
Minerals (kg)	3.28 (3.15~3.85)	NON-OSSIOUS			
Body Fat Mass (kg)	32.6 (7.3~14.6)				


Muscle-Fat Analysis

	Under	Normal	Over
Weight (kg)	55 70 85 100 115 130 145 160 175 190 205 %		80.9
SMM (kg)	70 80 90 100 110 120 130 140 150 160 170 %		26.9
Body Fat Mass (kg)	40 60 80 100 160 220 280 340 400 460 520 %		32.6


Obesity Analysis

	Under	Normal	Over
BMI (kg/m ²)	10.0 15.0 18.5 22.0 25.0 30.0 35.0 40.0 45.0 50.0 55.0		29.4
PBF (%)	0.0 5.0 10.0 15.0 20.0 25.0 30.0 35.0 40.0 45.0 50.0		40.3

Segmental Lean Analysis



Segmental Fat Analysis



* Segmental fat is estimated.

Body Composition History

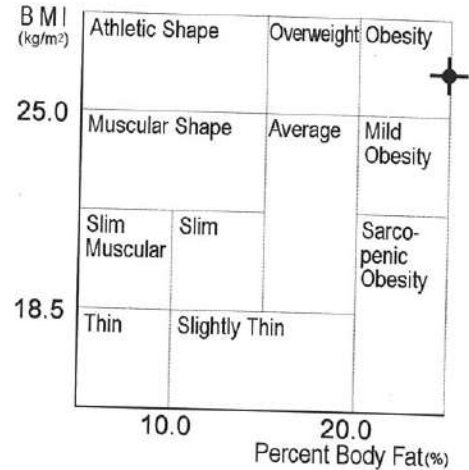
	Weight (kg)	SMM (kg)	PBF (%)
Recent	80.9	26.9	40.3
Total			

InBody Score

53/100 Points

* Total score that reflects the evaluation of body composition. A muscular person may score over 100 points.

Body Type



Weight Control

Target Weight	60.7 kg
Weight Control	- 20.2 kg
Fat Control	- 23.5 kg
Muscle Control	+ 3.3 kg

Obesity Evaluation

BMI	<input type="checkbox"/> Normal	<input type="checkbox"/> Under	<input checked="" type="checkbox"/> Slightly Over	<input type="checkbox"/> Over
PBF	<input type="checkbox"/> Normal	<input type="checkbox"/> Slightly Over	<input checked="" type="checkbox"/> Over	

Body Balance Evaluation

Upper	<input checked="" type="checkbox"/> Balanced	<input type="checkbox"/> Slightly Unbalanced	<input type="checkbox"/> Extremely Unbalanced
Lower	<input checked="" type="checkbox"/> Balanced	<input type="checkbox"/> Slightly Unbalanced	<input type="checkbox"/> Extremely Unbalanced
Upper-Lower	<input type="checkbox"/> Balanced	<input checked="" type="checkbox"/> Slightly Unbalanced	<input type="checkbox"/> Extremely Unbalanced

Research Parameters

Basal Metabolic Rate	1413 kcal	(1707~2004)
Waist-Hip Ratio	1.10	(0.80~0.90)
Visceral Fat Level	17	(1~9)
Obesity Degree	133 %	(90~110)
Bone Mineral Content	2.70 kg	(2.60~3.18)
SMI	7.3 kg/m ²	
Recommended calorie intake	2299 kcal	

Impedance

	RA	LA	TR	RL	LL
Z(Ω) 5 kHz	345.4	361.7	30.2	318.0	341.3
50 kHz	302.7	319.3	26.2	276.7	298.9
250 kHz	271.1	287.3	22.1	248.6	268.6

Dr. Rajeev Nangia

MBBS, MS (ENT)

Experience : 31 Years



Mr. Sunil Kumar

- No H/O Ear discharge
- No H/O tinnitus
- Ear Wax (+)

Recommendations

- Ear Wax removal
- follow up.

APOLLO HEALTH AND LIFESTYLE LTD.
APOLLO ONE
Plot No. 3, Block No. 34, Metro Pillar No. 77
Pusa Road, WEA Karol Bagh
New Delhi-110005

Apollo One (Unit of Apollo Health and Lifestyle Ltd)

Plot no. 3, Block no. 34, Pusa Road, WEA, opposite metro pillar no. 77, Karol Bagh,
New Delhi - 110005. Contact Number 011- 40393610 / Helpline No: 1860 500 7788
Emergency: 1066 / Email: ApolloOnePusaRoad@apolloclinic.com

Registered Office: Apollo Health and Lifestyle Limited
7-1-617/A, 615 and 616, Imperial Towers, 7th Floor,
Ameerpet, Hyderabad-500038, U85110TG2000PLC115819

www.apolloclinic.com

Dr. Alveen Kaur
Senior Consultant – Dental Surgeon
For Booking an Appointment
+91 8929440195
Days – Mon to Sat 10am to 6pm
DMC – A-12249



Mr. Sumit Kumar

30/M

OEI-

Gen- deposits⁺⁺
Calculus⁺⁺

tartar⁺⁺

Halitosis⁺⁺

R Adv.

- Deep oral prophylaxis
+ polishing.

Dr. Alveen Kaur

Signature:
APOLLO HEALTH AND LIFESTYLE LTD.
APOLLO ONE
Plot No. 3, Block No. 34, Metro Pillar No. 77
Pusa Road, WEA Karol Bagh
New Delhi

Apollo One (Unit of Apollo Health and Lifestyle Ltd)
Plot no. 3, Block no. 34, Pusa Road, WEA, opposite metro pillar no. 77, Karol Bagh,
New Delhi - 110005. Contact Number 011- 40393610 / Helpline No: 1860 500 7788
Emergency: 1066 / Email: ApolloOnePusaRoad@apolloclinic.com

Registered Office: Apollo Health and Lifestyle Limited
7-1-617/A, 615 and 616, Imperial Towers, 7th Floor,
Ameerpet, Hyderabad-500038, U85110TG2000PLC115819

www.apolloclinic.com

Eye Checkup


NAME: - MR. Sumit Kumar

Age: - 30

Date: - 28/9/24

SELF / CORPORATE: -

	Right Eye	Left Eye
Distant Vision	6/c	6/c
Near vision	6/c	6/c
Color vision	OK	OK
Fundus examination		
Intraocular pressure		
Slit lamp exam		

Signature: 



Apollo One (Unit of Apollo Health and Lifestyle Ltd)
Plot no. 3, Block no. 34, Pusa Road, WEA, opposite metro pillar no. 77, Karol Bagh,
New Delhi - 110005. Contact Number 011- 40393610 / Helpline No: 1860 500 7788
Emergency: 1066 / Email: ApolloOnePusaRoad@apolloclinic.com

Registered Office: Apollo Health and Lifestyle Limited
7-1-617/A, 615 and 616, Imperial Towers, 7th Floor,
Ameerpet, Hyderabad-500038, U85110TG2000PLC115819

www.apolloclinic.com

Mr. Sunit Kumar / 30yr / M



Advanced Diagnostics Powered by AI

Height : 166 cm	Weight : 80 kg	BMI : 29.03	Waist Circum :
Temp : 98.02 F	Pulse : 63 bpm	Resp : 18/min	B.P : 117/87 mmHg

SpO2 - 95%

General Examination / Allergies

History :-

Past His :- MS

Surgical His :- Lap Cholecystectomy
1yr Bone
Spine SX - 2yr Bone

Allergy :- NO

Family His :- MS

Covid Vaccines :- 2 doses

Diet :- veg

Physical Activity :- moderate

Menstruation His :- -

Marital His :- Married

Addictions :- NO

Central health checkup
c/o weakness & lethargy

CVS } none
RS }
CNS }
P/A } SHT B S ⊕

ADVICE :-

S-VITD, S-VITB, 12

APOLLO HEALTH AND LIFESTYLE LTD.
APOLLO ONE
Plot No. 3, Block No. 34, Metro Pillar No. 77
Pusa Road, WEA, Karol Bagh
New Delhi - 110005

Apollo One (Unit of Apollo Health and Lifestyle Ltd)
Plot no. 3, Block no. 34, Pusa Road, WEA, opposite metro pillar no. 77, Karol Bagh,
New Delhi - 110005. Contact Number 011- 40393610 / Helpline No: 1860 500 7788
Emergency: 1066 / Email: ApolloOnePusaRoad@apolloclinic.com

Registered Office: Apollo Health and Lifestyle Limited
7-1-617/A, 615 and 616, Imperial Towers, 7th Floor,
Ameerpet, Hyderabad-500038, U85110TG2000PLC115819

www.apolloclinic.com

=====

NAME: SUMIT KUMAR
DATE: 28.09.2024
REF. BY: - HEALTH CHECKUP

=====

AGE: 30Y /SEX/M
MR. NO: -CAOP.0000001912
S.NO.: - 2642

=====

X-RAY CHEST PA VIEW

Mid inspiratory film.

Rotation+

Both lung fields and hila are normal .

Both costophrenic and cardiophrenic angles are clear .

Both diaphragms are normal in position and contour .

Thoracic wall and soft tissues appear normal.

Please correlate clinically and with lab. Investigations


**DR. SEEMA PRAJAPATI
SENIOR RESIDENT
RADIOLOGIST**

Note: It is only a professional opinion. Kindly correlate clinically.

Apollo One (Unit of Apollo Health and Lifestyle Ltd)
Plot no. 3 , Block no. 34, Pusa Road, WEA, opposite metro pillar no. 77, Karol Bagh,
New Delhi - 110005. Contact Number 011- 40393610 / Helpline No: 1860 500 7788
Emergency: 1066 / Email: ApolloOnePusaRoad@apolloclinic.com

Registered Office: Apollo Health and Lifestyle Limited
7-1-617/A, 615 and 616, Imperial Towers, 7th Floor,
Ameerpet, Hyderabad-500038, U85110TG2000PLC115819

www.apolloclinic.com