



डॉ. सविता क्लिनिक

34, भूतल, मोहिनी अदिति आर्केड, शाहपुरा मस्जिद के पास
भरत नगर रोड, ई-7/194, अरेरा कॉलोनी, भोपाल - 462038

Mob. : 8989649694, 9516333619

Clinic Registration : CL/5392/Jun/2017

PNDT Registration : MPPCPNDT/BPL/2017/206



Name : Mrs. Nitika Lekwari. 32/male Age.....YRS./F

R/B.....No.Date 16/11/23

WHOLE ABDOMEN ULTRASOUND REPORT

Indication : Health check-up.

Liver appears normal / enlarged in size and shape with smooth in outline. Normal / increased perenchymal echogenicity is noted. No E/O focal lesion / IHBR dilatation is seen. Hepatic veins and portal veins appear normal.

No E/O Subdiaphragmatic Collection.

Gall Bladder is physiologically well distended / collapsed. No E/O echogenic foci in GB lumen. GB wall is normal / thickened. No E/O pericholecystic collection. common duct reveals normal course and caliber.

Pancreas appear normal in size, shape and echo texture with smooth contour. No peripancreatic pathology seen. (Not seen due to gases)

Spleen is normal / enlarged in size and normal in echo texture.

IVC and aorta appear to be normal.

No evidence of lymphadenopathy is noted.

No evidence of free fluid is noted.

Right Kidney is normal in size, shape and position. Corticomedullary differentiation (CMD) is well maintained. Normal cortical thickness is noted. No E/O hydronephrosis or calculus is noted. multiple concretion seen .68 / .45 / .46 cm

size, no hydronephrosis.

Dr. P. Savita, MD
MBBS, MD (O&G) Reg. No. 9971
स्त्री रोग विशेषज्ञ

PTO
Dr. Jayant Yadav, MD
MBBS, MD (Radiologist) Reg. No. 4166
रेडियोलॉजिस्ट

Left Kidney is normal in size, shape and position. CMD is well maintained. Normal cortical thickness is noted. No E/O hydronephrosis or calculus is noted. *1.52 cm size concretum seen.*

Urinary Bladder is well distended (physiological) / collapsed. Its contents are echo free. No E/O bladder wall thickening is noted. Post-void residue is insignificant. *Bilateral Urinary jet seen*

Prostate is normal in size, shape and echo texture with smooth outline. No E/O focal lesion is noted.

Uterus is ante / retro verted and normal in size, shape and echo texture with smooth outline. No E/O focal lesion is noted, endometrial echo appear normal. Cervical and vaginal shadows appear normal.

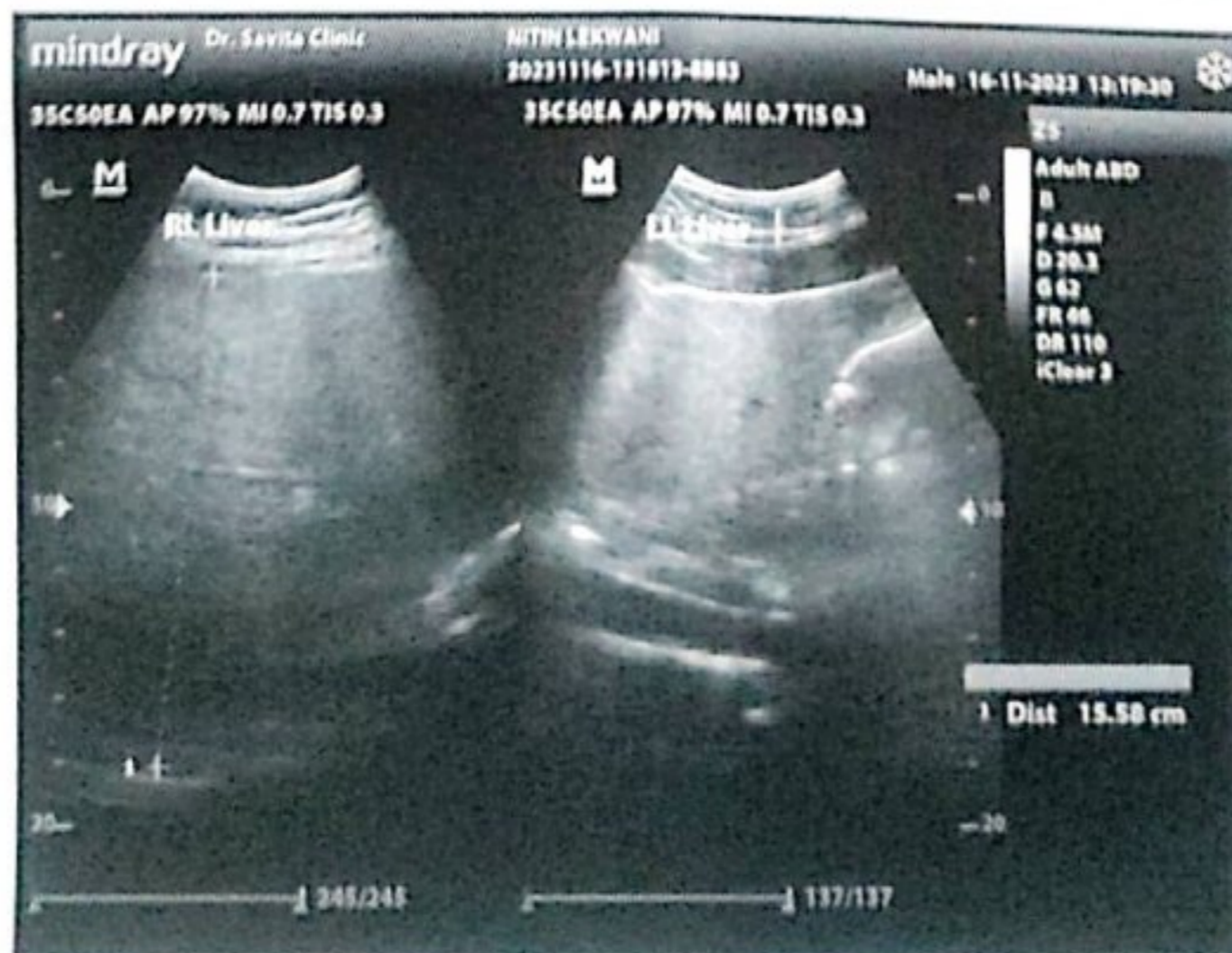
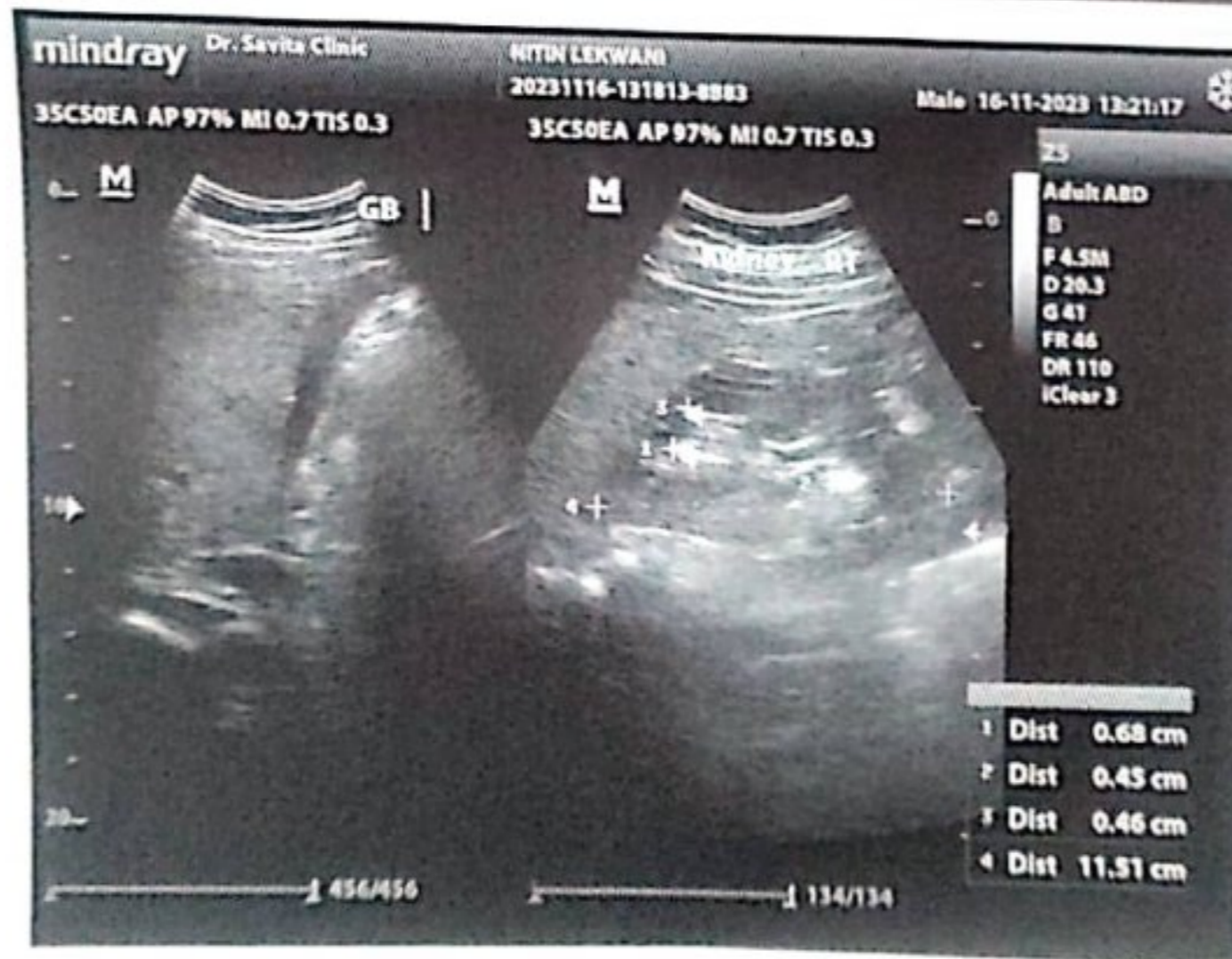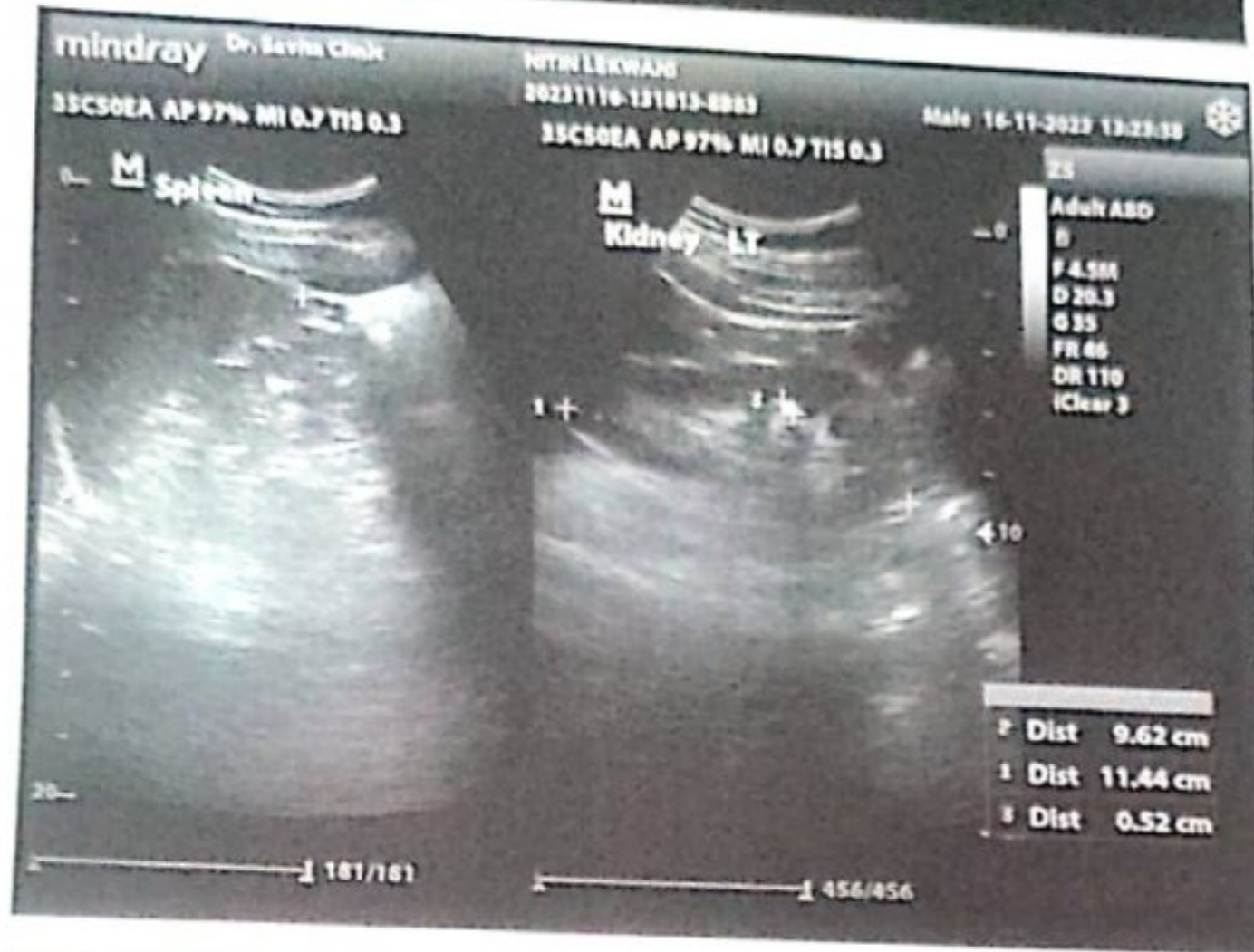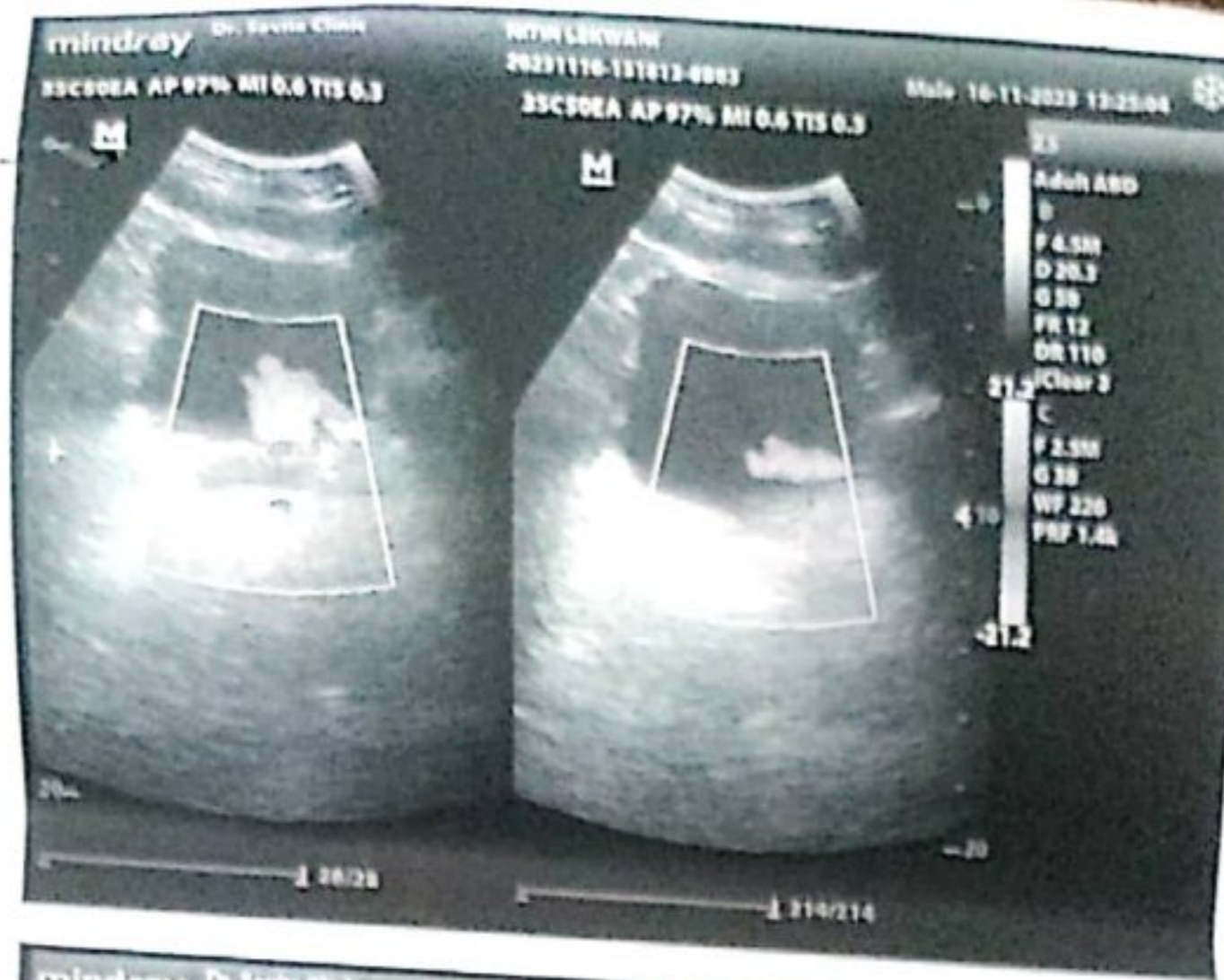
Right Ovary appears Enlarged / Normal in size, shape and echo texture.

Left Ovary appears Enlarged / Normal in size, shape and echo texture.

Impression : Normal study. *Bilateral renal concretum.*

Advised clinical Correlation.







दिवाकर डायग्नोस्टिक सेंटर

E-7/636, पंजाब नेशनल बैंक के पास, मैन रोड, अरेरा कॉलोनी, भोपाल (म.प्र.
मॉ : 9826340190

Pt Name :- Mr.Nitin Lekhwani
Age :- 33/M
Lab. No. :- 02
Date :- 16/11/2023

URINE ANALYSIS

<u>A. PHYSICALEXAMINATION</u>	
1. Colour	Pale Yellow
2. Appearance	Clear
3. Specific Gravity	Q.N.S.
<u>B. CHEMICAL EXAMINATION</u>	
1.Reaction	Acidic
2.Albumin	Nil
3.Sugar	Nil
4.Bile Salts	Absent
<u>C. MICROSCOPIEXAMINATION</u>	
Pus Cells	2-3/HPF
R.B.C.	Nil
Epithelial Cell	2-3/HPF
Cast	Nil
Crystals(Cal.Oxa)	Nil
Bacteria	Nil
Amorphous	Nil
T. Vaginatis	Nil



Pathologist
Dr. Deepika Agrawal
- MBBS, MD.
Consultant Pathologist



दिवाकर डायग्नोस्टिक सेंटर

E-7/636, पंजाब नेशनल बैंक के पास, मैन रोड, अरेरा कॉलोनी, भोपाल (म.प्र.
मॉ : 9826340190

Pt Name :- Mr.Nitin Lekhwani
Age :- 33/M
Lab. No. :- 02
Date :- 16/11/2023

EXAMINATION OF BLOOD

TEST	RESULT	NORMAL VALUE
Haemoglobin	15.9gms%	Female 12-16gms%, Male 14-18gms%
Red Cell count	5.90	4.5-5.6 million /cumm
Platelet Count	2.12	1.5-5.6 Lac/cumm
Leucocytes per.cu.mm	6100/cumm	5000-11000/cumm
Neutrophils	50%	50-70%
Lymphocytes	37%	20-40%
Eosinophils	07%	0-7%
Monocytes	06%	2-8%
PCV	49.1	37-47
MCV	83.3	76-96
MCH	26.9	27-32
MCHC	32.3	31-35
ESR	08	Male 0-9, Female 0-20mm/FHR
Blood Group	*B* Positive	By slide method
Total Serum Cholesterol	180.0	100-250 mg%
Serum Triglyceride	155.0	Up to 150 mg%
Serum Cholesterol HDL	49.0	Up to 65 mg%
Serum Cholesterol LDL	100.0	Up to 125 mg%
VLDL	31.0	Up to 30 mg%
S.Bilirubin(Total)	0.91	0.2-1.0mg/dl
Direct	0.50	0.0-0.25mg/dl
Indirect	0.41	
SGOT	25.0	5-35U/L
SGPT	27.0	8-40U/L
Alk Phosphatase	10.9	3-13 KA units
S. Protein(Total)	6.0	6.0-8.0mg%
Albumin	4.0	3.7-5.3mg%
Globulin	2.0	1.5 to 3.5 mg%
Blood Urea	25.0	Up to 40 mg%
S.Creatine	0.95	0.5-1.4mg/dl
S. Uric Acid	6.1	3.5-7.5mg%
GGTP	25.0	5-35 UL/dl
Fasting Blood Sugar	87.0	Up to 110 mg%
PP Blood Sugar	125.0	Up to 125 mg%
Glycosylated Hemoglobin HBA1c	5.8	Below - 6.0 % -Non Diabetic control 6-7 % -Excellent control Above- 8 % -Poor control
Thyrod Stimulating Hormone(TSH)	3.91	0.27-4.2

Pathologist

All test have technical limitation. Collaborative clinic pathological interpretation is mandatory. In case of disparity test may be repeated immediately. Typographical mistakes should be get correct instantly. This report is not valid for medico legal purpose.



Dr. Deepika Agrawal
MBBS, MD.
Consultant Pathologist



दिवाकर डायग्नोस्टिक सेंटर

E-7/636, पंजाब नेशनल बैंक के पास, मैन रोड, अरेरा कॉलोनी, भोपाल (म.प्र.
मॉ : 9826340190

Pt Name :	Mr.Nitin Lekhwani
Age :	33/M
Lab. No. :	02
Date :	16/11/2023
Skigram	X Ray Chest PA View
Radiologist	Dr. B.M.Agarwal MD (Radiology)

REPORT

Tricia Central

Thoracic cage normal

Both Lungs Field Clear.

Both hilers ++

Cardiac border normal

Both cp angles clear

Both domes and diaphragm normal

IMPRESSION

-Please rule out bronchitis

-COORELATE WITH CLINICAL FINDINGS.



Dr. Deepika Agrawal
Radiologist
Dr. Deepika Agrawal
MBBS, MD.
Consultant Pathologist

भारत निर्वाचन आयोग
ELECTION COMMISSION OF INDIA
भारतीय पाली पहचान पत्र - ELECTOR'S IDENTITY CARD

UKL2134982

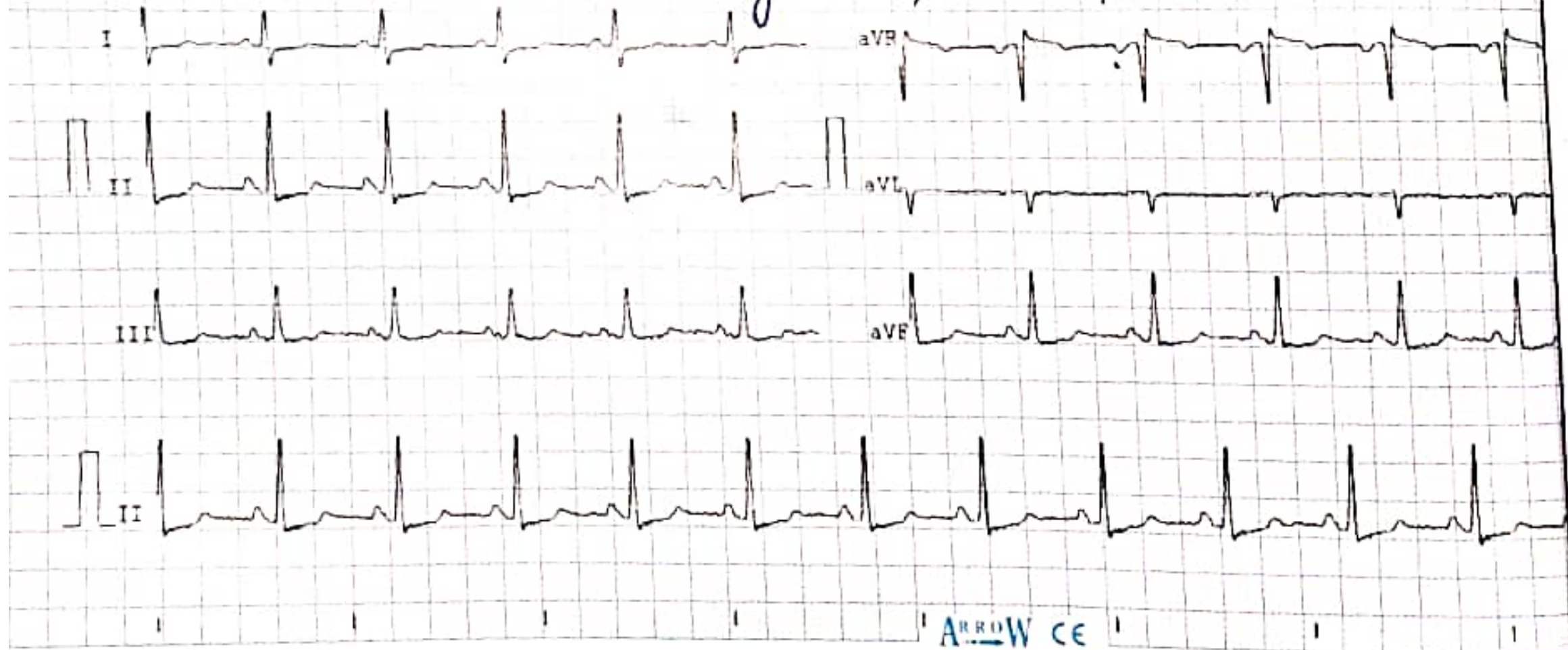


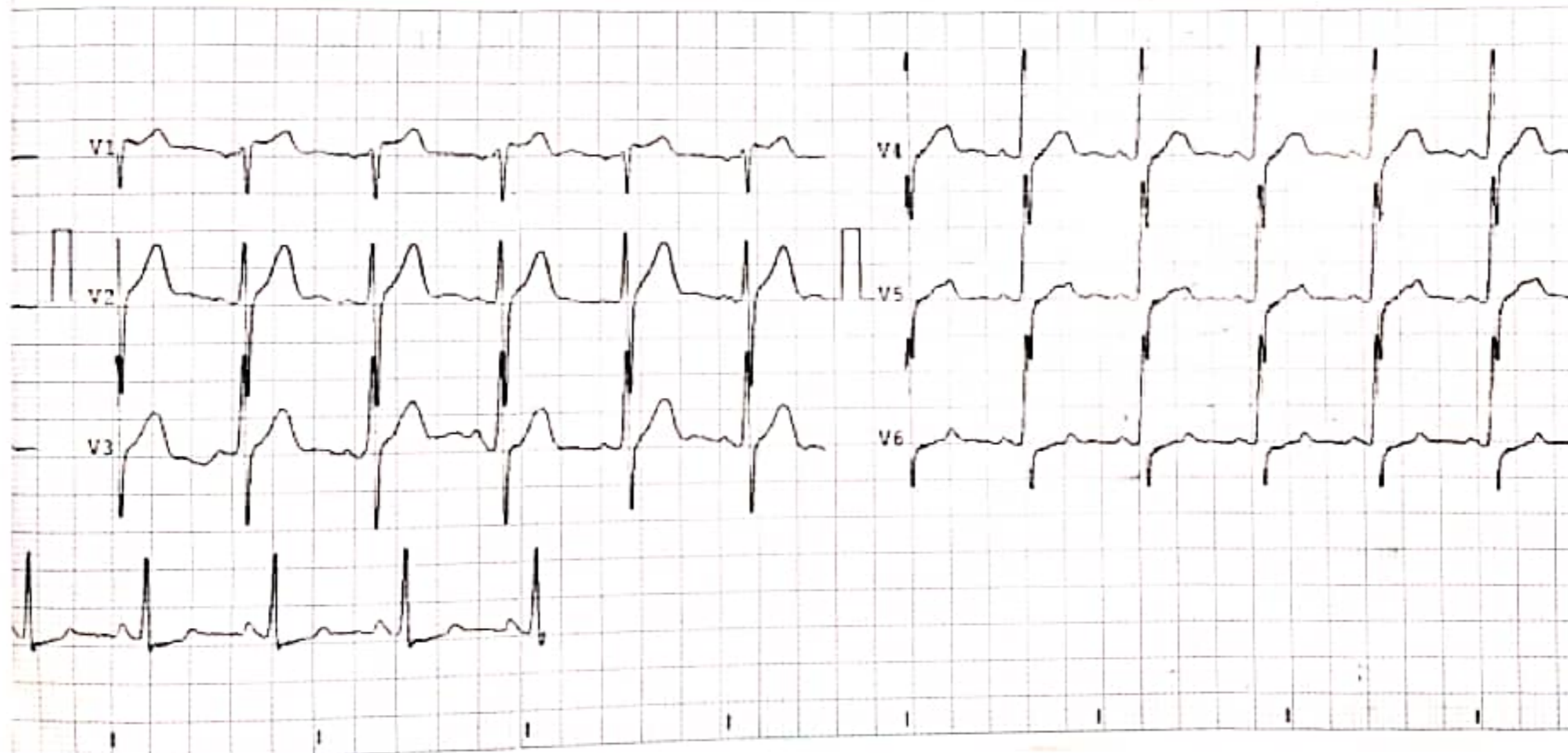
निर्वाचक का नाम : नित्य लेखवानी
ELECTOR'S NAME : NITYA LEKHWANI
पिता का नाम : जय लेखवानी
FATHER'S NAME : JAI LEKHWANI

VAD



Mr. Nitin Lekhware - 16/11/23
Age - 33/m





Observations :-

HR :- 96 bpm
 R-R :- 620 ms
 P-R :- 070 ms
 QRS :- 63 ms
 QT/QTc :- 288/365 ms
 P Axis :- 87 °
 R Axis :- 76 °
 T Axis :- 47 °

[Handwritten signature]



Remarks :-

Unconf. *Amal W. G. G.*

Diwaker Diagnostics Centre
E-7, 636 Aera Colony, Bhopal(M.P.)

Report



(GEM213180307)(R)Allengers

82 NIPIN LEKHWANI / 33 Yrs / M / 0 Cms / 0 Kg Date: 16-Nov-2023 Technician : BOB

Report :

TEST OBJECTIVE : ROUTINE CHECK UP
RISK FACTOR : MALE
ACTIVITY : MODERATE ACTIVE
MEDICATION : NONE
REASON FOR TERMINATION : FATIGUE, HEART RATE ACHIEVED
EXERCISE TOLERANCE : GOOD
EXERCISE INDUCED ARRHYTHMIAS : NO
HAEMODYNAMIC RESPONSE : NORMAL
CHRONOTROPIC RESPONSE : NORMAL
FINAL IMPRESSION : STRESS TEST IS NEGATIVE FOR EXERCISE INDUCED ISCHAEMIC HEART DISEASE

दिवाकर डायग्नोस्टिक सेंटर
E-7/636, पंजाब नेशनल बैंक के पास, मैन रोड, अरेरा कॉलोनी, भोपाल म.प.
मो: 9826340190



[Handwritten signature]

Doctor : Cardiologist





82 / NITIN LEKHWANI / 33 Yrs / M / 0 Cms / 0 Kg Date: 16-Nov-2023 Technician : BOB

Stage	Time	Duration	Belt Speed (mph)	Elevation	METs	Rate	% THR Achieved	BP	RPP	PVC	Comments
Supine	00:36	0:01	00.0	00.0	01.0	109	58 %	120/70	130	00	
Standing	01:00	0:01	00.0	00.0	01.0	106	57 %	120/70	127	00	
HV	01:34	0:01	00.0	00.0	01.0	105	56 %	120/70	125	00	
Warm Up	02:35	0:01	01.0	00.0	01.0	104	56 %	120/70	124	00	
ExStart	02:53	0:07	01.7	10.0	01.1	120	64 %	120/70	144	00	
BRUCE Stage 1	05:53	3:00	01.7	10.0	04.7	134	72 %	128/79	171	00	
BRUCE Stage 2	08:53	3:00	02.5	12.0	07.1	153	82 %	134/88	205	00	
PeakEx	09:45	0:52	03.4	14.0	08.0	164	88 %	134/88	219	00	
Recovery	10:44	1:00	00.0	00.0	01.2	140	75 %	128/79	179	00	
Recovery	11:44	2:00	00.0	00.0	01.0	258	138 %	120/70	309	00	
Recovery	12:15	2:30	00.0	00.0	01.0	128	68 %	120/70	153	00	

Findings :

Exercise Time : 06:53
 Max HR Attained : 258 bpm 138% of Target 187
 Max BP Attained : (Sys) 134/88
 Max WorkLoad Attained : 8 Fair response to induced stress
 Max ST Dep Lead & Value : Max ST Dep Lead & Value
 Test End Reasons : Fatigue, Heart Rate Acheived

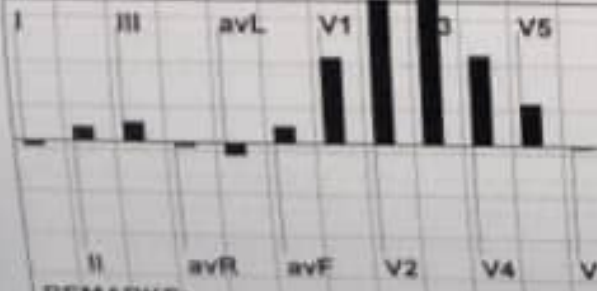
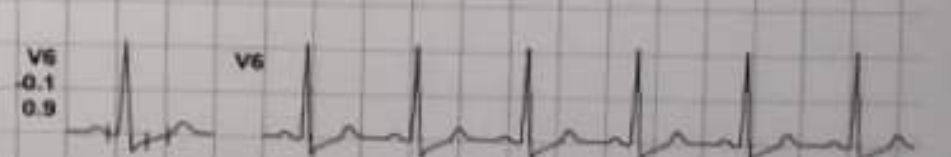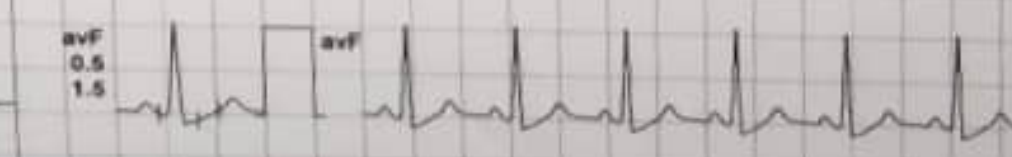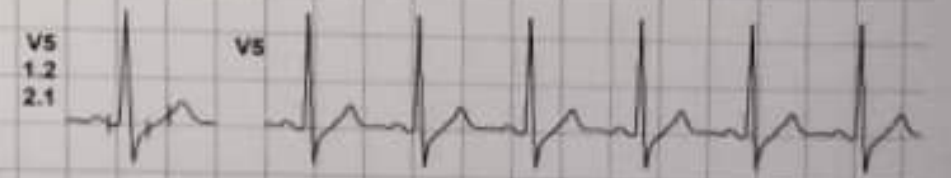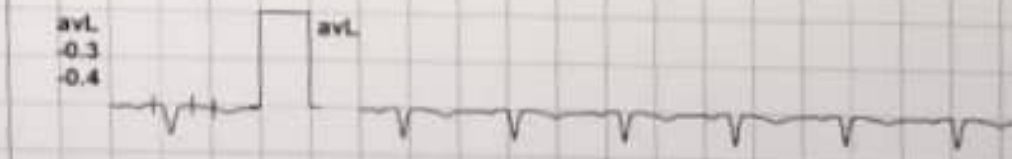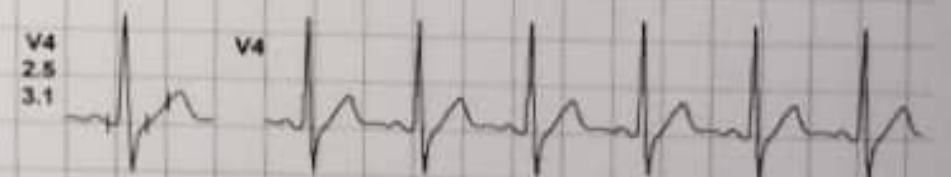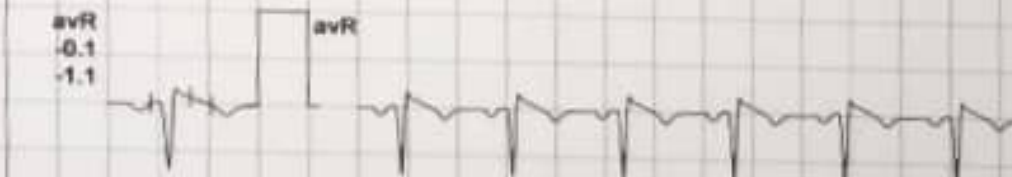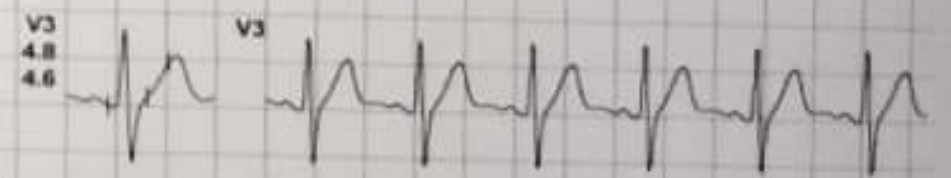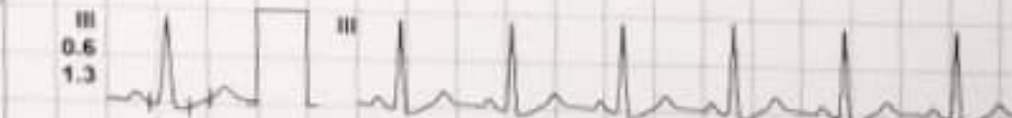
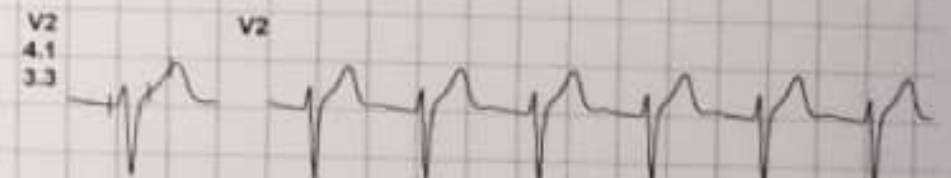
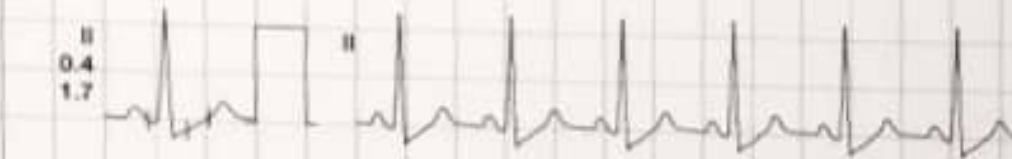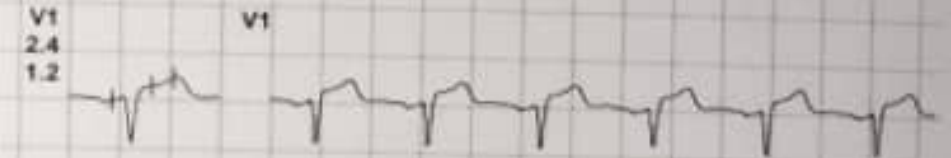
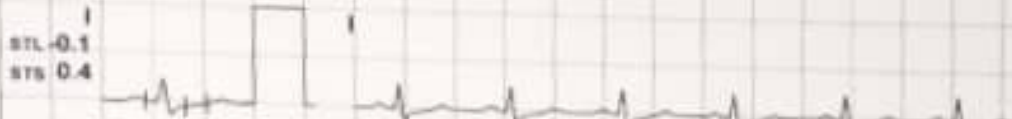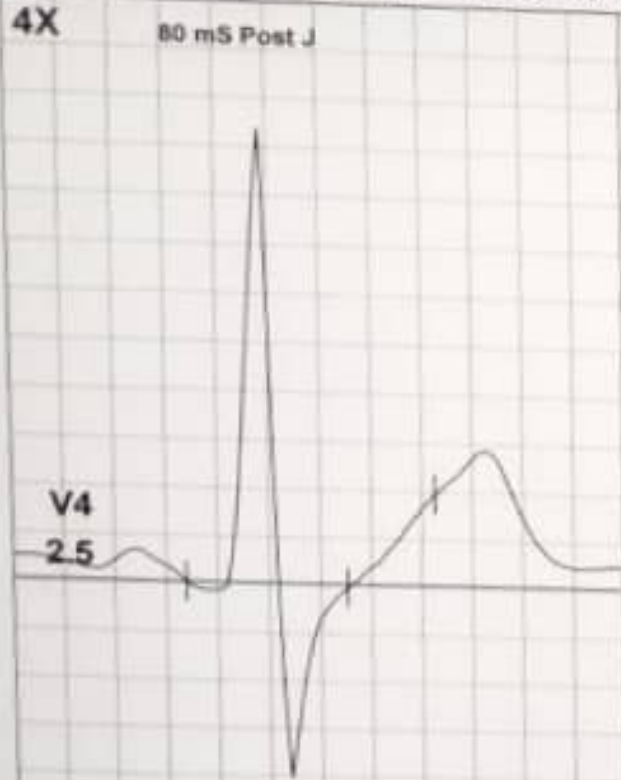
Doctor : Cardiologist



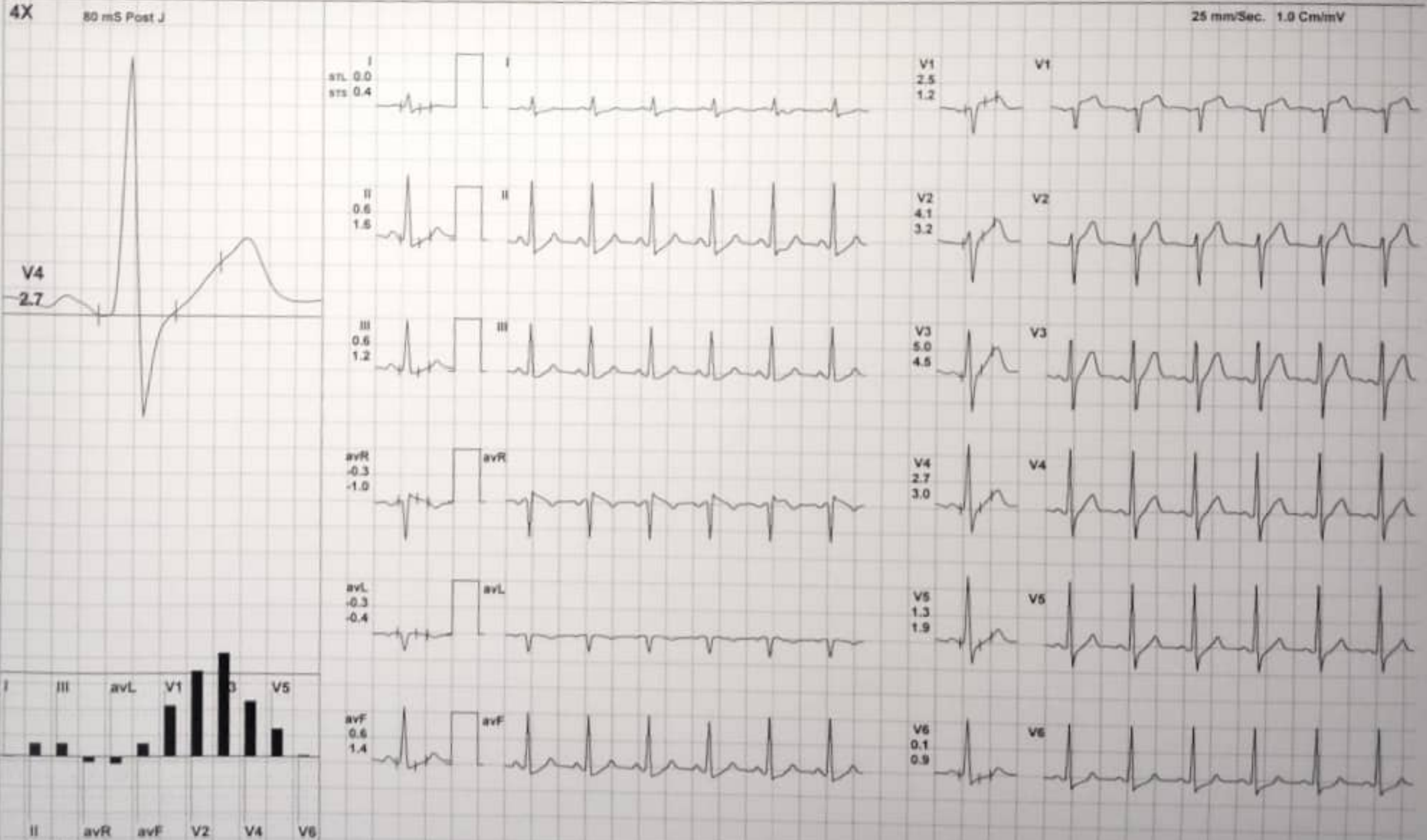
Date: 16-Nov-2023 10:47:07 AM METS: 1.0/ 109 bpm 58% of THR BP: 120/70 mmHg Raw ECG/ BLC On/ Notch On/ HF 0.05 Hz/LF 20 Hz

ExTime: 00:35 0.0 mph, 0.0%

25 mm/Sec. 1.0 Cm/mV



REMARKS:

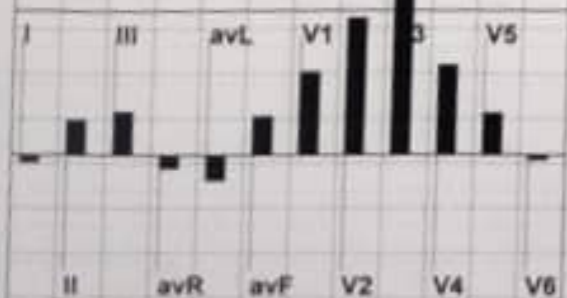
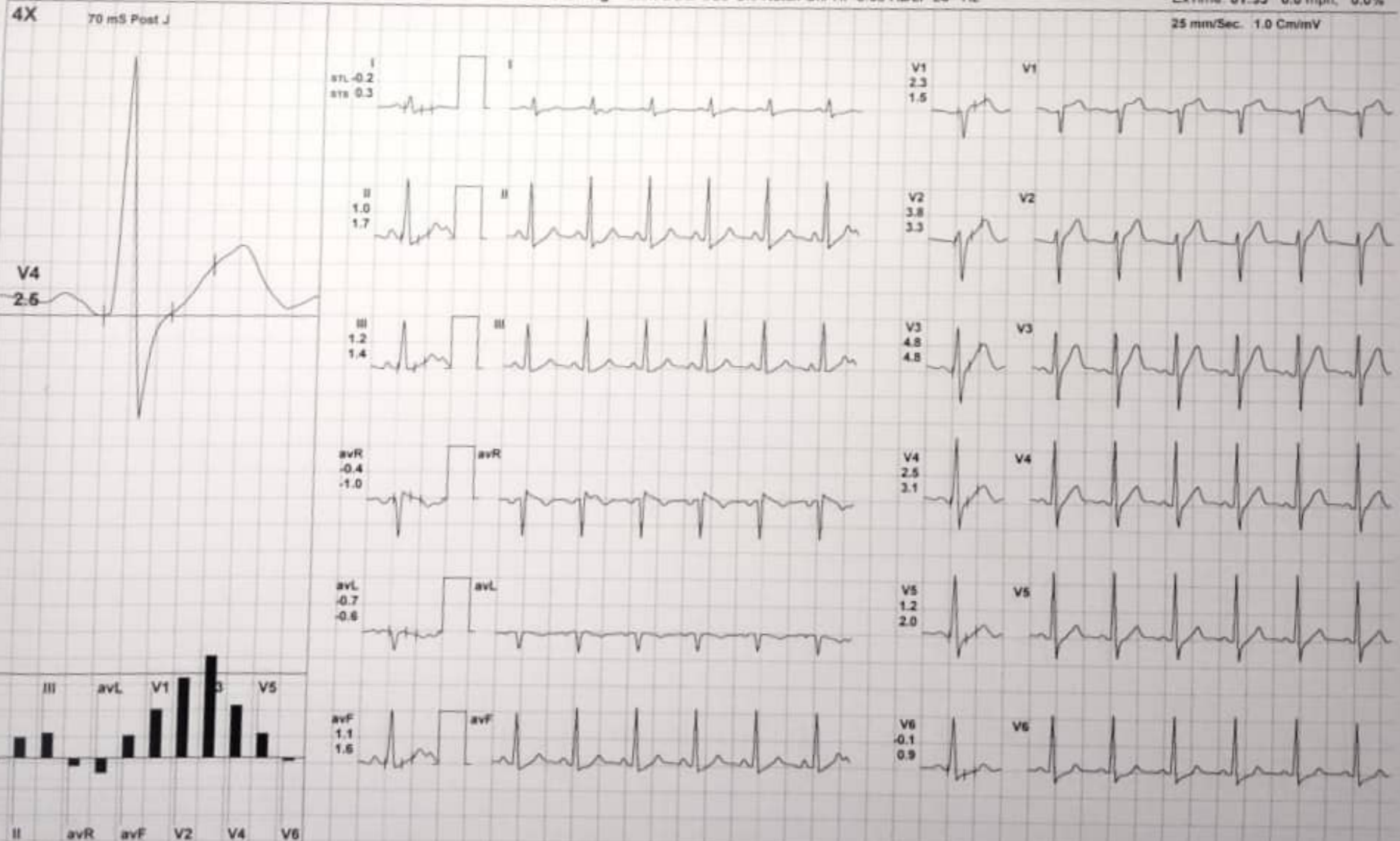


REMARKS:



Date: 16-Nov-2023 10:47:07 AM METS: 1.0/105 bpm 56% of THR BP: 120/70 mmHg Raw ECG/ BLC On/ Notch On/ HF 0.05 Hz/LF 20 Hz

ExTime: 01:33 0.0 mph, 0.0%



REMARKS:

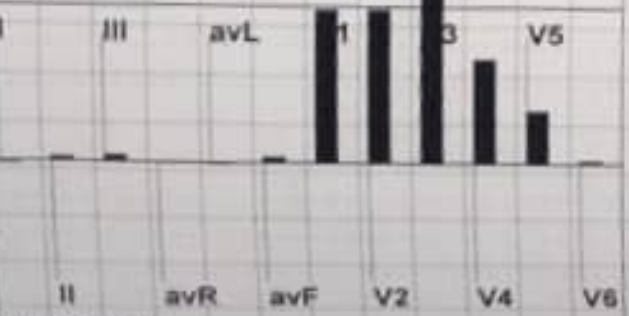
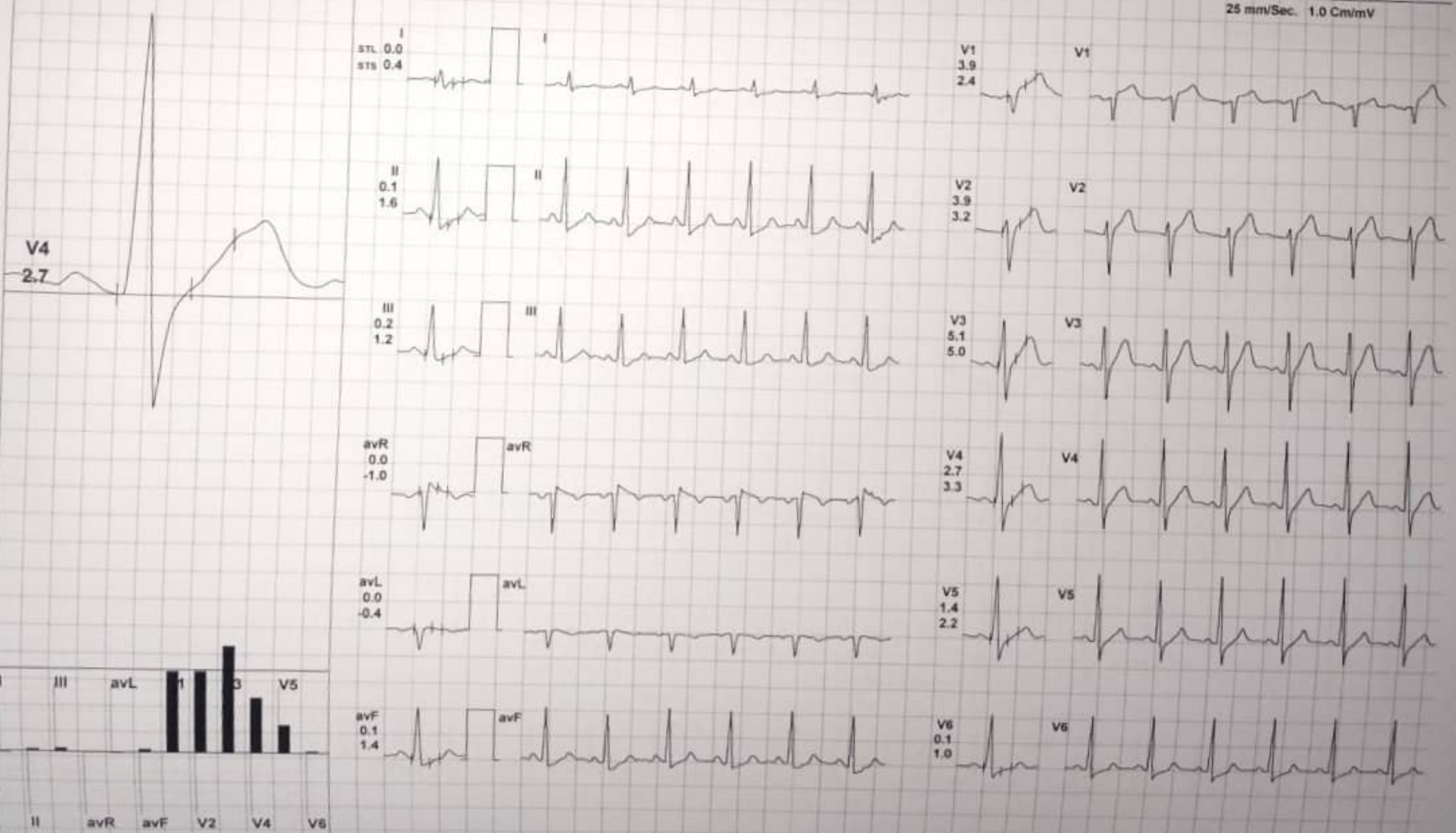


Date: 16-Nov-2023 10:47:07 AM METS: 1.0/ 104 bpm 55% of THR BP: 120/70 mmHg Raw ECG/ BLC On/ Notch On/ HF 0.05 Hz/LF 20 Hz

ExTime: 02:35 1.0 mph, 0.0%

25 mm/Sec. 1.0 Cm/mV

4X 70 mS Post J



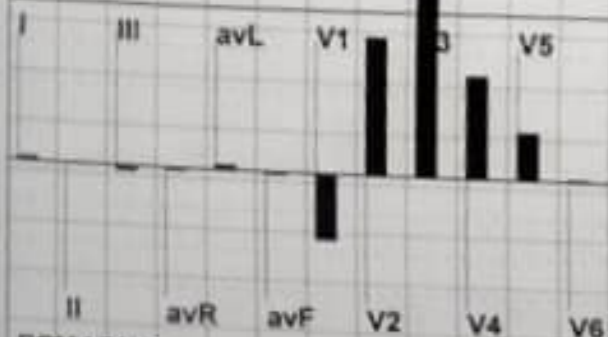
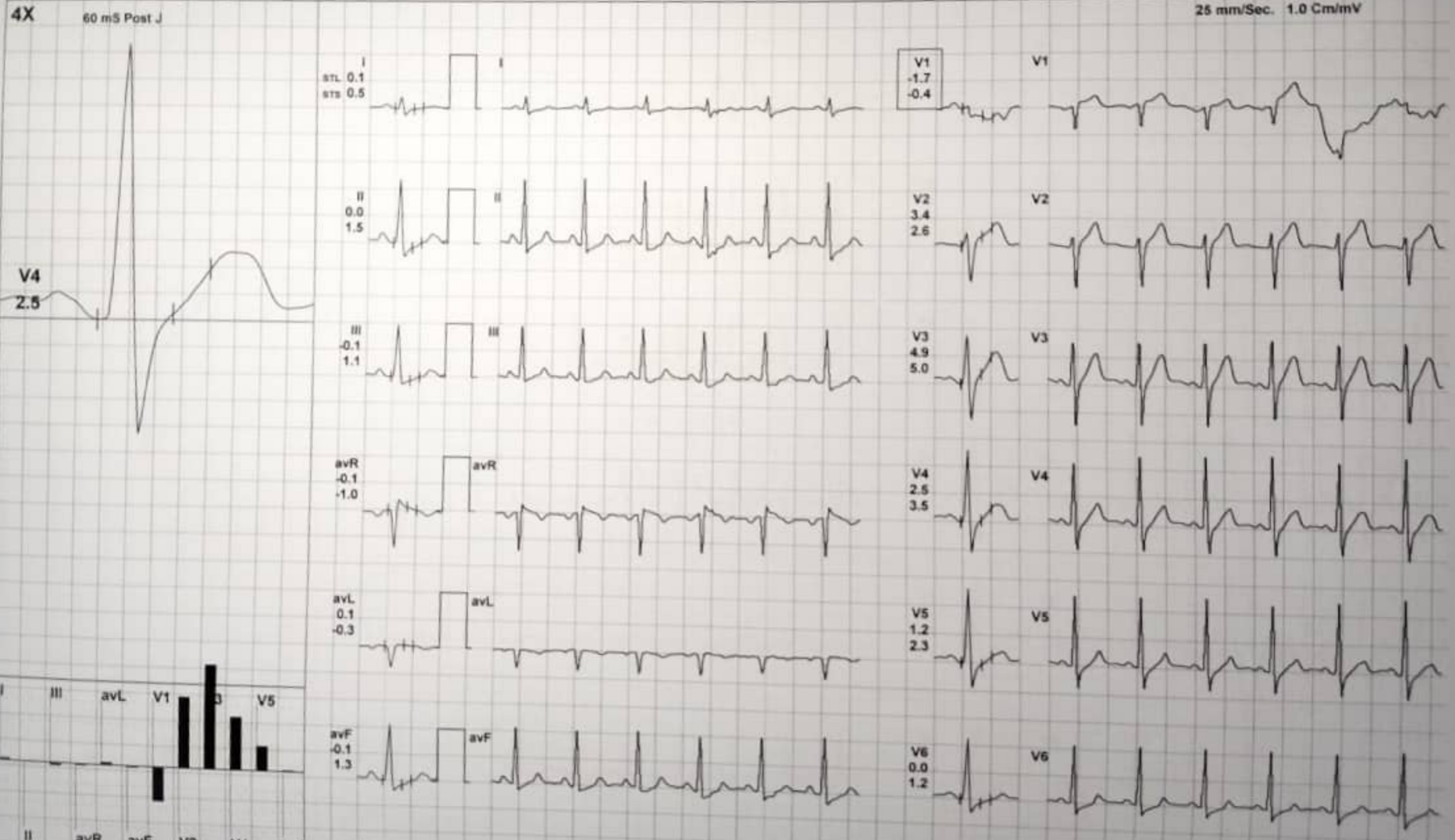
REMARKS:



82 / NITIN LEKHWANI / 33 Yrs / M

Date: 16-Nov-2023 10:47:07 AM METS: 1.0/ 113 bpm 60% of THR BP: 120/70 mmHg Raw ECG/ BLC On/ Notch On/ HF 0.05 Hz/LF 20 Hz

ExTime: 00:00 0.0 mph, 0.0%



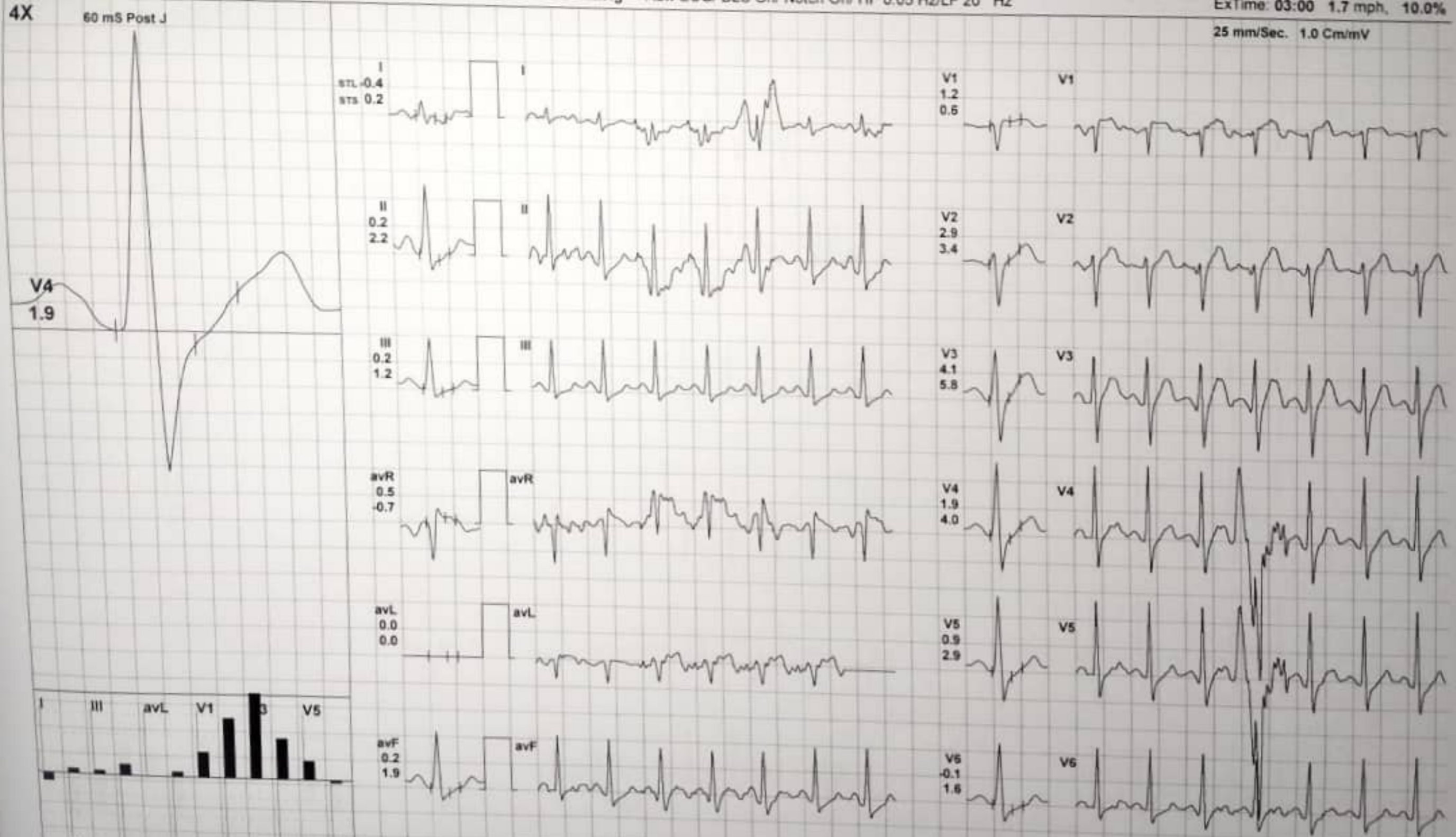
REMARKS:



Date: 16-Nov-2023 10:47:07 AM METS: 4.7/ 134 bpm 71% of THR BP: 128/79 mmHg Raw ECG/ BLC On/ Notch On/ HF 0.05 Hz/LF 20 Hz

ExTime: 03:00 1.7 mph, 10.0%

25 mm/Sec. 1.0 Cm/mV



REMARKS:



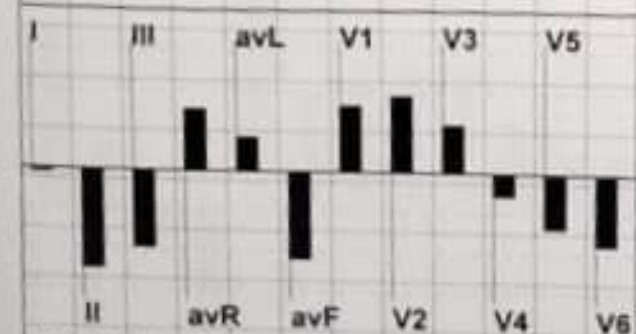
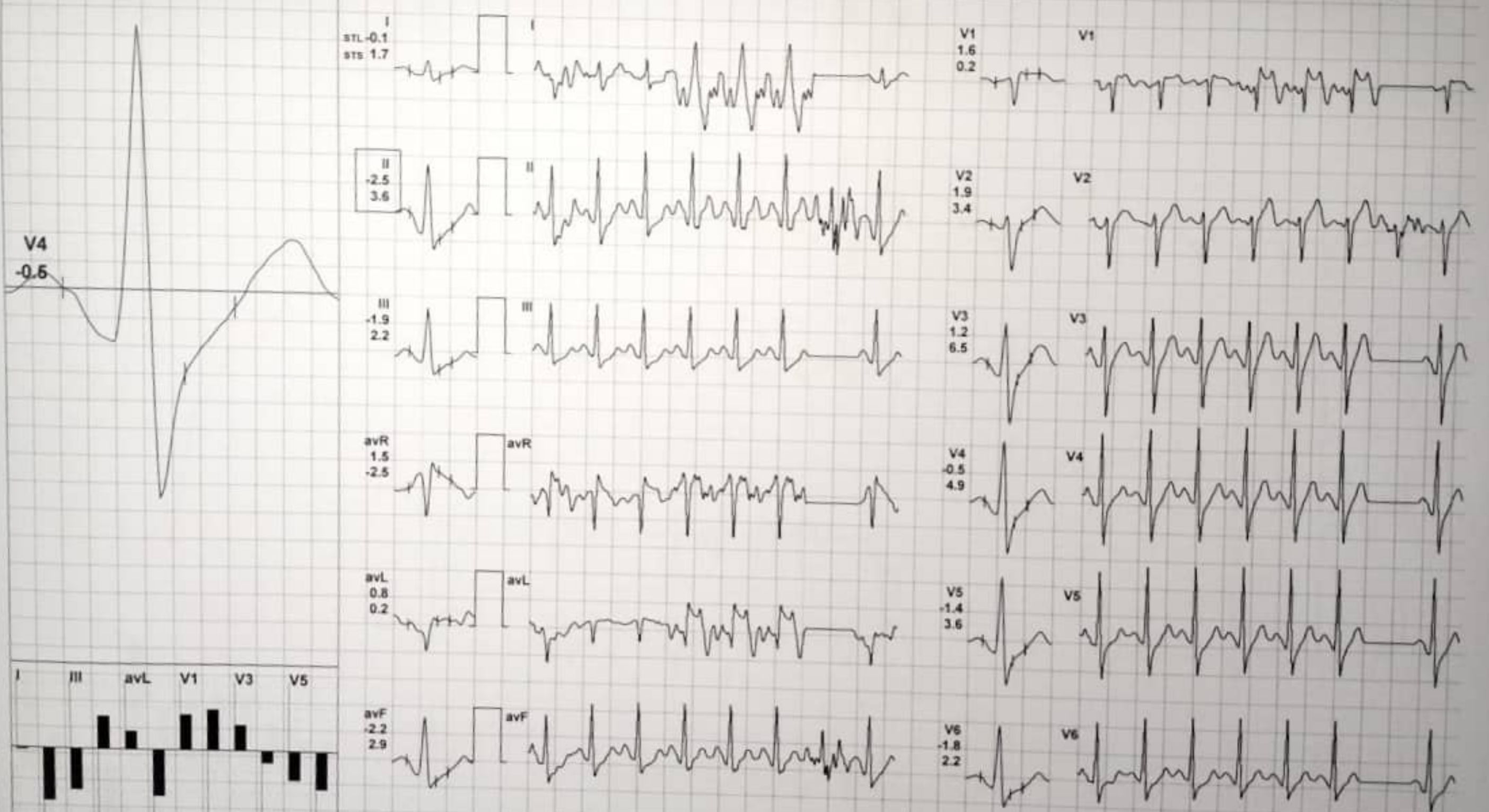
Date: 16-Nov-2023 10:47:07 AM

METS: 7.1/ 153 bpm 81% of THR BP: 134/88 mmHg Raw ECG/ BLC On/ Notch On/ HF 0.05 Hz/LF 20 Hz

ExTime: 06:00 2.5 mph, 12.0%

25 mm/Sec. 1.0 Cm/mV

4X 60 mS Post J



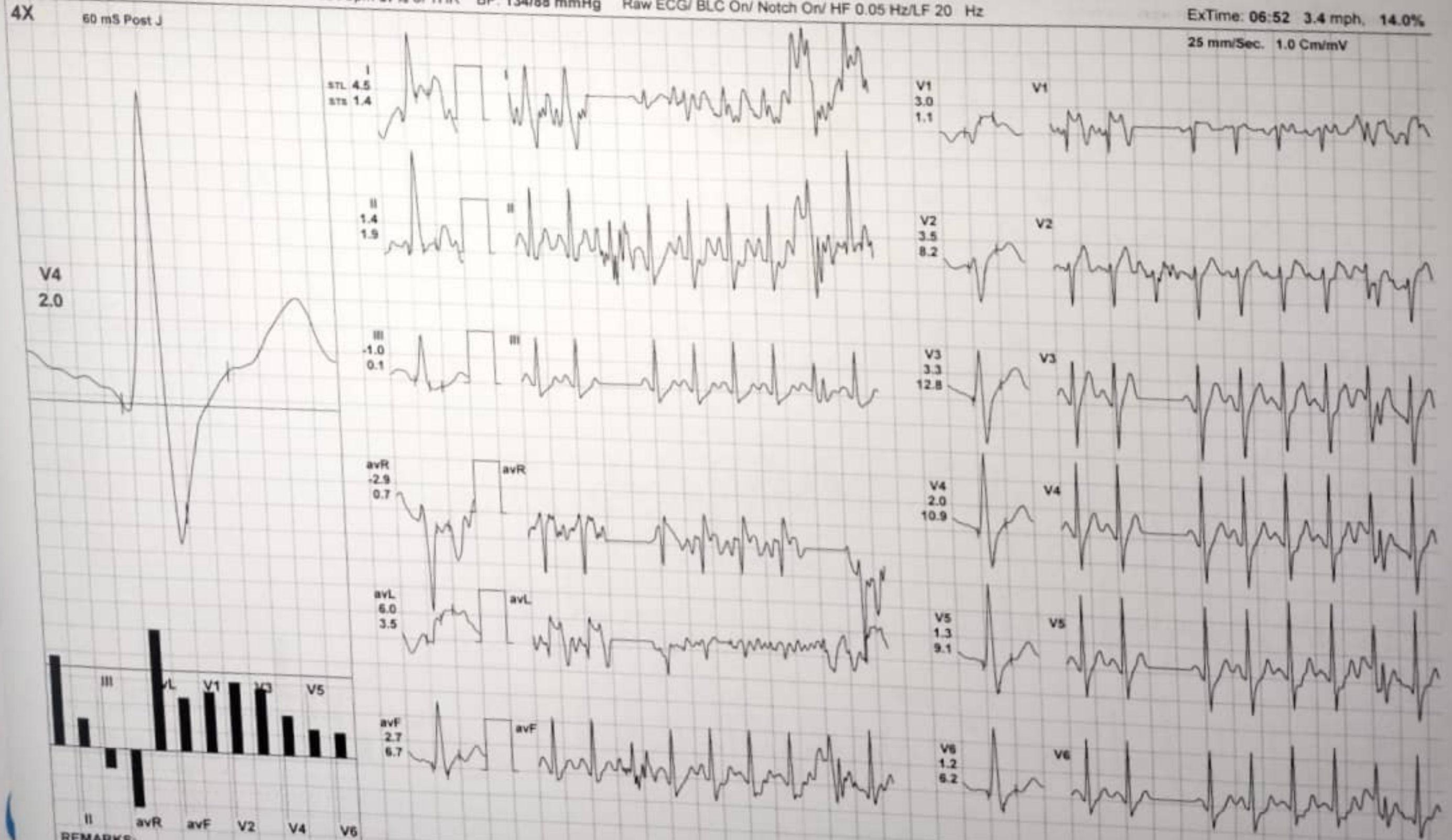REMARKS:



Date: 16-Nov-2023 10:47:07 AM METS: 8.0/ 164 bpm 87% of THR BP: 134/88 mmHg Raw ECG/ BLC On/ Notch On/ HF 0.05 Hz/LF 20 Hz

ExTime: 06:52 3.4 mph, 14.0%

25 mm/Sec. 1.0 Cm/mV



REMARKS:

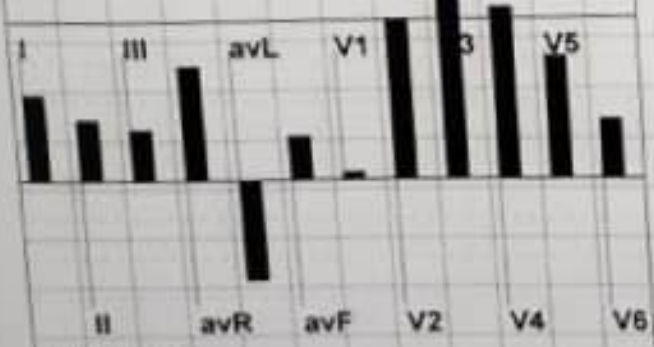
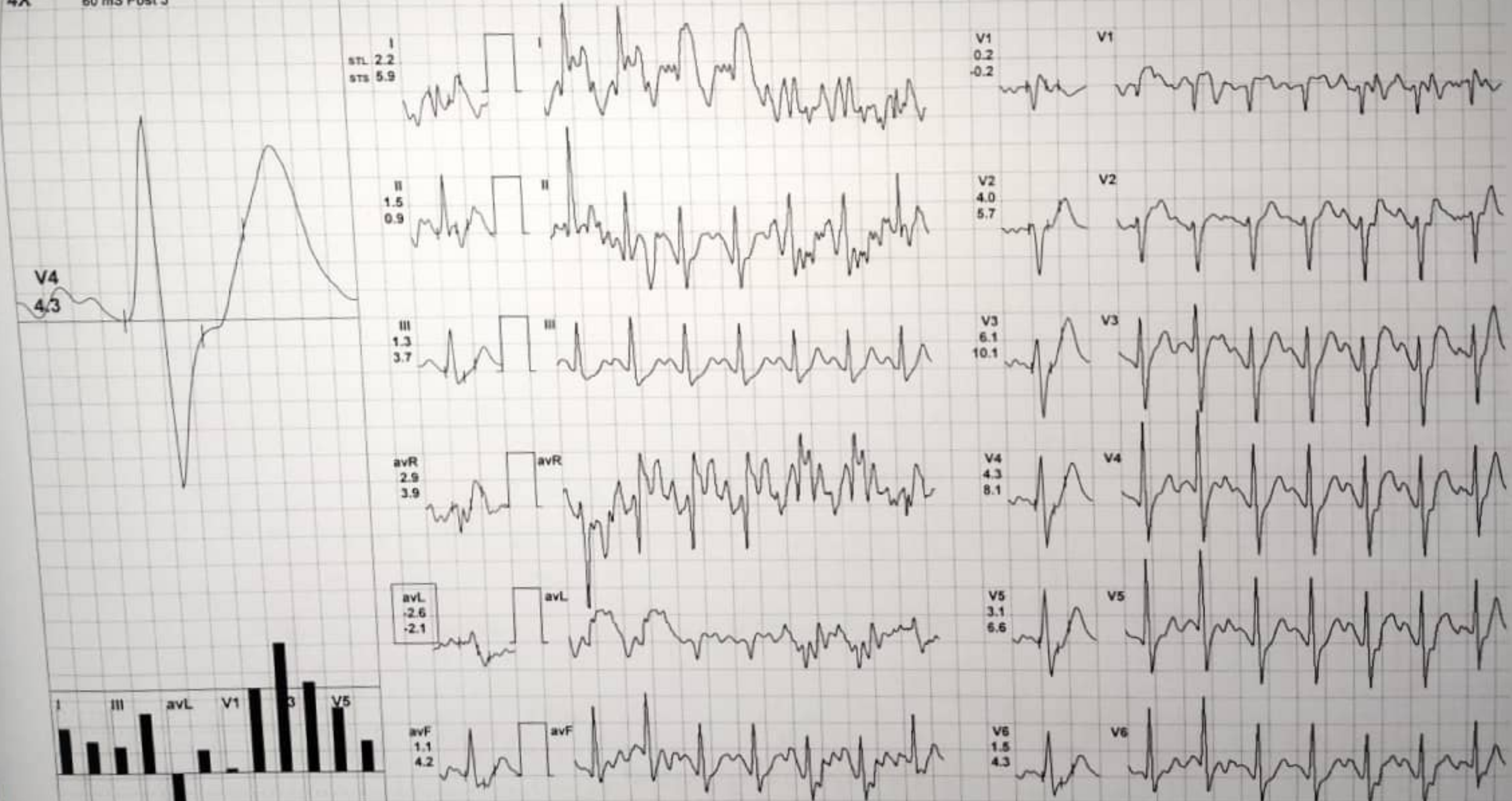


Date: 16-Nov-2023 10:47:07 AM METS: 1.1/ 140 bpm 74% of THR BP: 128/79 mmHg Raw ECG/ BLC On/ Notch On/ HF 0.05 Hz/LF 20 Hz

ExTime: 06:52 0.0 mph, 0.0%

25 mm/Sec. 1.0 Cm/mV

4X 60 mS Post J



REMARKS:



Date: 16-Nov-2023 10:47:07 AM

METS: 1.0/ 258 bpm 137% of THR

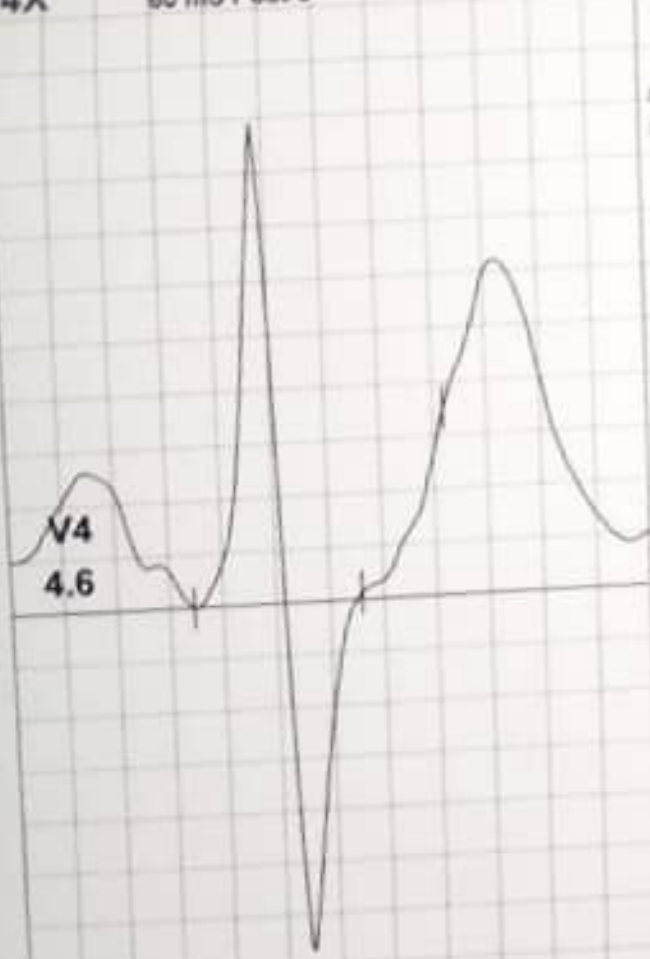
BP: 120/70 mmHg

Raw ECG/ BLC On/ Notch On/ HF 0.05 Hz/LF 20 Hz

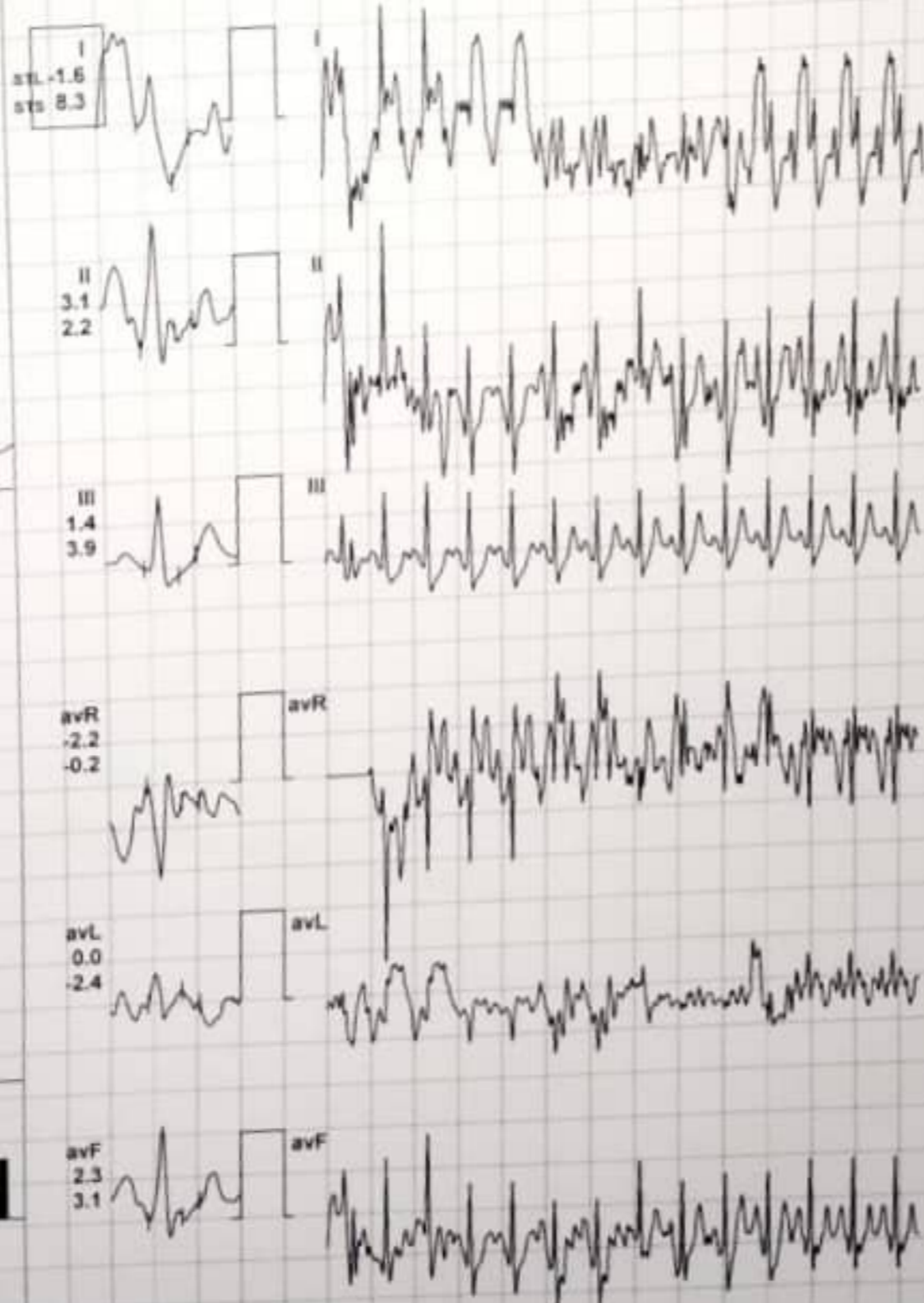ExTime: 06:52 0.0 mph, 0.0%

25 mm/Sec. 1.0 Cm/mV

4X 60 mS Post J



V4
4.6



I
STL -1.6
STs 8.3

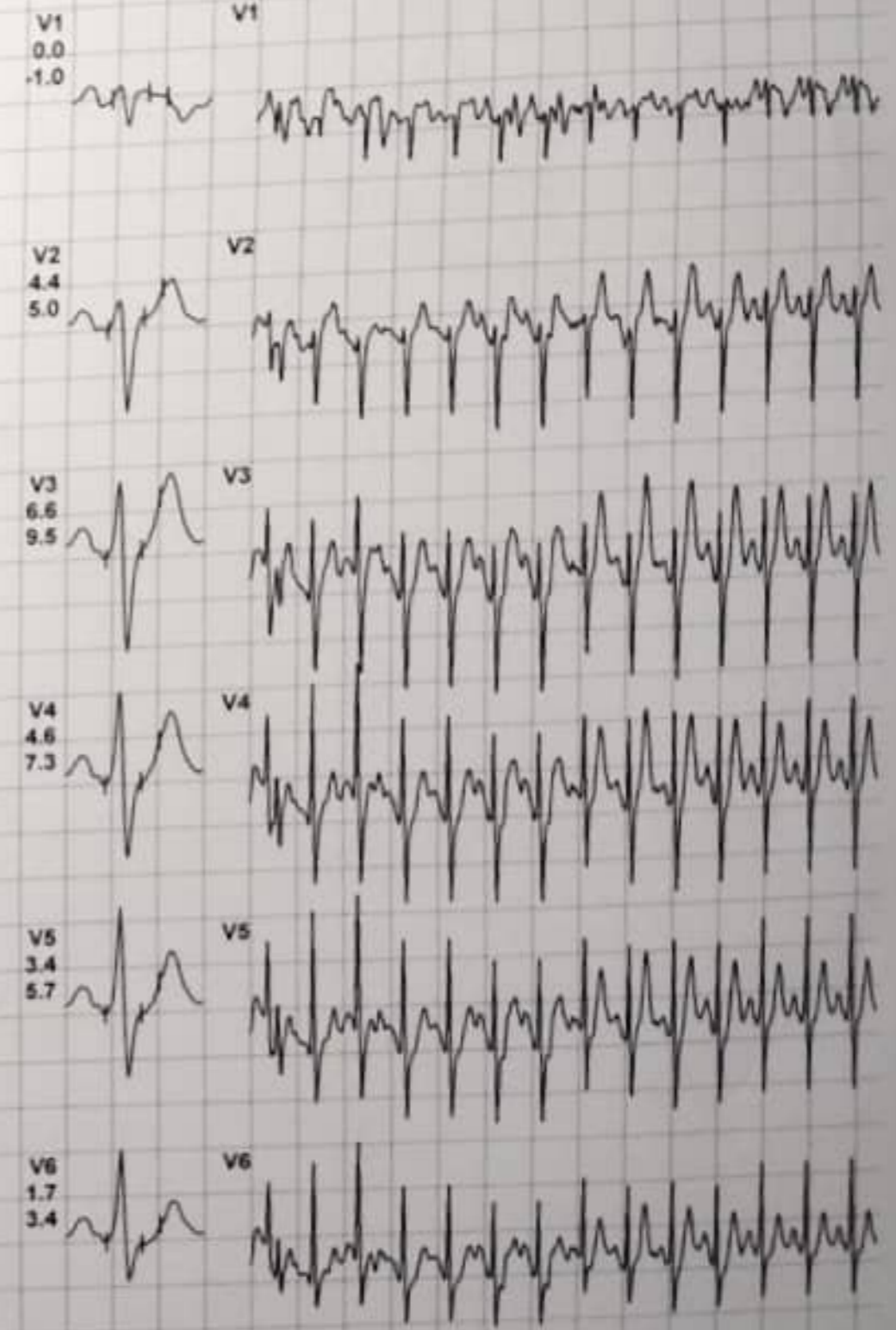
II
3.1
2.2

III
1.4
3.9

avR
-2.2
-0.2

avL
0.0
-2.4

avF
2.3
3.1



V1
0.0
-1.0

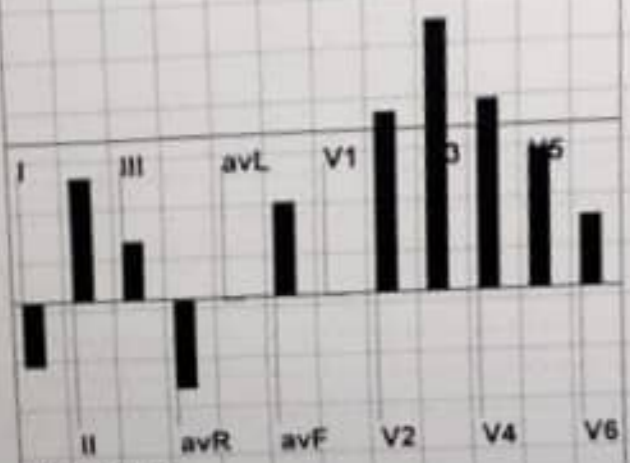
V2
4.4
5.0

V3
6.6
9.5

V4
4.6
7.3

V5
3.4
5.7

V6
1.7
3.4



REMARKS:

(GEM213180307)(A)Allengers



Diwakar Diagnostic Centre

पेथोलोजी | टी.एम्. | सी.जी. | एको कार्डियो ग्राफी | सोनोग्राफी



realme Shot by mayu ❤️



भारत निर्वाचन आयोग

ELECTION COMMISSION OF INDIA

मतदाता फोटो पहचान पत्र - ELECTOR PHOTO IDENTITY CARD



UKL2134989



निर्वाचक का नाम नितिन लेखवानी

ELECTOR'S NAME NITIN LEKHWANI

पिता का नाम जय लेखवानी

FATHER'S NAME JAI LEKHWANI