

CERTIFICATE OF MEDICAL FITNESS

This is to certify that I have conducted the clinical examination

of Mrs Geetha C on 21/11/23

After reviewing the medical history and on clinical examination it has been found that he/she is

	Tick
<ul style="list-style-type: none"> Medically Fit 	✓
<ul style="list-style-type: none"> Fit with restrictions/recommendations <p>Though following restrictions have been revealed, in my opinion, these are not impediments to the job.</p> <p>1. <u>Vision correction of Both eyes</u></p> <p>2. <u>& Distance vision</u></p> <p>3.</p> <p>However the employee should follow the advice/medication that has been communicated to him/her.</p> <p>Review after _____</p>	
<ul style="list-style-type: none"> Currently Unfit. <p>Review after _____ recommended</p>	
<ul style="list-style-type: none"> Unfit 	

Dr. [Signature]
Medical Officer
The Apollo Clinic, Mysore

Apollo Clinic
23, 1st Floor,
Kaldasa Road, Mysore - 02
Ph : 0821-40060147

This certificate is not meant for medico-legal purposes

Apollo Health and Lifestyle Limited
CIN: U85110TG2000PLC1158191
Regd. Office: T-10-63 E2, Ashoka Kaghupathi Chambers, 5th Floor, Begumpet, Hyderabad, Telangana - 500 016
Ph: +91-040-4604 7777 Fax No: 4904 7744 | Email ID: enquiry@apollohl.com | www.apollohl.com

APOLLO CLINICS NETWORK KARNATAKA
Bangalore | Basavanagudi | Bellandur | Electronic City | Fraser Town | HSR Layout | Indira Nagar | JP Nagar | Kundalahalli | Koramangala | Sarjapur Road | Mysore (VV Mohalla)

Online appointments: www.apolloclinic.com

TO BOOK AN APPOINTMENT
1860 500 7788

Date : 29-11-2023
MR NO : CMYS.0000058679

Department : GENERAL
Doctor : Dr Umur #62

Name : Mrs. C GEETHA

Registration No : 67084

Age/ Gender : 46 Y / Female

Qualification : MBBS- MD

Consultation Timing: 08:07

Height :	Weight :	BMI :	Waist Circum :
Temp :	Pulse :	Resp :	B.P :

General Examination /
Allergies History

Clinical Diagnosis & Management Plan

Vision

RT Eye

Lt Eye

Far vision

$\frac{6}{6}$ - 6 glasses

$\frac{6}{18}$ glasses

near vision

N-12 glasses

N-6 glasses

Color vision - Normal

C/S
as
MD

Vot 23

Follow up date :


Doctor Signature

Apollo Clinic
23, 1st Floor,
Kalidasa Road, Mysore - 02
Ph : 0821-4006040/41

Date : 29-11-2023
 MR NO : CMYS.0000058679
 Name : Mrs. C GEETHA
 Age/ Gender : 46 Y / Female

Department : GENERAL
 Doctor :
 Registration No : Dr. Praveen Kumar P
 Qualification : M.S (ENT)

Consultation Timing: 08:07

Height :	Weight :	BMI :	Waist Circum :
Temp :	Pulse :	Resp :	B.P :

General Examination /
 Allergies History

Clinical Diagnosis & Management Plan

Came for regular health checkup

Ear Bilateral G.M. Normal

Nose. nasal mucosa. Normal

oral cavity & oropharynx. Normal

neck Normal

As - recurrent

Follow up date :

Doctor Signature
Apollo Clinic
 # 23, 1st Floor,
 Kalidasa Road, Mysore - 02
 Ph : 0821-4006000/41

Date : 29-11-2023
 MR NO : CMYS.0000058679
 Name : Mrs. C GEETHA
 Age/ Gender : 46 Y / Female

Department : GENERAL
 Doctor :
 Registration No :
 Qualification :

Consultation Timing: 08:07

Height :	Weight :	BMI :	Waist Circum :
Temp :	Pulse :	Resp :	B.P :

General Examination /
 Allergies History
 FH → AS.
 FH → AS.

Clinical Diagnosis & Management Plan

MH → menopause 1yr.
 Adv: regular walk / yoga.
 avoid junk food.

ML → 21yrs. B12 -
 I & II
 FND.
 III - US
 not ambulatory

SAB - SHELUAL ISO 0-7-0 x6cm

Follow up date :

[Signature]
 Doctor Signature
Apollo Clinic
 # 23, 1st Floor,
 Kalidasa Road, Mysore - 02
 Ph : 0821-4006040/41

Date : 29-11-2023
 MR NO : CMYS.0000058679
 Name : Mrs. C GEETHA
 Age/ Gender : 46 Y / Female

Department : GENERAL Dietetics
 Doctor : Madhura . B. P

Registration No :
 Qualification : M.Sc Nutrition & Dietetics
 PHD*

Consultation Timing: 08:07

IBW - 49kg

Height : 149	Weight : 56kg	BMI : 25 kg/m ²	Waist Circum :
Temp :	Pulse :	Resp :	B.P :

General Examination /
 Allergies History

Clinical Diagnosis & Management Plan

- => Advised Balanced diet with protein rich foods.
- => Take small frequent meals. Do not skip meals
- => Include all variety of seasonal fruits, vegetables and green leafy vegetables regularly.
- => Include nuts like Almonds, walnuts and dry-fruits like dried dates & raisins.
- => Include seeds like flax seeds, pumpkin seed, sunflower seeds, sesame seeds and watermelon seeds - 1 teaspoon each, dry roasted.
- => Avoid maida, sugar, too much of salt, baking soda & creams.
- => Cooking oil - 1/2 litre / person / month.

Follow up date :

Doctor Signature
 Madhura . B. P
 29/11/2023

Apollo Clinic
 # 23, 1st Floor,
 Kalidasa Road, Mysore - 02
 Ph : 0821-4006010/41

Date : 29-11-2023
MR NO : CMYS.0000058679

Department : GENERAL Dental
Doctor : Dr. Jyothishree

Name : Mrs. C GEETHA
Age/ Gender : 46 Y / Female

Registration No :
Qualification :

Consultation Timing: 08:07

Height :	Weight :	BMI :	Waist Circum :
Temp :	Pulse :	Resp :	B.P :

General Examination /
Allergies History

Clinical Diagnosis & Management Plan

O/E

Genl. health condition noted

cat, sth

Adv:- To maintain
stress

Follow up date :

Syo Nishy

Doctor Signature

Apollo Clinic
23, 1st Floor,
Kalidasa Road, Mysore - 02
Ph : 0821-4006040/41

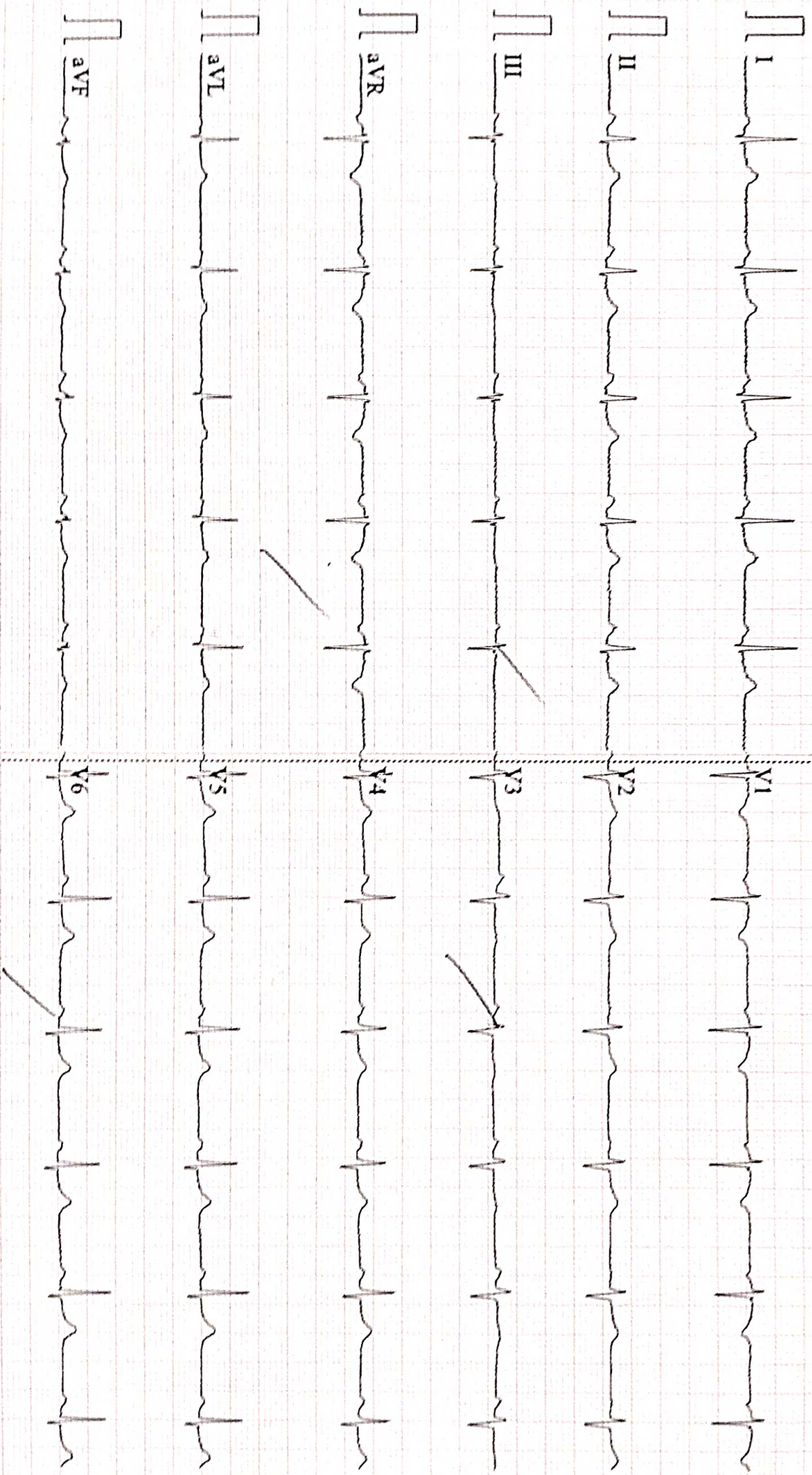
ID: 58679
MRS C GBETHA
Female 46Years
149cm 56kg 110/80 mmHg

29-11-2023 08:45:35 AM

Diagnosis Information:

Unconfirmed Report.

Apollo Clinic
23, 1st Floor,
Kallidasa Road, Mysore - 02
Ph : 0821-4006040/41



Patient Name	: Mrs. C GEETHA	Age	: 46 Y F
UHID	: CMYS.0000058679	OP Visit No	: CMYSOPV119773
Reported on	: 29-11-2023 15:39	Printed on	: 29-11-2023 15:40
Adm/Consult Doctor	:	Ref Doctor	: SELF

DEPARTMENT OF RADIOLOGY

X-RAY CHEST PA

Both lung fields and hila are normal .
No obvious active pleuro-parenchymal lesion seen .
Both costophrenic and cardiophrenic angles are clear .
Both diaphragms are normal in position and contour .
Thoracic wall and soft tissues appear normal.

IMPRESSION :NORMAL STUDY.



Pradeep

Printed on:29-11-2023 15:39

---End of the Report---

Dr. PRADEEP KUMAR C N
MBBS DNB(RADIOLOGY)
Radiology

Apollo Health and Lifestyle Limited

(CIN : U65110TG2000PLC115819)
Regd Office : 110-69-62 Ashoka Raghupathi Chambers, 5th Floor, Begumpet, Hyderabad, Telangana - 500 016
Ph: No. (040) 4904 7777 Fax No. 4904 7744 | Email ID: enquiry@apollohl.com | www.apollohl.com

APOLLO CLINICS NETWORK KARNATAKA

Bangalore | Sasavanasudi | Bellandur | Electronic City | Fraser Town | HSR Layout | Indira Nagar | JP Nagar | Kundalahalli |
Koramangala | Sarjapur Road | **Mysore** (VV Mohalla)

Online appointments: www.apolloclinic.com

TO BOOK AN APPOINTMENT

 **1860 500 7788**

Patient Name: Mrs Geetha C	Date : 29.11.2023.	Referring Doctor: Dr .Self
Age / Sex: 46Yrs/Female	UHID NO:58679	Location : OP
ULTRASONOGRAPHY- ABDOMEN & PELVIS		

LIVER: It is normal in size and echotexture. No focal lesions seen. IHBR are not dilated. CBD and Portal vein are normal.

GALL BLADDER: It is well distended and normal. No calculi seen.

SPLEEN: It is normal in size, outline and echopattern. No e/o focal lesions.

PANCREAS: It is normal.

RIGHT KIDNEY: It measures 97x42 mm with parenchymal thickness of 14mm. It is normal in size, outline and echotexture. No e/o calculus or hydronephrosis seen. Not seen in right renal fossa but seen in pelvis.

LEFT KIDNEY: It measures 105x45 mm with parenchymal thickness of 12 mm. It is normal in size, outline and echotexture. No e/o calculus or hydronephrosis seen.

URINARY BLADDER: It is well distended. The UB wall is normal. No calculi seen.

UTERUS: It is anteverted and measures 69x42x52mm with ET=06 mm. It is normal in size, outline and echotexture. **Small hypoechoic lesion measuring 17x16 mm seen in posterior wall.**

Rt. OVARY: It measures 27x24 mm. It is normal. No mass lesion seen.

Lt. OVARY: It measures 24x30 mm. It is normal. No mass lesion seen.

RIF: No evidence of focal collection or mass lesion seen. Appendix is not visualized.

OTHERS: No e/o free fluid in the abdomen. No e/o lymphadenopathy. No e/o gut wall thickening. No mass lesion seen in the abdomen.

IMPRESSION: ECTOPIC RIGHT KIDNEY; SMALL POSTERIOR WALL FIBROID.

pradeep

Dr. Pradeep Kumar C N, DNB
Apollo Health and Lifestyle Limited
Consultant Radiologist.

Regd. Office: 110/60/62 Ashoka Raghupathi Chambers, 5th Floor, Begumpet, Hyderabad, Telangana - 500 016
Ph: (+91) 94484 7777 Fax No: 4904 7744 | Email ID: enquiry@apollohl.com | www.apollohl.com

APOLLO CLINICS NETWORK KARNATAKA

Bangalore: Basavanagudi | Bellandur | Electronic City | Fraser Town | HSR Layout | Indira Nagar | JP Nagar | Kundalahalli |
Koramangala | Marjapur Road | Mysore (VV Mohalla)

Online appointments: www.apolloclinic.com

TO BOOK AN APPOINTMENT

1860 500 7788

Patient Name: Mrs. C Geetha	Date : 29.11.2023	Referring Doctor: Dr. Self
Age / Sex: 46 Yrs/Female	UHID No : 58679	Location : OP
ULTRASONOGRAPHY- BREAST		

RIGHT BREAST: It is normal in echopattern. No e/o focal nodular or mass lesions seen. No e/o calcifications. The skin over the breast is normal. Nipple and areola are normal. The subcutaneous, mammary and retro mammary zones are normal.

LEFT BREAST: It is normal in echopattern. No e/o focal nodular or mass lesions seen. No e/o calcifications. The skin over the breast is normal. Nipple and areola are normal. The subcutaneous, mammary and retro mammary zones are normal.

No e/o axillary lymphadenopathy.

IMPRESSION: NORMAL STUDY.

Pradeep
Dr. Pradeep Kumar C N, DNB.
Consultant Radiologist.

Apollo Health and Lifestyle Limited

CIN: U65110TG2000PLC115R191
Regd Office: 1-10 RD 62 Ashoka Raghupathi Chambers 5th Floor Begumpet Hyderabad Telangana - 500 016
Ph: (+91) 404 4804 7777 Fax No: 4904 7744 | Email ID: enquiry@apollohi.com | www.apollohi.com

APOLLO CLINICS NETWORK KARNATAKA
Bangalore | Basavanagudi | Bellandur | Electronic City | Fraser Town | HSR Layout | Indira Nagar | JP Nagar | Kundalahalli |
Kolar | Marjalahalli | Sarjapur Road | Mysore (VV Mohalla)

Online appointments: www.apolloclinic.com

TO BOOK AN APPOINTMENT

1860 500 7788

Patient's Name : Mrs. C Geetha	Age & sex : 46Yrs / Female
Date : 29.11.2023	UHID No 58679

2D ECHOCARDIOGRAPHY STUDY

Impression:

- Normal chamber volumes
- Normal biventricular function. LVEF 63%
- No regional wall motion abnormalities
- No clots. No pericardial effusion

Findings

Left Ventricle:	Normal
Right Ventricle	Normal
Left Atrium	Normal
Right Atrium	Normal
Aorta	Normal
Pulmonary Artery	Normal
IAS	Intact
IVS	Intact
Valves	Normal
Pericardium	Normal
Doppler	Trivial TR


Dr. C.B. KESHAVAMURTHY MD, DM, DNB
CONSULTANT CARDIOLOGIST

Apollo Health and Lifestyle Limited

CIN: UAS110TG2000PLC115819
Regd. Office: 1-10-60-62 Ashoka Raghupathi Chambers, 5th Floor, Begumpet, Hyderabad, Telangana - 500 016
Ph: No. 044-434 7777 Fax No. 4964 7744 | Email ID: enquiry@apollohi.com | www.apollohi.com

APOLLO CLINICS NETWORK KARNATAKA

Bangalore: Basavanagudi | Bellandur | Electronic City | Frazer Town | HSR Layout | Indira Nagar | JP Nagar | Kundalahalli | Koramangala | Sarajpet Road | Mysore: (VV Mohalla)

Online appointments: www.apolloclinic.com

TO BOOK AN APPOINTMENT

 **1860 500 7788**

Patient's Name : Mrs. C Geetha	Age & sex : 46Yrs / Female
Date : 29.11.2023	UHID No 58679

Measurements

AO : 2.33 cm
LA : 2.72 cm

RV : 1.70 cm
LVIDd : 3.75 cm
LVIDs : 2.48 cm
IVSd : 1.02 cm
IVSs : 1.33 cm
PWd : 0.98 cm
PWs : 1.24 cm
EF : 63.0 %
FS : 33.0 %

Doppler

MV	TV	AV	PV
E : 0.91 m/s	E 0.50 m/s	V max 1.20 m/s	V max 0.88 m/s
A : 0.48 m/s	A 0.43 m/s		
MR Nil	TR 1/4	AR Nil	PR Nil



Dr. C.B. KESHAVAMURTHY MD, DM, DNB
CONSULTANT CARDIOLOGIST

Apollo Health and Lifestyle Limited

(CIN: U65110TG2000PLC115819)
Regd. Office: 1-10-60-62, Ashoka Raghupathi Chambers, 5th Floor, Begumpet, Hyderabad, Telangana - 500 016
Ph. No: (040) 4904 7777 Fax No: 4904 7744 | E-mail ID: enquiry@apollohi.com | www.apollohi.com

APOLLO CLINICS NETWORK KARNATAKA
Bangalore | Basavanagudi | Bellandur | Electronic City | Fraser Town | HSR Layout | Indira Nagar | JP Nagar | Kundalahalli |
Koramangala | Sarjapur Road | Mysore (VV Mohalla)

Online appointments: www.apolloclinic.com

TO BOOK AN APPOINTMENT

1860 500 7788

Name: Mrs. C GEETHA
Age/Gender: 46 Y/F
Address: MYSORE
Location: MYSORE, KARNATAKA
Doctor:
Department: GENERAL
Rate Plan: MYSORE_06042023
Sponsor: ARCOFEMI HEALTHCARE LIMITED
Consulting Doctor: Dr. SABAH JAVED

MR No: CMYS.0000058679
Visit ID: CMYSOPV119773
Visit Date: 29-11-2023 08:07
Discharge Date:
Referred By: SELF

HT-CHIEF COMPLAINTS AND PRESENT KNOWN ILLNESS

Chief Complaints

COMPLAINTS:::: **For Corporate Health Checkup,**

Present Known Illness

Diabetes Mellitus: **No History of Diabetes Mellitus,**

Hypertension: **No History of Hypertension,**

Heart disease: **No History of Ischeamic Heart Disease,**

SYSTEMIC REVIEW

****Weight**

--->: **Stable,**

Number of kgs: **64,**

HT-HISTORY

Past Medical History

PAST MEDICAL HISTORY: **Nil Significant,**

Cancer: **NIL,

PHYSICAL EXAMINATION

PHYSICAL EXAMINATION

Constitutional: **Normal ,**

Eyes: **Normal ,**

ENT: **Normal ,**

Cardiovascular: **Normal ,**

Respiratory: **Normal ,**

Gastrointestinal: **Normal ,**

Genitourinary: **Normal ,**

Musculoskeletal: **Normal ,**

Integumentary: **Normal ,**

Neurological: **Normal ,**

Psychiatric: **Normal** ,

Endocrine: **Normal** ,

Hematologic/Lymphatic/Immuno: **Normal** ,

Allergic/Immunologic: **Normal** ,

SYSTEMIC EXAMINATION

IMPRESSION

Ultrasound Radiology

: **NORMAL**,

ECG

: **NORMAL**,

X-Ray

: **NORMAL**,

RECOMMENDATION

Fitness Report

Fitness.: **YES**,

DISCLAIMER

Disclaimer: **The health checkup examinations and routine investigations have certain limitations and may not be able to detect all the diseases. Any new or persisting symptoms should be brought to the attention of the consulting physician. Additional tests, consultations and follow up may be required in some cases.,**

Doctor's Signature

Patient Name	: Mrs. C GEETHA	Age/Gender	: 46 Y/F
UHID/MR No.	: CMYS.0000058679	OP Visit No	: CMYSOPV119773
Sample Collected on	:	Reported on	: 29-11-2023 15:40
LRN#	: RAD2163186	Specimen	:
Ref Doctor	: SELF		
Emp/Auth/TPA ID	: 630176		

DEPARTMENT OF RADIOLOGY

X-RAY CHEST PA

Both lung fields and hila are normal .


No obvious active pleuro-parenchymal lesion seen .

Both costophrenic and cardiophrenic angles are clear .

Both diaphragms are normal in position and contour .

Thoracic wall and soft tissues appear normal.

IMPRESSION :NORMAL STUDY.



Dr. PRADEEP KUMAR C N
MBBS DNB(RADIOLOGY)
Radiology

Patient Name	: Mrs. C GEETHA	Age/Gender	: 46 Y/F
UHID/MR No.	: CMYS.0000058679	OP Visit No	: CMYSOPV119773
Sample Collected on	:	Reported on	: 29-11-2023 09:51
LRN#	: RAD2163186	Specimen	:
Ref Doctor	: SELF		
Emp/Auth/TPA ID	: 630176		

DEPARTMENT OF RADIOLOGY

ULTRASOUND - WHOLE ABDOMEN

LIVER: It is normal in size and echotexture. No focal lesions seen. IHBR are not dilated. CBD and Portal vein are normal.

GALL BLADDER: It is well distended and normal. No calculi seen.

SPLEEN: It is normal in size, outline and echopattern. No e/o focal lesions.

PANCREAS: It is normal.

RIGHT KIDNEY: It measures 97x42 mm with parenchymal thickness of 14mm. It is normal in size, outline and echotexture. No e/o calculus or hydronephrosis seen. **Not seen in right renal fossa but seen in pelvis.**

LEFT KIDNEY: It measures 105x45 mm with parenchymal thickness of 12 mm. It is normal in size, outline and echotexture. No e/o calculus or hydronephrosis seen.

URINARY BLADDER: It is well distended. The UB wall is normal. No calculi seen.

UTERUS: It is anteverted and measures 69x42x52mm with ET=06 mm. It is normal in size, outline and echotexture. **Small hypoechoic lesion measuring 17x16 mm seen in posterior wall.**

Rt. OVARY: It measures 27x24 mm. It is normal. No mass lesion seen.


Lt. OVARY: It measures 24x30 mm. It is normal. No mass lesion seen.

RIF: No evidence of focal collection or mass lesion seen. Appendix is not visualized.

OTHERS: No e/o free fluid in the abdomen. No e/o lymphadenopathy. No e/o gut wall thickening. No mass lesion seen in the abdomen.

IMPRESSION: **ECTOPIC RIGHT KIDNEY; SMALL POSTERIOR WALL FIBROID.**

Pradeep Kumar C N, DNB
Consultant Radiologist.



Dr. PRADEEP KUMAR C N
MBBS DNB(RADIOLOGY)
Radiology



Patient Name : Mrs. C GEETHA

Age/Gender : 46 Y/F
