

Name : Mr. Md Mukhtar Ansari

Age: 31 Y

UHID:CELE.0000130445

Address : ecity

Sex: M

Plan : ARCOFEMI MEDIWHEEL MALE AHC CREDIT PAN
 INDIA OP AGREEMENT

OP Number:CELEOPV344017

Bill No :CELE-OCR-55874

Date : 17.03.2024 09:12

Sno	Service Type/ServiceName	Department
1	ARCOFEMI - MEDIWHEEL - FULL BODY ANNUAL PLUS MALE - 2D ECHO - PAN INDIA - FY2324	
1	GAMMA GLUTAMYL TRANSFERASE (GGT)	
2	2 D ECHO	
3	LIVER FUNCTION TEST (LFT)	
4	GLUCOSE, FASTING	
5	HEMOGRAM + PERIPHERAL SMEAR	
6	DIET CONSULTATION	
7	COMPLETE URINE EXAMINATION	
8	URINE GLUCOSE(POST PRANDIAL)	
9	PERIPHERAL SMEAR	
10	ECG	
11	RENAL PROFILE/RENAL FUNCTION TEST (RFT/KFT)	
12	DENTAL CONSULTATION - 15	
13	GLUCOSE, POST PRANDIAL (PP), 2 HOURS (POST MEAL)	
14	URINE GLUCOSE(FASTING)	
15	HbA1c, GLYCATED HEMOGLOBIN	
16	X-RAY CHEST PA	
17	ENT CONSULTATION -	
18	FITNESS BY GENERAL PHYSICIAN - 25	
19	BLOOD GROUP ABO AND RH FACTOR	
20	LIPID PROFILE	
21	BODY MASS INDEX (BMI)	
22	OPHTHAL BY GENERAL PHYSICIAN - 05	
23	ULTRASOUND - WHOLE ABDOMEN - 8 9.30	
24	THYROID PROFILE (TOTAL T3, TOTAL T4, TSH)	

Patient Name : Mr. Md Mukhtar Ansari
UHID : CELE.0000130445
Reported on : 17-03-2024 18:18
Adm/Consult Doctor :

Age : 31 Y M
OP Visit No : CELEOPV344017
Printed on : 19-03-2024 10:04
Ref Doctor : SELF

DEPARTMENT OF RADIOLOGY

X-RAY CHEST PA

Both lung fields and hila are normal .

No obvious active pleuro-parenchymal lesion seen .

Both costophrenic and cardiophrenic angles are clear .

Both diaphragms are normal in position and contour .


Thoracic wall and soft tissues appear normal.

CONCLUSION :

No obvious abnormality seen

Printed on:17-03-2024 18:18

---End of the Report---



Dr. VIGNESH K
MBBS, MD Radio-Diagnosis
Radiology

Apollo Health and Lifestyle Limited

(CIN - U85110TG2000PLC115819)

Regd. Office: 1-10-60/62, Ashoka Raghupathi Chambers, 5th Floor, Begumpet, Hyderabad, Telangana - 500 016.

Ph No: 040-4904 7777, Fax No: 4904 7744 | Email ID: enquiry@apollohl.com | www.apollohl.com

APOLLO CLINICS NETWORK KARNATAKA

Bangalore (Basavanagudi | Bellandur | Electronic City | Fraser Town | HSR Layout | Indira Nagar | JP Nagar | Kundalahalli | Koramangala | Sarjapur Road) **Mysore** (VV Mohalla)

Online appointments: www.apolloclinic.com

TO BOOK AN APPOINTMENT

1860 500 7788

NAME: MR. MD MUKHTAR ANSARI
AGE / SEX: 31 YRS/ MALE
DATE: 19/03/2024
REFERRED BY: ARCOFEMI

ABDOMINAL ULTRASONOGRAPHY REPORT

LIVER: appear normal in size and echogenicity. No focal lesion seen. The intra hepatic biliary and portal venous radicals are normal. Portal vein and CBD is normal

GALL BLADDER: moderately distended and appears normal. No abnormal wall thickening / pericholecystic fluid seen.

PANCREAS: Normal to the extent visualized.

SPLEEN: Measures 12.4 cm enlarged in size and echo texture. No focal lesion noted.

KIDNEYS: Both kidneys are normal in size and echo texture. Normal cortico-medullary differentiation is maintained. No calculus / hydronephrosis on both sides.

PELVIC ORGANS:

Urinary bladder is moderately distended and appears normal.

Prostate appear normal in size and echogenicity.

No free fluid in the abdomen and pelvis.

IMPRESSION:

- ***Mild splenomegaly.***

*To correlate clinically & with other investigations.
Not for medico-legal purpose*



DR. VIGNESH K

CONSULTANT RADIOLOGIST

Personal Details
UHID: 00XHE1PU6TN0RLV
PatientID: 130445
Name: MR MD MUKHTAR ANSARI
Age: 31
Gender: Male
Mobile: 9708654954

Pre-Existing Medical Conditions

Symptoms

Vitals

Measurements

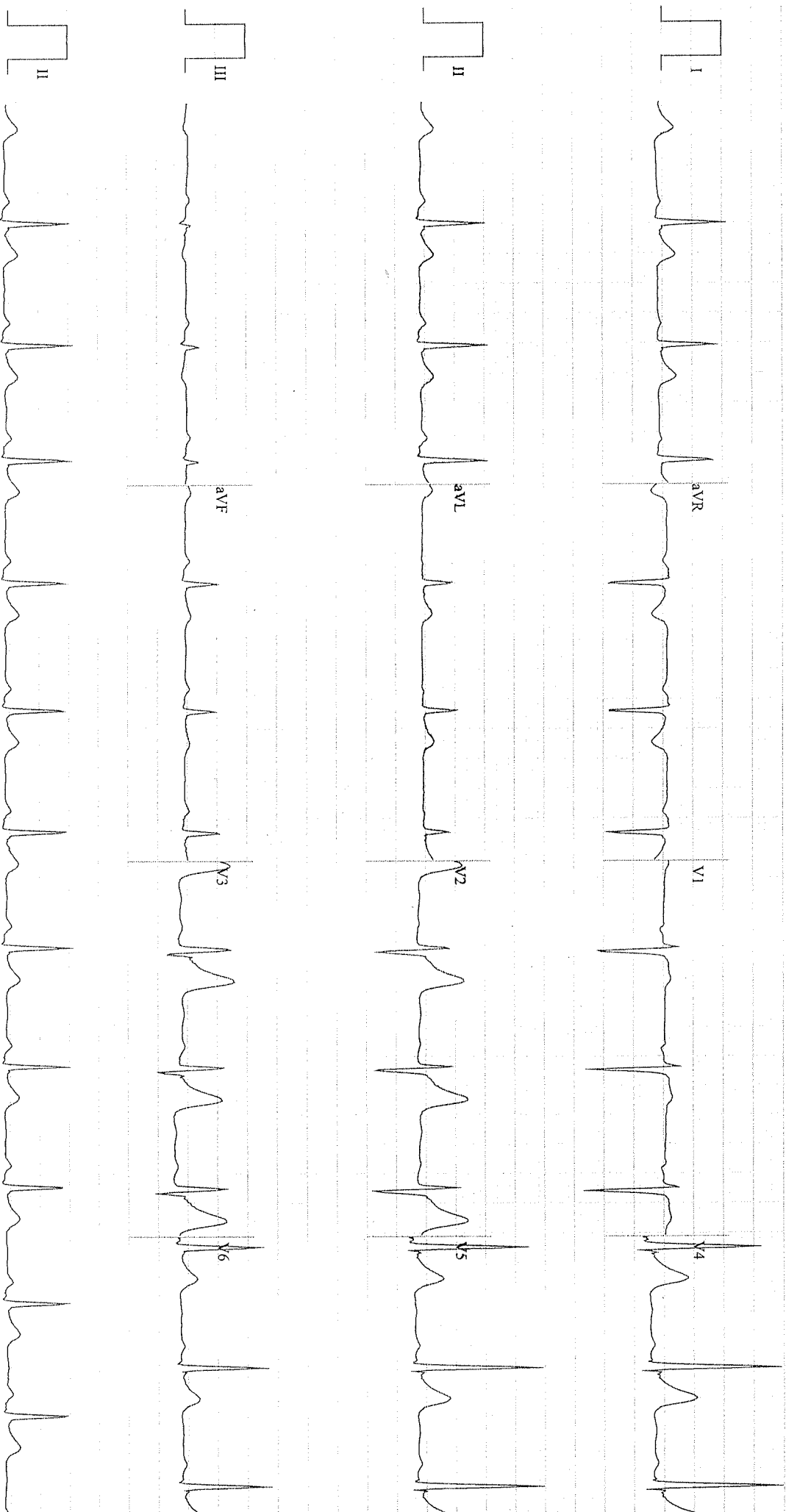
HR: 72 BPM
PR: 170 ms
PD: 125 ms
QRSD: 87 ms

QRS Axis: 32 deg
QT/QTc: 332/332 ms

Interpretation
Normal Sinus Rhythm
Normal Axis

Author:

Dr. Yogesh
M.D. DNB, J
Reg No- K



Speed: 25 mm/sec

F: 0.05 - 40 Hz

Limb: 10 mm/mV

Chest: 10 mm/mV

Disclaimer: This analysis is based on ECG data and should be used as an adjunct to clinical history. Symptoms and results of other non-invasive tests and must be interpreted by a qualified physician. Normal ECG does not rule out heart disease. Abnormal ECG does not always mean severe heart disease. Comments & report is based on available data. Clinical correlation is important.