

Name : Mrs. SUDHA KUMARI Age: 35 Y  
Sex: F  
Address : #14, 3RD FLOOR 7TH MAIN VENKTAPURA KORMANGALA  
Plan : ARCOFEMI MEDIWHEEL FEMALE AHC CREDIT PAN INDIA OP AGREEMENT

UHID:CHSR.0000060089



OP Number:CELEOPV342312

Bill No :CELE-OCR-55580

Date : 09.03.2024 08:31

Sno	Service Type/ServiceName	Department
1	ARCOFEMI - MEDIWHEEL - FULL BODY HC STARTER FEMALE - PAN INDIA - FY2324	
1	GAMMA GLUTAMYL TRANSFERASE (GGT) (12)	
2	LIVER FUNCTION TEST (LFT)	
3	GLUCOSE, FASTING	
4	HEMOGRAM + PERIPHERAL SMEAR	
5	GYNAECOLOGY CONSULTATION (16) - DR. KRISHNA SHAW	
6	DIET CONSULTATION (25) Completed with GP	
7	COMPLETE URINE EXAMINATION	
8	PERIPHERAL SMEAR	
9	ECG (13)	
10	LBC PAP-TEST- PAPSURE (16)	
11	RENAL PROFILE/RENAL FUNCTION TEST (RFT/KFT)	
12	DENTAL CONSULTATION (15)	
13	HbA1c, GLYCATED HEMOGLOBIN	
14	ENT CONSULTATION (6)	
15	FITNESS BY GENERAL PHYSICIAN (25)	
16	BLOOD GROUP ABO AND RH FACTOR	
17	LIPID PROFILE	
18	BODY MASS INDEX (BMI) (10)	
19	OPHTHAL BY GENERAL PHYSICIAN (5)	
20	ULTRASOUND - WHOLE ABDOMEN (8)	
21	THYROID PROFILE (TOTAL T3, TOTAL T4, TSH)	

V<sub>n</sub> → RE C/g NG  
LE C/g NG

Correction  
RE = -0.5 D SP  
LE = -0.5 D SP

**MEDICAL FITNESS CERTIFICATE**

**NAME:** Mrs. Sukha      **AGE/SEX:**      **UHID:**      **DATE:** 09/03/24

**CHIEF COMPLAINTS:**  
- c/o hairfall, c/o itching all over body (seasonal).

**PAST/FAMILY HISTORY:-**

Father - T2DM      Mother - HTN      Recent BP - 107/71

**ALLERGIES:-**

- Allergic to cold food / Amant

exp - 86 cm  
Abdomen - 91 cm  
Chest 90

**GENERAL EXAMINATION:-**

PULSE: 73 b/wt	BP: 115/79	TEMP: 98.6°F	RR: 22/min
HT: 154 cm	WT: 59.1	WAIST:	BMI: 24.7

**SYSTEMIC EXAMINATION:-**

RE = -0.5 DSP  
LE = -0.5 PSP

**VISION SCREENING**

<u>Vision</u>	<u>Rt</u>	<u>Lt</u>	<u>With Corrections</u>
<u>DISTANT</u>	6/9	6/9	-
<u>NEAR</u>	Nc	Nc	-
<u>COLOUR</u>			

old spectacles

**Chest:**  
**CVS:**  
**P/A:**

NAD.

**IMPRESSION:-**

**FINAL RECOMMENDATIONS:-**

C/S/B Dr. Yashaswini  
O/E  
Ear - B/L TMN (N) & intact.  
Nose - NAD  
Throat - NAD  
Clinically ENT - NAD



Dr. YASHASWINI, MBBS, DLO  
FELLOW IN RHINOLOGY  
ALLERGY SPECIALIST  
REG. No: 716435126633  
MOB: 9445089291 / 9945126633

**GENERAL PHYSICIAN**

Date: IST: 2024-03-09 08:38:52

**Personal Details**  
UHID: 00XHEIPU6TF0NYD  
PatientID: 60089  
Name: Mrs Sudha Kumari  
Age: 35  
Gender: Female  
Mobile: 9880903488

**Pre-Existing Medical-  
Conditions**


**Symptoms**

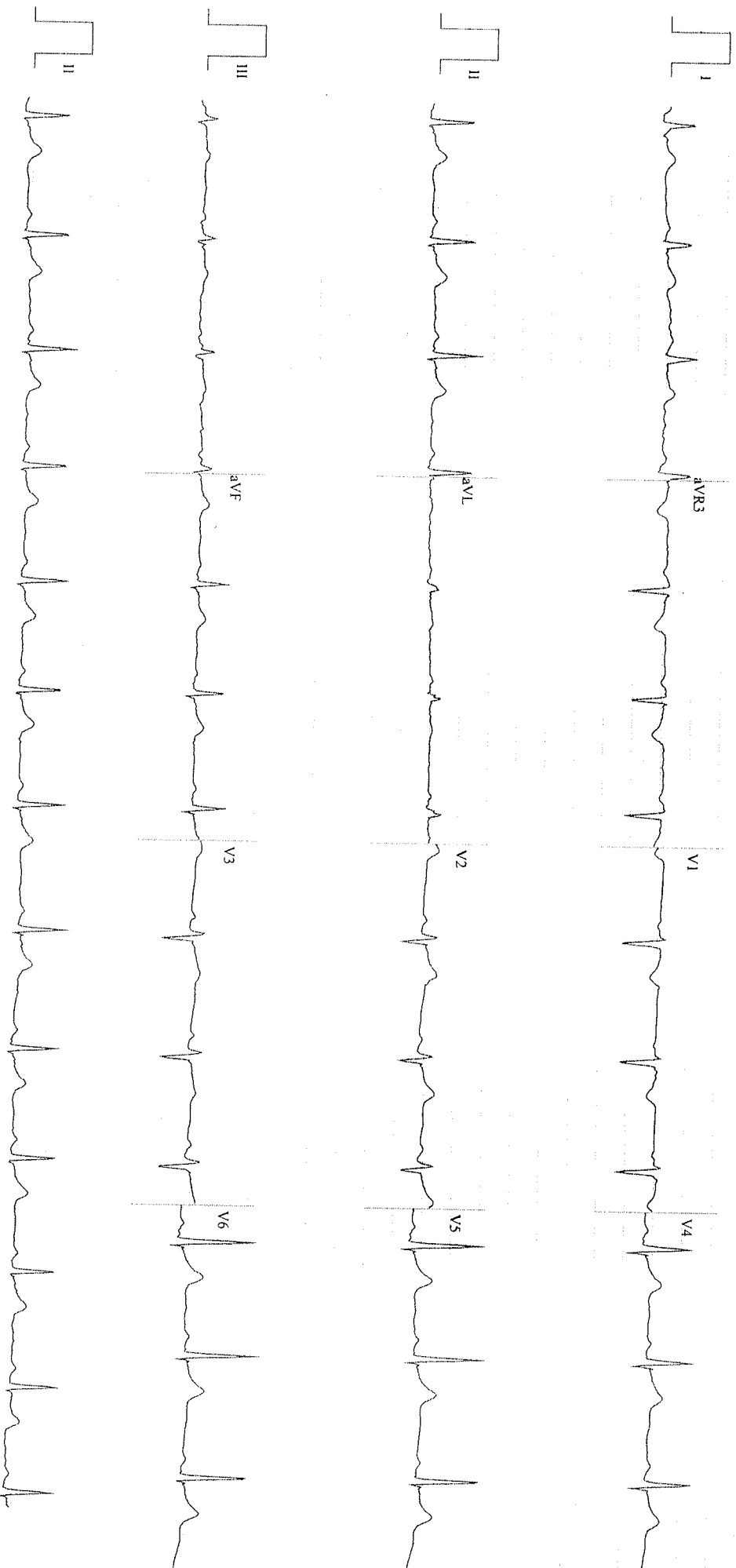
**Vitals**

**Measurements**  
HR: 73 BPM  
PR: 132 ms  
PD: 104 ms  
QRSD: 87 ms  
QRS Axis: 39 deg  
QT/QTc: 375/375 ms

Report ID: AHLIP\_00XHEIPU6TF0NYD\_V6TF000R  
**Interpretation**  
Sinus Rhythm Regular  
Normal Axis

**Apollo Medical  
Centre**  
Apollo Hospitals  
Gandhinagar, Chennai

Authorized by  
  
Dr. Yogesh Kothari  
MD, DNB, FESC, FEP  
Reg. No - KMC 44065



Disclaimer: 1. Analysis in this report is based on ECG alone and should be used as an adjunct to clinical history, symptoms and results of other non-invasive tests and not be interpreted as a qualified physician.  
2. Normal ECG does not rule out heart disease. Abnormal ECG does not always mean severe heart disease. Comments & report is based on available data. Clinical correlation is important.

Speed: 25 mm/sec F: 0.05 - 40 Hz Limb: 10 mm/mV Chest: 10 mm/mV

<b>NAME:</b>	MRS. SUDHA KUMARI
<b>AGE / SEX:</b>	35 YRS/ FEMALE
<b>DATE:</b>	09/03/2024
<b>REFERRED BY:</b>	ARCOFEMI

**ABDOMINAL ULTRASONOGRAPHY REPORT**

**LIVER:** Appear normal in size and echogenicity. No focal lesion seen. The intra hepatic biliary and portal venous radicals are normal. Portal vein and CBD is normal.

**GALL BLADDER:** moderately distended and appears normal. No abnormal wall thickening / pericholecystic fluid seen.

**Pancreas:** normal to the extend visualized.

**SPLEEN:** Normal in size and echo texture. No focal lesion noted

**KIDNEYS:** Both kidneys are normal in position, size and echo texture. Normal cortico-medullary differentiation is maintained. No calculus/ hydronephrosis on both sides.

**PELVIC ORGANS:**

Urinary bladder well distended and appears normal in size, contour and wall thickness.

Uterus appear normal in size and echo texture . Myometrial echoes appear normal.

**Anterior wall fibroid measuring 2x1.6 cm noted .**

ET measures ~ 8.6 mm.

Bilateral ovaries are normal in size, shape and echo texture.

No free fluid in the abdomen and pelvis.

**IMPRESSION:**

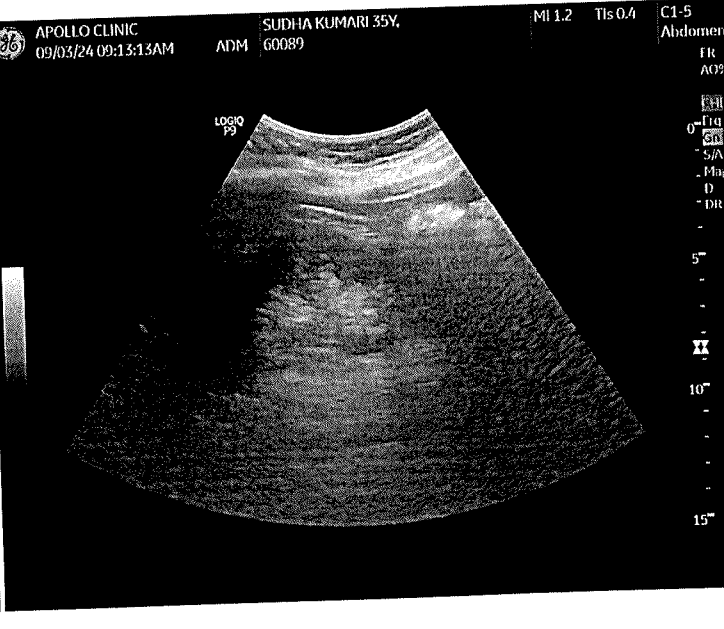
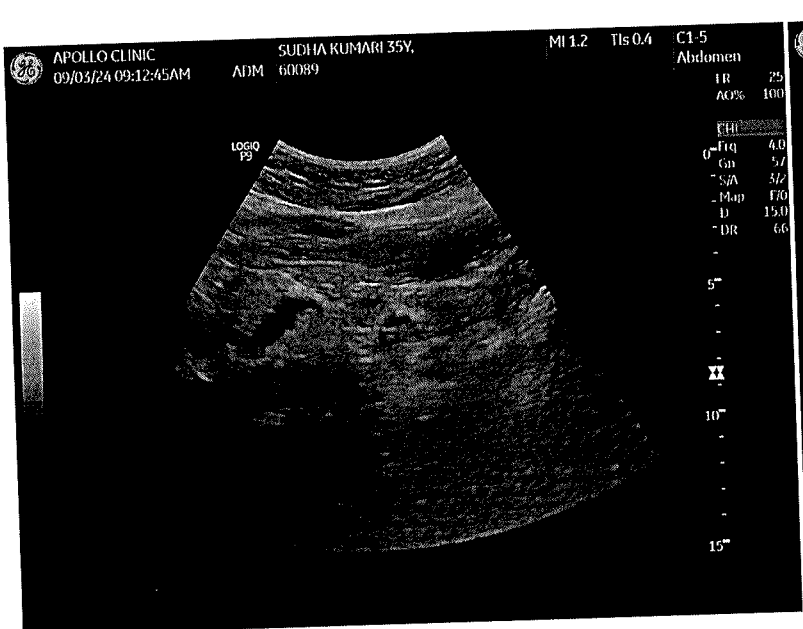
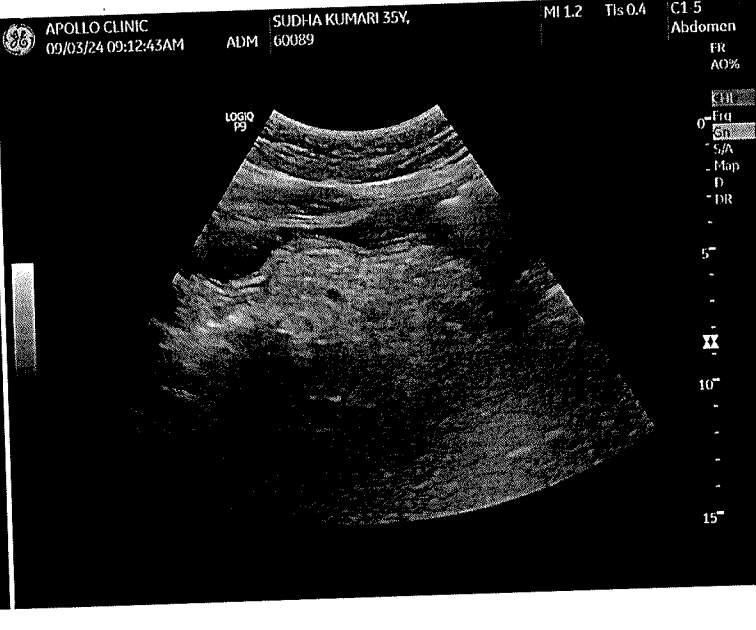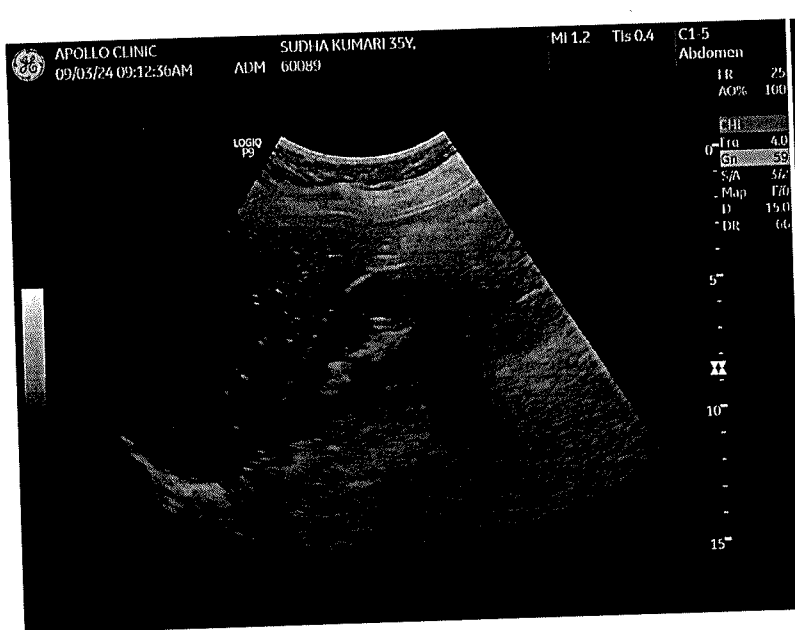
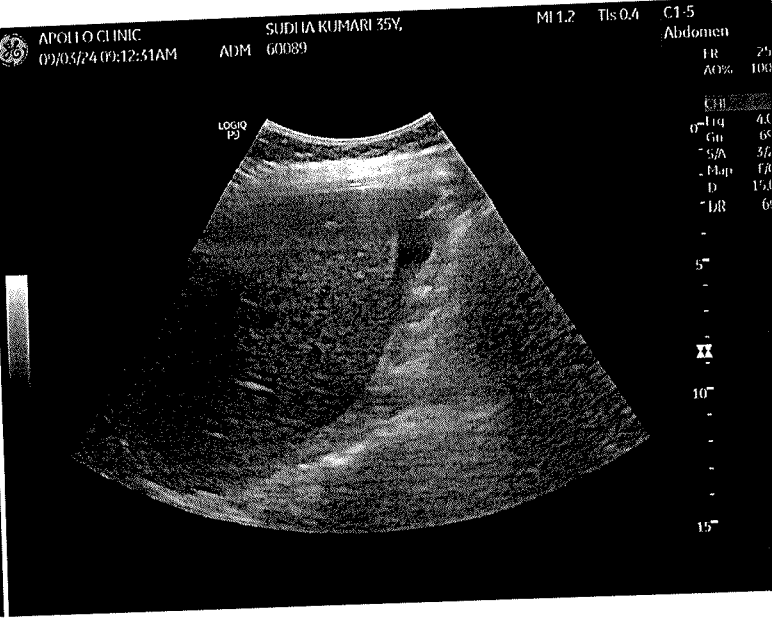
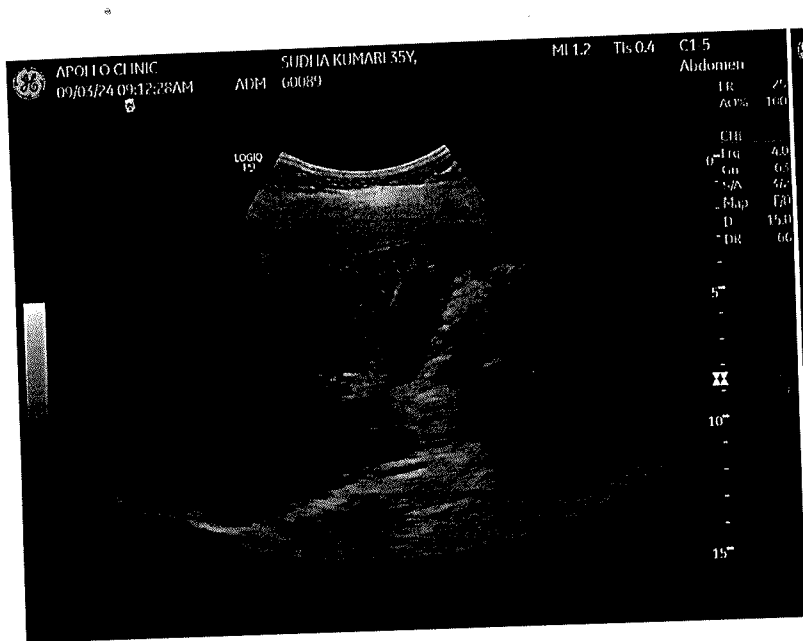- **Anterior wall fibroid as described**

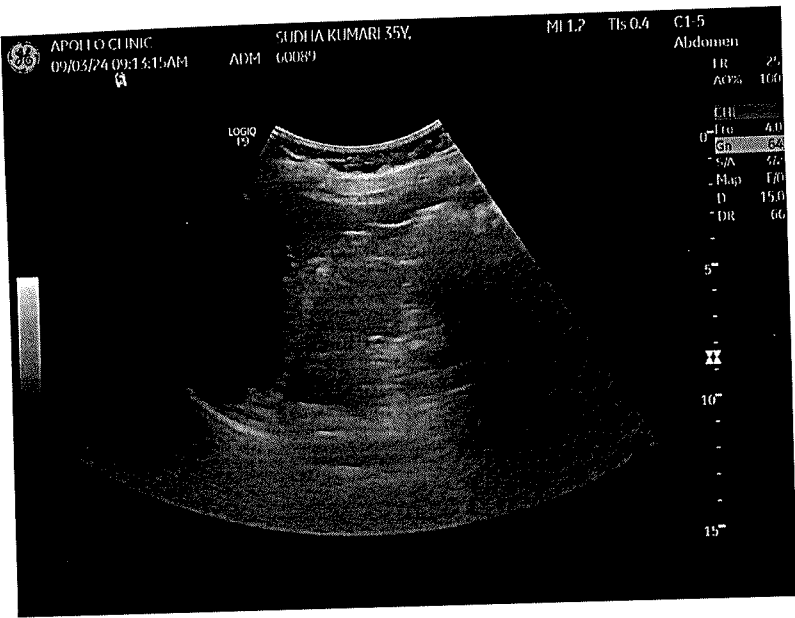
*To correlate clinically & with other investigations.  
Not for medico-legal purpose*



**DR. VIGNESH K**

**CONSULTANT RADIOLOGIST**





APOLLO CLINIC  
09/03/24 09:13:15AM

SUDHA KUMARI 35Y.  
ADM 00089

M1 1.2 Tls 0.4 C1-5

Abdomen  
FR 29  
ACFS 100  
FIR  
Fro 40  
Gh 88  
S/A 57  
Map 100  
D 150  
DR 66

5  
10  
15

# DENTAL SCRIPT



Date: 9/3/24

Patient ID: 60089 MHC

Patient Name: Sudha Kumari Age: 38 Sex: Male  Female

Main Complaint :

Medical History : —

Drug Allergy : ~

Medication currently taken by the Guest :

Initial Screenign Findings : RC 12 / CAP 76 / 67

Dental Caries :

Missing Teeth :

Impacted Teeth :

Attrition / Abrasion :

Bleeding :

Pockets / Recession :

Calculus / Stains : St

Mobility :

Restored Teeth :

Non - restorable Teeth for extraction /  
Root Stumps :

Malocclusion :

Others :

Advice :-

Scaling / y che cheep -

Doctor  
Name & Signature :

Mrs. Sudha Kumari 35 F

9/3/24

Dr. KRISHNA SHANKAR  
Gynae.

HC + LBC

Height :	Weight :	BMI :	Waist Circum :
Temp :	Pulse :	Resp :	B.P :

General Examination / Allergies  
History

Clinical Diagnosis & Management Plan

19/10 - NR

L.M.P 28/2/24.

P<sub>2</sub>L<sub>2</sub> Both ND. LCB 1.5 yrs feeding.

D/A. NAD

P/V.

P/S. Cr - (N) Hypertrophied.

R/L Br. NO lyp feeding  
Nadshy.

Adv -

R/W Reports,

- LBC.  
- usg.

*[Signature]*

Follow up date:

Doctor Signature





Government of India

Download Date: 18/10/2021



ಸುಧಾ ಕುಮಾರಿ  
Sudha Kumari  
ಜನ್ಮ ದಿನಾಂಕ/DOB: 08/01/1989  
♀/FEMALE

Issue Date: 05/10/2021

3926 2217 2911

VID : 9198 7355 1676 3520

ನನ್ನ ಆಧಾರ್. ನನ್ನ ಗುರುತು

Fwd: Health Check up Booking Confirmed Request(UBOIE3274),Package Code-PKG10000450, Beneficiary Code-304665

Sudha Kumari <kumarisudha09@gmail.com>

Sat 2024-03-09 8:01 AM

To: Electronic City <ecity@apolloclinic.com>

----- Forwarded message -----

From: **Mediwheel** <wellness@mediwheel.in>

Date: Wed, 28 Feb, 2024, 19:00

Subject: Health Check up Booking Confirmed Request(UBOIE3274),Package Code-PKG10000450, Beneficiary Code-304665

To: <kumarisudha09@gmail.com>

Cc: <customercare@mediwheel.in>

011-41195959

Dear **SUDHA KUMARI,**

We are pleased to confirm your health checkup booking request with the following details.

**Hospital Package Name** : Mediwheel Annual Health Checkup Female Starter

**Patient Package Name** : MediWheel Full Body Health Checkup Female 35 to 40

**Name of Diagnostic/Hospital** : Apollo Clinic - Electronic City

**Address of Diagnostic/Hospital-** : Apollo Clinic, 323/100, Opp.Ajmera infinity Apartment, Neeladri Nagar, Electronic city Phase -1, Electronic city - 560100

**City** : Bangalore

**State** :

**Pincode** : 560100

**Appointment Date** : 09-03-2024

**Confirmation Status** : Booking Confirmed

**Preferred Time** : 09:30 am - 10:00 am

**Booking Status** : Booking Confirmed

Member Information		
Booked Member Name	Age	Gender
SUDHA KUMARI	35 year	Female

Note - Please note to not pay any amount at the center.

Instructions to undergo Health Check: