

Name: mr gupta shailendra

Birth date: / /

57 years

1100 Sinus rhy .n
16007 Electronic ventricular pacemaker [pacemaker rhythm beat (beat 2)]

5211 Minimal voltage criteria for LVH, may be normal variant [R amp. (V5) > 3.0 mV]
0201 — Analysis based on intrinsic rhythm
9130 ** borderline ECG **

Indication:

Symptoms:

History:

lent. rate

R int

RS dur

IT/QTc(E) int

I/QRST axis

V5/SV1 amp

V5+SV1 amp

67 bpm

166 ms

92 ms

388/ 403 ms

61/ 30/ 38 °

3.15/ 0.96 mV

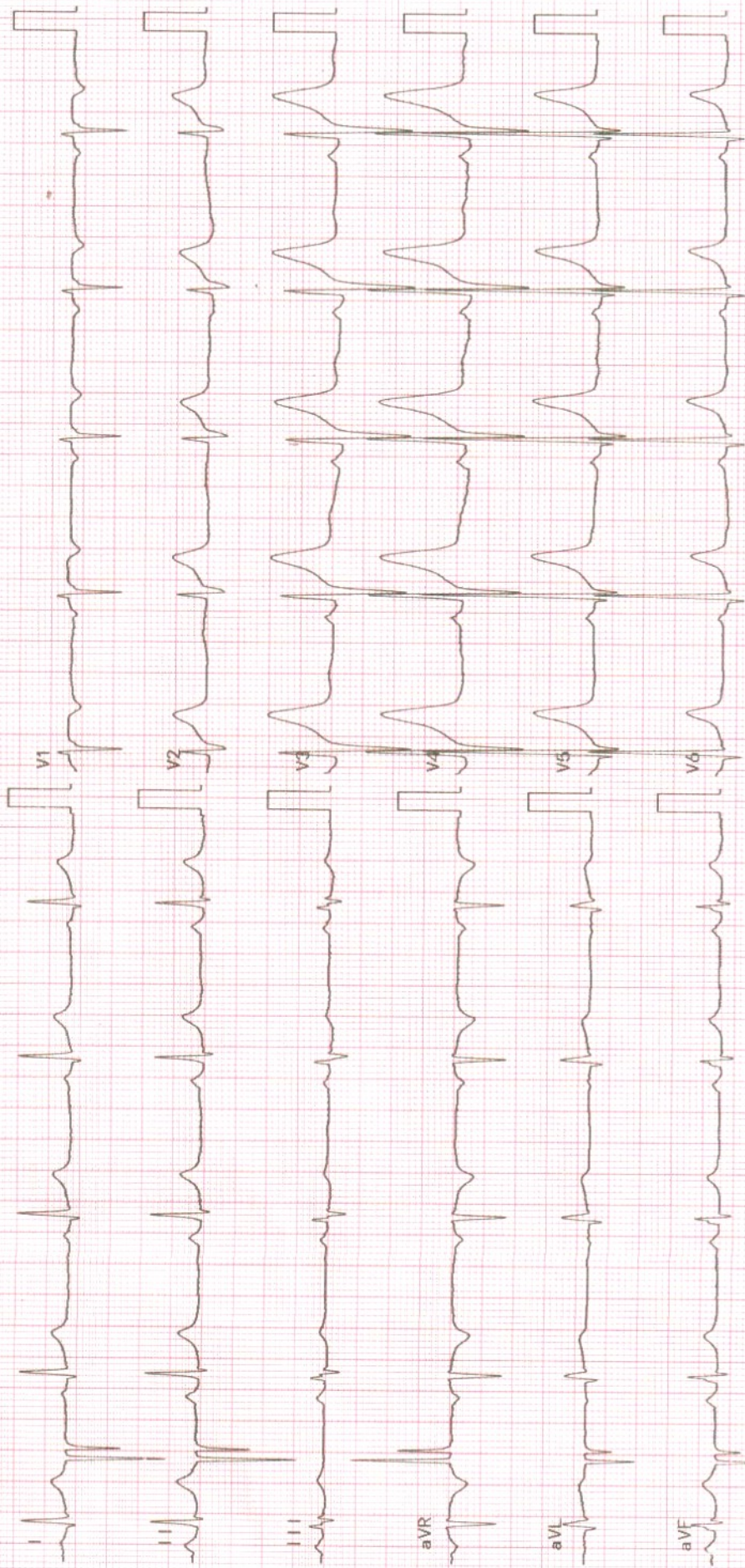
4.11 mV

10 mm/mV 25 mm/s

Filter: H50 D 35 Hz

10 mm/mV

Unconfirmed Report
Reviewed by:





NABH



NABL



No.1

**UNITED
HOSPITAL**Care Par Excellence
Jayanagar, Bangalore

Patient name :	Mr. GUPTA SHAILENDRA KUMAR	Date :	08/02/24
Age :	57 years GENDER: MALE	Patient ID :	17956
Ref by :	DR.CMO	OP/IP :	HEALTH CHECK

2D- ECHOCARDIOGRAPHY**M - MODE AND DOPPLER MEASUREMENTS**

(c.m)	(c.m)	(cm/sec)		
AO : 2.5 (2.5-3.7)	LVIDD : 3.9 (3.5-5.5)	MV EV : 62.4	AV : 81.3	MR : NORMAL
LA : 3.0 (1.9-4.0)	LVIDS : 3.6 (2.4-4.2)	AV : 125		AR : NORMAL
RA : 2.2 (<4.4)	IVSD : 0.8 (0.6-1.1)	PV : 96.4		PR : NORMAL
RV : 2.1 (<3.5)	IVSS : 1.1 (0.9-1.2)	TV EV : -----	AV : -----	TR : TRIVIAL TR
TAPSE: 1.8 (>1.6)	LVPWD : 0.9 (0.6-1.1)	Diastolic Function : GRADE 1 LVDD		
	LVPWS : 1.2 (0.9-1.2)			
	EF : 60%			

DESCRIPTIVE FINDINGS

Left Ventricle	: NORMAL
Right Ventricle	: NORMAL
Left Atrium	: NORMAL
Right Atrium	: NORMAL
Wall motion analysis:	NO RWMA
Mitral Valve	: NORMAL
Aortic Valve	: SCLEROTIC CHANGES, NON-STENOTIC, JET GRDT-5mmHg
Tricuspid Valve	: NORMAL, TRIVIAL TR
Pulmonary Valve	: NORMAL
IAS	: INTACT
IVS	: INTACT
Pericardium	: NORMAL
Other Findings	: IVC NORMAL

IMPRESSION :

SCLEROTIC AORTIC VALVE
 NORMAL LV SYSTOLIC FUNCTION EF : 60%
 GRADE 1 LV DIASTOLIC DYSFUNCTION
 NO PULMONARY HYPERTENSION
 NO REGIONAL WALL MOTION ABNORMALITIES
 NO CLOTS/ PERICARDIAL EFFUSION /VEGETATION

DR. RAHUL PATIL
CONSULTANT CARDIOLOGIST

UNITED HOSPITAL (A Unit of United Brothers Healthcare Services Private Limited)

United Hospital
No.110 (30), Madhavan Park Circle, 10th Main Rd,
3rd Block Jayanagar, Bangalore - 560 011

T: 080 4566 6666

E: appointments@unitedhospital.in
W: www.unitedhospitals.com



Out Patient Record

NABH Patient Name : Mr. GUPTA SHAILENDRA KUMAR
 NABL No.1
 Age / Sex : 57 Years / Male
 Spouse / Father Name :
 Address : # Flat No 004, Ground Floor Krishna Gardenia Apartment BCM Layout

UHID : UHJA23017956
 OP NO/Reg Dt : 08-02-2024 08:42 AM
 Department : Health check
 Referred By : medicwheel
 Consultant : Dr. Preventive Health Check Up
 KMC No. : Dr. Aat Shwella

Complaints / Findings / Observations :

Handwritten notes: V_n (glau) branching into 6/6 and 6/6, with a bracketed 4. Nil myopia.

Investigations:

Handwritten note: A/S OU normal

Treatment / Care of Plan / Provisional Diagnosis :

Handwritten notes: Fund's OU CDat 0.3:1 (undktd) FAEP

Follow Up Advice :

Handwritten notes: Ifn. OU chully normal except Refractive Error.

Handwritten note: Continue same glauis

Signature of the Doctor

Handwritten signature and date: 8/2/24

UNITED HOSPITAL (A Unit of United Brothers Healthcare Services Private Limited)

Out Patient Record

Patient Name : Mr.GUPTA SHAILENDRA KUMAR UHID : UHJA23017956
Age / Sex : 57 Years / Male OP NO/Reg Dt : 08-02-2024 08:42 AM
Spouse / Father Name : . . . Department : Health check
Address : # Flat No 004, Ground Floor Krishna Gardenia Apartment BCM Layout Referred By : Mediwheel
Consultant : Dr.Preventive Health Check Up
KMC No. : Dr. Anulecha

Complaints / Findings / Observations :

Regular health check up

SpO2 = 98%
PR = 80b/m
Bp = 130/80mmHg
HR = 176m
WT = 92 kg

Investigations:

Treatment / Care of Plan / Provisional Diagnosis :

Go

- Low fat diet, physical activity

Follow Up Advice :

①

cap. D - RBE

Box weekly one x 8 weeks

Medically fit





NABH



NABL



No.1

DEPARTMENT OF RADIODIAGNOSIS

Name	Gupta Shilendra Kumar	Date	08/02/24
Age	57 years	Hospital ID	UHJA23017956
Sex	Male	Ref.	Health check

ULTRASOUND ABDOMEN AND PELVIS

FINDINGS:

Liver is normal in size and echopattern. No intra or extra hepatic biliary duct dilatation. No focal lesions. **Portal vein** is normal in size, course and caliber. **CBD** is not dilated.

Gall bladder is normal without evidence of calculi, wall thickening or pericholecystic fluid.

Pancreas - Visualized part of the pancreatic head and body appears normal in size, contour and echogenicity. Rest of the pancreas is obscured by bowel gas.

Spleen is normal in size, shape, contour and echopattern. No focal lesion.

Right Kidney is normal in size (11.8 x 5.0 cms), position, shape and echopattern. Corticomedullary differentiation is maintained. No calculus or hydronephrosis. *Prominent extra renal pelvis is seen, measures 1.0 cms in AP dimension.*

Left Kidney is normal in size (11.1 x 4.2 cms), position, shape and echopattern. Corticomedullary differentiation is maintained. No calculus or hydronephrosis.

Retroperitoneum - Visualized aorta appeared normal. No obvious enlarged para-aortic nodes.

Urinary Bladder is distended, normal in contour and wall thickness. No evidence of calculi, mass or mural lesion.

Prostate is normal in echopattern and size, measures ~ 20 cc.

No ascites or pleural effusion. Appendix could not be localized. No RIF probe tenderness.

IMPRESSION:

- **No significant definite sonological abnormality detected.**



Dr. Elluru Santosh Kumar
Consultant Radiologist



NABH



NABL



No.1



Care Par Excellence
Jayanagar, Bangalore

DEPARTMENT OF RADIODIAGNOSIS

Name	Gupta Shilendra Kumar	Date	08/02/24
Age	57 years	Hospital ID	UHJA23017956
Sex	Male	Ref.	Health check

RADIOGRAPH OF THE CHEST (PA - VIEW)

FINDINGS:

Bilateral lung fields are normal.

Bilateral costo-phrenic angles are normal.

Cardia and mediastinal contours are normal.

The bony thorax is grossly normal.

IMPRESSION:

- No radiographic abnormality.

Dr. Elluru Santosh Kumar
Consultant Radiologist